

Anesthesiology  
1999; 91:1952-5  
© 1999 American Society of Anesthesiologists, Inc.  
Lippincott Williams & Wilkins, Inc.

## Epileptiform Discharges during 2 MAC Sevoflurane Anesthesia in Two Healthy Volunteers

Kaike K. Kaisti, M.D.,\* Satu K. Jääskeläinen, M.D.,† Juha O. Rinne, M.D.,‡ Liisa Metsähonkala, M.D.,§  
Harry Scheinin, M.D.||

VOLATILE anesthetics have divergent effects on cerebral neuronal activity; they suppress general activity, but may also have proconvulsant properties.<sup>1</sup> For example, the ability of enflurane to produce epileptic activity clearly is increased when it is administered at high concentrations with simultaneous hypocarbia,<sup>2</sup> and it has even been used for diagnostic activation of epileptic foci.<sup>3</sup>

Sevoflurane is a recently introduced volatile anesthetic. It is not considered to be epileptogenic but, in some animal models, has shown proconvulsant properties.<sup>4,5</sup> We report herein two electroencephalographic (EEG)-verified cases of epileptiform activity during the study of the effects of sevoflurane anesthesia on regional cerebral blood flow (rCBF). Assessments of rCBF were made using positron emission tomography (PET) with

injections of <sup>15</sup>O labeled water. Epileptiform discharges were noticed in two of eight subjects studied at 2 minimum alveolar concentration (MAC) anesthesia. The volunteers were young, right-handed, nonsmoking, male medical students. Prestudy evaluation, which included laboratory data and electrocardiograms (ECG), did not reveal any abnormal findings. The local ethics committee approved the study protocol and all subjects gave written, informed consent. Both subjects in this report confirmed having no personal or family history of seizure activity, neurologic symptoms, or drug allergies and that they were not taking any medications.

### Study Protocol

The subjects received no premedication and anesthesia was induced *via* mask with 7% sevoflurane in 100% oxygen. After the loss of eyelid reflex, subjects were administered 0.6 mg/kg rocuronium intravenously and a laryngeal mask was placed. Muscle relaxation was maintained with bolus doses of 10 mg intravenous rocuronium so that there was no more than one or two twitches to train-of-four nerve stimulation of the ulnar nerve at the wrist. A semiclosed ventilator system was used with 2.5 l of fresh gas flow of 30% oxygen-air mixture. The ET<sub>CO<sub>2</sub></sub> was kept at 4.5% by adjusting the tidal volume. Breathing frequency was set to 15 min<sup>-1</sup>.

In each subject, rCBF was assessed while the patient was awake and during anesthesia at 1 MAC, 1.5 MAC, and 2 MAC sevoflurane. The end-tidal concentration of anesthetic was increased in 0.5% steps at 30-min intervals, and two PET scans were obtained at 10-min intervals at the end of each level. During the flow scans, arterial radioactivity was measured with an on-line detector (Scanditronix, Uppsala, Sweden). The correction for delay and dispersion of the input function was made according to Iida *et al.*<sup>6</sup> The flow was calculated pixel by pixel using the autoradiographic method to attain para-

This article is featured in "This Month in Anesthesiology."  
Please see this issue of ANESTHESIOLOGY, page 7A.

\* Resident, Department of Anesthesiology, Turku University Hospital.

† Clinical Neurophysiologist, Department of Clinical Neurophysiology, Turku University Hospital.

‡ Professor, Turku PET Centre and Department of Neurology, University of Turku.

§ Staff Pediatrician, Department of Child Neurology, Turku University Hospital.

|| Professor, Turku PET Centre, and the Department of Pharmacology and Clinical Pharmacology, University of Turku.

Received from the Departments of Anesthesiology and Clinical Neurophysiology, Turku University Hospital, and the Turku PET Centre, University of Turku, Turku, Finland. Submitted for publication February 23, 1999. Accepted for publication July 15, 1999. Supported in part by the Turku University Hospital EVO grant No. 13323, Turku, Finland.

Address reprint requests to Dr. Scheinin: Department of Anesthesiology, Turku University Hospital, Turku, FIN-20520, Finland. Address electronic mail to: harry.scheinin@utu.fi

Key words: Adverse drug reaction; electroencephalography; positron emission tomography; cerebral blood flow.

## CASE REPORTS

metric images.<sup>7</sup> Regions of interest (ROI) were drawn on subjects' magnetic resonance images of the brain and were then used on PET images to obtain absolute values of rCBF.

All subjects underwent continuous EEG recording using digital EEG equipment (EasyEEG system, Cadwell, Kennewick, WA). Recording was initiated after induction and continued throughout the PET study. AgAgCl-electrodes and the 10-20 international electrode placement system were used. A four-channel montage covering the mid frontal-central and posterior temporal-occipital regions on both hemispheres was adopted, with three additional channels for recording eye movements, ECG, and surface electromyograph of the masticatory muscles. In addition, a BIS monitor (Aspect Medical Systems, Natick, MA) was used, with two active electrodes placed on the temples and one reference electrode placed on the midline of the forehead.<sup>8</sup>

### Case Reports

#### Case 1

Case 1 concerns the sixth subject of our study. The subject had been anesthetized for 1 h 40 min and was receiving 2 MAC sevoflurane when slight clonic movement was suddenly noticed first in the right and then in the left lower extremity. Sevoflurane concentration was decreased and at the time of PET (during the seizure) end-tidal sevoflurane was 3.1%. Peripheral oxygen saturation was never less than 97%. At the time of seizure, heart rate increased temporarily from 60–65  $\text{min}^{-1}$  to a maximum value of 79  $\text{min}^{-1}$ . The two consecutive values for systolic arterial pressure immediately before and after the seizure were 85 and 106 mmHg. End-tidal carbon dioxide ( $\text{ET}_{\text{CO}_2}$ ) increased from 33.8 mmHg to a maximum recorded value of 37.5 mmHg. Body temperature was not monitored, but the subject was well-covered and there was no shivering after anesthesia. The subject woke and recovered normally and was discharged 3.5 h after removal of laryngeal mask airway.

The electroencephalogram (EEG; fig. 1) was normal during wakefulness and showed normal anesthesia-related slowing when sevoflurane was administered. Before the seizure, at the 2-MAC level, the EEG showed a burst suppression pattern. As the EEG recording became inactive at the 2-MAC level, the Bispectral Index (BIS) decreased to zero. Ictal EEG recording showed rhythmic epileptiform discharge. This asymmetric EEG discharge pattern was fully compatible with the clinical seizure type (partial motor seizure). During the epileptiform discharge, the BIS value increased markedly, reaching its highest recorded value of 44.

Positron emission tomography results (fig. 2) showed that, at the 2-MAC level, rCBF was reduced to 49–80% of baseline values. The flow values of the ictal scan were symmetrically increased and were 87–135% compared with baseline values.

The native and contrast enhanced magnetic resonance image (1.5T) of the brain, results of a thorough clinical neurologic examination, and the sleep deprivation EEG were normal.

#### Case 2

Case 2 concerns the last subject of the study. The subject had been anesthetized for 1 h 25 min and was receiving 2 MAC sevoflurane when epileptiform activity was noticed on the EEG (fig. 1). Two partial, secondarily generalized EEG discharges lasted for 2 and 3 min, respectively, and they occurred 8 min apart. The second PET scan at 2 MAC was performed only 3 min after the first discharge. Peripheral oxygen saturation ( $\text{Sa}_{\text{O}_2}$ ) was 96–99%. Systolic arterial pressure immediately before and during the discharges were 88 and 105 mmHg, respectively. Heart rate remained at 65–70  $\text{min}^{-1}$ .  $\text{ET}_{\text{CO}_2}$  was 33.8 mmHg (whereas measured arterial partial pressure of carbon dioxide [ $\text{Pa}_{\text{CO}_2}$ ] = 34.2 mmHg). Nasopharyngeal temperature was 36.0°C. The subject woke and recovered normally and was discharged 3.5 h after the removal of the laryngeal mask airway.

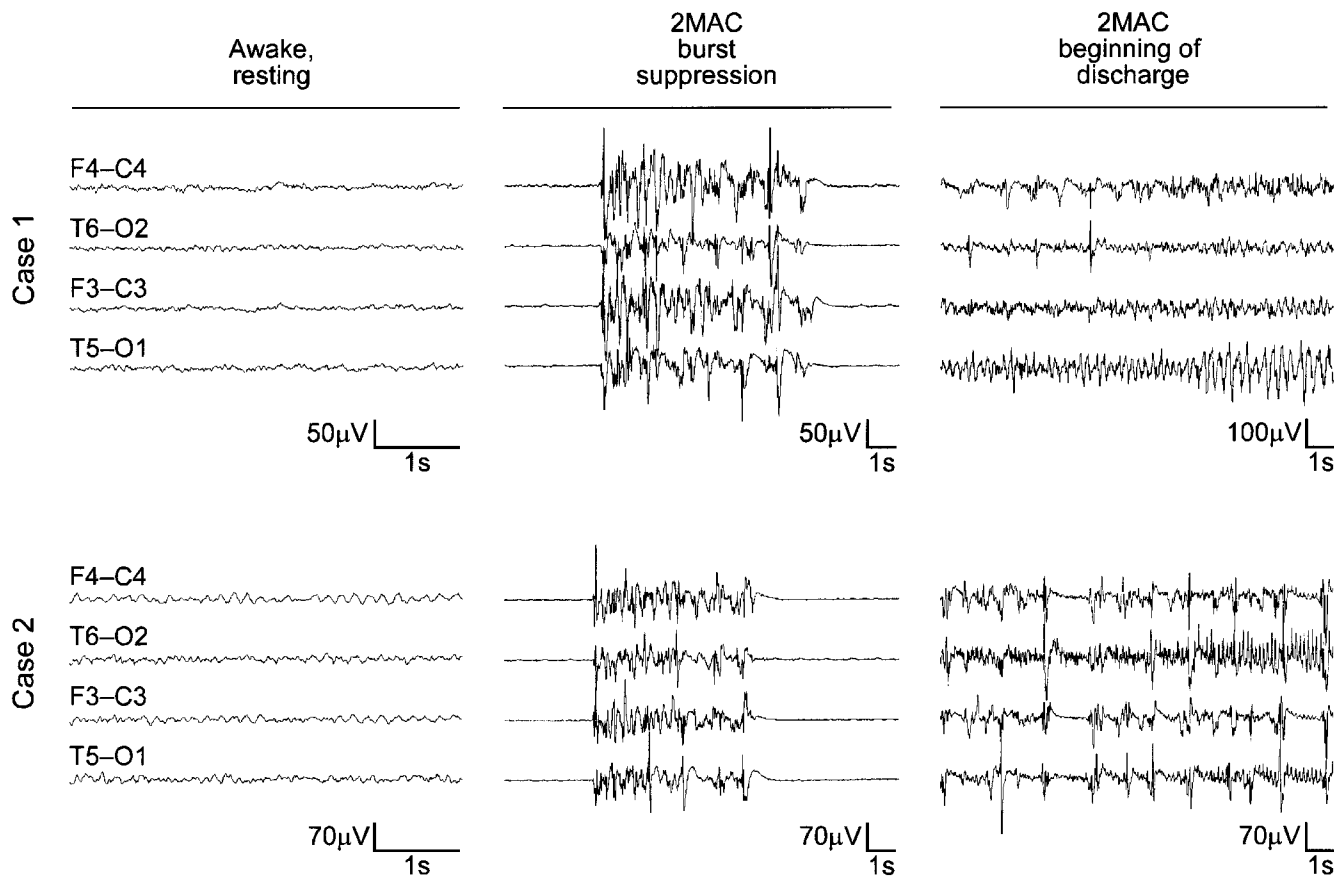
Before the induction of anesthesia, the EEG (fig. 1) showed slight general slowing. During the anesthesia, there was normal slowing of the EEG, and burst suppression appeared at the 1.5-MAC level. The BIS was reduced to 0–6 at the 2.0-MAC level. Two epileptiform discharges were recorded at the 2.0-MAC level of anesthesia without any clinical signs of an epileptic seizure. The BIS increased during both discharges, with recorded maximum values of 73 and 53.

The PET data (fig. 2) showed that, at the 2-MAC level, rCBF reduced to 40–59% of the baseline values. The second flow scan at 2 MAC was obtained after the first epileptic discharge, and rCBF values were 30–109% compared with baseline values, with clear increases in the right hemisphere.

The control EEG showed no epileptiform activity during sleep but, during wakefulness, the same mild, general slowing of background EEG activity was seen. The native and contrast-enhanced magnetic resonance images (1.5T) of the brain and the results from thorough clinical neurologic examination were normal.

### Discussion

We report epileptiform activity in two of eight healthy volunteers exposed to approximately 4% end-tidal sevoflurane. There are at least three previously reported cases of EEG discharges and two cases of epileptic seizures in clinical patients anesthetized with sevoflurane. Two pediatric patients with epilepsy were the only ones with histories of neurologic symptoms.<sup>9</sup> They had EEG-verified discharges during mask induction. In a young girl, an epileptic discharge was seen on a preoperative EEG during maintenance of hypotensive anesthesia for spinal fusion, with a sevoflurane concentration of 7%.<sup>10</sup> In another young girl, seizure occurred during mask induction of anesthesia for plastic surgery and, because it was resistant to medication, caused discontinuation of anesthesia.<sup>11</sup> In an appendectomy patient, the patient's left hand became spastic during maintenance, and tonic-clonic convulsion started when the patient was administered neostigmine at the end of the operation.<sup>12</sup> In all five cases, postoperative recovery and neurologic examination results were normal. There was no significant hypoxemia reported in any of the cases.



**Fig. 1.** Electroencephalograms (EEGs) (four-channel montage) in two healthy subjects showing activity awake, during anesthesia, and at the beginning of epileptiform discharges. Before the seizure, the EEG of the first subject showed a burst-suppression pattern with long suppression periods of up to 40 s. Ictal EEG showed rhythmic epileptiform discharge in the theta–delta frequency range, first in the left hemisphere for 100 s, and immediately thereafter for 80 s in the right hemisphere. Before the induction of anesthesia, the EEG of the second subject showed slight general slowing in the form of poorly organized, mixed beta–alpha–theta activity in the occipital derivations, and an increase of diffuse theta activity, with a slight predominance on the right side. Two partial, secondarily generalized electroencephalographic discharges lasted for 2 and 3 min, respectively, and they occurred 8 min apart. The first epileptiform discharge of the second subject began in the right hemisphere as a low-voltage beta rhythm that rapidly generalized and, at the same time, slowed down and increased in amplitude. The second epileptiform discharge started in the left hemisphere, and also spread to the other side.

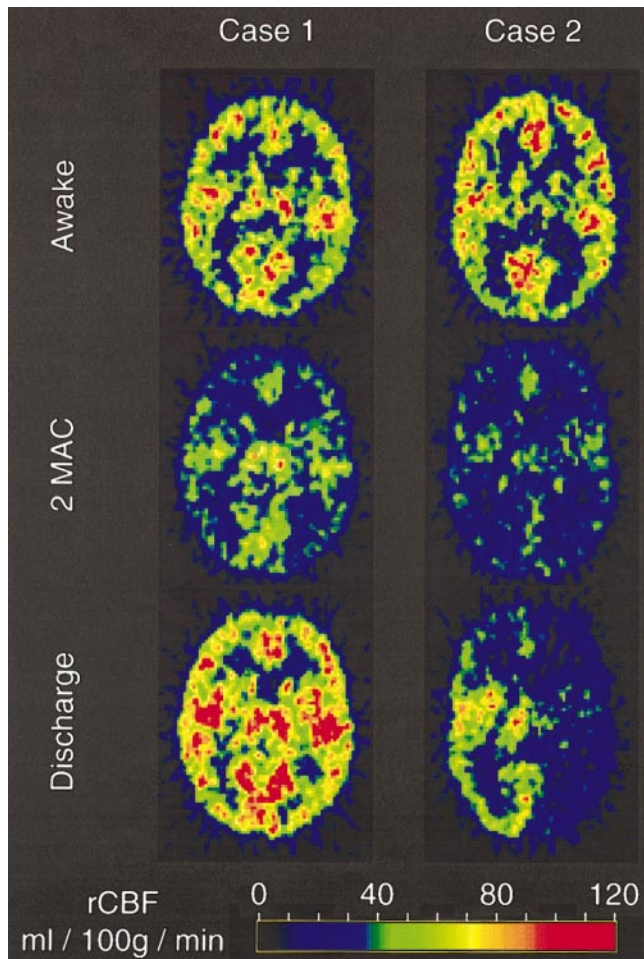
In the current study, sevoflurane was the only centrally active drug. The  $ET_{CO_2}$  and mean arterial pressure values were unremarkable in both cases. All PET studies were performed in a dimly lit room with no sudden loud noises. Subjects also wore earplugs and their ears were covered with a plastic head holder. Equipment for monitoring muscle relaxation and blood pressure were inactive when the discharges began.

Sevoflurane, 4%, and the total absence of surgical stimulation produced a state of burst suppression, with relatively long isoelectric episodes seen on the EEG. The visual appearance of these bursts had similar excitatory features as the bursts during deep enflurane anesthesia.<sup>13</sup>

During the epileptiform discharges the BIS value increased markedly. Simultaneously, the discharge activity was also visible on the raw EEG display of the monitor. We, therefore, suggest that when using on-line electrophysiologic monitoring devices, such as the BIS, the raw EEG signal should be checked if the derived parameters behave inconsistently.

Previously, PET and single photon emission computed tomography have been used to study regional cerebral flow and metabolism of epileptic patients and to locate epileptic foci for possible operative treatment. In comparison to normal brain tissue, the area of epileptic focus has decreased rCBF and regional metabolism interictally and increased ictally.<sup>14</sup> Our findings of increased rCBF





**Fig. 2.**  $H_2^{15}O$  positron emission tomography images at 7 cm above the orbitomeatal line of two healthy subjects, showing regional cerebral blood flow (rCBF) while awake and during sevoflurane anesthesia. During 2 MAC anesthesia, rCBF was uniformly reduced in both subjects. In the first case, epileptic discharges concerning both hemispheres caused a symmetric increase in the simultaneous flow scan at 3.1% sevoflurane. In the second case, epileptic discharge in the right hemisphere caused an ipsilateral increase in the immediately postictal flow scan at 4% sevoflurane.

correlate well with simultaneous EEG data and agree with previous studies.

We conclude that sevoflurane appears to have epileptogenic potential in healthy patients during burst-suppression anesthesia. Although the implications of our findings are unclear, experimental data indicate that pro-

longed epileptiform discharge itself may be harmful.<sup>15</sup> Therefore, further human studies are warranted.

## References

1. Modica PA, Tempelhoff R, White PF: Pro- and anticonvulsant effects of anesthetics: I. *Anesth Analg* 1990; 70(3):303-15
2. Neigh JL, Garman JK, Harp JR: The electroencephalographic pattern during anesthesia with Ethrane: Effects of depth of anesthesia, PaCO<sub>2</sub>, and nitrous oxide. *ANESTHESIOLOGY* 1971; 35(5):482-7
3. Flemming DC, Fitzpatrick J, Fariello RG, Duff T, Hellman D, Hoff BH: Diagnostic activation of epileptic foci by enflurane. *ANESTHESIOLOGY* 1980; 52(5):431-3
4. Osawa M, Shingu K, Murakawa M, Adachi T, Kurata J, Seo N, Murayama T, Nakao S, Mori K: Effects of sevoflurane on central nervous system electrical activity in cats. *Anesth Analg* 1994; 79(1):52-7
5. Scheller MS, Nakakimura K, Fleischer JE, Zornow MH: Cerebral effects of sevoflurane in the dog: Comparison with isoflurane and enflurane. *Br J Anaesth* 1990; 65(3):388-92
6. Iida H, Kanno I, Miura S, Murakami M, Takahashi K, Uemura K: Error analysis of a quantitative cerebral blood flow measurement using  $H_2^{15}O$  autoradiography and positron emission tomography, with respect to the dispersion of the input function. *J Cereb Blood Flow Metab* 1986; 6(5):536-45
7. Howard BE, Ginsberg MD, Hassel WR, Lockwood AH, Freed P: On the uniqueness of cerebral blood flow measured by the in vivo autoradiographic strategy and positron emission tomography. *J Cereb Blood Flow Metab* 1983; 3(4):432-41
8. Rampil IJ: A primer for EEG signal processing in anesthesia. *ANESTHESIOLOGY* 1998; 89(4):980-1002
9. Komatsu H, Taie S, Endo S, Fukuda K, Ueki M, Nogaya J, Ogi K: Electrical seizures during sevoflurane anesthesia in two pediatric patients with epilepsy. *ANESTHESIOLOGY* 1994; 81(6):1535-7
10. Woodforth IJ, Hicks RG, Crawford MR, Stephen JP, Burke DJ: Electroencephalographic evidence of seizure activity under deep sevoflurane anesthesia in a nonepileptic patient. *ANESTHESIOLOGY* 1997; 87(6):1579-82
11. Adachi M, Ikemoto Y, Kubo K, Takuma C: Seizure-like movements during induction of anaesthesia with sevoflurane. *Br J Anaesth* 1992; 68(2):214-5
12. Terasako K, Ishii S: Postoperative seizure-like activity following sevoflurane anesthesia. *Acta Anaesth* 1996; 40:953-4
13. Rosén I, Södenberg M: Electroencephalographic activity in children under enflurane anesthesia. *Acta Anaesth Scand* 1975; 19(5):361-9
14. Franck G, Sadzot B, Salmon E, Depresseux JC, Grisar T, Peters JM: Regional cerebral blood flow and metabolic rates in human focal epilepsy and status epilepticus. *Adv Neurol* 1986; 44:935-48
15. Thompson SM, Fortunato C, McKinney RA, Muller M, Gahwiler BH: Mechanisms underlying the neuropathological consequences of epileptic activity in the rat hippocampus in vitro. *J Comp Neurol* 1996; 372(4):515-28