

Anesthesiology
 1999; 91:1964-5
 © 1999 American Society of Anesthesiologists, Inc.
 Lippincott Williams & Wilkins, Inc.

The Three Axis Alignment Theory and the “Sniffing Position”: Perpetuation of an Anatomic Myth?

To the Editor:—A review of the classic anesthesiology literature reveals a common thread in the instructions for direct laryngoscopy: To successfully visualize the larynx, one must align three (oral, laryngeal, and pharyngeal) anatomic axes.¹⁻⁷ Placing a patient in the “sniffing position” is the accepted maneuver for aligning these axes.

Recently, we evaluated a radiograph obtained during intubation in the sniffing position, drew lines along the axes (fig. 1), and did not observe this alignment. We then reviewed the literature to understand the origin of this concept. The sniffing position has been credited to Chevalier Jackson in 1913, although he did not use this terminology or demonstrate alignment of the axes diagrammatically. He simply suggested that the patient be placed on a pillow in a natural position with the head extended.⁸ He went on to suggest that, in fact, the pillow might be removed, the thumbs placed on the forehead of the patient, and the forehead vigorously forced downward and backward, causing an anterior movement of the skull on the atlas and throwing the cervical vertebrae forward.

After this proposal by Jackson, numerous authors offered their modifications of the technique. However, the first (only?) authors to study the problem experimentally were Bannister and MacBeth,⁹ whose frequently cited 1944 *Lancet* article graphically demonstrates the alignment of the three axes by use of an added pillow beneath the occiput, thus flexing the neck.⁹ The authors then propose that straightening the right angle formed by the axis of the mouth and the pharyngolaryngeal axis requires extension of the head on the atlantooccipital joint. They support their view with a series of drawings and radiographs. Although the authors' drawings illustrate plainly that the axes may be brought into complete alignment, close examination of the radiographs shows that the drawing did not coincide with the radiograph. Whereas the hard palate is aligned with the larynx in the drawing, the angle of the larynx to the hard palate in the radiograph is roughly 36°. If one compares radiographs in the article, it becomes apparent that the laryngoscope shown in one radiograph (patient in sniffing position) is not in the mouth. Otherwise this patient would be missing all the upper incisors. Perhaps this is what was referred to previously in the article as “cooking” a diagram. In spite of this, the “three-axes rule” became reality.

It would appear to us that, although the sniffing position may provide the best laryngeal view, the explanation of the benefit of the sniffing position based on alignment of the three axes is an error perpetuated since 1944 that deserves reexamination.

Frédéric Adnet, M.D., Ph.D.
 Assistant Professor
 Department of Anesthesiology
 Hôpital Avicenne, University Paris XIII
 Paris, France
 frederic.adnet@avc.ap-hop-paris.fr

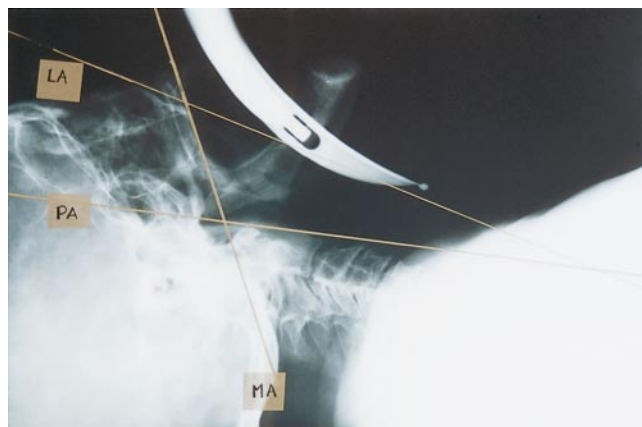

Fig. 1. Intubation in sniffing position. LA = laryngeal axis; MA = mouth axis; PA = pharyngeal axis.

Stephen W. Borron, M.D., M.S.

Visiting Researcher
 Toxicological Intensive Care Unit
 INSERM U-26
 Hôpital Fernand Widal
 University Paris VII
 Paris, France

Frédéric Lapostolle, M.D.

Assistant Professor
 Department of Anesthesiology
 Hôpital Avicenne, University Paris XIII
 Paris, France

Claude Lapandry, M.D.

Assistant Professor
 Department of Anesthesiology
 Hôpital Avicenne, University Paris XIII
 Paris, France

References

1. Stoelting RK: Endotracheal intubation, *Anesthesia*. Edited by Miller RD. New York, Churchill Livingstone, 1986, pp 523-32
2. Finucane BT, Santora AH: Techniques of intubation, *Airway Management*. Edited by Finucane BT, Santora AH. St. Louis, Mosby, 1996, pp 161-86
3. Société Française d'Anesthésie et de Réanimation: Intubation difficile. *Ann Fr Anesth Réanim* 1996; 15:207-14
4. Benumof JL: Conventional (laryngoscopic) orotracheal and nasotracheal intubation (single-lumen tube), *Airway Management*, Princi-

CORRESPONDENCE

ples and Practices. Edited by Benumof JL. St Louis, Mosby, 1996, pp 261-76

5. Murrin KR: Causes of difficult intubation and intubation procedure, Difficulties in Tracheal Intubation. Edited by Latta IP, Vaughan RS. London, WB Saunders Company, 1997, pp 89-106

6. Schwartz DE, Wiener-Kronish JP: Management of difficult airway. Clin Chest Med 1991; 12:483-95

7. Scott J: Oral endotracheal intubation, The Airway: Emergency

Management. Edited by Dailey RH, Simon B, Young GP, Stewart RD. St. Louis, Mosby-Year Book, 1992, pp 73-91

8. Jackson C: The technique of insertion of intratracheal insufflation tubes. Surg Gynecol Obstet 1913; 17:507-9

9. Bannister FB, Macbeth RG: Direct laryngoscopy and tracheal intubation. Lancet 1944; ii:651-4

(Accepted for publication June 22, 1999.)

Anesthesiology
1999; 91:1965-6
© 1999 American Society of Anesthesiologists, Inc.
Lippincott Williams & Wilkins, Inc.

Attempted Placement of a Thoracic Epidural Catheter *via* the Caudal Route in a Newborn

To the Editor:—Inadvertent placement of an epidural catheter in the presacral area *via* the caudal route is described in a full-term infant who underwent repair of tracheoesophageal fistula.

A 3.1-kg full-term boy infant with a prenatal diagnosis of tracheoesophageal fistula with esophageal atresia and left pulmonary agenesis presented at birth with respiratory distress. Routine monitors were placed in the operating room, and after preoxygenation an awake tracheal intubation was performed. Anesthesia was maintained with isoflurane, oxygen, and air with the infant breathing spontaneously. Chest and abdominal radiograms showed no vertebral anomalies. An epidural catheter was inserted in the caudal space using a sterile technique to facilitate perioperative pain management and early tracheal extubation. An 18-gauge angiocatheter was placed in the caudal space and a 20-gauge polyamide epidural catheter was advanced into the epidural space *via* the angiocatheter. No cerebrospinal fluid or blood was noted. The catheter was advanced with ease to the anticipated length for mid thoracic placement. No tachycardia, dysrhythmia, or increase in blood pressure was recorded after a test dose of 0.3 ml lidocaine, 1.5%, with epinephrine (1:200,000). An open gastrostomy was then performed. A loading dose of 1.5 ml bupivacaine solution, 0.125%, was given *via* the epidural catheter. This was followed by a continuous infusion of 0.05% bupivacaine and fentanyl (1 μ g/ml) at 1 ml/h. The end-tidal concentration of isoflurane was kept constant during the gastrostomy, and no changes in the patient's blood pressure and heart rate were noted. Routine epidurography with 0.5 ml contrast (iohexol, 180 mg/ml) showed the catheter coiled in the presacral space (fig. 1). The epidural infusion was discontinued.

The patient was then positioned for a right posterolateral thoracotomy. The fistula was ligated and divided, and the esophageal anastomosis was performed without complication. The caudally placed catheter was removed and replaced at the end of surgery. During a sterile technique, an 18-gauge Crawford epidural needle was placed in the caudal space. No blood or cerebrospinal fluid was noted. A 20-gauge polyamide epidural catheter was easily advanced to a premeasured distance from the caudal space to the mid thoracic area. An epidurogram (0.5 ml iohexol, 180 mg/ml) confirmed the tip of the catheter at the mid thoracic level and absorption of the contrast from the presacral space (fig. 2). No tachycardia, dysrhythmia, or increase in blood pres-

sure was seen after a test dose of 0.3 ml lidocaine, 1.5%, with epinephrine (1:200,000). The epidural catheter was infused with 0.05% bupivacaine and fentanyl (1 μ g/ml) at 1 ml/h. The patient was breathing spontaneously and underwent ventilation at arrival to the intensive care unit. Fentanyl was removed from the epidural infusion and the analgesia was adequate. The patient was weaned from the ventilator and the trachea was extubated in the next 24 h. The epidural catheter was removed on the fourth postoperative day.

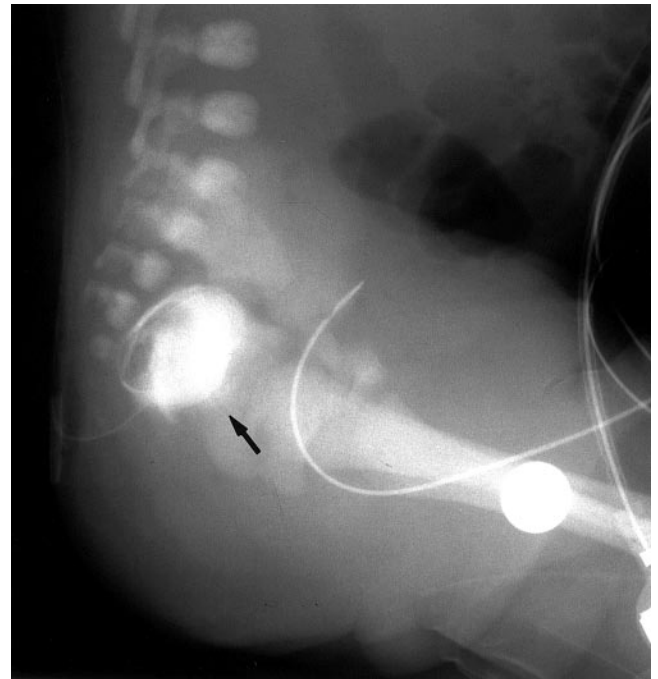


Fig. 1. Pelvic radiogram in the lateral view showing contrast medium in the presacral space (arrow) and a coiled epidural catheter.