

CORRESPONDENCE

ples and Practices. Edited by Benumof JL. St Louis, Mosby, 1996, pp 261-76

5. Murrin KR: Causes of difficult intubation and intubation procedure, Difficulties in Tracheal Intubation. Edited by Latta IP, Vaughan RS. London, WB Saunders Company, 1997, pp 89-106

6. Schwartz DE, Wiener-Kronish JP: Management of difficult airway. Clin Chest Med 1991; 12:483-95

7. Scott J: Oral endotracheal intubation, The Airway: Emergency

Management. Edited by Dailey RH, Simon B, Young GP, Stewart RD. St. Louis, Mosby-Year Book, 1992, pp 73-91

8. Jackson C: The technique of insertion of intratracheal insufflation tubes. Surg Gynecol Obstet 1913; 17:507-9

9. Bannister FB, Macbeth RG: Direct laryngoscopy and tracheal intubation. Lancet 1944; ii:651-4

(Accepted for publication June 22, 1999.)

Anesthesiology
1999; 91:1965-6
© 1999 American Society of Anesthesiologists, Inc.
Lippincott Williams & Wilkins, Inc.

Attempted Placement of a Thoracic Epidural Catheter *via* the Caudal Route in a Newborn

To the Editor:—Inadvertent placement of an epidural catheter in the presacral area *via* the caudal route is described in a full-term infant who underwent repair of tracheoesophageal fistula.

A 3.1-kg full-term boy infant with a prenatal diagnosis of tracheoesophageal fistula with esophageal atresia and left pulmonary agenesis presented at birth with respiratory distress. Routine monitors were placed in the operating room, and after preoxygenation an awake tracheal intubation was performed. Anesthesia was maintained with isoflurane, oxygen, and air with the infant breathing spontaneously. Chest and abdominal radiograms showed no vertebral anomalies. An epidural catheter was inserted in the caudal space using a sterile technique to facilitate perioperative pain management and early tracheal extubation. An 18-gauge angiocatheter was placed in the caudal space and a 20-gauge polyamide epidural catheter was advanced into the epidural space *via* the angiocatheter. No cerebrospinal fluid or blood was noted. The catheter was advanced with ease to the anticipated length for mid thoracic placement. No tachycardia, dysrhythmia, or increase in blood pressure was recorded after a test dose of 0.3 ml lidocaine, 1.5%, with epinephrine (1:200,000). An open gastrostomy was then performed. A loading dose of 1.5 ml bupivacaine solution, 0.125%, was given *via* the epidural catheter. This was followed by a continuous infusion of 0.05% bupivacaine and fentanyl (1 μ g/ml) at 1 ml/h. The end-tidal concentration of isoflurane was kept constant during the gastrostomy, and no changes in the patient's blood pressure and heart rate were noted. Routine epidurography with 0.5 ml contrast (iohexol, 180 mg/ml) showed the catheter coiled in the presacral space (fig. 1). The epidural infusion was discontinued.

The patient was then positioned for a right posterolateral thoracotomy. The fistula was ligated and divided, and the esophageal anastomosis was performed without complication. The caudally placed catheter was removed and replaced at the end of surgery. During a sterile technique, an 18-gauge Crawford epidural needle was placed in the caudal space. No blood or cerebrospinal fluid was noted. A 20-gauge polyamide epidural catheter was easily advanced to a premeasured distance from the caudal space to the mid thoracic area. An epidurogram (0.5 ml iohexol, 180 mg/ml) confirmed the tip of the catheter at the mid thoracic level and absorption of the contrast from the presacral space (fig. 2). No tachycardia, dysrhythmia, or increase in blood pres-

sure was seen after a test dose of 0.3 ml lidocaine, 1.5%, with epinephrine (1:200,000). The epidural catheter was infused with 0.05% bupivacaine and fentanyl (1 μ g/ml) at 1 ml/h. The patient was breathing spontaneously and underwent ventilation at arrival to the intensive care unit. Fentanyl was removed from the epidural infusion and the analgesia was adequate. The patient was weaned from the ventilator and the trachea was extubated in the next 24 h. The epidural catheter was removed on the fourth postoperative day.

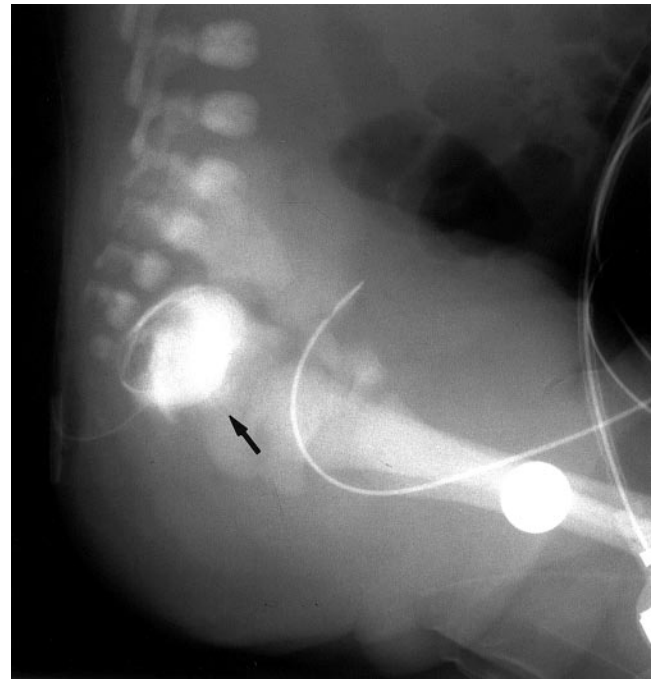


Fig. 1. Pelvic radiogram in the lateral view showing contrast medium in the presacral space (arrow) and a coiled epidural catheter.

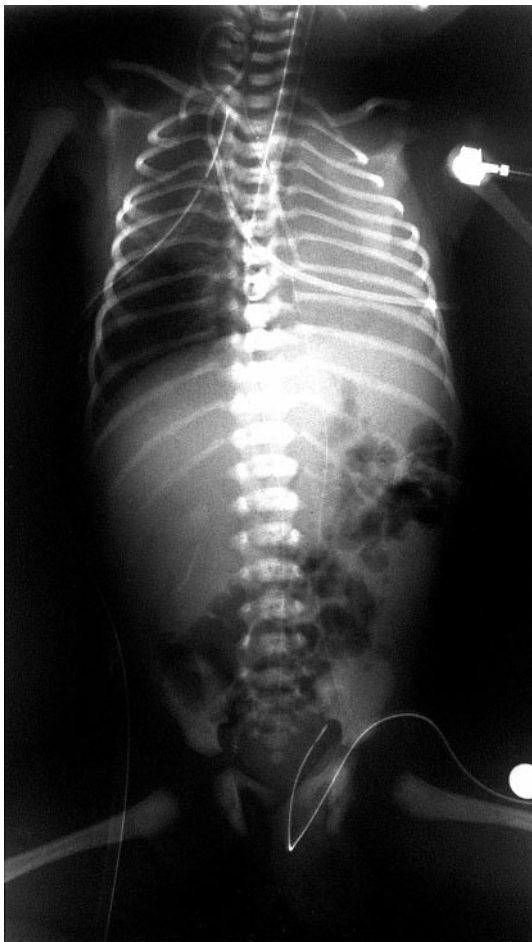

Figure 2. Chest and abdomen radiograms. Epidurogram showing thoracic placement of the catheter tip. Note resolution of previously opacified presacral space.

Thoracic epidural anesthesia *via* the caudal approach has been reported with success in neonates and infants. Gunter and Eng¹ were able to place a thoracic epidural using the caudal approach in 19 of 20 children. However, Blanco *et al.*² reported a lower success rate when attempting thoracic epidural placement from the lumbar region in children. They also found that the ease of advancement of the epidural catheter does not necessarily predict the desired catheter position.

Epidural needles and angiocatheters have been used for entering the caudal space in infants.^{3,4} In our patient, the 18-gauge angiocatheter probably entered the presacral space *via* the lower portion of the sacrum, and the epidural catheter was easily threaded into the presacral space. This complication was not seen when the Crawford needle was used. Confirmation of the position of the catheter before starting an infusion is therefore recommended because the ease in advancement of the catheter may be misleading.

Alfonso Casta, M.D.

Assistant Professor

Department of Anesthesia,

Harvard Medical School and Children's Hospital

Boston, Massachusetts

casta@a1.tch.harvard.edu

References

1. Gunter JB, Eng CE: Thoracic epidural anesthesia via the caudal approach in children. *ANESTHESIOLOGY* 1992; 76:935-8
2. Blanco D, Llamazares J, Rincon R, Ortiz M, Vidal F: Thoracic epidural anesthesia via the lumbar approach in infants and children. *ANESTHESIOLOGY* 1996; 84:1312-6
3. Bösenberg AT, Bland BAR, Schulte-Steinberg O, Downing JW: Thoracic epidural anesthesia via caudal route in infants. *ANESTHESIOLOGY* 1988; 69:265-9
4. Dalens B: Caudal anesthesia, *Regional Anesthesia in Infants, Children, and Adolescents*. Edited by Dalens B. Baltimore, Williams & Wilkins, 1995, pp 171-94

(Accepted for publication June 24, 1999.)