

## CASE REPORTS

Anesthesiology  
2000; 92:603-7  
© 2000 American Society of Anesthesiologists, Inc.  
Lippincott Williams & Wilkins, Inc.

### Erroneous Conclusion from Processed Electroencephalogram with Changing Anesthetic Depth

Eric J. Heyer, M.D., Ph.D.,\* David C. Adams, M.D.,† Catherine Moses, B.A.,‡ Donald O. Quest, M.D.,§  
E. Sander Connolly, M.D.||

INTRAOPERATIVE monitoring of the electroencephalogram (EEG) is commonly used for detection of cerebral ischemia during carotid endarterectomy. Although real-time interpretation of analog EEG recordings may be considered the "gold standard" for ischemia detection, various signal-processing techniques have been used to ease the interpretation of intraoperative EEG. Several reviews of various EEG-processing techniques are now available.<sup>1,2</sup>

Appropriate monitoring of intraoperative EEG for cerebral ischemia assumes that anesthetic depth remains relatively constant, because changes in anesthetic depth or surgical stimulation are known to have profound effects on the EEG.<sup>3</sup> We report the case of a patient having a carotid endarterectomy in which the processed EEG showed a significant loss of "power," and a shift of the spectral edge frequency to lower frequencies during anesthetic emergence. If the EEG had been recorded under conditions of a stable anesthetic when the carotid artery was clamped, the record could have been interpreted as cerebral ischemia.

#### Case Report

A 65-yr-old woman with a history of hypertension and asymptomatic bilateral 90% carotid artery stenosis presented for elective right carotid

endarterectomy. Routine physical examination, laboratory values, electrocardiogram, and chest radiograph were otherwise within normal limits.

In addition to application of routine monitors, a left radial artery catheter was inserted. EEG electrodes were placed in an approximation of the International 10-20 system using an electrode-embedded nylon cap (Electro-cap International Inc., Eaton, OH). An eight-channel EEG (Neurotrac II, Moberg Medical, Ambler, PA) in a monopolar montage (F3, F4, C3, C4, P3, P4, T5 and T6 referred to CZ) was recorded continuously and stored digitally. Low- and high-filter settings were 0.5 and 30 Hz, respectively. A 2 MHz-pulse wave transcranial Doppler (TCD) probe (Multigon Industries Inc., Yonkers, NY) was applied over the right temporal window to insonate the ipsilateral middle cerebral artery.

Following intravenous 100 µg fentanyl and 2 mg midazolam, general anesthesia was induced using 250 mg sodium thiopental, and tracheal intubation was facilitated with succinylcholine. Anesthesia was maintained using N<sub>2</sub>O and isoflurane. Neuromuscular blockade was achieved with 10 mg vecuronium and reversed with 3.5 mg neostigmine and 0.6 mg glycopyrrolate. All hemodynamic and anesthetic data were monitored continuously and recorded every minute by a computer-based data acquisition system (Lifelog from MI<sup>2</sup>, Rosemont, PA).

The patient underwent a routine carotid endarterectomy with general anesthesia. Before and after application of the carotid cross clamps, systolic blood pressure was maintained within the patient's normal range between 120 and 150 mmHg. Phenylephrine was used to increase systolic blood pressure to approximately 180 mmHg during carotid artery cross clamping. Because there were no EEG changes indicative of ischemia with carotid artery clamping, no shunt was inserted (fig. 1, upper; preclamp, clamp). There was a 30% decline in mean TCD velocity with clamping, which returned to normal after removal of the clamps.

During wound closure, the isoflurane was discontinued and the total gas flows were increased from total flows of 3 l/min to a approximately 6 l/min. Shortly after increasing fresh gas flows, a profound shift of the spectral edge to lower frequencies was observed in all electrodes, which is illustrated in figure 1 for frontal and central electrodes on the right hemisphere (fig. 1, upper; postclamp). When the gain for this section of the EEG was doubled, no shift in spectral edge was seen. Concurrent raw EEG recordings were of low amplitude (fig. 1, lower; EEG postclamp). There was no change in the TCD flow velocity, and the patient awoke fully alert, responsive, and without any neurologic deficits approximately 10 min later. A similar sequence of events occurred in this patient 3 months later when she underwent a left carotid endarterectomy.

For illustrative purposes, one author (EJH) underwent an EEG recording using the same eight-channel montage, but without anesthesia. The EEG was recorded at two mental states, with eyes closed (resting) or reading (fig. 2). The EEG demonstrated that the spectral

\* Associate Professor, Departments of Anesthesiology and Neurology.

† Clinical Associate Professor, Mount Sinai School of Medicine, New York, New York.

‡ Research Associate, Department of Anesthesiology.

§ Professor, Department of Neurosurgery.

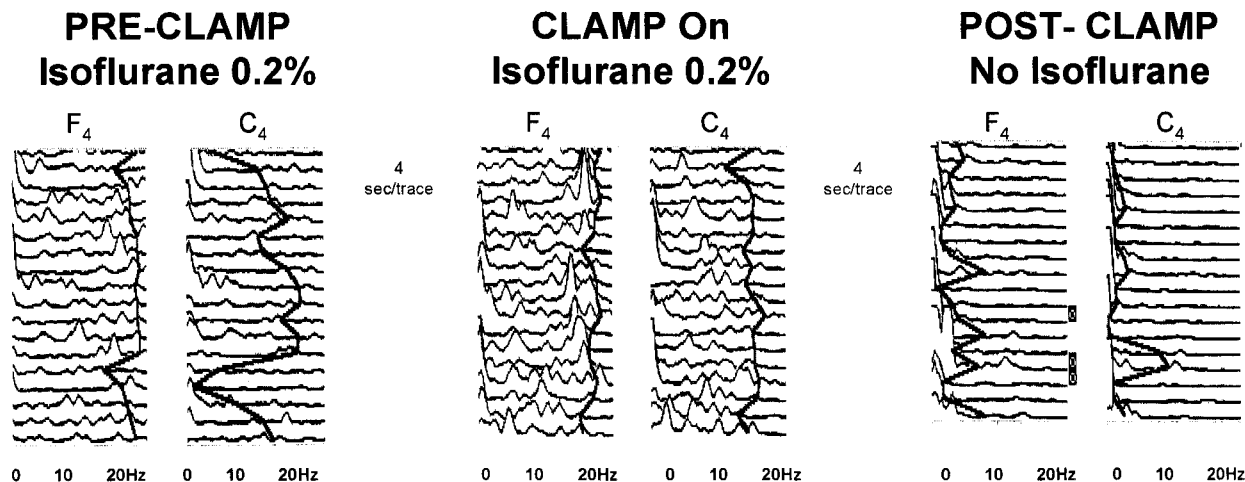
|| Irving Assistant Professor, Department of Neurosurgery.

Received from the Departments of Anesthesiology, Neurology, and Neurosurgery, Columbia University, New York, New York. Received for publication July 14, 1999. Accepted for publication September 17, 1999. Support was provided solely from institutional and departmental resources.

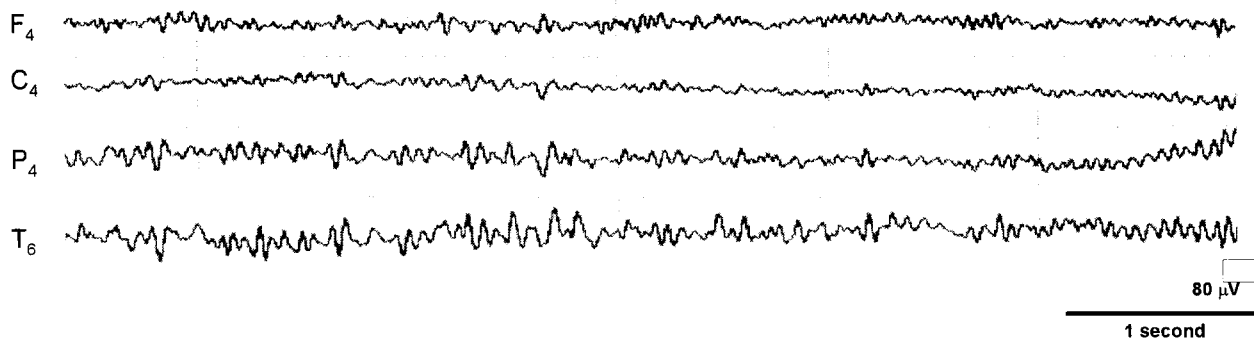
Address correspondence to Dr. Heyer: Department of Anesthesiology, Columbia University, PH 5-535, 630 West 168th Street, New York, NY 10032-3784. Address electronic mail to: ejh3@columbia.edu

Key words: CEA; cerebral ischemia; EEG; neuropsychometric transcranial Doppler ultrasonography; spectral edge.

## Compressed Spectral Array



## EEG Post-Clamp: No Isoflurane



**Fig. 1. (Upper)** Compressed Spectral Array: Preclamp, clamp, and postclamp periods. Processed EEG of frontal and central electrodes from the right side of the head ( $F_4$ ,  $C_4$ ) are shown for three time periods, precross clamp, X-clamp, and postcross clamp. Identical changes were seen for the left side (not shown). The expiratory end-tidal concentration of isoflurane was 0.2%, for the first two time periods and zero for the third. The spectral edge is shown as the continuous vertical trace and represents 97% of total power. The frequencies are plotted on the horizontal axis from 0.5 to 20 Hz and power as  $\mu V^2$  on the vertical axis. Each trace is 4 s in duration. **(Lower)** EEG postclamp: No isoflurane. The lower trace is four channels from the right side of the head of an eight-channel EEG monopolar montage where electrodes  $F_4$ ,  $C_4$ ,  $P_4$ , and  $T_6$  referred to  $C_z$  denote positions using the International 10–20 conventions. The amplification and time scale is 80  $\mu V$  and 1 s per their respective bars. The end-tidal expiratory concentration of isoflurane is zero.

edge frequency decreased significantly with increased concentration and alertness (fig. 3).

### Discussion

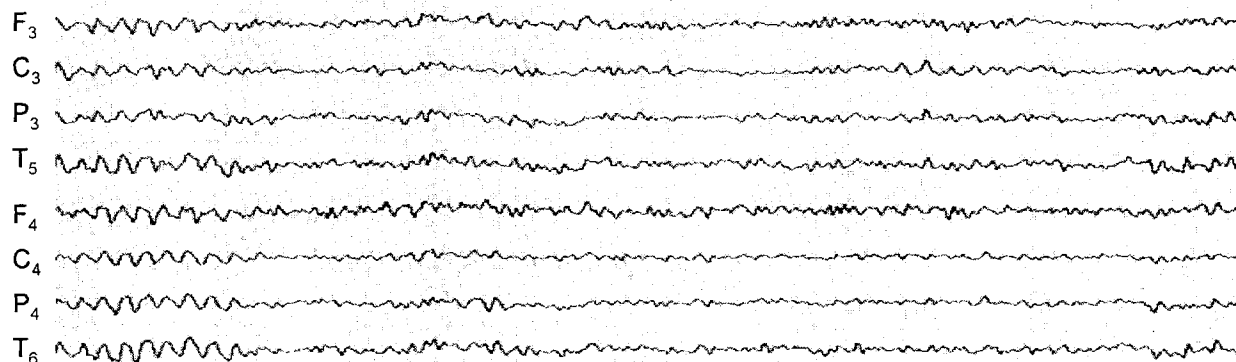
Intraoperative EEG patterns vary as a function of the type of anesthetic medications used, the extent of surgical stimulation, and alterations in the anesthetized state.<sup>4–8</sup> In this regard, the EEG may show dramatic, anesthetic-dependent changes during emergence. Typi-

cally, a shift in the EEG power spectrum results from a decrease in low frequencies ( $\delta$  and  $\theta$ ) and an increase in high frequencies ( $\alpha$  and  $\beta$ ) during emergence from isoflurane,<sup>4,9</sup> whereas similar changes are not seen with a fentanyl-based anesthetic.<sup>4</sup>

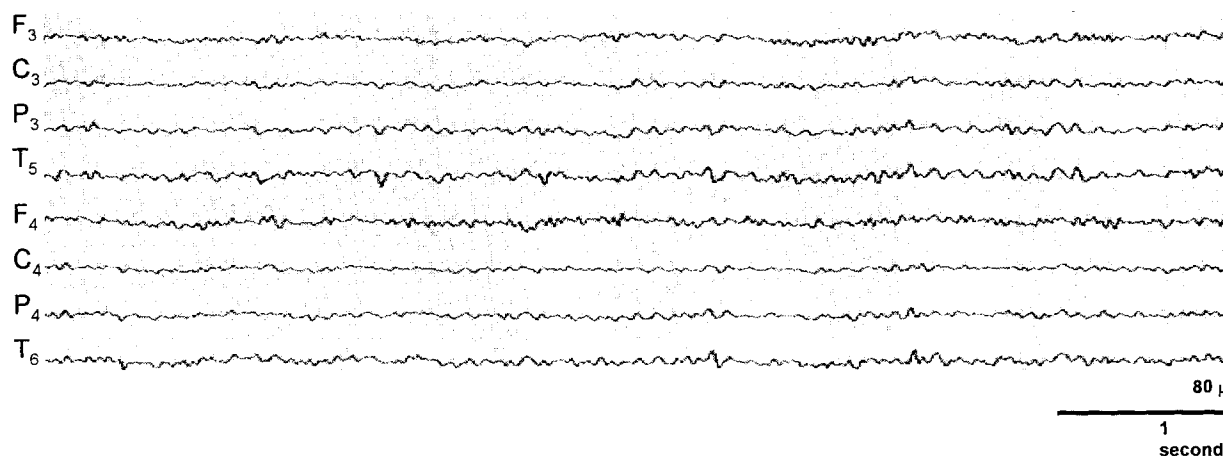
During general inhalational anesthesia, a high amplitude EEG pattern reflecting synchronous electrical activity among different cortical areas driven by central brain nuclei is frequently observed. In contrast, during emergence there is relatively less synchronous cortical elec-

## EEG: At rest and reading

### Eyes closed, resting



### Eyes open, reading



**Fig. 2. EEG: Resting and reading.** These two traces are recorded from a nonanesthetized control in an eight channel EEG monopolar montage where electrodes F<sub>3</sub>, F<sub>4</sub>, C<sub>3</sub>, C<sub>4</sub>, P<sub>3</sub>, P<sub>4</sub>, T<sub>5</sub> and T<sub>6</sub> referred to C<sub>z</sub> denote positions using the International 10–20 conventions. The upper record is with the subject's eyes closed (resting) and the lower while reading. The amplification and time scale is 80  $\mu$ V and 1 s per their respective bars.

trical activity, resulting in a low-voltage, high-frequency EEG. It appears that although the frequency content of this low-voltage EEG can be interpreted by visual inspection, it falls below the amplitude resolution of the processed EEG. Consequently, a leftward shift of the spectral edge frequency is seen. The benign nature of the change is apparent when the gain of the processed EEG is increased. Further support for this argument is a similar change in the EEG of *EJH* from resting to reading seen in the processed and raw EEG (figs. 2 and 3). Processed EEG algorithms have to be interpreted considering the surgical stimulus, the anesthetic, and changes in the anesthetic state. In all cases, the raw EEG must be

available so that artifacts can be easily distinguished from meaningful physiologic changes.

We have reviewed 105 EEG records from patients undergoing similar general anesthetic techniques for carotid endarterectomy. In approximately 55% of these records, the spectral edge frequencies dramatically shifted to lower frequencies during emergence. These shifts were more likely to occur when the end-tidal isoflurane concentrations declined more rapidly. One concern is that these EEG changes may actually reflect cerebral ischemia; however, none of these EEG changes were accompanied by appropriate alterations in the middle cerebral artery flow velocity as measured by TCD.

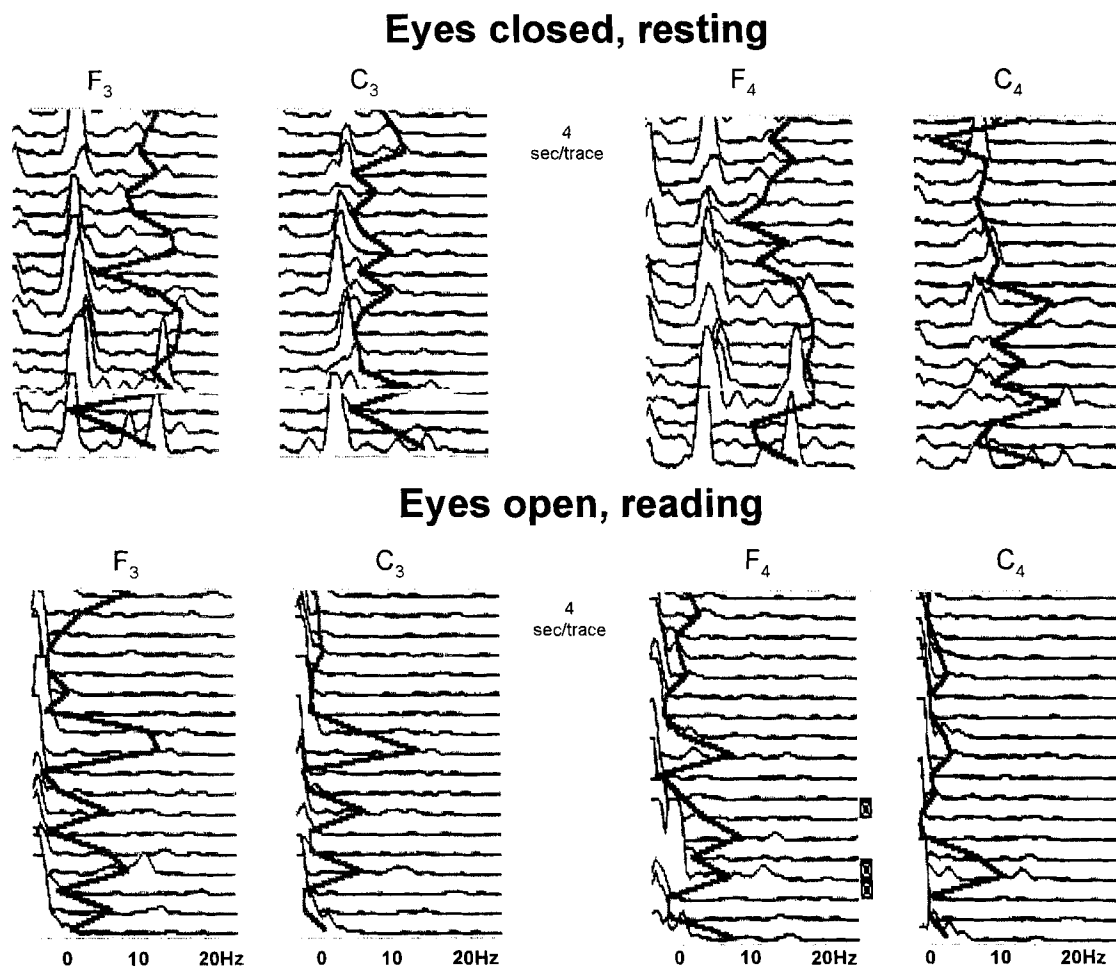


Fig. 3. Compressed spectral array: Resting and reading. Processed EEG of frontal and central electrodes from the left and right sides of the head ( $F_3$ ,  $F_4$ ,  $C_3$ ,  $C_4$ ) are shown for two mental states, eyes closed (resting) and reading. The spectral edge is shown as the continuous vertical trace and represents 97% of total power. The frequencies are plotted on the horizontal axis from 0.5 to 20 Hz and power as  $\mu V^2$  on the vertical axis. Each trace is 4 s in duration.

Furthermore, in an ongoing prospective study evaluating cognitive performance in patients having carotid endarterectomy, we have not seen differences in cognitive performance associated with these EEG changes.

The EEG is generally considered to be a sensitive indicator of intraoperative cerebral ischemia, and is commonly used during carotid endarterectomy. One of the basic assumptions made for its appropriate use is that the anesthetic state remain constant. Electroencephalographic changes are observed during alterations of the anesthetic state, either to greater depth when "paradoxical awakening" has been described<sup>5-8</sup> or to lighter states, as in our case, when changes that might otherwise be associated with cerebral ischemia are occasionally observed. Our conclusions that it is difficult to inter-

pret the EEG under these circumstances and impossible to diagnose cerebral ischemia when processed EEG and spectral edge frequency are the sole measures of cerebral well-being are in agreement with those of Bischoff *et al.*<sup>6</sup> Because the effects of anesthesia and surgical stimulation are the primary modulators of intraoperative EEG, caution should be exercised in making interpretations when either or both of these variables are being altered. Our findings demonstrate that EEG spectral changes produced by an alteration in the anesthetic (*e.g.*, a reduction in the isoflurane concentration to zero) can mimic those that, under steady-state anesthesia, would be interpreted as cerebral ischemia. This phenomenon may be an important confounding variable in processed EEG-based monitors that attempt to provide a measure of