

## CASE REPORTS

in some cases, the mechanism of injury associated with postoperative ulnar neuropathy may not occur intraoperatively. Based on the cases reported in this study and in our previous prospective study of perioperative ulnar neuropathy, we speculate that symptoms of ulnar neuropathy in both medical and surgical inpatients may be related to prolonged periods of bedrest in the supine position.

## References

1. Alvine FG, Schurrer ME: Postoperative ulnar-nerve palsy: Are there predisposing factors? *J Bone Joint Surg Am* 1987; 69:255-9
2. Perreault L, Drolet P, Farnay J: Ulnar nerve palsy at the elbow after general anesthesia. *Can J Anaesth* 1992; 39:499-503
3. Stoelting RK: Postoperative ulnar nerve palsy: Is it a preventable complication? *Anesth Analg* 1993; 76:7-9
4. Kroll DA, Caplan RA, Posner K, Ward RJ, Cheney FW: Nerve injury associated with anesthesia. *ANESTHESIOLOGY* 1990; 73:202-7
5. Warner MA, Warner ME, Martin JT: Ulnar neuropathy: Incidence, outcome, and risk factors in sedated or anesthetized patients. *ANESTHESIOLOGY* 1994; 81:1332-40
6. Cheney FW, Domino KB, Caplan RA, Posner KL: Nerve injury associated with anesthesia. *ANESTHESIOLOGY* 1999; 90:1062-9
7. Britt BA, Gordon RA: Peripheral nerve injuries associated with anaesthesia. *Can Anaesth Soc J* 1964; 11:514-36
8. Dornette WHL: Compression neuropathies: Medical aspects and legal implications. *Int Anesthesiol Clin* 1986; 24:201-9
9. Warner MA, Warner DO, Matsumoto JY, Harper CM, Schroeder DR, Maxson PM: Ulnar neuropathy in surgical patients. *ANESTHESIOLOGY* 1999; 90:54-9
10. Contreras MG, Warner MA, Charboneau WJ, Cahill DR: The anatomy of the ulnar nerve at the elbow: Potential relationship of acute ulnar neuropathy to gender differences. *Clin Anat* 1998; 11:372-8
11. Shimokata H, Tobin JD, Muller DC, Elahi D, Coon PJ, Andres R: Studies in the distribution of body fat: I. Effects of age, sex, and obesity. *J Gerontol* 1989; 44:66-73
12. DeKoninck J, Lorrain D, Gagnon P: Sleep positions and position shifts in five age groups: an ontogenetic picture. *Sleep* 1992; 15:143-9
13. Campbell WW, Pridgeon RM, Riaz G, Astruc J, Sahni KS: Variations in anatomy of the ulnar nerve at the cubital tunnel: Pitfalls in the diagnosis of ulnar neuropathy at the elbow. *Muscle Nerve* 1991; 14:733-8
14. O'Driscoll SW, Horii E, Carmichael SW, Morrey BF: The cubital tunnel and ulnar neuropathy. *J Bone Joint Surg* 1991; 73:613-7

Anesthesiology  
2000; 92:615-9  
© 2000 American Society of Anesthesiologists, Inc.  
Lippincott Williams & Wilkins, Inc.

## Reversible Catecholamine-induced Cardiomyopathy by Subcutaneous Injections of Epinephrine Solution in an Anesthetized Patient

Yoshiharu Sato, M.D.,\* Makoto Tanaka, M.D.,† Toshiaki Nishikawa, M.D.‡

CATECHOLAMINE-INDUCED cardiomyopathy has been recognized for several decades.<sup>1</sup> It is associated with certain pathologic conditions, such as pheochromocytoma

and subarachnoid hemorrhage, in which excessively high concentrations of endogenous catecholamines are regarded as the cause.<sup>2-5</sup> Large doses of exogenously administered norepinephrine in humans and animals also produce characteristic myocardial lesions that include focal myofiber necrosis and degeneration and mononuclear leukocytic infiltration.<sup>1,6-8</sup> Although previous case reports are confined to these pathologic conditions or catecholamine overdoses, cardiomyopathy that developed acutely after a clinically relevant dose of exogenously administered epinephrine has never been reported in humans.

Clinical pictures of catecholamine cardiomyopathy are divergent and may present dissociation between diffuse impairment of myocardial contractile function *versus* little or no evidence of myocardial damage detected by

\* Resident.

† Associate Professor.

‡ Professor and Chair.

Received from the Department of Anesthesia, Akita University School of Medicine, Akita, Japan. Submitted for publication May 17, 1999. Accepted for publication September 24, 1999. Support was provided solely from institutional and/or departmental sources.

Address reprint requests to Dr. Tanaka: Department of Anesthesia, Akita University School of Medicine, Hondo 1-1-1, Akita-shi, Akita-ken 010-8543, Japan. Address electronic mail to: mtanaka@med.akita-u.ac.jp

Key words: Complication; myocardial injury; myosin light chain isotype 1; troponin T.

## CASE REPORTS

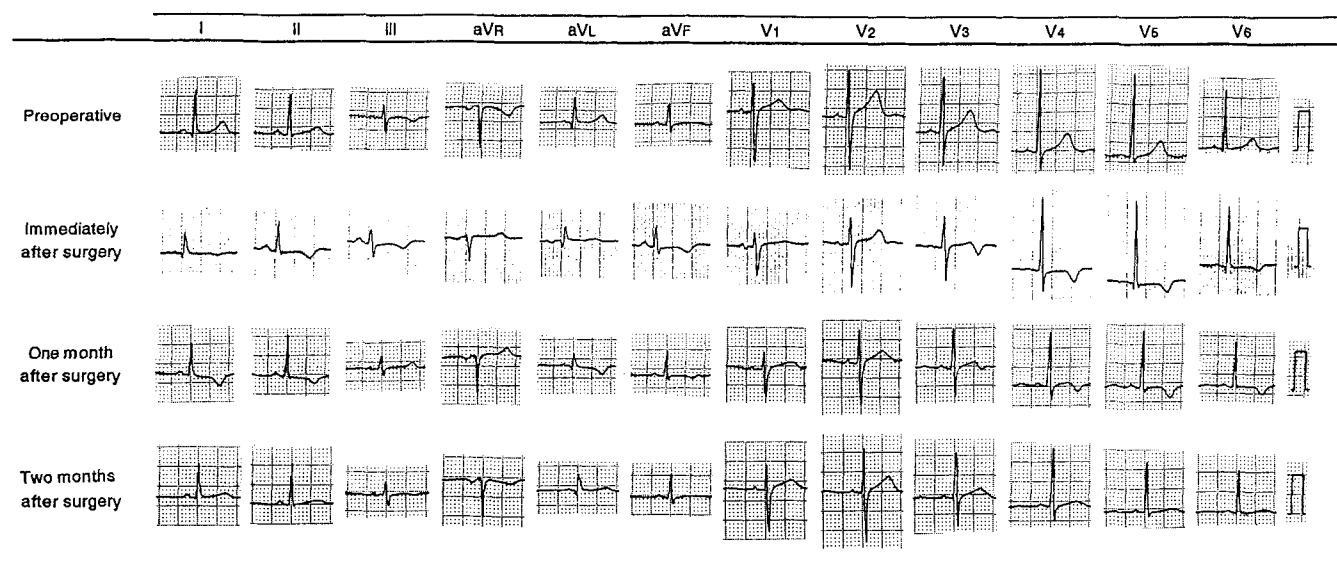


Fig. 1. Changes of 12-lead electrocardiography preoperatively and immediately (30 min) 1 and 2 months after surgery in a 39-yr-old healthy patient in whom catecholamine-induced cardiomyopathy developed after subcutaneous injections of 100  $\mu$ g epinephrine.

cardiospecific laboratory tests, including creatine phosphokinase-MB isozymes.<sup>4,9</sup> However, plasma concentrations of more sensitive and specific markers for myocardial injury, such as cardiac troponin T and myosin light chain isotype 1,<sup>10,11</sup> have never been determined in patients with catecholamine cardiomyopathy. In this report, we describe a case of near-complete recovery from profound generalized hypokinesia, which was diagnosed as catecholamine cardiomyopathy after a small subcutaneous dose of saline with epinephrine solution, in an otherwise healthy patient during general anesthesia and report changes of electrocardiography (EKG), echocardiography, and cardiospecific biochemical markers during the course of recovery.

### Case Report

A 39-yr-old woman (American Society of Anesthesiologists physical status I; weight, 52 kg; height 156 cm) presented for resection of dermatofibrosarcoma protuberans on the right upper breast. Her medical history was unremarkable, and activities of daily life were not restricted. Her preoperative laboratory tests results were all within normal ranges, and EKG showed regular sinus rhythm with neither clinically significant ST-segment deviation nor paroxysmal ventricular contractions (fig. 1). Her preoperative blood pressure and heart rate (HR) were 108/64 mmHg and 68 beats/min, respectively. Screening for a metastatic lesion, which included the adrenal glands, was also negative.

After premedication with 5 mg oral diazepam and 20 mg famotidine,

general anesthesia was induced with 250 mg intravenous thiopental, and her trachea was intubated after administration of 10 mg intravenous vecuronium. Then, her lungs were mechanically ventilated with 2% (inspiratory) sevoflurane and 67% nitrous oxide in oxygen (fresh gas flow of 6 l/min throughout the surgery), while end-tidal carbon dioxide was maintained between 29 and 35 mmHg. Before skin incision, to minimize surgical bleeding, 30 ml saline with 1:330,000 epinephrine solution was injected into the subcutaneous tissue in divided doses, each of which was preceded by a negative aspiration test. At completion of injections, HR increased from 70 to 90 beats/min, and multifocal paroxysmal ventricular contractions were seen on the monitor during EKG (lead II). Normal sinus rhythm was rapidly restored by an administration of 40 mg intravenous lidocaine. However, blood pressure (BP) and HR continued to increase, and were 156/114 mmHg and 112 beats/min, respectively, when ST-segment elevation was noted on the monitor during EKG 10 min after injection of the epinephrine solution. Nitroglycerin was given intravenously in divided doses up to 1,500  $\mu$ g until the ST segment and BP returned to the baseline levels within another 10 min. After resolution of the EKG and hemodynamic variables, arterial blood gas and electrolytes analysis revealed the following: partial pressure of arterial oxygen ( $P_{aO_2}$ ): 105.8 mmHg (inspired oxygen fraction [ $F_{I_{O_2}}$ ] = 0.33); partial pressure of arterial carbon dioxide ( $P_{aCO_2}$ ): 33.9 mmHg; pH: 7.383; base-excess: -4.2 mEq/l; sodium: 143.2 mEq/l; potassium: 3.32 mEq/l; and ionized calcium: 1.05 mEq/l. Because BP and HR remained stable (136/90 mmHg and 92 beats/min, respectively), surgery was resumed, and the remaining anesthetic course was uneventful using inspiratory 1.5% sevoflurane, nitrous oxide, and intermittent intravenous fentanyl up to 300  $\mu$ g. However, a negative T wave developed gradually and was seen on the EKG monitor during the course of surgery, which lasted 4 h. When surgery was completed, all anesthetics were discontinued, and the patient's trachea was extubated in the operating room without any

## CASE REPORTS

Table 1. Pre- and Postoperative Laboratory and Echocardiographic Data

	Preoperative	Immediately after surgery	POD 1	POD 2	POD 3	POD 4	POD 5	POD 6	POD 8
WBC ( $\mu$ l)	4,200		11,000	8,300	6,800	6,500	5,100	5,200	4,700
AST (U/l)	21		35	28	31	34	46	57	43
LDH (U/l)	159		157	170	176	137	152	160	169
CPK (U/l)	65		195	137	83	73	87	85	56
CPK-MB (U/l)			11			6	11	10	7
Cardiac-specific troponin T (ng/ml)		0.87	0.24	<0.05	<0.05	<0.05	<0.05	<0.05	
Myosin light chain isotype 1 (ng/ml)		<1.0	<1.0	2.4	2.4	2.6	1.7	1.7	
Ejection fraction (%)		20	35	40				50	62

Cardiac-specific troponin T was measured by enzyme immunoassay (normal range < 0.25 ng/ml). Myosin light chain isotype 1 was measured by radio immunoassay (normal range <2.5 ng/ml). WBC = white blood cell count; AST = aspartate aminotransferase; LDH = lactic dehydrogenase; POD = postoperative day; CPK = creatine phosphokinase.

difficulty. Estimated blood loss was 80 ml, and 2,500 ml lactated Ringer's solution was infused.

In the postanesthesia recovery area, BP and HR were stable and were 95/60 mmHg and 95 beats/min, respectively. However, 30 min after the completion of surgery, 12-lead EKG revealed negative T waves in leads I, II, III, aVF, and V<sub>3</sub>-V<sub>6</sub>, which were not evident preoperatively (fig. 1). Echocardiography performed immediately after EKG showed profound global hypokinesis of both ventricles with an ejection fraction (EF) of 20% (table 1). The patient was immediately transferred to the intensive care unit, where a central venous catheter was placed, and 5  $\mu$ g  $\cdot$  kg<sup>-1</sup>  $\cdot$  min<sup>-1</sup> intravenous dobutamine and 0.5  $\mu$ g  $\cdot$  kg<sup>-1</sup>  $\cdot$  min<sup>-1</sup> nitroglycerin were started. As a result, systolic BP and HR were maintained between 130 and 140 mmHg and between 90 and 100 beats/min, respectively. Central venous pressure was less than 10 mmHg. Heart sounds were unremarkable, and no crepitations were heard during auscultation. The chest radiograph showed neither enlargement of the cardiac shadow nor pulmonary congestion. On postoperative day 1, the patient was able to sit up without orthostatic hypotension, and echocardiography showed that EF returned to 35%. There was no development of metabolic acidosis. Therefore, dobutamine and nitroglycerin were gradually weaned and discontinued, and the patient was transferred from the intensive care unit to the ward.

From postoperative days 2 to 8, the EF continued to improve (table 1). Although echocardiography showed apical and anteroseptal severe hypokinesis with a left ventricular EF of 40% on postoperative day 2, the movements of these severely hypokinetic regions were normalized during the next week, with a resultant EF of 62% on postoperative day 8. At that time, the patient was able to walk without shortness of breath. The percentage of creatine phosphokinase-MB isozyme was 5.6% of the total creatine phosphokinase on postoperative day 1, cardiac troponin T remained within a normal range, and myosin light chain isotype 1 showed only a slight increase on postoperative day 4 (table 1).

Inverted T waves were present in leads I, II, aVL, aVF, and V<sub>4</sub>-V<sub>6</sub> 1 month after the episode. The follow-up EKG showed partial recovery but showed nonspecific flattening of T waves in those leads 2 months later, when the patient was able to lead a daily life without limitation (fig. 1).

## Discussion

Cardiotoxic effects of excessive catecholamines, known as catecholamine-induced cardiomyopathy, have

been documented for several decades both in animal models and human hearts.<sup>1</sup> In rats, continuous infusions of norepinephrine can produce myocardial injury characterized by myofiber necrosis, myofibrillar degeneration, and mononuclear leukocytic infiltration seen focally but predominantly in the subendocardial areas.<sup>7,8</sup> In humans, similar myocardial lesions may be seen at necropsy of patients exposed long-term to endogenous catecholamines, such as pheochromocytoma,<sup>2,3</sup> or short-term to exogenous norepinephrine administered as a therapeutic intervention.<sup>1</sup> Impairment of myocardial contraction may be global or focal.<sup>3,4</sup> Another manifestation of catecholamine cardiomyopathy includes little or no laboratory evidence of myocardial injury for the extent and severity of reduced myocardial function observed by an imaging study.<sup>4,9</sup> Impaired cardiac performance may be reversible or irreversible.<sup>2,5,12-14</sup> Although the exact mechanism has not been elucidated fully, the generation of oxygen-derived free radicals may be the primary mechanism leading to membrane damage and myocyte death.<sup>8</sup>

To the best of our knowledge, this is the first reported case of catecholamine cardiomyopathy induced by a clinically acceptable dose of exogenous epinephrine in a patient with no evidence of coronary artery disease or peripheral vascular abnormalities. The only other available case of epinephrine-induced cardiomyopathy in the literature was caused by an accidental epinephrine overdose.<sup>14</sup> In that case, the patient received a total dose of 7 mg injected into the cervix for cone biopsy. Ventricular premature complexes rapidly developed, followed by bigeminy, pulmonary edema necessitating tracheal intubation, and global left ventricular dysfunction (EF < 20%) and hypotension that required inotropic support and use of an intraaortic balloon pump. Creatine phosphokinase increased to 615 U/l at 24 h with a positive

MB band, but no other biochemical markers were reported. The cardiac function was normalized gradually to an EF of 60% during the course of 8 days, and the patient was asymptomatic 1 yr later. The clinical picture of our case is similar, in that ventricular dysrhythmia developed rapidly after epinephrine injections, followed by profound depression of myocardial function, which showed near-complete recovery 8 days later. However, no signs of pulmonary edema developed in our patient and she showed preserved responsiveness to dobutamine.<sup>6,15</sup> Furthermore, cardiac troponin T and myosin light chain isotype 1, highly effective biochemical markers for various myocardial injuries elevated for a prolonged period of time,<sup>16,17</sup> were only marginally increased at sporadic occasions, as compared with the degree of increases associated with acute myocardial infarction.<sup>16,18-20</sup> These observations suggest that the severity of myocardial injury in our patient was less than in the previous report, at least in part, because of a far smaller epinephrine dose injected in our patient (100  $\mu$ g).

It was not clear why the clinical dose of epinephrine led to cardiomyopathy in our patient, who was diagnosed as clinically healthy in the preoperative period. Several evidence suggests an altered  $\beta$ -adrenergic regulatory system and enhanced cardiovascular responsiveness to exogenous catecholamine in patients with idiopathic cardiomyopathy.<sup>21,22</sup> Myocardial disorders, such as viral myocarditis, may have a delayed onset and insidious progress and may not always be detected by subjective symptoms or standard tests, including EKG.<sup>23,24</sup> Although no previous literature showed unusual cardiovascular responses to exogenous epinephrine in viral myocarditis, we cannot exclude a possibility that our patient had subtle myocardial abnormalities that we could not recognize, which led to extraordinary response to the reasonable dose of epinephrine. Indeed, this may be supported by the fact that multifocal paroxysmal ventricular contractions developed in our patient only after 1.9  $\mu$ g/kg epinephrine was injected subcutaneously, whereas previous studies showed that no premature ventricular contractions developed after submucosal injections of epinephrine less than 5  $\mu$ g/kg in sevoflurane- isoflurane- or desflurane-anesthetized patients.<sup>25,26</sup>

Subcutaneous injection of saline plus epinephrine solution is a frequently used technique to reduce blood loss from the surgical site. Although ventricular arrhythmia may be occasionally noted as a result of inadvertent intravascular injection or rapid absorption of small dose

of epinephrine from subcutaneous or submucosal tissue,<sup>25,26</sup> anesthesiologists should always be aware of the development of catecholamine cardiomyopathy as a rare but potentially lethal complication of subcutaneously injected epinephrine.

## References

1. Szakacs JE, Cannon A: I-Norepinephrine myocarditis. *Am J Clin Pathol* 1958; 30:425-34
2. Sardesai SH, Mourant AJ, Sivathandon Y, Farrow R, Gibbons DO: Pheochromocytoma and catecholamine induced cardiomyopathy presenting as heart failure. *Br Heart J* 1990; 63:234-7
3. Frustaci A, Loperfido F, Gentiloni N, Caldarulo M, Morgante E, Russo MA: Catecholamine-induced cardiomyopathy in multiple endocrine neoplasia: A histologic, ultrastructural, and biochemical study. *Chest* 1991; 99:382-5
4. Tanaka M, Dohi S: Anesthetic management of a patient with severe subarachnoid hemorrhage and diffuse lung edema. *Masui* 1989; 38:1083-91
5. Fahmy N, Assaad M, Bathija P, Whittier FC: Postoperative acute pulmonary edema: A rare presentation of pheochromocytoma. *Clin Nephrol* 1997; 48:122-4
6. Fripp RR, Lee JC, Downing SE: Inotropic responsiveness of the heart in catecholamine cardiomyopathy. *Am Heart J* 1981; 101:17-21
7. Simons MS, Dowling SE: Coronary vasoconstriction and catecholamine cardiomyopathy. *Am Heart J* 1985; 109:297-304
8. Jiang JP, Dowling SE: Catecholamine cardiomyopathy: Review and analysis of pathogenic mechanisms. *Yale J Biol Med* 1990; 63:581-91
9. Hannerneister KE, Reichenbach DD: QRS changes, pulmonary edema, and myocardial necrosis associated with subarachnoid hemorrhage. *Am Heart J* 1969; 78:94-100
10. Mair J: Cardiac troponin I and troponin T: Are enzymes still relevant as cardiac markers? *Clin Chim Acta* 1997; 257:99-115
11. Ravkilde J, Botker HE, Sogaard P, Selmer J, Rej R, Jorgensen PJ, Horder M, Thygesen K: Human ventricular myosin light chain isotype 1 as a marker of myocardial injury. *Cardiology* 1994; 84:135-44
12. Salathe M, Weiss P, Ritz R: Rapid reversal of heart failure in a patient with pheochromocytoma and catecholamine-induced cardiomyopathy who was treated with captopril. *Br Heart J* 1992; 68:527-8
13. Wood R, Commerford PJ, Rose AG, Tooke A: Reversible catecholamine-induced cardiomyopathy. *Am Heart J* 1991; 121:610-3
14. Fyfe AI, Daly PA, Dorian P, Tough J: Reversible "Cardiomyopathy" after accidental adrenaline overdose. *Am J Cardiol* 1991; 67:318-9
15. Corder SW, Heyliger CE, Beamish RE, Dhalla NS: Defect in the adrenaline receptor-adenylate cyclase system during development of catecholamine-induced cardiomyopathy. *Am Heart J* 1984; 107:537-42
16. Katus HA, Remppis A, Looser S, Hallermeier K, Scheffold T, Kubler W: Enzyme linked immuno assay of cardiac troponin T for the detection of acute myocardial infarction in patients. *J Mol Cell Cardiol* 1989; 21:1349-53
17. Wang J, Shi Q, Wu TW, Jackowski G, Mickle DAG: The quantitation of human ventricular myosin light chain I in serum after myocardial necrosis and infarction. *Clin Chim Acta* 1989; 181:325-36
18. Uji Y, Sugiuchi H, Okabe H: Measurement of human ventricular myosin light chain-1 by monoclonal solid-phase enzyme immunoassay

## CASE REPORTS

in patients with acute myocardial infarction. *J Clin Lab Anal* 1991; 5:242-6

19. Kragten JA, Hermens WT, Dicijen-Visser MP: Cardiac troponin T release into plasma after acute myocardial infarction: Only fractional recovery compared with enzymes. *Ann Clin Biochem* 1996; 33:314-23

20. Yazaki Y, Nagai R, Yamaoki K, Ueda S: Myocardial infarct size from serum cardiac myosin light chain: Clinical and experimental studies. *Adv Myocardiol* 1983; 4:489-95

21. Mäki T, Leinonen H, Näveri H, Sovijärvi A, Kontula K, Härkönen M: Response of the beta-adrenergic system to maximal dynamic exercise in congestive heart failure secondary to idiopathic dilated cardiomyopathy. *Am J Cardiol* 1989; 63:1348-53

22. Koga Y, Miyazaki Y, Shida M, Chiba M, Toshima H: Increased

cardiovascular responses to norepinephrine in patients with hypertrophic cardiomyopathy. *Jpn Heart J* 1990; 31:271-85

23. Woodruff JF: Viral myocarditis: A review. *Am J Pathol* 1980; 101:427-84

24. Abelmann WH: Viral myocarditis and its sequelae. *Annu Rev Med* 1973; 24:145-52

25. Navarro R, Weiskopf RB, Moore MA, Lockhart S, Eger EI II, Koblin D, Lu G, Wilson C: Humans anesthetized with sevoflurane or isoflurane have similar arrhythmic response to epinephrine. *ANESTHESIOLOGY* 1994; 80:545-9

26. Moore MA, Weiskopf RB, Eger EI II, Wilson C, Lu G: Arrhythmogenic doses of epinephrine are similar during desflurane or isoflurane anesthesia in humans. *ANESTHESIOLOGY* 1993; 79:943-7