

immobilized for more than 72 h without any DVT prophylaxis.<sup>6</sup> Conspicuous by its absence is any report of such devices precipitating an embolic event during general surgery.

We cannot establish causality. It is possible that the embolism would have occurred irrespective of the placement of the sequential devices because of the presence of multiple risk factors in our patient, including age, obesity, malignancy, estrogen replacement hormones, and relative immobility (because of illness). Nevertheless, the temporal association between activation of the pneumatic device and sudden onset of symptoms at least suggests that the application of preventive measure may have paradoxically triggered a life-threatening complication.

Such an anecdotal report should not be held up as the sole basis for changing clinical practice, particularly when benefits of these compression devices outweigh the risk of complication. However, we suggest that these well-intentioned prophylactic measures may have adverse consequences, particularly if they are not used appropriately. Clinicians who care for patients with

moderate to high risk for DVT who are fitted with these devices should remain alert for signs and symptoms of acute embolism, especially during the first few minutes and hours after their application.

## References

1. Goldhaber, Samuel Z: Medical progress: Pulmonary embolism. *N Engl J Med* 1998; 339:93-104
2. Clagett PG, Anderson FA Jr, Geerts W, Heit JA, Knudson M, Lieberman JR, Merli GJ, Wheeler HB: Prevention of venous thromboembolism. *Chest* 1998; 114(Suppl 5):531S-60S
3. McGrath BJ, Hsia J, Boyd A, Shay P, Graeter J, Conry K, Campbell D, Naulty JS: Venous embolization after deflation of lower extremity tourniquets. *Anesth Analg* 1994; 78:349-53
4. Civetta JM, Taylor RW, Kirby RR: *Critical Care*, 3rd Edition. Philadelphia, Lippincott-Raven, 1997
5. Nicolaides AN, Bergqvist D, Hull R, et al.: Prevention of venous thromboembolism: International consensus statement (guidelines according to scientific evidence). Nicosia, Cyprus: Med-Orion Publishing Company, 1997
6. Kendal SCD: *Sequel Compression System Procedure Guide*, Model # 6325. Manfield, MA, The Kendall Company

Anesthesiology  
2000; 92:882-5  
© 2000 American Society of Anesthesiologists, Inc.  
Lippincott Williams & Wilkins, Inc.

## Reversal of Intraoperative Myocardial Ischemia with a Hemoglobin-based Oxygen Carrier

Marc Niquille, M.D.,\* Marc Touzet, M.D.,† Isabelle Leblanc, M.D.,‡ Jean-François Baron, M.D.§

THE hemoglobin-based oxygen-carrying solutions currently under investigation have oxygen transport and exchange properties similar to blood. However, their

cardiovascular effects are still a subject of controversy. In particular, there have been several reports of extensive vasoconstriction,<sup>1-4</sup> and several authors have suggested that this effect may be deleterious for the myocardium in patients with coronary artery disease.<sup>5,6</sup>

\* Research Fellow.

† Staff Anesthesiologist.

‡ Resident.

§ Professor.

Received from the Department of Anesthesiology, Broussais Hospital, Paris, France. Submitted for publication June 18, 1999. Accepted for publication November 3, 1999. Supported by Biopure Corporation, Cambridge, Massachusetts.

Address reprint requests to Dr. Baron: Department of Anesthesiology, Broussais Hospital, 96 rue Didot, 75014 Paris, France. Address electronic mail to: jfbaron.broussais@in vivo.edu

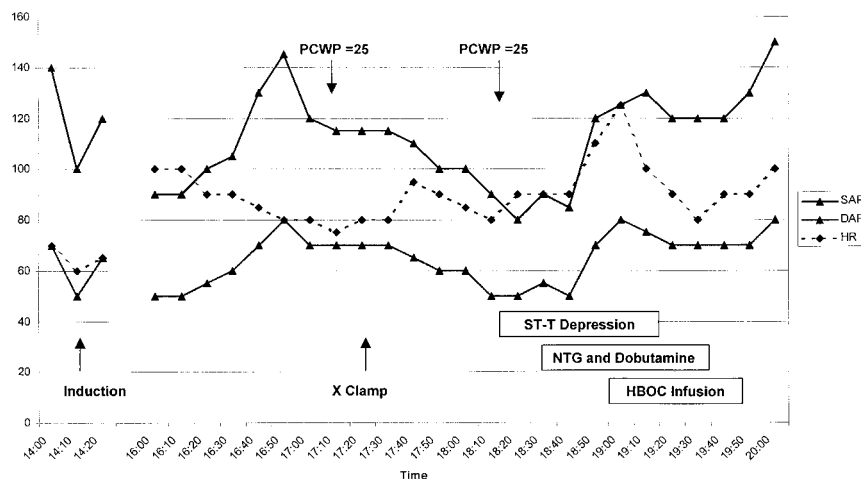
Key words: Cardiovascular effects; coronary artery disease; tissue oxygenation.

## Case Report

A 64 yr-old man with abdominal aortic occlusive disease was admitted for an occlusion of the right lower limb of an aortobifemoral graft. The patient had previously undergone several radiologic and surgical lower-limb revascularization procedures. The patient reported an uncomplicated myocardial infarction after a previous aortobifemoral grafting procedure. However, there was no subsequent angina or cardiac insufficiency. On admission, his electrocardiogram showed a atrial fibrillation longstanding with a ventricular rate of 90 beats/min. Intravenous heparin was started but was complicated by a significant lower gastrointestinal hemorrhage leading to a decrease in hemoglobin

## CASE REPORTS

**Fig. 1.** Partial reproduction of the anesthetic chart. Induction = induction of anesthesia; SAP = systolic arterial pressure; DAP = diastolic arterial pressure; PCWP = pulmonary capillary wedge pressure; X clamp = aortic cross-clamping.



concentration from 15.5 to 11.7 g/dl. Endoscopic exploration of the gastrointestinal tract failed to reveal a precise cause, but bleeding ceased. The patient was scheduled for a revision aortobifemoral graft.

Before surgery, the patient was enrolled in a randomized, single-blind, erythrocyte-controlled trial to evaluate the efficacy and the safety of an hemoglobin-based oxygen carrier (HBOC-201). The patient was informed of all risks and potential benefits, and written informed consent was obtained. The patient was not enrolled in a predonation program and was not treated with erythropoietin.

Anesthesia was induced using titrated doses of fentanyl, propofol, and atracurium. A pulmonary artery catheter was inserted, revealing high pulmonary capillary wedge pressure (25 mmHg). Anesthesia was maintained using a continuous infusion of propofol and intermittent fentanyl. Surgery was uneventful until aortic cross-clamping. During cross-clamping, the patient developed progressive systolic and diastolic hypotension to 80/50 mmHg (fig. 1) associated with new 2-mm ST-T segment depression on monitored standard leads II and V5. Pulmonary capillary wedge pressure remained at 25 mmHg. A dobutamine ( $6 \mu\text{g} \cdot \text{kg}^{-1} \cdot \text{min}^{-1}$ ) and nitroglycerin ( $0.5 \mu\text{g} \cdot \text{kg}^{-1} \cdot \text{min}^{-1}$ ) infusion was started. Blood pressure and heart rate increased (fig. 1) but with no improvement in ST-segment depression. Hemoglobin concentration at this point was 7.6 g/dl, and the decision to transfuse blood was made. In accordance with the trial protocol, the patient was randomly assigned to receive 60 g (500 ml) of HBOC-201. After the start of the infusion, systemic arterial blood pressure slightly increased and heart rate decreased with rapid normalization of the ST-T segment (fig. 1). Dobutamine and nitroglycerin infusions were stopped, and surgery was completed. During the postoperative period, recurrent tachycardia and ST-T changes were successfully treated by a second infusion of 30 g HBOC-201. On postoperative day 1, total hemoglobin was 11.3 g/dl with a plasma-free hemoglobin level of 2.2 g/dl. Troponin Ic levels remained normal, and the patient was discharged to the ward. On postoperative day 6, a new episode of gastrointestinal hemorrhage was observed. Total hemoglobin decreased from 9.0 to 7.4 g/dl, and 60 g HBOC-201 was infused without adverse events. Reexploration of the gastrointestinal tract revealed four small benign rectal polyps that were removed.

On postoperative day 2, moderate jaundice with a transient increase in AST (493 UI/l; normal values = 15–48 UI/l), ALT (121 UI/l; normal values = 10–40 UI/l), and lipase (120 UI/l; normal values = 7–60 UI/l)

was noted. These returned to baseline within 3 days, without clinical or ultrasound evidence of hepatic or pancreatic lesion. The patient was discharged home on postoperative day 28 with a hematocrit of 37% and total hemoglobin of 11.6 g/dl without receiving allogenic packed erythrocytes or erythropoietin therapy.

## Discussion

Hemoglobin-based oxygen carrier 201 is an intravenous solution of glutaraldehyde-polymerized bovine hemoglobin. Cardiovascular effects of HBOC-201 are still a subject of controversy because it has been demonstrated that iso-volumic exchange during acute normovolemic hemodilution may result in decreased cardiac output associated with peripheral vasoconstriction.<sup>3,4</sup> Several investigators have stressed that this effect may be deleterious, especially in patients with coronary artery disease.<sup>5,6</sup>

This high-risk patient with cardiac and vascular disease experienced intraoperative myocardial ischemia likely related to anemia, hypotension, and tachycardia. The infusion of HBOC-201 led to a rapid hemodynamic improvement with normalization of ST-T segment abnormalities. This beneficial effect may have been related either to the cardiovascular effects of HBOC-201 or to its ability to improve tissue oxygenation.

Hemoglobin-induced vasoconstriction may result in reduced blood flow to vital organs and severe pulmonary hypertension.<sup>7</sup> It has been suggested that this vasoconstrictive effect may be mediated in part by endothelin, inhibition of nitric oxide, and sensitization of peripheral  $\alpha$  receptors.<sup>8</sup> The magnitude of this vasoconstrictive effect seems to be attenuated by polymerization of hemoglobin either by glutaraldehyde<sup>9</sup> as HBOC-201 or *o*-raffinose.<sup>10</sup> The effect of polymerization is likely caused by surface modification

and/or intramolecular cross-linking, rather than an increase in molecular size limiting extravasation.<sup>9</sup> The consequences of the vasoconstrictive effect of HBOC on coronary circulation is also unclear. Early studies performed with incompletely purified hemoglobin solutions described coronary vasoconstriction.<sup>11-13</sup> More recent studies<sup>14,15</sup> have used modified, highly purified, and heat pasteurized hemoglobin-based solutions (diaspirin cross-linked). Infusion of diaspirin cross-linked hemoglobin increases blood pressure as well as blood flow to the myocardium and gastrointestinal tract. An endothelin receptor antagonist (phosphoramidon) could attenuate the systemic hemodynamic effects and some regional circulatory effects of diaspirin cross-linked hemoglobin. However, the increase in blood flow to the myocardium could not be modified by an endothelin receptor antagonist. Accordingly, in our case report, it may be suggested that cardiovascular effects of HBOC-201 may have contributed to the improvement in the hemodynamic status of the patient by increasing arterial pressure, coronary perfusion pressure, and decreasing heart rate. However, we cannot rule out the possibility that the same effects could have been accomplished with another colloid.

In addition, when compared with blood, HBOCs could improve tissue oxygenation more significantly. Standl *et al.*<sup>16</sup> compared the effects of stored erythrocytes, freshly donated blood, and HBOC-201 on muscular tissue oxygenation after extreme isovolemic hemodilution in a canine model. At a hematocrit of 10%, skeletal muscle tissue oxygen tension was decreased by approximately 50%. After transfusion, an increase of 0.7 g/dl of hemoglobin using HBOC-201 resulted in restoration of baseline tissue oxygenation. An increase in hemoglobin of 2.7 and 2.1 g/dl with fresh and stored blood, respectively, were needed to restore normal tissue oxygenation. These results demonstrate a higher oxygenation potential of HBOC as compared with fresh or stored erythrocytes in relation with better oxygen extraction.<sup>16</sup> The right shift of the oxygen-hemoglobin dissociation curve ( $P_{50}$  32-35 mmHg) and a better distribution of blood oxygen-carrying capacity at the microcirculatory level are the main mechanisms explaining the improvement of tissue oxygenation.<sup>17,18</sup> Whether this played a role in the event observed in our patient is unknown.

In this patient, infusion of HBOC-201 was followed by a mild increase of AST, ALT, and lipase levels. However, there were not clinically significant and returned to baseline values rapidly. Such alterations have been reported in patients exposed to HBOC-201 in previous phase I and II studies, but its clinical relevance remains

unknown. The increase in AST was greater than that of ALT and could also be related, in part, to the surgical procedure. The jaundice is explained by the interstitial diffusion and catabolism of the free hemoglobin.

## References

1. Caron A, Menu P, Faivre-Fiorina B, Labrude P, Alayash AI, Vigneron C: Cardiovascular and hemorheological effects of three modified human hemoglobin solutions in hemodiluted rabbits. *J Appl Physiol* 1999; 86:541-8
2. Dietz NM, Martin CM, Beltran-del-Rio AG, Joyner MJ: The effects of cross-linked hemoglobin on regional vascular conductance in dogs. *Anesth Analg* 1997; 85:265-73
3. Kasper SM, Walter M, Grune F, Bischoff A, Erasmi H, Buzello W: Effects of a hemoglobin-based oxygen carrier (HBOC-201) on hemodynamics and oxygen transport in patients undergoing preoperative hemodilution for elective abdominal aortic surgery. *Anesth Analg* 1996; 83:921-7
4. Kasper SM, Grune F, Walter M, Amr N, Erasmi H, Buzello W: The effects of increased doses of bovine hemoglobin on hemodynamics and oxygen transport in patients undergoing preoperative hemodilution for elective abdominal aortic surgery. *Anesth Analg* 1998; 87:284-91
5. Lee R, Neya K, Svizzero TA, Vlahakes GJ: Limitations of the efficacy of hemoglobin-based oxygen-carrying solutions. *J Appl Physiol* 1995; 79:236-42
6. Hess JR: Review of modified hemoglobin research at Letterman: Attempts to delineate the toxicity of cell-free tetrameric hemoglobin. *Artif Cells Blood Substit Immobil Biotechnol* 1995; 23:277-89
7. de Figueiredo LF: Vasoactive properties of synthetic blood substitutes. *Medicina* 1998; 58:403-10
8. Schultz SC, Grady B, Cole F, Hamilton I, Burhop K, Malcolm DS: A role for endothelin and nitric oxide in the pressor response to diaspirin cross-linked hemoglobin. *J Lab Clin Med* 1993; 122:301-8
9. Doyle MP, Apostol I, Kerwin BA: Glutaraldehyde modification of recombinant human hemoglobin alters its hemodynamic properties. *J Biol Chem* 1999; 274:2583-91
10. Lieberthal W, Fuhro R, Freedman JE, Toolan G, Loscalzo J, Valeri CR: O-*raffinose* cross-linking markedly reduces systemic and renal vasoconstrictor effects of unmodified human hemoglobin. *J Pharmacol Exp Ther* 1999; 288:1278-87
11. Macdonald VW, Motterlini R: Vasoconstrictor effects in isolated rabbit heart perfused with bis(3,5-dibromosalicyl)fumarate cross-linked hemoglobin (alpha alpha Hb). *Artif Cells Blood Substit Immobil Biotechnol* 1994; 22:565-75
12. Hess JR, Macdonald VW, Gomez CS, Coppes V: Increased vascular resistance with hemoglobin-based oxygen carriers. *Artif Cells Blood Substit Immobil Biotechnol* 1994; 22:361-72
13. Biro GP, Taichman GC, Lada B, Keon WJ, Rosen AL, Sehgal LR: Coronary vascular actions of stroma-free hemoglobin preparations. *Artif Organs* 1988; 12:40-50
14. Gulati A, Singh R, Chung SM, Sen AP: Role of endothelin-converting enzyme in the systemic hemodynamics and regional circulatory effects of proendothelin-1 (1-38) and diaspirin cross-linked hemoglobin in rats. *J Lab Clin Med* 1995; 126:559-70
15. Gulati A, Sharma AC, Singh G: Role of endothelin in the cardiovascular effects of diaspirin crosslinked and stroma reduced hemoglobin. *Crit Care Med* 1996; 24:137-47

## CASE REPORTS

16. Standl T, Horn P, Wilhelm S, Greim C, Freitag M, Freitag U, Sputtek A, Jacobs E, Schulte am Esch J: Bovine haemoglobin is more potent than autologous red blood cells in restoring muscular tissue oxygenation after profound isovolaemic haemodilution in dogs. *Can J Anaesth* 1996; 43:714-23

17. Horn EP, Standl T, Wilhelm S, Jacobs EE, Freitag U, Freitag M,

Schulte am Esch J: Bovine hemoglobin increases skeletal muscle oxygenation during 95% artificial arterial stenosis. *Surgery* 1997; 121: 411-8

18. Homer LD, Weathersby PK, Kiesow LA: Oxygen gradients between red blood cells in the microcirculation. *Microvasc Res* 1981; 22:308-23

Anesthesiology  
2000; 92:885-7  
© 2000 American Society of Anesthesiologists, Inc.  
Lippincott Williams & Wilkins, Inc.

## Acute Myocardial Ischemia after Administration of Ondansetron Hydrochloride

Voytek Bosek, M.D.\* Pink Hu, M.D.,† Lary A. Robinson, M.D.‡

ONDANSETRON hydrochloride (Zofran; Glaxo Wellcome Inc., Research Triangle Park, NC) antagonizes the effect of serotonin at the 5-hydroxytryptamine<sub>3</sub> (5-HT<sub>3</sub>) receptors.<sup>1</sup> Serotonin is released from the enterochromaffin cells of the small intestine, stimulates the vagal afferents through the 5-HT<sub>3</sub> receptors, and initiates the vomiting reflex. Through its 5-HT<sub>3</sub>-blocking effect, ondansetron hydrochloride has been progressively introduced into the practice of anesthesiology to treat perioperative nausea and vomiting. Administration of ondansetron is believed to be safe and is associated with very few reported serious side effects.<sup>1,2</sup> However, we describe a patient with no history of cardiac abnormalities who experienced a severe episode of acute myocardial ischemia that occurred during the intravenous injection of ondansetron in the early postoperative period.

### Case Report

A 60-yr-old woman who was a nonsmoker developed slight exertional wheezing. A 2-cm-diameter left lower lobe lung mass with a surrounding infiltrate was found on a chest radiograph and subsequent computed chest tomography, with no lymphadenopathy. A transbronchial biopsy provided the diagnosis of well-differentiated adenocarcinoma with bronchioloalveolar features. She had a medical history of several prior minor operations with no complications. She also reported the subjective feeling of an occasional extrasystole, but no other cardiac symptoms were elicited. She was very physically active, exercising frequently each week in a health club. Her physical examination was entirely normal. The preoperative electrocardiogram (ECG) demonstrated only minimal nonspecific S-T changes. Other than a mild anemia (hemoglobin, 11.5 g/dl), results of her laboratory tests were normal. Pulmonary function testing showed very mild airway obstruction.

The patient (52 kg, 162 cm, American Society of Anesthesiologists physical status II) was scheduled for a left lower lobectomy. On the morning of surgery, a thoracic epidural catheter was placed with no paresthesias, blood, or cerebrospinal fluid return. The patient then underwent an uncomplicated left lower lobectomy and mediastinal lymphadenectomy with general anesthesia; ventilatory separation of the lungs was accomplished with a left-sided double-lumen endotracheal tube. She was easily extubated in the operating room. The initial postoperative course was uneventful. The patient received good pain relief from epidurally administered ropivacaine and fentanyl. The final pathology revealed a 2.1 × 2.0-cm well-differentiated bronchioloalveolar carcinoma involving the visceral pleura, with all lymph nodes free of metastases, staged as T2N0M0 (stage IB).

In the surgical intensive care unit on the first postoperative day while still on continuous ECG monitoring (fig. 1), the patient started to complain of nausea, worse than the mild intermittent nausea present on the day of surgery. She received droperidol 0.625 mg intravenously in three consecutive doses approximately 30 min apart, but without adequate therapeutic effect. Her continuously monitored arterial oxygen saturation on room air at that time was 99%. Because of the continuing nausea, antiemetic ondansetron was prescribed. Immediately after intravenous administration of 2.0 mg ondansetron, the

\* Associate Professor, Department of Anesthesiology.

† Resident, Department of Anesthesiology.

‡ Professor, Department of Cardiothoracic Surgery.

Received from the Department of Anesthesiology and Cardiothoracic Surgery, H. Lee Moffitt Cancer Center and Research Institute NCI, University of South Florida College of Medicine, Tampa, Florida. Submitted for publication July 6, 1999. Accepted for publication November 3, 1999. Support was provided solely from departmental and/or institutional sources.

Address reprint requests to Dr. Bosek: Department of Anesthesiology, H. Lee Moffitt Cancer Center, 12902 Magnolia Drive, Tampa, Florida 33612-9497. Address electronic mail to: bosekv@moffitt.usf.edu

Key words: Antiemetics; perioperative complications; serotonin antagonists; ventricular tachycardia.