

CORRESPONDENCE

3. Sprung CL, Peduzzi PN, Shatney CH, Schein RMH, Wilson MF, Sheagren JN, Hinshaw LB, The Veterans Administration Systemic Sepsis Cooperative Study Group: Impact of encephalopathy on mortality in the sepsis syndrome. *Crit Care Med* 1990; 18:801-6

4. Jackson AC, Gilbert JJ, Young GB, Bolton CF: The encephalopathy of sepsis. *Can J Neurol Sci* 1985; 12:303-7

5. Persson L, Hardemark HG, Gustafsson J, Rundstrom G, Mendel-Hartvig I, Esscher T, Pahlmann S: S-100 protein and neuron-specific enolase in cerebrospinal fluid and serum: Markers of cell damage in human central nervous system. *Stroke* 1987; 18:911-8

6. Zarkovic K, Zarkovic N, Schlag G, Redl H, Waeg G: Histological aspects of sepsis-induced brain changes in a baboon model, Shock, Sepsis, and Organ Failure—Brain Damage Secondary to Hemorrhagic-Traumatic Shock, Sepsis, and Traumatic Brain Injury. Edited by Schlag G, Redl H, Traber D. Berlin, Heidelberg, New York, Springer, 1997, pp 146-64

7. Bone RC, Balk RA, Cerra FB, Dellinger RP, Fein AM, Knaus WA, Schein RMH, Sibbald WJ: ACCP/SCCM consensus conference: Definitions for sepsis and organ failure and guidelines for the use of innovative therapies in sepsis. *Chest* 1992; 101:1644-55

8. Collazos J, Esteban C, Fernández A, Genollá J: Measurement of the serum tumor marker neuron-specific enolase in patients with benign pulmonary diseases. *Am J Respir Crit Care Med* 1994; 150:143-5

9. Gao F, Harris DN, Sapsed-Byrne S, Sharp S: Neurone-specific enolase and Sangtec 100 assays during cardiac surgery: Part III—Does haemolysis affect their accuracy? *Perfusion* 1997; 12:171-7

10. Missler U, Wiesmann M, Friedrich C, Kaps M: S-100 protein and neuron-specific enolase concentrations in blood as indicators of infarction volume and prognosis in acute ischemic stroke. *Stroke* 1997; 28:1956-60

11. Isobe T, Takahashi K, Okuyama T: S-100 α (alpha alpha) protein is present in neurons of the central and peripheral nervous system. *J Neurochem* 1984; 43:1494-6

12. Marangos PJ, Schmechel DE: Neuron specific enolase, a clinically useful marker for neurons and neuroendocrine cells. *Annu Rev Neurosci* 1987; 10:269-95

(Accepted for publication October 21, 1999.)

Anesthesiology
2000; 92:907-8
© 2000 American Society of Anesthesiologists, Inc.
Lippincott Williams & Wilkins, Inc.

Uncoiling of Wire in Arrow Flextip Epidural Catheter On Removal

To the Editor:—We wish to report the uncoiling and separation of the internal wire of a Flextip epidural catheter (Arrow International, Reading, PA) on removal. We placed a Flextip catheter into the L3-L4 interspace of a 14-yr-old gravida 1, 80-kg, 160-cm tall patient for labor analgesia using a 17-gauge Tuohy needle and the technique of loss of resistance to air. We attempted to introduce the epidural catheter, but it would not pass beyond the end of the needle. We then advanced the epidural needle approximately 1 mm in accordance with the directions supplied by the manufacturer and were then able to introduce the epidural catheter into the epidural space. The catheter was advanced 4 cm into the epidural space, and the needle was withdrawn. The epidural catheter functioned normally for labor analgesia. Subsequently, the local anesthetic infusion was discontinued, and the conduction block was allowed to recede. On removal of the catheter, there was considerable resistance to withdrawal. We asked the patient to flex her back to facilitate the removal of catheter. With increased flexion, we were able to withdraw the catheter. However, on continued attempts to withdraw, we realized that the plastic outer portion of the catheter had been removed from the patient's back, but the wire was uncoiling and still within the patient. At this time, because the patient had good sensation and movement in all dermatomes where epidural analgesia had been present, we believed that it was acceptable to continue with gentle traction as long as there were no paresthesias during this procedure. The wire gradually was removed from the patient's back with no symptoms or sequelae.

We believe this is the first report of the internal wire of an epidural catheter uncoiling within the patient's back. This may pose risk to the patient because the sharp wire may increase the potential for internal

lacerations. We examined the catheter and wire using a microscope and found that the plastic catheter appeared intact, but a sharp hook was present at the end of the wire (fig. 1) Figure 2 shows the epidural catheter with 19 cm of the extended uncoiled wire.

The possibility exists that structures in the epidural space may be lacerated by the sharp wire during removal from the patient. This may increase the possibility of epidural hematoma. We removed the catheter after the block had resolved, and no symptoms were present at that time. In a recent case report,¹ an epidural catheter fragment was retained after coiling around a nerve root. One can speculate that if an epidural catheter has coiled around a nerve root and also separates, as it did in our patient, injury to the nerve root may be more likely.

Harvey J. Woehlck, M.D.

Associate Professor of Anesthesiology
hwoehlck@mcw.edu

Bhupinder Bolla, M.D.

Resident in Anesthesiology
Medical College of Wisconsin
Milwaukee, Wisconsin 53226

Reference

1. Blanchard N, Clabea J, Ossart M, Dekens J, Legars D, Tchaoussoff J: Radicular pain due to a retained fragment of epidural catheter. *ANESTHESIOLOGY* 1997; 87:1567-9

(Accepted for publication October 22, 1999.)

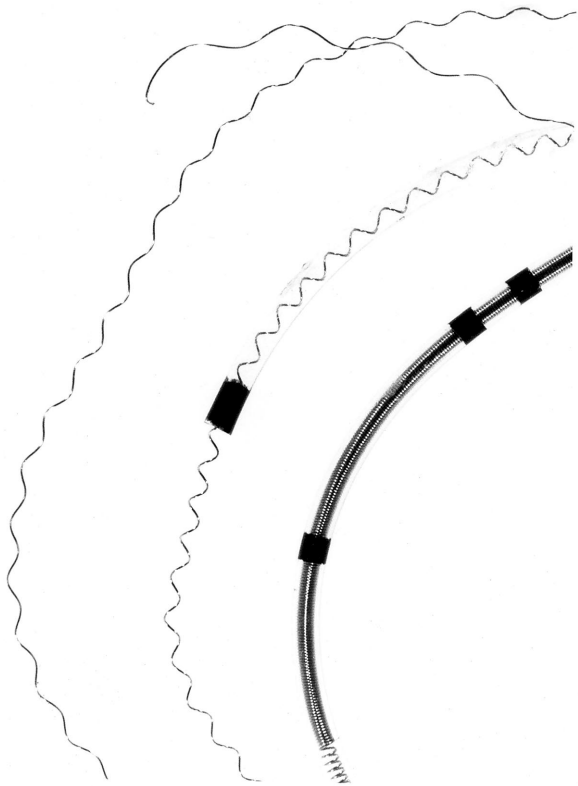


Fig. 1. The catheter and part of the wire that uncoiled and was extended beyond the plastic portion of the catheter is shown. Note the sharp hook at the end of the wire.

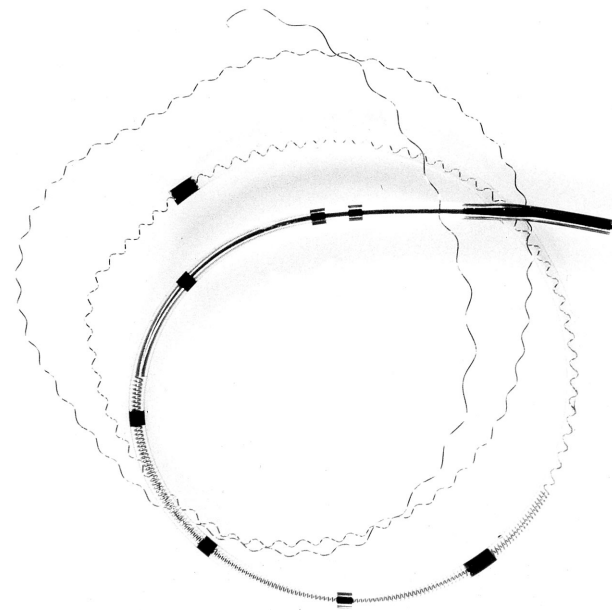


Fig. 2. The catheter is shown with a 19-cm length of wire extending beyond the plastic portion of the epidural catheter.

Anesthesiology
2000; 92:908-9
© 2000 American Society of Anesthesiologists, Inc.
Lippincott Williams & Wilkins, Inc.

In Reply:—Dr. Woehlk's concern for the possibility of the wire lacerating structures in the epidural space during removal is the first of its kind to be reported to Arrow International, Inc. Based on Arrow's experience with the FlexTip Plus, there have been no reported incidents of lacerations from the wire. The clinical advantages of the FlexTip Plus is that it is softer than conventional catheters and has been proven to reduce indwelling complications.

The outer surface of the FlexTip Plus is a very soft polyurethane material. This softness offers many clinical advantages; however, occasionally users encounter a catheter that is more difficult to remove and requires extra care. Familiarizing oneself with the properties of the FlexTip Plus and specific removal techniques will allow the catheter use to be uneventful, even in a situation in which the catheter at first appears to be difficult to remove.

The FlexTip Plus is extremely strong and can withstand significant stretching, but it is not unbreakable. New users should acclimate themselves with the catheter's elongation properties and break point. Resistance is a signal that the patient's anatomy is applying atypical force to the indwelling portion of the catheter. If the catheter cannot be withdrawn with minimal force, Arrow recommends considering the following options:

1. Reposition the patient and/or allow the patient to relax for several minutes/hours and attempt removal later. Studies have proven that the force required to remove an epidural catheter can vary dramatically depending on patient positioning. Arrow recommends that the patient be placed in the same position for removal as they were for placement.
2. Some users have found that injecting a small bolus of saline or positive pressure with air while removing the catheter has helped. These techniques are documented in the literature.¹
3. Finally, in conjunction with suggestion no. 1, several users have described how they successfully stretched the catheter slightly and taped it to the skin, thus creating permanent tension on the catheter. As the patient relaxes and moves, the forces holding the indwelling portion of the catheter diminish, and the tension on the catheter (created by stretching and taping) cause it to automatically retract from the epidural space. Depending on the length of catheter indwelling and how much the catheter is stretched before taping it down, following this procedure should make the catheter easier to remove. This technique may be repeated if necessary.

CORRESPONDENCE

Under no circumstance should extreme force be applied to the catheter during removal. We also recommend a review of the current literature, because alternative techniques have been published.

We strongly believe that the FlexTip Plus is associated with far fewer indwelling complications than standard epidural catheters and that this occurrence is rare compared with the number of catheters sold.

Douglas G. Keim
Marketing Associate, Regional Anesthesia

Anesthesiology
2000; 92:909
© 2000 American Society of Anesthesiologists, Inc.
Lippincott Williams & Wilkins, Inc.

Enterococcus faecalis Meningitis after Spinal Anesthesia

To the Editor:—We read with interest the recent case report of *Streptococcus salivarius* meningitis occurring after spinal anesthesia described by Laurila *et al.*¹ We report another case of meningitis after spinal anesthesia caused by an unusual microorganism, *Enterococcus faecalis*. A 20-yr-old healthy man underwent spinal anesthesia for surgery to treat inguinal hernia. The patient's history and preoperative examination revealed no preexisting pathology. He had no symptoms of systemic infection. Spinal anesthesia was performed with the patient in the sitting position, and there was no evidence of local skin infection. The skin was prepared with povidone iodine 10% (Betadine; Asta Medica S.A., Madrid, Spain), which was wiped off vigorously from the puncture site with sterile sponges. Sterile technique (mask, hat, sterile drape, and sterile gloves) was used. A disposable 27-gauge pencil-point spinal needle with sterile introducer (Whitacre spinal set; Becton Dickinson S.A., Madrid, Spain) was inserted at the L3-L4 spinal interspace, on the first attempt, 3 min after back cleaning. Free flow of cerebrospinal fluid (CSF) was obtained on the first attempt, and a mixture of 10 mg hyperbaric bupivacaine, 0.5%, (B. Braun Medical S.A., Barcelona, Spain) and 20 µg fentanyl (Roche S.A., Madrid, Spain) was injected. The patient was turned supine. The immediate perioperative period was unremarkable, and the patient appeared well. Approximately 17 h after completion of the surgery, the patient became acutely confused and complained of severe headache and stiff neck. He was noted to have an altered mental status, fever, signs of meningeal irritability, and nausea and vomiting. A diagnosis of acute meningitis was considered. Lumbar puncture was performed, and CSF samples and blood were sent for analysis. There was no erythema or cellulitis at the site of needle insertion. A sample blood count was obtained, which revealed leukocytosis (23,050 cells/µl) with polymorphonucleocytes. A sample of CSF appeared turbid. Analysis of CSF showed a protein concentration of 1,239 mg/dl (normal range, 20–50 mg/dl), a glucose concentration of 19 mg/dl (normal range, 40–70 mg/dl), a leukocyte count of 9,550/µl (normal range, < 5/µl; 96% polymorphs, 4% monocytes). Gram-positive cocci were observed by Gram staining, and in bacterial culture, *E. faecalis* was found. Urine and blood cultures obtained concomitantly showed no growth. The patient was transferred to the intensive care unit, was treated with ampicilline and gentamicin, and was discharged home on the ninth postoperative day with no residual neurologic deficit.

Enterococci are the most common aerobic, Gram-positive cocci

Arrow International, Inc.
Reading, Pennsylvania

Reference

1. Gadalla F: Removal of a tenacious epidural catheter (letter). *Anesth Analg* 1992; 75:1070

(Accepted for publication October 22, 1999.)

found in the bowel flora of humans. These organisms are clinically important nosocomial pathogens. They are usually associated with urinary tract, wound, and blood infections that develop after instrumentation or intravascular-catheter contamination. These organisms less frequently cause meningitis² and endocarditis.³ Meningitis is a rare complication of spinal anesthesia. When meningitis occurs after spinal or epidural block, it is often difficult to establish a cause-and-effect relationship between it and spinal anesthesia.⁴ Two routes exist for such infection to reach the CSF. First, failure of aseptic techniques could result in the introduction of exogenous organisms into the CSF. Second, bacteria in the patient's blood at the time of lumbar puncture may gain access to the subarachnoid space because of microscopic bleeding caused by insertion of the needle. However, most cases of meningitis after central nerve block are probably aseptic in origin.⁵

In our opinion, this case resulted from some unidentified failure of the aseptic technique, because an endogenous source, including hematogenous spread during elective herniorrhaphy in a healthy man, is unlikely.

José A. Tortosa M.D., Ph.D.
Joaquín Hernández-Palazón M.D., Ph.D.
Specialist
Department of Anesthesia
Hospital Universitario "Virgen de la Arrixaca"
Murcia, Spain
isv01mu@nacom.es

References

1. Laurila JJ, Kostamovaara PA, Alahunhta S: *Streptococcus salivarius* meningitis after spinal anesthesia. *ANESTHESIOLOGY* 1998; 89:1579–80
2. Ready LB, Heifer D: Bacterial meningitis in parturients after epidural anesthesia. *ANESTHESIOLOGY* 1989; 71:988–90
3. Stevenson KB, Murray EW, Sarubbi FA: Enterococcal meningitis: Report of four cases and review. *Clin Infect Dis* 1994; 18:233–9
4. Wedel DJ, Horlocker TT: Risks of regional anesthesia: Infectious, septic. *Reg Anesth* 1996; 21(Suppl 6):57–61
5. Burke, D, Wildsmith JAW: Meningitis after spinal anaesthesia. *Br J Anaesth* 1997; 78:635–6

(Accepted for publication October 25, 1999.)