

5. Karakousis CP, Kanter PM, Park HC, Sharma SD, Moore R, Ewing JH: Tourniquet infusion versus hyperthermic perfusion. *Cancer* 1982; 49:850-8

6. Kremenz ET, Ryan RF, Carter RD, Sutherland CM, Reed RJ: Hyperthermic regional perfusion for melanoma of the limbs: cutaneous melanoma, *Clinical Management and Treatment Results Worldwide*. Edited by Balch CM, Milton GW. Philadelphia, JB Lippincott, 1985, pp 171-95

7. Klaase JM, Kroon BB, van Geel AN, Eggermont AM, Franklin HR:

Systemic leakage during isolated limb perfusion for melanoma. *Br J Surg* 1993; 80:1124-6

8. Caldwell JE: Desflurane clinical pharmacokinetics and pharmacodynamics. *Clin Pharmacokinet* 1994; 27(1):6-18

9. Yasuda N, Lockhart SH, Eger EI II, Weiskopf RB, Johnson BH, Freire BA, Fassoulaki A: Kinetics of desflurane, isoflurane and halothane in humans. *ANESTHESIOLOGY* 1991; 74:489-98

10. Ohmeda Modulus CD Anesthesia System, Module 6, Respiratory Gas Monitor (operation and maintenance manual).

Anesthesiology

2000; 93:576-8

© 2000 American Society of Anesthesiologists, Inc.

Lippincott Williams & Wilkins, Inc.

Right Atrial Membrane Interfering with Insertion of Pulmonary Artery Catheter

Uriel A. Yodfat, M.D.

RIGHT atrial membranes arise from resorption failure of the sinus venosus valve.^{1,2} Most right atrial membranes are attributed to the degree of persistence of valve tissue and are associated with congenital defects. A case in which a right atrial membrane interferes with passage of a pulmonary artery catheter is presented.

Case Report

An 81-yr-old man (105 kg, 180 cm) presented for a coronary artery bypass grafting procedure. Preoperative cardiac catheterization revealed severe three-vessel occlusive coronary artery disease. Left ventricular function was estimated to be normal, with an ejection fraction of 60%. Cardiac output was 4.8 l/min, with an index of 2.1. Pulmonary artery pressure, measured *via* the femoral vein to the inferior vena cava route, was normal. Results of a physical examination were remarkable only for a plethoric purplish red face, which the patient has

Staff Anesthesiologist, Riverside Anesthesia, Camp Hill, Pennsylvania; Assistant Professor of Anesthesia, Department of Anesthesia, Pennsylvania State University Medical Center.

Received from the Department of Anesthesia, Pennsylvania State University Medical Center, Hershey, Pennsylvania. Submitted for publication December 3, 1999. Accepted for publication April 13, 2000. Supported in part by the Pennsylvania State University Medical Center.

Address reprint requests to Dr. Yodfat: 207 House Avenue, Suite 102, Camp Hill, Pennsylvania 17011. Address electronic mail to: uyodfat@netscape.net

Individual article reprints may be purchased through the Journal Web site, www.anesthesiology.org

Key words: Cor Triatriatum Dexter; sinoatrial valve; transesophageal echocardiography.

had for many years. Results of other laboratory tests and of chest radiography were noncontributory.

On the morning of surgery, the patient was brought to the operating room, routine monitors were placed, intravenous access was obtained, and a radial arterial catheter was inserted. General anesthesia was induced, and an endotracheal tube was inserted without difficulty. The right internal jugular vein was identified, and an 18-gauge catheter was inserted. Catheter position was verified by blood aspiration and by pressure transduction to rule out arterial insertion. A wire was passed through the catheter but met with resistance at a depth of 15-20 cm. Several attempts to reposition the wire, including reinsertion of the catheter by several experienced operators from the anesthesia and surgery team, were also met with resistance.

A right-sided subclavian approach was attempted, but, again, it was met with the same resistance at similar depths. Subsequently, the left subclavian vein was cannulated after a wire was passed without resistance. Multiple attempts to float a pulmonary artery catheter were unsuccessful, without sight of a right ventricular pressure trace. The catheter was left at a depth of 20 cm, and preparation for surgery continued.

Transesophageal echocardiography was performed. The transesophageal echocardiography revealed a long right atrial membrane that extended from the lower portion of the interatrial septum, above the tricuspid valve, which divided the right atrial lumen into anterolateral and posteromedial chambers (fig. 1). The membrane appeared to be mobile in its center but fixed by its margins. A microbubble imaging contrast test performed by injecting agitated saline *via* the central line side port showed filling of the posteromedial portion first and a rapid propagation into the anterolateral portion *via* what appeared to be a single opening in the membrane close to the interatrial septum.

No right-to-left shunts in the form of an atrial septal defect or a patent foramen ovale were shown. Results of the rest of the transesophageal echocardiography examination were normal. After the patient's chest was opened, the surgeon noted that the venous system draining into the right atrium was exceptionally dilated.

Because of these findings, the right atrium was opened during the cardiopulmonary bypass period of the procedure, and the membrane was identified and resected. The transesophageal echocardiography

CASE REPORTS

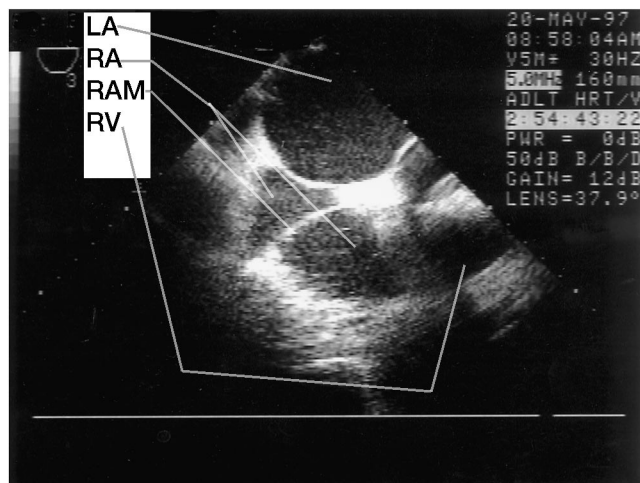


Fig. 1. Transesophageal echocardiographic view of the left atrium (LA), right atrium (RA), right atrial membrane (RAM), and right ventricle (RV) in partial view.

findings were confirmed, and a diagnosis of Cor Triatriatum Dexter was made. The rest of the operation was uneventful, and the patient was weaned from the cardiopulmonary bypass machine without difficulty. The pulmonary artery catheter was floated into position without difficulty after cardiopulmonary bypass. The patient was taken to the intensive care unit, and he was extubated several hours later. He was discharged from the hospital on the ninth postoperative day.

Discussion

Right atrial membranes represent embryonic remnants from the fetal development of the valve between the sinus venosus and the primitive common atrium. During the fourth week of human embryonic development, the common atrium is separated from the sinus venosus by a bileaflet valve, known as the valve of the sinus venosus or as the sinoatrial valve. As the primitive common atrium divides, the left leaflet of the sinoatrial valve is incorporated into the right surface of the interatrial septum and becomes part of the septum secundum. The right leaflet of the sinoatrial valve resorbs between the ninth and fifteenth weeks of gestation and leaves behind the Eustachian valve of the inferior vena cava and the Thebesian valve of the coronary sinus. During this time, the sinus venosus gives rise to the superior and inferior vena cava and to the coronary sinus.

In the adult heart, the remnant of the right leaflet can be traced to a small fold near the opening of the inferior vena cava. Failure of complete resorption of the right leaflet of the sinoatrial valve leads to a scale of anatomic findings, with or without physiologic implications, depending on the degree of persistence of leaflet tissue and

accompanying defects.¹ In the mild form, a large eustachian valve can be identified near the orifice of the inferior vena cava. This valve remnant has a free-floating edge in the right atrium, and it is a relatively common incidental finding during transesophageal echocardiography.² A more developed valve remnant can be fenestrated and form a perforated veil, known as the Chiari network.¹ The extreme case of a persistent sinoatrial right leaflet completely divides the right atrium into an anterolateral and posteromedial portion, and is therefore known as Cor Triatriatum Dexter.³ Such a membrane usually has a single fenestration close to the interatrial septum. A right atrial membrane was first noted in 1871 by Lauenstein,⁴ but the term Cor Triatriatum Dexter was mentioned first in 1963 by Doucette.⁵

The incidence of Cor Triatriatum Dexter comprises approximately 0.025% of the cases of congenital heart disease, but it has an unclear definition because it can be found in different anatomic degrees, with varying physiologic and symptomatologic presentations. It is unclear why a well-developed membrane that divides the right atrium in two and possibly creates a grade chronic obstruction to flow, as described in this case report, presents incidentally with so few symptoms, compared with other symptomatic membranes found in adulthood^{1,3} or in childhood that cause heart failure and cyanosis.⁶

The function of the Eustachian valve in fetal life is to divert blood flow from the inferior vena cava *via* the foramen ovale to the left atrium. When Cor Triatriatum Dexter is present, it often is accompanied by a patent foramen ovale or by an atrial septal defect, which diverts some of the right atrial blood, in a right-to-left shunt, to the left atrium, potentially causing cyanosis.

The current case is characterized by a well-developed anatomically impressive membrane; yet, because of membrane fenestration, there was little flow obstruction, and because of an absent patent foramen ovale and atrial septal defect, there was no flow diversion or shunt which allowed the patient to lead a normal life, without significant symptoms related to the right atrial membrane. In rare instances, a right atrial membrane was reported to cause such significant obstruction to flow that the presenting symptoms were of tricuspid atresia, and the tricuspid valve and the right ventricle were underdeveloped. Other cases reported a membrane that prolapsed through the tricuspid valve into the right ventricle, and even through the pulmonic valve.⁷⁻⁹ The diagnosis of right atrial membranes is best made by use of two-dimensional echocardiography,^{1,3,10} and, when

found, recommendations for resection are probably related to symptoms resulting from the membrane.

References

1. Dobbertin A, Warnes C, Seward J: Cor Triatriatum Dexter in an adult diagnosed by transesophageal echocardiography: A case report. *J Am Soc Echocardiogr* 1995; 8:952-7
2. Fiorilli R, Argento G, Tomasco B, Serino W: Cor Triatriatum Dexter diagnosed by transesophageal echocardiography. *J Clin Ultrasound* 1995;23:502-4
3. Valdes-Cruz LM, Cayre RO: Anomalies of the tricuspid valve and right atrium. *Echocardiographic Diagnosis of Congenital Heart Disease*. Philadelphia, Lippincott-Raven, 1999, pp 237-9
4. Lauenstein C: Varietat der klappen des rechten atrium. *Virchows Arch* 1876; 68:632-3
5. Doucette J, Knoblich R: Persistent right valve of the sinus venosus: So-called Cor Triatriatum Dexter. Review of the literature and report of a case. *Arch Pathol* 1963; 75:105-12

6. Burton D, Chin A, Weinberg PM, Pigott JD: Identification of Cor Triatriatum Dexter by two-dimensional echocardiography. *Am J Cardiol* 1987; 60:409-10

7. Dubin IN, Hollinshead WH: Congenitally insufficient tricuspid valve accompanied by an anomalous septum in the right atrium. *Arch Pathol* 1944; 38:225-8

8. Folger GM: Supravalvular tricuspid stenosis: Association with developmental abnormalities of the right heart and derivatives of the sixth aortic arch. *Am J Cardiol* 1968; 21:81-7

9. Nakano S, Kawashima Y, Miyamoto T, Kitamura S, Manabe H: Supravalvular tricuspid stenosis resulting from persistent right sinus venosus valve: A report of successful correction. *Ann Thorac Surg* 1974; 17:591-5

10. Battle-Diaz J, Stanley P, Kratz C, Fouron JC, Guerin R, Davignon A: Echocardiographic manifestations of persistence of the right sinus venosus valve. *Am J Cardiol* 1979; 43:850-3

Anesthesiology
2000; 93:578-9
© 2000 American Society of Anesthesiologists, Inc.
Lippincott Williams & Wilkins, Inc.

Anaphylaxis during Insertion of a Ventriculoperitoneal Shunt

Edmund D. Carver, F.R.C.A.,* Bernard M. Braude, F.R.C.P.C.,† Adelle R. Atkinson, F.R.C.P.C.,‡ Milton Gold, F.R.C.P.C.§

THE authors describe two episodes of anaphylaxis in a child undergoing revision of a ventriculoperitoneal shunt. Initially, the anaphylaxis was attributed to either vancomycin or latex allergy; however, after the second episode, the child was found to be sensitive to bacitracin that had been

used to soak the shunt tubing before insertion on both occasions.

Case Report

A 9-yr-old boy with a repaired myelomeningocele and congenital hydrocephalus had undergone four previous shunt revisions. He had a history of urticarial reactions to cefaclor and flucloxacillin. One year previously, he experienced urticaria, facial swelling, and difficulty breathing after administration of topical polymyxin B sulfate ointment with bacitracin (Polysporin; Warner-Lambert Canada Inc., Scarborough, Ontario, Canada).

The patient presented with signs of increased intracranial pressure which indicated a need for urgent shunt revision. An intravenous infusion of vancomycin was started to provide antibiotic coverage. Cutaneous flushing occurred, consistent with "Red Man" syndrome, which was treated by slowing the infusion rate and by administration of intravenous diphenhydramine.

In the operating room the next day, routine precautions to avoid exposure to latex were taken. After induction of anesthesia, an intravenous infusion of vancomycin was started. One hour after induction, systolic blood pressure decreased suddenly to 50 mmHg. This was associated with bilateral expiratory wheezing, cutaneous erythema, an increase in peak airway pressure from 20 to 35 cm H₂O, and a decrease in hemoglobin oxygen saturation from 99% to 89%. The patient's lungs were ventilated with 100% oxygen, and he was administered an intravenous fluid bolus of 500 ml Ringer's lactate and 50 µg intravenous epinephrine. Systolic blood pressure returned to 90 mmHg, hemoglo-

* Fellow, Pediatric Anesthesiology. Current position: Specialist Registrar in Anesthesia, Royal Victoria Infirmary, Newcastle-upon-Tyne, United Kingdom.

† Staff Anesthesiologist and Assistant Professor.

‡ Fellow, Immunology and Allergy.

§ Staff Allergist and Associate Professor.

Received from the Departments of Anesthesiology and Immunology and Allergy, The Hospital for Sick Children and the University of Toronto, Toronto, Ontario, Canada. Submitted for publication December 17, 1999. Accepted for publication April 13, 2000. Support was provided solely from institutional and/or departmental sources.

Address reprint requests to Dr. Carver: Specialist Registrar in Anaesthesia, Royal Victoria Infirmary, Queen Victoria Road, Newcastle-upon-Tyne, NE1 4LP, United Kingdom. Address electronic mail to: ed.jus@lineone.net

Individual article reprints may be purchased through the Journal Web site, www.anesthesiology.org

Key words: Allergy; bacitracin; hydrocephalus; neurosurgery.