

B9

**TITLE:** LOSS OF RELAXATION TO FENOLDOPAM IN THE RAT RENAL AND SUPERIOR MESENTERIC ARTERY, BUT NOT IN THE AORTA  
**AUTHORS:** M.H. Wall, MD, P.R. Roberts, MD, M. Shouse, MS, J.R. Tobin, MD, R.C. Prielipp, MD  
**AFFILIATION:** Dept. of Anesthesiology, Wake Forest University School of Medicine, Winston-Salem, NC 27157

Fenoldopam (FEN) is a selective dopamine DA1 receptor agonist, which would be predicted to cause progressive relaxation of vascular smooth muscle, in contrast to dopamine, a non-selective dopamine, beta and alpha agonist (1). We hypothesized that FEN would cause progressive and uniform relaxation of all abdominal arterial vessels (isolated aortic [Ao], renal [RA] and superior mesenteric [SMA] vascular rings) harvested from normal adult rats.

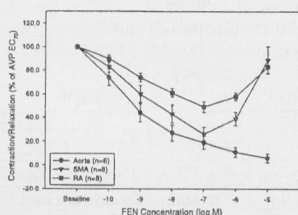
After Animal Care and Use Committee approval Ao (n=6), RA (n=8) and SMA (n=8) arteries were removed from euthanized 325-350 gm male Sprague-Dawley rats and 3 mm rings were prepared and suspended in a bath of oxygenated Krebs-Henseleit buffer at 37°C. Tension was recorded with Grass FTO3 force transducers. Baseline tension of each ring was determined and intact endothelium was confirmed by relaxing a phenylephrine (10<sup>-6</sup> M) precontracted vessel with 10<sup>-7</sup> M acetylcholine. Next, cumulative concentration-contraction curves were obtained for AVP (10<sup>-10</sup> to 10<sup>-7</sup> M). The concentration of AVP causing 70% of the maximum contraction was determined (EC<sub>70</sub>). The EC<sub>70</sub> was used to precontract the rings, and then a concentration-response curve was obtained for FEN (10<sup>-10</sup> to 10<sup>-5</sup> M). Data shown are % of AVP EC<sub>70</sub> ± SEM. Differences between groups were analyzed by repeated measures ANOVA. P<0.05 was considered significant.

FEN (10<sup>-10</sup> to 10<sup>-5</sup> M) caused concentration dependent relaxation in Ao rings (see figure). SMA and RA rings precontracted with AVP showed a bi-phasic response with progressive relaxation from 10<sup>-10</sup> to 10<sup>-7</sup> M FEN, then progressive contraction at 10<sup>-6</sup> and 10<sup>-5</sup> M FEN. The concentration-response curves between all three ring groups were statistically different (main effect: P<0.001; ring/dose interaction: P<0.0001).

FEN has dramatically different pharmacodynamic effects in vascular rings isolated from different arteries of rats. This is the first report of bi-phasic effects of FEN in renal and mesenteric arteries. These results show that while the specific DA1 agonist FEN may be a vasodilator in some beds, the pharmacodynamic response is not uniform in all regional vascular beds. These altered responses in regional vascular beds may be due to changes in the number or function in regional DA1 receptors, FEN binding to other receptors, or regional differences in DA1 signal transduction or the receptor-effector complex. Further mechanistic studies are underway.

**References:** 1. Drugs 1997;54:634-650

Supported by WFUSM Venture funds and a SCA/REF Starter Grant.



B10

**TITLE:** SPLIT-LUNG VOLUMETRY IN PATIENTS AFTER SINGLE-LUNG TRANSPLANTATION USING <sup>3</sup>HELIUM-MRI  
**AUTHORS:** K. Markstaller, B. Eberle, H.-U. Kauczor\*, J. Lill\*\*, M. Puderbach\*, N. Weiler  
**AFFILIATION:** Departments of Anesthesiology, \*Radiology, and \*\*Pulmonology, Johannes Gutenberg-University, D - 55131 Mainz, Germany

Conventional pulmonary function testing (PFT) is the non-invasive method of choice to follow-up patients after lung transplantation. PFTs do not, however, allow volumetry of defined lung regions, e.g., to assess the contribution of a single graft to total ventilated pulmonary volume. Recently, inhalation of laser-polarized <sup>3</sup>Helium has been shown to allow high-resolution magnetic resonance imaging of ventilated airspaces in the lungs (<sup>3</sup>HeMRI). We describe the utilization of this noninvasive technique for determination of ventilated volume of each single lung.

**Materials and Methods:** With Ethics Committee approval and informed consent, 8 healthy volunteers (age = 24-43 yrs) and 5 patients (age = 48-64 yrs) with idiopathic pulmonary fibrosis (IPF) after single-lung transplantation (SLTX) underwent PFTs and <sup>3</sup>He-MRI (1.5 T-MR scanner; breathhold imaging of a single breath of 260 ± 51 ml <sup>3</sup>He). Vital capacity (VC), functional residual capacity (FRC), and tidal volume (V<sub>T</sub>) were determined. Split-lung volume (<sup>3</sup>HeLV) was measured from three-dimensionally reconstructed <sup>3</sup>He lung images. Data are means ± SD; \* = p < .05 vs. healthy volunteers.

Results:	Healthy volunteers		SLTX-patients	
VC (% predicted)	106 ± 9		68 ± 12 *	
FRC+V <sub>T</sub> (ml)	3821 ± 976		2422 ± 73 *	
	Right lung	Left lung	Native lung	Graft
<sup>3</sup> HeLV (ml)	2121 ± 276	1967 ± 262	1238 ± 45	2256 ± 442
% of total <sup>3</sup> HeLV	52 ± 1	48 ± 1	34 ± 6 *	66 ± 6 *

In both healthy volunteers and patients, total <sup>3</sup>HeLV (both lungs) correlated with conventionally determined volume (FRC+V<sub>T</sub>), with R = 0.78 in volunteers, and R = 0.96 in patients with SLTX patients.

**Conclusions:** The new technique of <sup>3</sup>He-MRT allows image-based, non-invasive split-lung volumetry. Regional volumetry of smaller lung units is also feasible. Potential applications of this technique are the prediction of functional residual capacity after pulmonary resection, and follow-up monitoring after lung transplantation.

This study was supported by the German Research Society (DFG TH315/8)