

B25

Comparing Techniques of Resident Instruction in Fiberoptic Intubation John T. Denny, Lawrence Kushins, Asher Yama, Sharon Morgan and Burak Alptekin. Anesthesia and Critical Care, UMDNJ-Robert Wood Johnson Medical School, New Brunswick, NJ, United States.

INTRODUCTION:

ICU patients with difficult anatomy occasionally require fiberoptic intubation (FOI). Instruction in difficult airway management is an integral component of anesthesiology residency training. There exists a wide variability in curricula and methods of instruction in difficult airway management. (1) One essential difficult airway technique is mastering fiberoptic intubation. There is no clear best method for residents learning FOI. Some advocate learning in sedated, awake patients while others advocate residents learning in apneic patients following induction of general anesthesia. Learning FOI is often described as an anxiety producing event by residents. Excess anxiety is recognized as affecting concentration and learning. Therefore we studied which method of learning FOI produced higher resident ratings of their comfort level with learning FOI.

METHODS:

Residents in their CA-2 year learned FOI by two different techniques. In one technique, Monitored Anesthesia Care(=MAC), they performed FOI on awake patients sedated with midazolam and fentanyl. The other technique was FOI on apneic patients after the induction of general anesthesia. Following each attempt, residents rated their comfort with FOI on a scale of 1-10, with 1 being very comfortable and 10 being very uncomfortable.

RESULTS:

	MAC	Apneic
n attempts	25	27
Mean resident comfort rating	3.52	3.59

Data was analyzed using the students T-test. No significant difference was found between the two techniques, (p = 0.42).

DISCUSSION:

Our results indicated that residents reported no significant difference in comfort rating between learning FOI in sedated patients versus in apneic patients under general anesthesia. Previous work has addressed the difficulty of instructing residents in FOI. Novice anesthesia residents have successfully learned FOI in apneic patients under general anesthesia. (2) However, no studies exist comparing learning FOI in spontaneously breathing patients to learning in apneic patients. FOI may be more difficult to perform in apneic anesthetized patients due to airway collapse and obstruction in unconscious patients. (3) In addition, the time constraints imposed by apneic patients limit the duration of residents attempts. These factors imply that learning FOI in apneic patients may be more frustrating than in sedated, spontaneously breathing patients. The goal of our study was to better understand which approach leads to improved resident learning conditions. The mean resident comfort ratings were not significantly different between the two groups, indicating residents felt equally comfortable learning FOI in apneic patients as in sedated patients. The results suggest that residents are comfortable with learning FOI in apneic patients, despite the time constraints imposed by the technique.

REFERENCES:1.) Anesthesiology 1995; 83: 1343-6.

2.) Anesthesiology 1996; 84: 1101-6.

3.) Can J Anaesth 1994; 41:996-1008.

B26

TITLE: FAILURE OF PLATELET SURFACE EXPRESSION OF GP α II β III IN HUMAN TRAUMATIC INJURY AND HEMORRHAGIC SHOCK

AUTHORS: M.W. Russell, M.D., J. McComb

AFFILIATION: Dept. of Anesthesia, University of Pennsylvania, Philadelphia, PA 19104

Coagulopathy is commonly seen in patients during resuscitation from traumatic injury and hemorrhagic shock (T/HS). There is evidence to suggest that events associated with ischemia/re-perfusion, such as an increase in NO activity and the release of oxygen free radicals, may reduce the ability of platelets to mobilize and/or activate the fibrin(ogen) receptor, GP α II β III. The presence of activated α II β III can be measured using a monoclonal antibody (PAC-1, Becton-Dickenson, Inc.) to the active binding site conjugated to fluorescein isothiocyanate (FITC). Fluorescent activity of PAC-1 FITC labeled platelets can be measured using flow cytometry. We report the near total suppression in active GP α II β III receptor binding in a patient suffering severe T/HS.

MM suffered a massive injury following a high-speed motor vehicle accident. Clinical indices were consistent with severe T/HS. Blood was taken immediately post-operatively for comparison to two control subjects. Samples were incubated with PAC-1 FITC. RGDS, a peptide competitive inhibitor at the GP α II β III active site, was used to screen for platelet activation due to sampling technique. Samples were incubated thrombin receptor activating peptide (TRAP) in progressive concentrations. Figure 1 demonstrates 70 % suppression of PAC-1 binding presumably due to failure of activation or presentation of GP α II β III.

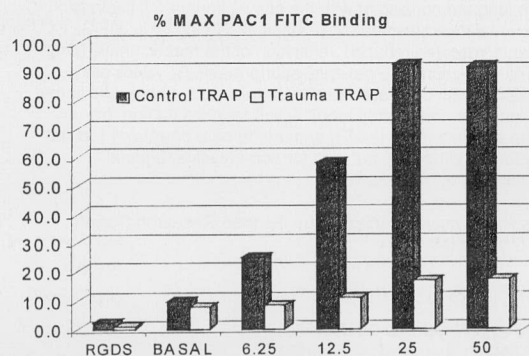


Figure 1. PAC1 binding in response to progressive agonist concentrations (x axis is micromoles)