

## Ventilator Alarm Failure Due to Modification of the Scavenging System

William C. Oliver, Jr., M.D.,\* John P. Abenstein, M.D.,\* Gregory A. Nuttall, M.D.\*

FAILURE and misuse of anesthetic administration equipment is a cause of death and brain damage associated with anesthesia.<sup>1</sup> However, failure of anesthesia systems is affected by human error in more than 80% of cases that result in critical events and patient injury.<sup>2</sup> These injuries may be prevented with a better understanding of anesthesia equipment and improved monitoring devices.<sup>3</sup> Recently, the potential for prolonged apnea in two ventilator-dependent patients occurred as a result of ventilator alarm failure caused by misuse of anesthesia equipment, which prompted this report.

### Case Reports

#### Case 1

A 4-month-old, 4.1-kg infant with ventricular and atrial septal defects was scheduled to undergo closure of both defects by means of cardiopulmonary bypass. After anesthetic induction, a 4.0-ID cuffed endotracheal tube was placed orally, and the child's lungs were mechanically ventilated with use of a Siemens Servo 900c ventilator (Siemens-Elementa AB, Solna, Sweden). Fresh gas flow to the ventilator was supplied by an Ohmeda Modulus II anesthesia machine (Ohmeda, Madison, WI). Ventilator settings included minute ventilation (MV) of 2.5 l, respiratory rate of 35 breaths/min, inspiratory time of 25%, inspiratory pause of 5%, and peak airway pressure of 20 cm H<sub>2</sub>O. The endotracheal tube was disconnected from the breathing system temporarily to position the infant on the operating table. Twenty seconds after disconnection, the lower expiratory MV alarm had not sounded as expected. The pulse oximeter continued to show 99% saturation. The lower MV expiratory alarm was set at 0.5 l. Although the child had been disconnected for approximately 60 s, both the needle gauge and the digital readout showed an MV of 2.0-2.5 l. The lungs were ventilated manually without significant desaturation. The expiratory MV value never decreased below 2 l.

#### Case 2

Ten days later, a 6-day-old, 3.1-kg, cyanotic infant with transposition of the great arteries was scheduled for anatomic correction. After anesthetic induction and treatment similar to that in case 1, a different Siemens servo 900c ventilator was set with an MV of 1.2 l, a respiratory rate of 30 breaths/min, an inspiratory time of 25%, and an inspiratory pause of 5%. As before, the infant was disconnected from the breathing

circuit to ensure safe positioning on the operating table. Again, the ventilator lower expiratory MV alarm did not sound, and both the needle gauge and the digital readout showed an expired MV of 1.0-1.5 l. The oxygen saturation measured by pulse oximetry (SpO<sub>2</sub>) was 85%.

With further investigation, it seemed that the problem was related to the use of the Ohmeda scavenging system, which was connected to both the Siemens Servo 900c ventilator and the Ohmeda Modulus II anesthesia machine ventilator (fig. 1). Waste gas from either ventilator enters the evacuation system at point A. Hospital suction is connected to point B, and an adjustable needle valve varies the suction flow from 0 to a maximum draw of 15 l/min. The positive-pressure relief valve vents waste gases into the room if the pressure in the scavenging interface reservoir bag exceeds 5 cm H<sub>2</sub>O. This occurs when waste gas flows exceed the adjusted evacuation flow rate. The positive-pressure relief valve prevents excessive airway pressure and possibly prevents cumulative gas trapping from being presented to the patient's lungs. The negative-pressure relief valve opens to allow room air into the evacuation system and then through the hospital suction system when pressure in the scavenging system is less than -0.5 cm H<sub>2</sub>O. This occurs when the scavenging system is adjusted to remove more gas volume/min than the anesthesia administration system is presenting to the scavenging system. The reservoir bag will collapse, generating negative pressure. The negative-pressure relief valve prevents significant negative pressure from being transmitted to the patient's lungs.

### Discussion

When the Siemens Servo 900c ventilator was used with an Ohmeda Modulus II anesthesia machine, to simplify the system, the Siemens evacuation component was removed, and the evacuation tubing of the Siemens Servo 900c was connected to point D of the Ohmeda scavenging system, and point CD was obstructed. With the Ohmeda scavenging system adjustment knob (fig. 1) open, the Ohmeda negative-pressure relief valve opens at -0.5 cm H<sub>2</sub>O. At this negative pressure, the scavenging system draws approximately 1.0-1.5 l/min room air into the Siemens Servo 900c ventilator through the expiratory limb. In an adult, a flow of 1.0-1.5 l/min would be inconsequential because the lower expiratory MV alarm would be set at 4-5 l. With the small MV of an infant, the lower expiratory MV alarm is not activated. The expired MV never reaches a value of 0 l/min, even with the endotracheal tube disconnected from the breathing system.

A solution to this problem is the attachment of a long reservoir tube, open to room air, to an additional arm of the intake port of the Ohmeda closed-reservoir scavenging interface point C. This effectively modifies the scavenging system into an open system, and neither positive nor negative pressure is possible within the scavenging apparatus. It eliminates the negative-pressure-generated

\* Assistant Professor of Anesthesiology, Department of Anesthesiology.

Received from the Mayo Clinic and Mayo Foundation, Rochester, Minnesota. Submitted for publication December 22, 1999. Accepted for publication May 18, 2000. Support was provided solely from institutional and/or departmental sources.

Address reprint requests to Dr. Oliver: Mayo Clinic, 200 First Street, SW, Rochester, Minnesota 55905. Address electronic mail to: oliver.william@mayo.edu. Individual article reprints may be purchased through the Journal Web site, www.anesthesiology.org.

Key words: Anesthesia equipment; critical events.

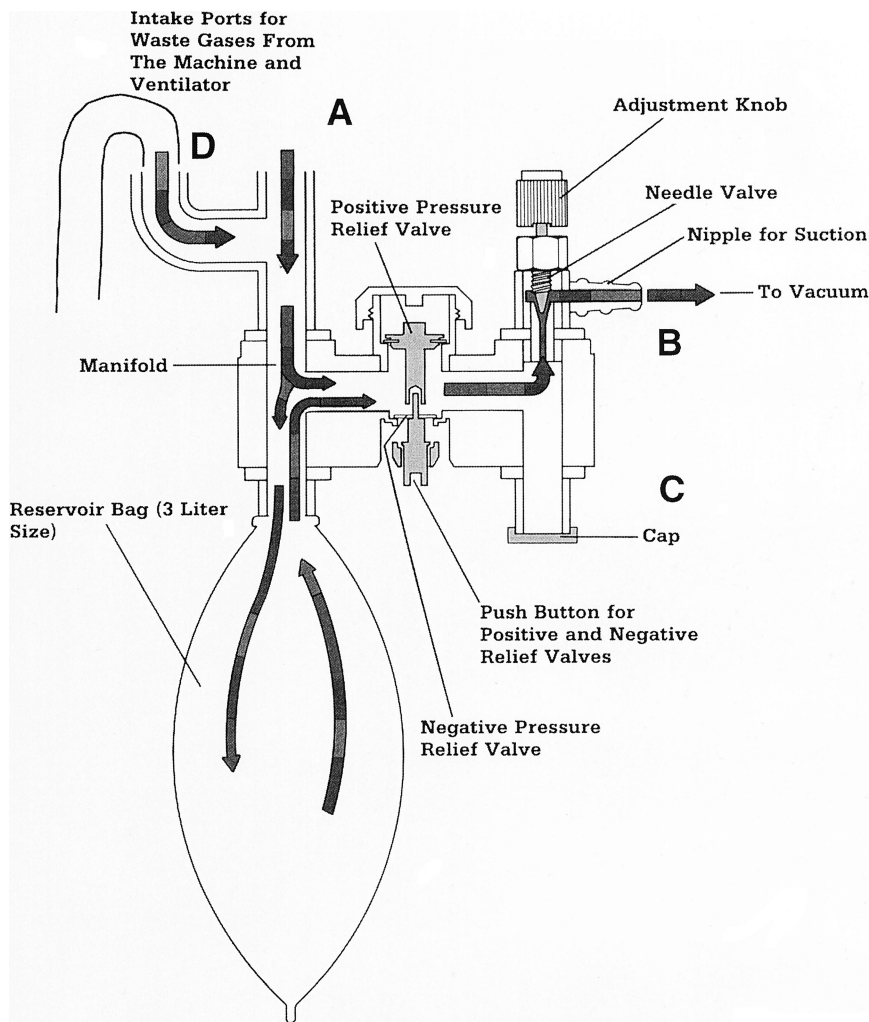


Fig. 1. The flow of waste gases through the interface manifold of a gas scavenging system that is connected to the vacuum source. (Reprinted with permission from Bowie E, Huffman LM: *The Anesthesia Machine: Essentials for Understanding*. Madison, Datex-Ohmeda, 1985.)

flow through the expiratory system of the Siemens Servo 900c ventilator. If the reservoir tube total volume exceeds 3 l, the same as the volume of the reservoir bag, it vents waste gas into the operating room to the same degree as the unmodified semiclosed Ohmeda scavenging system.

In conclusion, this report shows the potential consequences of user error and use of anesthesia equipment. Inadequate knowledge of anesthesia equipment and ventilators may compromise important monitoring devices and alarms, placing patients at increased risk for complications and death.

The authors thank Gerald J. Rach, Supervisor, Biomedical Department/Anesthesia Maintenance, Mayo Clinic and Foundation, Rochester, Minnesota, for technical expertise in anesthesia equipment in the preparation of this manuscript.

## References

1. Caplan RA, Vistica MF, Posner KL, Cheney FW: Adverse anesthetic outcomes arising from gas delivery equipment: A closed claims analysis. *ANESTHESIOLOGY* 1997; 87:741-8
2. Williamson JA, Webb RK, Sellen A, Runciman WB, Van Der Walt JH: Human failure: An analysis of 2000 incident reports. *Anaesth Intens Care* 1993; 21:678-83
3. Caplan RA, Posner KL, Ward RJ, Cheney FW: Adverse respiratory events in anesthesia: A closed claims analysis. *ANESTHESIOLOGY* 1990; 72:828-33

## Acute Thrombosis of the External Iliac Artery after a Short Procedure in the High Lithotomy Position

Thomas Geeraerts, M.D.,\* Pierre Albaladejo, M.D.,† Stéphane Droupy, M.D.,‡ Pascal Blanchet, M.D.,§  
Alain Le Baleur, M.D.,|| Dan Benhamou, M.D.#

COMPLICATIONS of the lithotomy position are well-known and include lower extremity compartment syndrome, peroneal nerve dysfunction, femoral neuropathy, and deep vein thrombosis.<sup>1</sup> The main risk factor for such complications is duration of surgery longer than 4 h. These complications may be explained by direct nervous or muscular compression or by decreased arterial and venous blood flow in the lower extremities.

We describe a case of acute arterial ischemia occurring after brief urologic surgery in the lithotomy position in a patient presenting with a severe lower limb arteritis. To our knowledge, only one previous case of lower extremity arterial thrombosis has been reported (Canterbury *et al.*<sup>2</sup>).

### Case Report

A 46-yr-old man with American Society of Anesthesiologists physical status III was scheduled to undergo transurethral resection of a bladder tumor. The patient had several cardiovascular risk factors: active smoking, hypercholesterolemia, diabetes mellitus, and hypertension. He had a clinical history of severe arteritis (bilateral calf pain after 300 m walking). Arterial ultrasonography performed 6 months before surgery showed patent iliac vessels, several femoropopliteal stenoses, occlusion of the right superficial femoral artery, and severe distal atherosclerosis. He was in sinus rhythm. His medical treatment included verapamil, taken until the day of surgery, and aspirin, which was discontinued 15 days before surgery.

Bladder transurethral resection was performed with general anesthesia with the patient in the high lithotomy position. Anesthesia was induced with propofol and sufentanil and maintained with desflurane and nitrous oxide. A laryngeal mask airway was placed. Blood pressure was measured from the right arm with use of an oscillometric method. Systolic blood pressure was higher than 110 mmHg during the entire procedure. No vasoconstrictor drugs were used. No arrhythmia occurred. Because the tumor was located near the right ureteral ostium, the right obturator nerve was stimulated four times during the procedure, resulting in transient contractions of the right adductor muscles. The patient was kept in the high lithotomy position for 50 min. Emergence from anesthesia was uneventful. After arrival in the recovery room, the patient reported right calf pain. The right foot and leg were pale and cold, with sensory and motor dysfunction; right pedal

and popliteal pulses were absent. The calf showed no muscular tension. Pulse rate was regular at 55 beats/min, arterial blood pressure was 130/70 mmHg, and electrocardiography showed no changes as compared with preoperative electrocardiography. Acute arterial ischemia was confirmed by acoustic ultrasonography. Arteriography was performed immediately and showed thrombosis of the initial part of the right external iliac artery and severe distal arteritis with developed collateral branches. Doppler ultrasonographic examination showed normal venous blood flow and no evidence of deep vein thrombosis. Intravenous ilomedin (prostacyclin analog) and heparin were administered. This treatment was followed by an improvement in motor function and cutaneous temperature. Nevertheless, subacute ischemic and sensory disorders were still present. Iliofemoral bypass and lumbar sympathectomy were performed successfully 2 days later. Intravenous ilomedin and heparin were infused postoperatively. The patient was discharged from the hospital after regaining normal motor and sensory functions of the right leg.

### Discussion

We have described a complication of the high (but not exaggerated) lithotomy position in a short urologic procedure. Neurologic, venous, and muscular complications have been described extensively, usually in patients kept in the lithotomy position for more than 4 h. These complications usually are explained by local compression, distortion of nervous or vascular elements by exaggerated flexion of the thighs, and decrease in perfusion pressure in the lower extremities.

In the current case, several factors may have contributed to acute arterial ischemia. First, the patient had atherosclerotic disease. As shown by Halliwill *et al.*,<sup>3</sup> the lithotomy position decreases lower extremity perfusion pressure in young, healthy volunteers. Canterbury *et al.*<sup>2</sup> described a case of lower extremity arterial thrombosis after a 40-min surgery with the patient in the lithotomy position, explained by popliteal vessel angulation. In their study of 100 patients, they showed that the ankle-arm index (ankle/arm systolic blood pressure ratio) decreased significantly immediately after placing the lower extremities in the lithotomy position and remained abnormal throughout surgery. The decrease in blood flow was more pronounced in patients with arterial calcifications. We can suppose reasonably that severe hypoperfusion of the lower extremities occurred in our patient and was not detected because blood pressure measured at the brachial artery remained in the normal range. Because the patient probably had an abnormal systolic blood flow, the lithotomy position may have critically

\* Resident, † Staff Anesthesiologist, # Chairman, Professor of Anesthesiology, Department of Anesthesiology, ‡ Associate Professor, § Staff Surgeon, Department of Urology, || Staff Surgeon, Department of Surgery.

Received from the Hôpital de Bicêtre, le Kremlin-Bicêtre, France. Submitted for publication April 11, 2000. Accepted for publication May 23, 2000. Support was provided solely from institutional and/or departmental sources.

Address reprint requests to Dr. Albaladejo: Department of Anesthesiology, Hôpital de Bicêtre, 94275 Le Kremlin Bicêtre, France. Address electronic mail to: darkb@imagin.fr. Individual article reprints may be purchased through the Journal Web site, www.anesthesiology.org.

Key words: Acetylsalicylic acid; complication; surgery.

decreased blood flow in the lower extremities and possibly contributed to the constitution of arterial thrombosis.

Several studies have shown that the femoral nerve and vessels can be distorted in the lithotomy position. Hopper *et al.*<sup>4</sup> provided anatomic explanations for femoral neuropathy after a procedure in the lithotomy position. In cadaver studies, flexing, abducting, and externally rotating thighs have been shown to angulate (80–90°) the femoral nerve and vessels.<sup>5,6</sup> In a study of 177 cases in which the exaggerated lithotomy position was used, Angermeier *et al.*<sup>1</sup> described four thromboembolic complications that were possibly caused by venous compression. Nilsson *et al.*<sup>7</sup> found that filling the bladder with irrigation fluid with the patient in the lithotomy position resulted in echographic signs of iliac venous obstruction. In the case reported herein, all these mechanical factors may explain a decrease in blood flow in a compressed iliac artery. Another hypothesis is the possibility of an atherosclerotic plaque rupture caused by angulation and compression of the artery. Transient contractions of adductors during bladder resection by obturator nerve stimulation also may have contributed to a plaque rupture. This hypothesis is supported by the finding that the complication occurred during a short surgical procedure.

The recent discontinuation of acetylsalicylic acid before surgery may have facilitated the occurrence of arterial thrombosis. Experimental studies<sup>8</sup> have shown that

fibrin gel porosity may be increased after discontinuation of antiplatelet drugs and may explain accelerated thrombosis in patients with coronary artery disease. Beving *et al.*<sup>9</sup> demonstrated that high levels of arachidonic acid metabolite are produced by platelets 1 to 2 weeks after discontinuation of acetylsalicylic acid. This abnormally high platelet activity after discontinuation of acetylsalicylic acid might increase the risk of thrombosis.

## References

1. Angermeier KW, Jordan GH: Complications of the exaggerated lithotomy position: A review of 177 cases. *J Urol* 1994; 151:866–8
2. Canterbury TD, Wheeler WE, Scott-Conner CE: Effects of the lithotomy position on arterial blood flow in the lower extremities. *W V Med J* 1992; 88:100–1
3. Halliwill JR, Hewitt SA, Joyner MJ, Warner MA: Effect of various lithotomy positions on lower-extremity blood pressure. *ANESTHESIOLOGY* 1998; 89:1373–6
4. Hopper CL, Baker JB: Bilateral femoral neuropathy complicating vaginal hysterectomy: Analysis of contributing factors in 3 patients. *Obstet Gynecol* 1968; 32:543–7
5. Hakim M, Katirji B: Femoral mononeuropathy induced by the lithotomy position: A report of 5 cases with a review of literature. *Muscle Nerve* 1993; 16:891–5
6. Katirji MB, Lanska DJ: Femoral mononeuropathy after radical prostatectomy. *Urology* 1990; 36:539–40
7. Nilsson A, Jogestrand T, Ekengren J, Hahn RG: Femoral vein blood flow during transurethral resection of the prostate. *Br J Urol* 1996; 77:207–11
8. Fatah K, Beving H, Albage A, Ivert T, Blombäck M: Acetylsalicylic acid may protect the patient by increasing fibrin gel porosity: Is withdrawing of treatment harmful to the patient? *Eur Heart J* 1996; 17:1362–6
9. Beving H, Zhao C, Albage A, Ivert T: Abnormally high platelet activity after discontinuation of acetylsalicylic acid treatment. *Blood Coagul Fibrinolysis* 1996; 7:80–4

Anesthesiology 2000; 93:1354–5

© 2000 American Society of Anesthesiologists, Inc. Lippincott Williams & Wilkins, Inc.

## Acute Subdural Hematoma following Spinal Anesthesia with a Very Small Spinal Needle

Emmanuel Cantais, M.D.,\* Dan Behnamou, Ph.D.,† Dominique Petit, M.D.,\* Bruno Palmier, Ph.D.‡

INTRACRANIAL subdural hematoma is a rare but potentially fatal complication of dural puncture after spinal anesthesia or accidental puncture with a Tuohy needle. The leakage of cerebrospinal fluid may lower intracranial pressure, and caudal movement of the spinal cord and brain stretches and tears dural veins, resulting in subdural bleeding. Cerebrospinal fluid leakage more often causes postdural puncture headache (PDPH), of which the incidence and severity correlate well with the needle

size and tip design. Using the smallest possible spinal pencil-point needles is recommended to minimize these complications. The purpose of this article is to report a case of fatal subdural hematoma after spinal anesthesia with a 27-gauge Whitacre needle.

### Case Report

A 42-yr-old man, who was healthy except for long-standing asthma treated with inhaled salbutamol, underwent uneventful anesthesia using a 27-gauge needle for surgical management of an Achilles tendon rupture. He had no history of trauma, headache, or coagulation abnormalities. Preoperative laboratory blood tests, including platelet count, prothrombin time, and activated prothromboplastin time, yielded normal results. Because of the asthma, a regional anesthetic technique was chosen. Spinal anesthesia, performed at the L3–L4 interspace using a 27-gauge Whitacre needle, was successful on the first attempt. The intraoperative course was uneventful except for a moderate decrease in blood pressure (from 140 mmHg to 110 mmHg for systolic blood pressure), which necessitated no treatment. The leg was placed in a plaster cast at the end of surgery.

Postoperative medication consisted of paracetamol (2 g three times

\* Staff Anesthesiologist, ‡ Professor, Service de Réanimation, Hôpital d'Instruction des Armées Sainte Anne. † Professor, Département d'Anesthésie Réanimation and Regional Anesthesia Hot Line, Hôpitaux de Bicêtre et de Bécélère-Université Paris Sud, Kremlin-Bicêtre, France.

Received from the Military Teaching Hospital, Intensive Care Unit, Hôpital d'Instruction des Armées Sainte Anne, Toulon-Naval, France. Submitted for publication March 7, 2000. Accepted for publication June 12, 2000. Support was provided solely from institutional and/or departmental sources.

Address reprint requests to Dr. Cantais: HIA Sainte Anne, Bvd Ste Anne, Service de Réanimation, 83800 Toulon-Naval, France. Address electronic mail to: cantais.emmanuel@wanadoo.fr. Individual article reprints may be purchased through the Journal Web site, www.anesthesiology.org.

Key words: Low-molecular-weight heparin; postdural headache; spinal needle.

a day) and enoxaparin (40 mg subcutaneously daily). The patient experienced a generalized headache 2 h later, which was particularly severe in the occipital area. It was interpreted as a PDPH because it was more intense while seated. The patient declined autologous epidural blood patch, proposed by the anesthesiologist. Treatment for the next 3 days consisted of an increase in fluid intake (2,500 ml/day) and bed rest in the supine position. The headache improved and the patient was discharged on day 4. Thromboprophylaxis was continued.

On the ninth postoperative day, the patient contacted the anesthesiologist because of a severe headache, both in the upright and in the recumbent position. The physician advised hospital admission, but this was declined by the patient. The next day, the headache decreased in severity and was localized to the frontotemporal region. The patient became sleepy and vomited, as his family reported later. He became comatose on the afternoon of the same day. An endotracheal tube was inserted, and he was transported to our hospital.

At admission, the patient was comatose, with the left pupil dilated and minimally reactive, presenting with right hemiparesis. Both plantar responses were in extension. Transcranial Doppler ultrasonography indicated increased intracranial pressure, with very low diastolic velocity in the middle cerebral artery because blood pressure was increased. A computed tomographic scan showed a 2-cm-thick acute left subdural hematoma. Left temporal craniotomy was performed immediately (52 min after admission) to remove this recent and homogeneous hematoma. No bleeding point was identified. Postoperatively, the patient remained comatose and decerebrate. Angiography ruled out the presence of a vascular malformation, and magnetic nuclear resonance imaging showed important mesencephalic and thalamic lesions. The patient died 2 days later (on the twelfth postoperative day).

## Discussion

Acute intracranial subdural hematoma is a rare but potentially lethal complication that can occur after spinal anesthesia, epidural anesthesia, or myelography.<sup>1-3</sup> The needles used ranged in size from 16 to 25 gauge. Five deaths have been recorded. The same pathogenic mechanism has been postulated for PDPH and subdural hematoma.<sup>4</sup> Cerebrospinal fluid leakage from the dural hole reduces cerebrospinal fluid volume. The reduced intracranial pressure allows the brain to move caudally with stretching of the dural veins. This produces pain. Vasodilatation of intracranial vessels also may contribute to pain. The needle hole in the dura can remain open for many weeks. PDPH is a relatively common complication, whereas subdural hematoma is rare. In these more serious cases, cortical veins are stretched and torn, which results in subdural bleeding. In some cases, the source of bleeding is identified by the neurosurgeon (small artery in subarachnoid tissue or cortical veins). Small-size needles with a pencil-point tip are known to produce the lowest incidence and severity of postspinal headache.<sup>5</sup> One does not expect an easy dural puncture with use of a 27-gauge Whitacre needle to produce a tear sufficiently large to create cerebrospinal fluid loss and subdural hematoma. One important clinical feature of PDPH is its relation with position. Headache becomes more severe when the patient is in the upright position, and it is relieved by lying down. Very few other diseases can display posturodependent headache (cerebral thrombophlebitis,<sup>6</sup> incipient eclampsia,<sup>7</sup> meningitis,<sup>8</sup> and oth-

ers), and, thus, position-related headache is almost synonymous with PDPH. Diagnosis of PDPH probably should be excluded when the relation with position is not found. When a posturodependent headache after a dural tap becomes permanent and loses its relation with position, a subdural hematoma should be sought urgently with computed tomography. In the case presented herein, on the ninth postoperative day, the nature of the headache changed and became unrelated to position. The patient declined hospital admission, which might have avoided a fatal outcome.

The development of cerebral subdural hematoma might have been a spontaneous event related to the administration of low-molecular-weight heparin (LMWH), used to prevent deep vein thrombosis in a patient with a plaster cast.<sup>9</sup> Although spontaneous hematoma may occur in patients treated with anticoagulants, recent literature has emphasized the deleterious role of LMWH in producing spinal or epidural subdural hematoma. In the current case, the patient was administered a prophylactic dose of LMWH which is considered adequate.<sup>10</sup> Platelet count and coagulation profile (prothrombin time and activated prothromboplastin time) were normal at admission to the intensive care unit, as expected with LMWH. This indicates either that anticoagulant administration should be discontinued when PDPH occurs or that assessment of headache characteristics (its relation with position particularly) should be performed with increased frequency in anticoagulated patients.

To avoid a potential negative outcome, regular follow-up of patients with headache after neuraxial block helps delineate between a typical PDPH and a nonpositional headache, the latter necessitating more aggressive attention, particularly in a patient with another risk factor of bleeding, such as LMWH treatment.

## References

1. Bjärhall M, Ekseth K, Boström S, Vegfors M: Intracranial subdural haematoma: A rare complication following spinal anaesthesia. *Acta Anaesthesiol Scand* 1996; 40:1249-51
2. Cohen JE, Godes J, Morales B: Postpartum bilateral subdural hematoma following spinal anesthesia: Case report. *Surg Neurol* 1997; 47:6-8
3. Vos PE, Boer WAD, Wurzer JA, Gijn JV: Subdural hematoma after lumbar puncture: Two case reports and review of the literature. *Clin Neurol Neurosurg* 1991; 93:127-32
4. Macon ME, Armstrong L, Brown EM: Subdural hematoma following spinal anesthesia. *ANESTHESIOLOGY* 1990; 72:380-1
5. Halpern S, Preston R: Postdural puncture headache and spinal needle design: Metaanalyses. *ANESTHESIOLOGY* 1994; 81:1376-83
6. Borum SE, Naul LG, McLeskey CH: Postpartum dural venous sinus thrombosis after postdural puncture headache and epidural blood patch. *ANESTHESIOLOGY* 1997; 86:487-90
7. Ariola SE, Russo TO, Marx GF: Postdural puncture headache or incipient eclampsia? *Int J Obstet Anesth* 1991; 1:33-4
8. Sansome AJT, Barnes GR, Barrett RF: An unusual presentation of meningitis as a consequence of inadvertent dural puncture. *Int J Obstet Anesth* 1991; 1:35-7
9. Kock HJ, Schmit-Neuerburg KP, Hanke J, Rudovsky G, Hirche H: Thromboprophylaxis with low-molecular weight heparin in outpatients with plaster-cast immobilisation of the leg. *Lancet* 1995; 346:459-61
10. Tryba M, Wedel DJ: Central neuraxial block and low molecular weight heparin (enoxaparine): Lessons learned from different dosage regimens in two continents. *Acta Anaesthesiol Scand Suppl* 1997; 111:100-4

## Intraoperative Hemodialysis during Emergency Laparotomy

James R. Cooper, B.S.N.,\* Stephen B. Kurtz, M.D.,† Mark D. Sawyer, M.D.,‡ Bradly J. Narr, M.D.§

MANY patients with advanced organ system dysfunction present for anesthesia and surgery. The incidence of renal failure that requires dialysis has increased dramatically in the past decade.<sup>1</sup> We describe two cases in which intraoperative hemodialysis was performed for refractory hyperkalemia.

### Case Reports

#### Case 1

A 61-yr-old man had a history of aortic and mitral valve replacement, chronic renal insufficiency (baseline creatinine level 2.2 mg/dl), ascites, and a known umbilical hernia. Long-term medications included furosemide, aldactone, digoxin, warfarin, and losartan. He presented with fever, emesis, and painful bulging of the hernia defect. A presumptive diagnosis of strangulated umbilical hernia was made. Initial laboratory evaluation showed a potassium ( $K^+$ ) concentration of 7.6 mEq/l. Intravenous administration of 50 ml dextrose, 50%, 10 U regular insulin, and 1 g calcium chloride were followed by a repeat  $K^+$  of 6.8 mEq/l. In addition, blood urea nitrogen level was 86 mg/dl (baseline 53), creatine level was 2.6 mg/dl, glucose level was 134 mg/dl, and arterial blood gases with room air showed an arterial oxygen tension ( $P_{aO_2}$ ) of 89 mmHg, an arterial carbon dioxide tension ( $P_{aCO_2}$ ) of 37 mmHg,  $HCO_3^-$  of 22 mEq/l, and a pH 7.39. An electrocardiogram showed sinus bradycardia with left bundle-branch block and was unchanged from 3 months before. He received 4 units fresh frozen plasma to reverse chronic anticoagulation.

He arrived in the operating room with a pulse of 85 beats/min, a blood pressure of 140/70 mmHg, and a respiratory rate of 18 breaths/min. A right internal jugular dialysis catheter (Mahurkar 11.5-French dual lumen; Sherwood Medical Company, St. Louis, MO) and an arterial catheter were placed while the patient was awake. All intravenous infusions were normal saline. A modified rapid sequence induction was performed, and, 15 min later, dialysis was begun.  $K^+$  concentration at that time was 6.5 mEq/l. His pulse rate gradually decreased during the first hour of hemodialysis to 50 beats/min, and his blood pressure remained stable at 120-145/55-75 mmHg throughout the procedure. The hernia sac was dissected, and, after incision of the surrounding fascia, the bowel that had looked ischemic regained viability. More than 2 l ascites were removed from the abdomen, and the hernia was repaired. He was given 2 more units fresh frozen plasma and a total of 1,250 ml normal saline during 2 h anesthesia. Muscle relaxant was reversed, and the patient was extubated while dialysis continued. He underwent dialysis for a total of 1 h and 45 min against a dialysate with

a  $K^+$  concentration of 1 mEq/l. No fluid was removed during hemodialysis. Urine production was negligible. When transferred to the intensive care unit, he was breathing spontaneously, alert, and oriented, with a  $K^+$  concentration of 5.0 mEq/l. Five h postoperatively, arterial blood gases showed a partial pressure of oxygen ( $P_{O_2}$ ) of 132, a partial pressure of carbon dioxide ( $P_{CO_2}$ ) of 46, a pH of 7.36, and 25 mEq/l  $HCO_3^-$  on 3 l oxygen/min administered *via* nasal cannulae. Aldactone was held postoperatively for 3 days. He produced 350 ml urine during the first 12 h after the procedure, and urine flow continued to be adequate. No further dialysis was performed during his hospital stay. At discharge, creatinine concentration was 1.9 mg/dl, and  $K^+$  concentration was 4.5 mEq/l. His usual medical regimen was restarted, and he has continued to do well.

#### Case 2

A 29-yr-old woman with an 18-yr history of insulin-dependent diabetes was involved in an automobile collision while driving to a dialysis center for her triweekly hemodialysis treatment. At admission to the emergency room, the patient was conscious, oriented, and reporting severe abdominal pain. Abdominal computed tomography showed diffuse fluid throughout the retroperitoneum and air within the mesentery. A diagnosis of small bowel rupture was considered. Arterial blood gas evaluation showed a hemoglobin concentration of 8.7 g/dl (baseline 10.3 g/dl 1 week previously), a sodium ( $Na^+$ ) concentration of 133 mEq/l, a  $K^+$  concentration of 6.9 mEq/l (baseline 3.9 mEq/l week previously), a glucose concentration of 278 mg/dl, a  $P_{aO_2}$  of 129 mmHg, a  $P_{aCO_2}$  of 42, and a pH of 7.37. She had an arteriovenous fistula for chronic hemodialysis in the right arm. She was administered intravenous insulin and prepared for arrival to the operating room.

At arrival in the operating room, her pulse was 105 beats/min, with a blood pressure of 124/72 mmHg. Electrolytes obtained just before incision showed a  $Na^+$  concentration of 131, a  $K^+$  concentration of 5.4 mEq/l, a glucose concentration of 111 mg/dl, and an ionized calcium ( $Ca^{2+}$ ) concentration of 3.88 mg/dl. Calcium chloride 500 mg, was administered intravenously. Hemodialysis was initiated 30 min after induction, using the existing right arteriovenous fistula. Vital signs were stable, with a gradual decrease in pulse rate to 75 beats/min and blood pressures of 100-120/60-75 mmHg. During 2½ h dialysis she underwent transfusion of 2 units packed red cells *via* the dialysis machine, and no fluid was removed. Laboratory tests after dialysis revealed a  $K^+$  concentration of 3.3 mEq/l, a glucose concentration of 138 mg/dl, and a  $Ca^{2+}$  concentration of 4.3 mg/dl. The duodenal perforation was repaired, and the patient was taken to the intensive care unit. She was extubated 12 h later and had hemodialysis every 24 h for the next 3 days to remove fluid. Her recovery was otherwise uneventful.

\* Student Nurse Anesthetist, Mayo School of Health-Related Sciences, † Associate Professor of Medicine, Division of Hypertension and Nephrology, ‡ Assistant Professor of Surgery, Department of Surgery, § Assistant Professor of Anesthesiology, Department of Anesthesiology.

Received from the Mayo Clinic, Rochester, Minnesota. Submitted for publication January 31, 2000. Accepted for publication June 15, 2000. Support was provided solely by the Mayo Foundation, Department of Anesthesiology.

Address reprint requests to Dr. Narr: Mayo Clinic/Mayo Foundation, 200 First Street SW, Rochester, Minnesota 55905. Address electronic mail to: narr.bradly@mayo.edu. Individual article reprints may be purchased through the Journal Web site, www.anesthesiology.org.

Key words: Dialysis; hyperkalemia.

longer necessitate systemic anticoagulation, and new dialysis membranes are well-tolerated hemodynamically and cause minimal systemic disturbance. If appropriate equipment and personnel can be mobilized, intraoperative dialysis is not an anesthetic challenge. Some intravascular volume will be lost when blood replaces the priming fluid in the dialyzer, but this has minimal effects. Our impression was that immediate surgical intervention with perioperative dialysis during the procedures was in the patient's best interest. We have continuous coverage in our hospital for emergency dialysis by a nephrology team that was available for intraoperative care.

Indications for intraoperative hemodialysis should be limited to severe electrolyte abnormalities and some types of volume overload. In patients with no renal function in whom immediate surgical intervention is necessary, ultrafiltration can be used to remove fluid without dialysis. However, vasodilators, ventilatory assistance with positive end-expiratory pressure, and inotropic support are more common treatments. Hemodynamically unstable patients with ongoing blood loss may not tolerate dialysis. Patients who have surgical diagnoses that allow for preoperative optimization should be treated medically or should undergo dialysis in a more traditional environment.

Hyperkalemia is a life-threatening disorder. Medical interventions to shift  $K^+$  into cells (hyperventilation, intravenous sodium bicarbonate, glucose, and insulin infusion) that mitigate the effect of hyperkalemia on electrically excitable tissues (intravenous calcium) or removal of  $K^+$  from the body (cation exchange resins *via* the gut or dialysis) are treatment options. As these cases show, we used several of these treatments. Hemodialysis is an efficient mechanism for treating hyperkalemia.<sup>2</sup> A case has been reported in which severe hyperkalemia occurred after transfusion in a patient with end-stage renal disease. He underwent dialysis intraopera-

tively to correct the electrolyte abnormality.<sup>3</sup> Our patients were hemodynamically stable, without active hemorrhage. We could not use the gut for cation exchange resins, and they both had the potential for further exacerbation of  $K^+$  homeostasis. To correct hyperkalemia in this setting, we chose hemodialysis.

Hemodialysis is the most efficient means of decreasing serum  $K^+$ , with the bulk of the loss occurring during the first hour. The normal dialysate consists of an  $Na^+$  concentration of 140 mEq/l and a  $K^+$  content ranging from 0 to 4 mEq/l. Because hemodialysis can rapidly decrease  $K^+$  levels, hypokalemia can become a concern. Holter studies indicate that patients whose  $K^+$  levels decrease to below 3.5 mEq/l and who have left ventricular hypertrophy or are prescribed digoxin are at risk for ventricular arrhythmias. Patients other than these have undergone dialysis to lower serum  $K^+$  levels without adverse consequences.<sup>4</sup>

Intraoperative hemodialysis can be used to treat severe hyperkalemia and allow simultaneous surgical intervention. This has the potential to improve patient outcome when ischemia of bowel can be reversed or peritoneal contamination can be limited by rapid surgical intervention. By choosing to use dialysis intraoperatively, we prevented further increases in serum  $K^+$  levels and the complications that potentially accompany it. Hemodynamically stable patients can undergo dialysis safely during general anesthesia.

## References

1. HICFA Data. Incidence and prevalence of ESRD: United States renal data. *Am J Kid Dis* 1999; 34(suppl 1):s40-50
2. Hou S, McElroy PA, Nootens J, Beach M: Safety and efficacy of low potassium dialysate. *Am J Kid Dis* 1989; 13:137-43
3. Tek E, Sekerci S, Arslan G: Intraoperative hemodialysis during emergency intracranial surgery. *Anesth Analg* 1996; 83:658-9
4. Morrison G, Michelson EL, Brown S, Morganroth J: Mechanism and prevention of cardiac arrhythmias in chronic hemodialysis patients. *Kid Int* 1980; 17:811-9

Anesthesiology 2000; 93:1357-9

© 2000 American Society of Anesthesiologists, Inc. Lippincott Williams & Wilkins, Inc.

## Seizure-like Activity on Emergence from Sevoflurane Anesthesia

Cheryl A. Hilty, M.D.,\* John C. Drummond, M.D., F.R.C.P.C.†

\* Resident, Department of Anesthesiology, University of California, † Professor and Chair, Department of Anesthesiology, University of California; and Staff Anesthesiologist, Veterans Affairs Medical Center.

Received from the Department of Anesthesiology, the University of California, San Diego, California, and the Veterans Affairs Medical Center, La Jolla, California. Submitted for publication March 20, 2000. Accepted for publication June 15, 2000. Support was provided solely from institutional and/or departmental sources.

Address reprint requests to Dr. Drummond: UCSD Medical Center, Department of Anesthesiology, 200 W. Arbor Drive, # 8812, San Diego, California 92103-8812. Address electronic mail to: jdrummond@ucsd.edu. Individual article reprints may be purchased through the Journal Web site, www.anesthesiology.org.

Key words: Complications; epileptogenesis.

THERE are indications that sevoflurane may be epileptogenic in some circumstances.<sup>1-7</sup> There have been several reports of epileptiform electroencephalographic activity in adults and children and occasional reports of grand mal convulsions in children. However, there has been only one report of a grand mal-type seizure occurring in an adult, and the frequency of such events and the predisposing circumstances, if any, are undefined. We present the case of a 19-yr-old man with no seizure history who, during two consecutive emergences from general anesthesia with sevoflurane, experienced tonic-clonic motor activity consistent with grand mal convulsions.

Downloaded from http://ajph.aphspublishers.org/ by guest on 29 May 2023

## Case Report

A 19-yr-old man presented for left-sided radical orchiectomy. History was significant for methamphetamine use by inhalation. He was taking no medications and asserted no drug use in the preceding three weeks. There was no personal or family history of seizures or other neurologic disorders. Hemoglobin, electrolytes, and plasma glucose values were normal.

Midazolam, 1 mg, was administered before induction. Preoxygenation was performed with use of a semiclosed anesthesia circuit and a tightly applied mask. Induction of anesthesia was accomplished uneventfully by introducing 8% sevoflurane, in 50% nitrous oxide, with oxygen at a fresh gas flow of 10 l/min. Anesthesia was maintained with 50% nitrous oxide and 2% sevoflurane (dial setting) by mask. The patient breathed spontaneously. Respiratory rate was initially 28 breaths/min, with an end-tidal carbon dioxide concentration of 22–24 mmHg. Fentanyl, 100  $\mu$ g, was administered in 25- $\mu$ g increments. Respiratory rate decreased to 14 breaths/min and end-tidal carbon dioxide increased to 31–33 mm Hg. Blood loss was 400 ml. Lactated Ringer's solution, 1 l, and 500 cc hetastarch were administered. The patient remained hemodynamically stable, with a blood pressure of 100–115/60–74 mmHg and a pulse rate of 85–100 beats/min throughout the 90-min procedure.

After wound closure, sevoflurane and nitrous oxide were discontinued. Oxygen administration continued at 8 l/min. Approximately 2½ min later, rhythmic jerking movements began in the legs and spread quickly to the remainder of the body. The movements were accompanied by an arched back and a stiff neck and jaw. Effective respiration ceased. Oxygen saturation measured by pulse oximetry (SpO<sub>2</sub>) decreased to the mid 80s (%), and the capnograph showed no expired carbon dioxide. To facilitate ventilation *via* mask, sevoflurane was reintroduced at a dial setting of 8%. The tonic-clonic activity ceased within 30 s, and effective manual ventilation was achieved immediately. SpO<sub>2</sub> returned to normal rapidly, and the total duration of SpO<sub>2</sub> less than 90% was less than 2 min. The patient resumed spontaneous ventilation immediately. Approximately 3 min thereafter, sevoflurane administration was discontinued again. Within 2 min, an essentially identical occurrence of tonic-clonic activity ensued. Midazolam, 1 mg, and propofol, 30 mg, were administered, and the apparent seizure activity abated promptly. Mask ventilation with oxygen was reinstated, and spontaneous ventilation again resumed quickly. Diazepam, 5 mg, was administered. During the next 10 min, the patient awakened but was disoriented.

Neurologic consultation was obtained, and diphenylhydantoin was administered. Serum toxicology screening yielded negative results for stimulant-type drugs. Computed tomography and magnetic resonance imaging scans showed a lesion in the left posterior cortex that was suspicious for ganglioneuroma (a benign tumor of mixed neuronal and glial origin). Encephalomalacia, secondary to trauma and cysticercosis, were offered as less likely diagnostic possibilities. There was no evidence of micrometastases. No further seizure activity was observed, and the patient's sensorium returned to normal within 4 h. The patient later reported that he had experienced blunt trauma to the head approximately 2 yr previously. The radiologist's opinion was that a traumatic lesion dating from that time would have been associated with more atrophy than was evident from the scans. Electroencephalography 24 h later was interpreted as normal during wakefulness, during sleep, and after hyperventilation. The testicular mass was reported subsequently to be a malignant germ cell tumor.

## Discussion

Epileptiform electroencephalographic activity and seizure-like motor activity have been reported in association with the administration of sevoflurane. The latter

has occurred principally in children during induction with relatively high concentrations of sevoflurane. The majority of reports have described epileptiform electroencephalographic activity, mostly polyspike and polyspike-and-wave patterns, with minimal or no associated motor manifestations. Epileptiform electroencephalographic activity has been observed in healthy adults,<sup>6,7</sup> a nonepileptic child,<sup>5</sup> and two children with histories of epilepsy.<sup>3</sup> There have been a limited number of reports of frank motor convulsions in association with sevoflurane. In a report by Haga *et al.*,<sup>2</sup> "convulsions" were reported to have occurred during induction in 6% of pediatric patients who received either 4% or 6% sevoflurane. Adachi *et al.*<sup>1</sup> reported seizure-like motor activity also during induction, in a 9-yr-old girl. There has been only one case report of a grand mal convulsion occurring in an adult patient in association with administration of sevoflurane.<sup>4</sup> In that case, an apparent grand mal convulsion also occurred during emergence from anesthesia. The neurologically normal adult patient had received a general anesthetic that included thiopental and vecuronium for induction, followed by a maintenance regimen similar to that used in the current patient, *i.e.*, nitrous oxide, sevoflurane, and fentanyl (50  $\mu$ g). Neostigmine and atropine were administered to reverse neuro-muscular blockade, and, soon thereafter, a grand mal convulsion occurred. Subsequent electroencephalography was normal. However, the patient did not undergo radiologic evaluation, and, therefore, the presence of small, potentially predisposing cortical lesions, such as that discovered in the present patient, cannot be excluded.

Potentially predisposing factors were sought in our patient. Computed tomography revealed a preexisting cortical lesion, which could have served as the nidus of seizure initiation. No other predisposing factors were identified. The patient's history of illicit drug use was remote. No other anesthetic agents with well-established proconvulsant or central nervous system-irritant properties were employed. Although various narcotics have been suspected of having proconvulsant properties, fentanyl, in a dose of 100  $\mu$ g, has never been implicated. The patient was not significantly hypocarbic during the procedure.

It is not possible to be certain whether the motor activity observed in our patient was a true convulsion, intense myoclonic activity, or something similar to the opisthotonic reactions that have been associated with propofol.<sup>8</sup> In this situation, there was some suggestion of a Jacksonian progression and an apparent postictal state early in the recovery period, although interpretation of the latter may have been confounded by the administration of 5 mg diazepam. For the clinician managing one of these occurrences, the potential patient hazards associated with all three events are similar, and



the necessity for readiness to intervene rapidly to prevent patient injury is equivalent.

This patient had no apparent neurologic sequelae. The same has been true of all of other reported patients in whom either abnormal electroencephalographic or motor activity has been observed. Accordingly, it seems inappropriate to recommend significant restraint on the use of sevoflurane. Events of this nature are rare. In addition, the current case included a confluence of circumstances that are probably relatively uncommon in adult anesthesia, *i.e.*, the use of an inhalation induction in an adult patient with a preexisting intracerebral lesion who received an anesthetic that included a minimal amount of agents with potential seizure suppressant effects (*i.e.*, no induction agent and only 1 mg midazolam). Nonetheless, our experience indicates that clinicians should be aware of the possibility of the occurrence of seizure-like activity at emergence from sevoflurane anesthesia. They should be particularly attentive to that possibility in patients whose preexisting state includes some condition that potentially might predispose to the occurrence of seizures, including

intraparenchymal, especially cortical, cerebral lesions (scarring, primary tumors, metastases) or pharmacologic agents that lower seizure threshold.

## References

1. Adachi M, Ikemoto Y, Kubo K, Takuma C: Seizure-like movements during induction of anaesthesia with sevoflurane. *Br J Anaesth* 1992; 68:214-5
2. Haga S, Shima T, Momose K, Andoh K, Hashimoto Y: Anesthetic induction of children with high concentrations of sevoflurane (Japanese). *Japanese Journal of Anesthesiology* 1992; 41:1951-5
3. Komatsu H, Taie S, Endo S, Fukuda K, Ueki M, Nogaya J, Ogli K: Electrical seizures during sevoflurane anesthesia in two pediatric patients with epilepsy. *ANESTHESIOLOGY* 1994; 81:1535-7
4. Terasako K, Ishii S: Postoperative seizure-like activity following sevoflurane anesthesia. *Acta Anaesthesiol Scand* 1996; 40:953-4
5. Woodforth JJ, Hicks RG, Crawford MR, Stephen JPH, Burke DJ: Electroencephalographic evidence of seizure activity under deep sevoflurane anesthesia in a nonepileptic patient. *ANESTHESIOLOGY* 1997; 87:1579-82
6. Kaisti KK, Jaaskelainen SK, Rinne JO, Metsahonkala L, Scheinin H: Epileptiform discharges during 2 MAC sevoflurane anesthesia in two healthy volunteers. *ANESTHESIOLOGY* 1999; 91:1952-5
7. Yli-Hankala A, Vakkuri A, Sarkela M, Lindgren L, Korttila K, Jantti V: Epileptiform electroencephalogram during mask induction of anesthesia with sevoflurane. *ANESTHESIOLOGY* 1999; 6:1596-1603
8. Bevan JC: Propofol-related convulsions. *Can J Anaesth* 1993; 40:805-9

Anesthesiology 2000; 93:1359-61

© 2000 American Society of Anesthesiologists, Inc. Lippincott Williams & Wilkins, Inc.

## Ventricular Tachycardia Caused by Hyperkalemia after Administration of Hypertonic Mannitol

Atsushi Seto, M.D.,\* Masako Murakami, M.D.,† Hiroshi Fukuyama, M.D.,\* Kuniyuki Nijijima, M.D.,\* Kazuyoshi Aoyama, M.D.,‡ Ichiro Takenaka, M.D.,\* Tatsuo Kadoya, M.D.§

MANNITOL is used commonly to reduce intracranial pressure during the perioperative period. Studies have shown that administration of hypertonic mannitol causes an increase in plasma potassium concentration.<sup>1-4</sup> However, there are few reports of life-threatening hyperkalemia associated with mannitol during anesthesia. We report a case of ventricular tachycardia (VT) associated with hyperkalemia that developed after administering hypertonic mannitol to a neurosurgical patient.

### Case Report

A 52-yr-old, 174-cm, 62-kg man with a subarachnoid hemorrhage was admitted to our hospital for clipping of an anterior communicating

artery aneurysm. The patient had been in good health and had been administered no medication until the morning of admission, when he presented with a severe headache. He had a Glasgow Coma Scale score of 15, without neurologic abnormalities. Preoperative 12-lead electrocardiography, chest radiography, and routine laboratory evaluation showed no abnormalities.

The next day, the patient was premedicated with triazolam and pirenzepine. At the time of arrival to the operating room, he was fully alert. Electrocardiography showed a normal sinus rhythm with a rate of 55 beats/min, a normal QRS duration, and a normal QT interval. Normal saline was infused through a venous catheter. A catheter then was inserted into the radial artery, and arterial blood analysis while the patient was breathing room air showed a pH of 7.39, a partial pressure of oxygen (P<sub>O<sub>2</sub></sub>) of 88 mmHg, a partial pressure of carbon dioxide (P<sub>CO<sub>2</sub></sub>) of 41 mmHg, a bicarbonate concentration of 26 mm, a sodium concentration of 140 mm, and a potassium concentration of 4.8 mm. General anesthesia was induced with use of propofol and fentanyl, and muscle relaxation was produced with use of vecuronium. After tracheal intubation, the patient underwent ventilation to achieve an end-tidal carbon dioxide value of 22-25 mmHg. Anesthesia was maintained with use of 1-1.5% sevoflurane and 60% nitrous oxide in oxygen. Fentanyl and vecuronium were added as needed.

The patient was hemodynamically stable throughout induction and at the start of surgery. Mannitol, 60 g, was administered intravenously during 20 min after surgical incision. Approximately 1 h after the beginning of mannitol infusion, when the electrocardiograph showed peaked T-waves and a wide QRS complex, an arterial blood sample was obtained, which showed a pH of 7.49, an arterial oxygen tension (P<sub>aO<sub>2</sub></sub>) of 174 mmHg, an arterial carbon dioxide tension (P<sub>aCO<sub>2</sub></sub>) of 27 mmHg, a bicarbonate concentration of 21 mm, a sodium concentration of 124 mm, and a potassium concentration of 6.8 mm. Infusion

\* Staff Anesthetist, § Anesthetist in Chief, Department of Anesthesia, Nippon Steel Yawata Memorial Hospital. † Anesthetist in Chief, Department of Anesthesia, Saiseikai-Yahata General Hospital. ‡ Anesthetist in Chief, Department of Anesthesia, Moji Rosai Hospital.

Received from the Department of Anesthesia, Nippon Steel Yawata Memorial Hospital, Kitakyushu, Japan; the Department of Anesthesia, Saiseikai-Yahata General Hospital, Kitakyushu, Japan; and the Department of Anesthesia, Moji Rosai Hospital, Kitakyushu, Japan. Submitted for publication March 6, 2000. Accepted for publication June 23, 2000. Support was provided solely from institutional and/or departmental sources.

Address reprint requests to Dr. Takenaka: Department of Anesthesia, Nippon Steel Yawata Memorial Hospital, 1-1-1 Harunomachi, Yahatahigashi-ku, Kitakyushu 805-8508, Japan. Address electronic mail to: itaken@d4.dion.ne.jp. Individual article reprints may be purchased through the Journal Web site, www.anesthesiology.org.

Key words: Neurosurgical anesthesia.

Downloaded from http://ajph.aaphublications.org/ at National Institute of Health on May 29, 2015

of 500 ml glucose, 10%, in water containing 20 U insulin was started. Five min later, VT at a rate of 150 beats/min occurred, and systolic blood pressure decreased to less than 50 mmHg. Lidocaine, 90 mg, was administered, followed by continuous infusion at 2 mg/min, and 10 ml calcium gluconate, 8.4%, and 5 U insulin with 20 ml glucose, 50%, were administered, which restored VT to sinus rhythm at a rate of 60 beats/min. Systolic blood pressure increased to 115 mmHg. At the time, electrocardiography and echocardiography showed no evidence of an acute myocardial ischemic event. Twenty min later, plasma potassium concentration was 6.3 mM. The width of the QRS complex gradually normalized. Surgery was completed without further incident. At the end of surgery, sodium and potassium concentrations were 136 mM and 5.0 mM, respectively. During the 230-min procedure, blood loss was estimated to be 100 ml, and 2,000 ml normal saline was infused. No potassium-containing solutions were administered. Urine output was 1,200 ml, and the color of the urine was clear and amber. Urinary potassium excretion was 60 mmol during surgery. The patient had an uneventful postoperative course. The next day, plasma potassium concentration was 4.9 mM and 12-lead electrocardiography showed no changes compared with preoperative electrocardiography. The patient was discharged on the eighteenth postoperative day, and there were no sequelae.

## Discussion

There are several contributing factors to the development of VT, such as ischemic heart disease, valvular heart disease, cardiomyopathy, drugs, and electrolyte imbalance.<sup>5</sup> We do not think that cardiac disease or drugs caused VT because the patient had no diseases and had been administered no drugs. There was no evidence of an acute myocardial ischemic event when VT occurred. We believe that hyperkalemia was associated casually to VT because the characteristic electrocardiographic changes of hyperkalemia preceded VT, and plasma potassium concentration was high when VT occurred. In addition, VT did not recur when plasma concentration of potassium decreased. In this patient, VT occurred even though the degree of hyperkalemia was not marked. Hyponatremia is reported to increase the cardiac toxicity of hyperkalemia; however, this mechanism is incompletely identified.<sup>6-8</sup> Hyponatremia after administration of mannitol may participate in the occurrence of VT caused by hyperkalemia. Attention should be given also to plasma sodium concentration during hyperkalemia.

The causes of hyperkalemia are divided into the following three categories: increased intake of potassium, decreased urinary excretion of potassium, and transcellular movement of potassium from cells into the extracellular fluid.<sup>8</sup> In this patient, the first two were ruled out because of the intravenous administration of potassium-free solutions and urinary potassium excretion during surgery. There are some factors that contribute to the transcellular movement of potassium, which include an acute increase in plasma osmolality, acidosis, malignant hyperthermia, rhabdomyolysis, hemolysis, insulin

deficiency, and drugs.<sup>8</sup> Several investigators have shown that hyperosmolality induced by mannitol increases plasma potassium concentration.<sup>1-4</sup> Plasma potassium concentration has been reported to increase until 2 h after hypertonic mannitol infusion, which is consistent with the time course of the occurrence of VT in this patient.<sup>3</sup> Acidosis, malignant hyperthermia, rhabdomyolysis, and hemolysis were ruled out because of the lack of suitable clinical and laboratory findings. The patient did not have diabetes mellitus, and no drugs other than mannitol were administered before hyperkalemia occurred. Therefore, we believe that hyperosmolality after administering hypertonic mannitol is causative of hyperkalemia.

Dilutional acidosis has been proposed as a possible mechanism of hyperkalemia because of the transcellular movement of potassium after administration of hypertonic mannitol.<sup>1</sup> Maintenance of steady acid-base status, however, does not prevent the increase in plasma potassium concentration.<sup>2-4,8</sup> Two alternative mechanisms that shift potassium out of the cells after mannitol administration have been suggested. First, a solvent drag phenomenon that moves potassium-rich intracellular water into the hypertonic extracellular compartment through the water pores is involved.<sup>2-4,8</sup> Second, the loss of water in the cells, caused by hyperosmolality in the extracellular fluids, increases the intracellular potassium concentration, which creates a favorable gradient for passive potassium exit through potassium channels. These mechanisms may have caused hyperkalemia after administration of hypertonic mannitol in this patient.

Administering mannitol in a dose of 1 g/kg caused hyperkalemia in this patient. A dose range of 0.25-1 g/kg mannitol is considered standard for reduction of intracranial pressure.<sup>9</sup> A previous study demonstrated that an increase in plasma osmolality of 10 mOsm necessitates reduction of intracranial pressure, which can be generated by 0.25 g/kg mannitol.<sup>10</sup> Because the extreme osmotic gradient produced by mannitol may cause electrolyte imbalance, we recommend administration of smaller dose (0.25-0.5 g/kg) and measuring of plasma osmolality. When large doses of mannitol are given, careful monitoring of the electrolyte status is essential.

This case shows a potential risk of life-threatening ventricular tachyarrhythmia caused by hyperkalemia after administration of hypertonic mannitol. It is essential to observe changes in the electrocardiogram and in plasma electrolyte concentration after administering hypertonic mannitol.

## References

1. Moreno M, Murphy C, Goldsmith C: Increase in serum potassium resulting from the administration of hypertonic mannitol and other solutions. *J Lab Clin Med* 1969; 73:291-8

2. Kim WG, Brown EB: Potassium transfer with constant extracellular pH. *J Lab Clin Med* 1968; 71:678-85
3. Makoff DL, Da Silva JA, Rosenbaum BJ, Levy SE, Maxwell MH: Hyper-tonic expansion: Acid-base and electrolyte changes. *Am J Physiol* 1970; 218:1201-7
4. Conte G, Dal Canton A, Imperatore P, De Nicola L, Gigliotti G, Pisanti N, Memoli B, Fuiano G, Esposito C, Andreucci VE: Acute increase in plasma osmo-lality as a cause of hyperkalemia in patients with renal failure. *Kidney Int* 1990; 38:301-7
5. Stoelting RK, Dierdorf SF: *Anesthesia and Co-existing Disease*, 3rd edition. New York, Churchill Livingstone, 1998, pp 57-78
6. Garcia-Palmieri MR: Reversal of hyperkalemic cardiotoxicity with hyper-tonic saline. *Am Heart J* 1962; 64:483-8
7. Ballantyne F III, Davis LD, Reynold EW Jr: Cellular basis for reversal of hyperkalemic electrocardiographic changes by sodium. *Am J Physiol* 1975; 229: 935-40
8. Rose BD: *Clinical physiology of acid-base and electrolyte disorders*, 4th edition. New York, McGraw-Hill, 1994, pp 823-62
9. Drummond JC, Patel PM: *Neurosurgical anesthesia, Anesthesia*, 5th edition. Edited by Miller RD. New York, Churchill Livingstone, 2000, pp 1895-933
10. Marshall LF, Smith RW, Rauscher LA, Shapiro HM: Mannitol dose require-ments in brain-injured patients. *J Neurosurg* 1978; 48:169-72