

Malignant Hyperthermia-like Episode in Becker Muscular Dystrophy

Kleopas A. Kleopa, M.D.,* Henry Rosenberg, M.D.,† Terry Heiman-Patterson, M.D.‡

HYPERKALEMIA and rhabdomyolysis after the use of succinylcholine and potent inhalation anesthetic agents has been reported in patients with Duchenne (DMD) and Becker muscular dystrophy (BMD).^{1,2} In addition, some patients with DMD are susceptible to malignant hyperthermia (MH) based on positive results of *in vitro* the halothane-caffeine contracture test (IVCT).^{2,3}

We report an unusual case of hyperkalemic cardiac arrest and rhabdomyolysis in an 18-yr-old man with a history of muscular dystrophy, after a 6-h orthognathic procedure conducted with use of isoflurane and rocuronium. Subsequently, the results of the IVCT were positive and muscle dystrophin analysis confirmed the diagnosis of BMD.

Case Report

An 18-yr-old man weighing 127 kg was admitted for elective orthognathic surgery. Family history was unremarkable. At the age of 5 yr he began to develop muscle fatigue and weakness. His creatine kinase (CK) was elevated to approximately 10,000 U/l. Muscle biopsy showed mild myopathic changes and DMD was suspected. However, his weakness did not progress and subsequent muscle biopsy at age 12 yr was unchanged, leaving the diagnosis unclear. He underwent hernia repair (agents unknown) at age 6 yr without problems. Medical history was otherwise unremarkable and the patient was not prescribed medication. Preoperative CK level was 3,053 U/l, and results of blood gas analysis were normal.

Anesthesia was induced with use of thiopental, rocuronium, and isoflurane. Standard monitoring was used, including end-tidal capnography and esophageal temperature recording. The 6-h surgery was uneventful, without hypotension, rigidity, or hyperthermia. End-tidal carbon dioxide remained in the range of 30–36 mmHg throughout the surgery. Blood transfusion was not necessary. In the recovery room, the patient woke up, was hemodynamically stable, and started moving his extremities to command. Two minutes later, while he was still intubated, heart rate decreased to the range of 40 beats/min and he became unresponsive. Atropine, 0.5mg, was administered, along with

carotid massage. Cardiopulmonary resuscitation was started immediately. Initial electrocardiography showed wide complex tachycardia and standard advanced cardiac life support (ACLS) protocol was followed, with defibrillation and administration of epinephrine, lidocaine, and bretylium. Vasopressors, including dopamine, epinephrine, and norepinephrine bitartrate, were administered, and 1 mEq/kg sodium bicarbonate was injected.

Initial measurement of arterial blood gases showed metabolic acidosis and hypercapnia, despite adequate oxygenation (table 1). Hyperkalemia, hypocalcemia, hyperphosphatemia, and increasing CK level also were found. The patient was immediately treated using glucose, insulin, and calcium and the rhythm converted to sinus tachycardia. Based on the evidence of muscle hypermetabolism and rhabdomyolysis, MH was suspected. Dantrolene sodium (720 mg) was administered and continued for 12 h to a total of 10 mg/kg. Resuscitation was performed for 2 h 20 min until the patient was hemodynamically stable; he was then transferred to the intensive care unit. Renal failure developed and the patient's urine became dark; results of myoglobin testing were positive. Eight hours after the onset of cardiac arrest, CK was greater than 50,000 U/l, and his temperature increased to 40.9°C (table 1). No evidence of infection was seen after chest radiography of blood or urine culturing.

Severe weakness in all extremities was noted, and CK level remained increased more than 50,000 U/l for 1 week before it decreased gradually. Five days after cardiac arrest, hemodialysis was necessary until renal function recovered 2 weeks later. Muscle strength improved gradually and the patient was extubated 2 weeks after the event. He was transferred to a rehabilitation facility 1 month later and baseline neurologic status returned within 3 months. Subsequent muscle biopsy with IVCT was requested.

Muscle Biopsy

Diagnostic vastus lateralis muscle biopsy was performed during local anesthesia and was processed for histopathologic evaluation and frozen histochemistry using standard techniques. Mild variation in fiber size and a small number of central nuclei and split fibers were found, consistent with early myopathic changes. Western blot analysis of muscle dystrophin (Athena Diagnostics Inc., Worcester, MA) showed decreased molecular size and quantity (20–100% of normal), typical for BMD.

Malignant Hyperthermia Testing

Muscle samples were removed for MH contracture testing as previously described.⁴ The muscle initially was adjusted to a resting tension of 2 g and stimulated supramaximally with use of a pulse generator to confirm viability. Ten viable muscle strips were exposed to increasing concentrations of halothane (1–3%), and the maximal response within 5 min was recorded. Subsequently, additional strips were exposed to incremental doses of caffeine (0.125–16 mM). Skeletal muscle strip response to halothane was greater than 2 g (normal, < 0.7 g), and to caffeine 0.4 g (normal, < 0.3 g).

Discussion

The sudden onset of hyperkalemia and rhabdomyolysis is remarkable in a patient with BMD after anesthesia using a potent inhalation agent and a nondepolarizing

* Fellow, Department of Neurology, Hospital of the University of Pennsylvania.
† Professor of Anesthesiology, Department of Anesthesiology, Jefferson Medical College, Thomas Jefferson University. ‡ Professor of Neurology, School of Medicine, MCP-Hahnemann University.

Received from the Department of Neurology, MCP-Hahnemann University; the Hospital of the University of Pennsylvania; and the Department of Anesthesiology, Jefferson Medical College, Thomas Jefferson University, Philadelphia, Pennsylvania. Submitted for publication March 13, 2000. Accepted for publication June 23, 2000. Support was provided solely from institutional and/or departmental sources.

Address reprint requests to Dr. Rosenberg: Thomas Jefferson University Medical College, Department of Anesthesiology, 111 South 11th Street, Suite G-8490, Philadelphia, Pennsylvania 19107-5092. Address electronic mail to: Henry.Rosenberg@mail.tju.edu. Individual article reprints may be purchased through the Journal Web site, www.anesthesiology.org.

Key words: Cardiac arrest; dystrophinopathy; *in vitro* halothane-caffeine contracture test; rhabdomyolysis.

Table 1. Laboratory Findings during the MH-like Episode

	Time after Onset						Normal Values
	30 min	1 h	2 h	4 h	8 h	24 h	
Arterial blood gases							
pH	7.17	7.36	7.48	7.33	7.41	7.50	7.35–7.45
P _{CO₂}	65.7	32.0	25.9	41.3	35.9	22.6	35–45 mmHg
P _{O₂}	156	269	147	239	157	177	80–100 mmHg
HCO ₃	24	18	20	22	23	25	22–26 mEq/l
Chemistry							
Potassium	6.3	6.9	4.1	3.5	4.0	3.6	3.5–5.0 mEq/l
Sodium	170	146	155	154	150	146	135–148 mEq/l
Chloride	95	93	96	97	101	99	101–111 mEq/l
CO ₂	50	23	23	21	18	22	22–30 mEq/l
BUN	20	22	24	25	34	40	7–23 mg/dl
Creatinine	1.3	1.6	ND	ND	3.2	4.0	0.7–1.4 mg/dl
Calcium	6.3	5.6	ND	ND	6.1	5.0	8.5–10.8 mg/dl
Magnesium	3.7	ND	3.1	2.8	2.5	2.5	1.8–2.6 mg/dl
Phosphorus	14.8	16.8	ND	ND	5.5	7.7	2.5–4.7 mg/dl
CK*	7,330	ND	ND	ND	>50,000	>50,000	30–230 U/l
Temperature					40.9°C	37.2°C	

* Preoperative creatine kinase (CK) = 3,053 U/l.

MH = malignant hyperthermia; P_{CO₂} = partial pressure of carbon dioxide; P_{O₂} = partial pressure of oxygen; HCO₃ = bicarbonate; CO₂ = carbon dioxide; BUN = blood urea nitrogen; ND = not done.

muscle relaxant. In previously reported similar cases the onset of hyperkalemia almost invariably followed succinylcholine administration.^{2,5–7} Rhabdomyolysis developed in a few DMD patients without the use of succinylcholine,^{8–11} cardiac arrest occurred only in a child with BMD during anesthetic induction with halothane.¹² It therefore appears that at least some patients with dystrophinopathy, including BMD, are at risk of the same muscle destruction and hyperkalemia after anesthesia with potent volatile inhalation agents alone as with the addition of succinylcholine. The mortality rate is potentially high.¹³

Malignant hyperthermia-like episodes of unusually late onset have been reported previously.^{1,10,11} Similar to the current patient, cardiac arrest in one case occurred 10 min after the patient regained consciousness from anesthesia.¹¹ Perhaps the absence of muscle activity during anesthesia restricted the release of calcium from the sarcoplasmic reticulum. At awakening, increased muscle activity, in combination with residual anesthesia, potentiated calcium release and the cascade of metabolic effects.^{1,14}

During typical episodes of MH, rigidity may be absent in 25% of patients, and actual hyperthermia develops in only one third.^{1,2} Moreover, dantrolene may prevent or delay the onset of these symptoms. Unlike typical MH, hyperkalemia during or after anesthesia in patients with dystrophinopathies may manifest suddenly, without the typical MH increase in end-tidal carbon dioxide.^{5,6} However, in some patients with muscular dystrophy, muscle rigidity that is more typical of MH developed after administration of succinylcholine.^{2,3} In the current patient, postanesthesia onset of cardiac arrest, biochemical evidence of acute muscle hypermetabolism and rhabdomyolysis, lack of rigidity, and delayed onset of hyperthermia, led to the classification as an MH-like event.

The positive response to IVCT, as is typically seen with true MH susceptibility, is unusual in BMD. We previously documented such responses in some patients with DMD.^{2,3} Results of the IVCT were negative in a BMD patient after a clinical episode of rhabdomyolysis and masseter spasm,² but they were positive in another BMD patient without an MH-like episode.² The result of the IVCT, with a specificity of approximately 80% using the North American protocol,¹⁵ may represent a false-positive response in our patient. Elevated myoplasmic calcium levels, increased calcium release at baseline, and impaired mechanisms that re-sequester calcium have been found in dystrophin-deficient muscle.¹⁶ Increased intracellular calcium levels may be caused by failure of calcium adenosine triphosphatase or dystrophin-related structural membrane alterations affecting calcium channel function.¹⁷ Potent inhalation agents increase calcium release from the sarcoplasmic reticulum,¹⁸ exacerbating the baseline abnormality. These factors may lead to uncontrolled elevation of myoplasmic calcium, causing hypermetabolic state, membrane breakdown, and rhabdomyolysis.^{1,14}

Another explanation for both the clinical event and the positive response to the IVCT in this case could be the coexistence of BMD and MH. This seems to be less likely because of different inheritance patterns and lack of family history. However, it cannot be excluded because genetic testing for MH was not possible in this family. More than 50% of MH in susceptible families has been linked to the *RYR1* gene on chromosome 19q13, which encodes the ryanodine receptor, with more than 20 known mutations.^{14,19} Several other genetic loci may be involved in MH.¹⁹ Despite the progress in the molecular genetics of MH, replacement of the IVCT by genetic testing is not

possible because of the enormous size of the *RYR1* gene and emerging genetic heterogeneity.¹⁹ Further improvement in the diagnostic accuracy of the IVCT is necessary. The use of 4-chloro-m-cresol may be promising.²⁰

This case also raises the question whether patients with myopathies who experience hyperkalemic arrest in the perioperative period should be administered dantrolene as part of the resuscitation. Primary attention always should be directed to the restoration of circulatory effectiveness and correction of hyperkalemia.¹ However, unexplained metabolic acidosis and hypercapnia that indicates muscle hypermetabolism, along with evidence of rhabdomyolysis, should raise the possibility of true MH or an MH-like episode.¹⁴ Dantrolene administration is appropriate in both cases. Regardless of the underlying molecular genetic mechanism, classic MH and MH-like events associated with other myopathies seem to share the common final pathway of calcium-induced muscle hypermetabolism,^{1,14,19} which can be reversed by dantrolene.

Routine testing for MH susceptibility is not necessary in every patient with dystrophinopathy. However, as this case shows, MH-susceptible patients have a greater risk of MH-like episodes, and potent inhalation anesthetics and succinylcholine should be avoided. If an MH-like event occurs, full evaluation should be considered with use of muscle biopsy when clinically indicated, the IVCT, and genetic testing for MH-associated mutations.

References

- Heiman-Patterson TD: Neuroleptic malignant syndrome and malignant hyperthermia: Important issues for the medical consultant. *Med Clin North Am* 1993; 77:477-92
- Heiman-Patterson TD, Natter HM, Rosenberg HR, Fletcher JE, Tahmouh AJ: Malignant Hyperthermia susceptibility in X-linked muscle dystrophies. *Pediatr Neurol* 1986; 2:356-8
- Heiman-Patterson TD, Rosenberg H, Fletcher JE, Tahmouh AJ: Halothane-Caffeine contracture testing in neuromuscular diseases. *Muscle Nerve* 1988; 11:453-57
- Larach MG: Standardization of the caffeine halothane muscle contracture test. North American Malignant Hyperthermia Group. *Anesth Analg* 1989; 69:511-5
- Farrell PT: Anesthesia-induced rhabdomyolysis causing cardiac arrest: Case report and review of anesthesia and the dystrophinopathies. *Anaesth Intensive Care* 1994; 22:597-601
- Sullivan M, Thompson KW, Hill D: Succinylcholine-induced cardiac arrest in children with undiagnosed myopathy. *Can J Anaesth* 1994; 41:497-501
- Wu CC, Tseng CS, Shen CH, Yang TC, Chi KP, Ho WM: Succinylcholine-induced cardiac arrest in unsuspected Becker muscular dystrophy: A case report. *Acta Anaesthesiol Sin* 1998; 36:165-8
- Kelfer HM, Singer WD, Reynolds RN: Malignant hyperthermia in a child with Duchenne muscular dystrophy. *Pediatrics* 1983; 71:118-9
- Sethna NF, Rockoff MA: Cardiac arrest following inhalation induction of anesthesia in a child with Duchenne's muscular dystrophy. *Can Anaesth Soc* 1986; 33:799-802
- Rubiano R, Chang J-L, Carroll J, Sonbolian N, Larson CE: Acute rhabdomyolysis following halothane anesthesia without succinylcholine. *ANESTHESIOLOGY* 1987; 67:856-7
- Chalkiadis GA, Branch KG: Cardiac arrest after isoflurane anaesthesia in patient with Duchenne's muscular dystrophy. *Anaesthesia* 1990; 45:22-5
- Marks WA, Bodensteiner JB, Reitz RD: Cardiac arrest during anesthetic induction in a child with Becker type muscular dystrophy. *J Child Neurol* 1987; 2:160-1
- Larach MG, Rosenberg H, Gronert GA, Allen GC: Hyperkalemic cardiac arrest during anesthetics in infants and children with occult myopathies. *Clin Pediatr* 1997; 36:9-16
- Loke J, MacLennan D: Malignant hyperthermia and central core disease: Disorders of Ca²⁺ release channels. *Am J Med* 1998; 104:470-86
- Allen GC, Larach MG, Kunselman AR: The sensitivity and specificity of the caffeine-halothane contracture test: A report from the North American Malignant Hyperthermia Registry. The North American Malignant Hyperthermia Registry of MHAUS. *ANESTHESIOLOGY* 1998; 88:579-88
- Imbert N, Cognard C, Dupont G, Guillou C, Raymond G: Abnormal calcium homeostasis in Duchenne muscular dystrophy myotubes contracting in vitro. *Cell Calcium* 1995; 18:177-86
- Carlson CG: The dystrophinopathies: An alternative to the structural hypothesis. *Neurobiol Dis* 1998; 5:3-15
- Nelson TE, Sweo T: Ca²⁺ uptake and Ca²⁺ release by skeletal muscle sarcoplasmic reticulum: Differing sensitivity to inhalational anesthetics. *ANESTHESIOLOGY* 1988; 69:571-7
- Jurkat-Rott K, McCarthy T, Lehmann-Horn F: Genetics and pathogenesis of malignant hyperthermia. *Muscle Nerve* 2000; 23:4-17
- Baur CP, Bellon L, Felleiter P, Fiege M, Fricker R, Glahn K, Heffron JJ, Herrmann-Frank A, Jurkat-Rott K, Klinger W, Lehane M, Ørding H, Tegazzin V, Wappler F, Georgieff M, Lehmann-Horn F: A multicenter study of 4-chloro-m-cresol for diagnosing malignant hyperthermia susceptibility. *Anesth Analg* 2000; 90:200-

Anesthesiology 2000; 93:1537-9

© 2000 American Society of Anesthesiologists, Inc. Lippincott Williams & Wilkins, Inc.

Transient Neurologic Symptom (TNS) following Intrathecal Ropivacaine

Sugantha Ganapathy, F.R.C.A., F.R.C.P.C.,* Harjinder B. Sandhu, F.R.C.P.C.,† Carol A. Stockall, F.R.C.P.C.,‡ Debra Hurley, R.N.§

SCHNEIDER *et al.*¹ initially described transient neurologic symptom (TNS) in 1993 after hyperbaric lidocaine

spinal anesthesia. The reported incidence varies from 0-37% based on the drug used and surgical position, with hyperbaric 5% lidocaine resulting in the highest incidence of TNS and bupivacaine resulting in the lowest incidence.² Lithotomy position and flexion of knee are associated with a higher incidence.² Ropivacaine, an enantiomerically pure local anesthetic has been documented to produce less motor blockade than other local anesthetics. Van Kleef *et al.*³ documented the efficacy of ropivacaine as a spinal anesthetic. Gautier *et al.*⁴ used it for outpatient arthroscopy and report no TNS in 90 patients. We have used low-dose ropivacaine (10 mg) intrathecally for knee arthroscopy in a small number of patients. We report one

* Associate Professor of Anesthesia, † Clinical Fellow in Regional Anesthesia, ‡ Associate Professor of Anesthesia and Director of Ambulatory Anesthesia, § Research Coordinator.

Received from the Department of Anesthesia, London Health Sciences Centre, University Campus, University of Western Ontario, London, Ontario, Canada. Submitted for publication April 28, 2000. Accepted for publication June 23, 2000. Support was provided solely from institutional and/or departmental sources.

Address reprint requests to Dr Ganapathy: Department of Anesthesia, London Health Sciences Centre, University Campus, University of Western Ontario, 339 Windermere Road, London, Ontario, Canada N6A 5A5. Address electronic mail to: sganapat@julian.uwo.ca. Individual article reprints may be purchased through the Journal Web site, www.anesthesiology.org.

Key words: Regional anesthesia; ropivacaine; spinal anesthesia.

Downloaded from <http://ajphaphapublications.org/> at www.aphipublications.org/ on February 27, 2024

patient who received 10 mg hyperbaric ropivacaine and in whom TNS developed, lasting 3 weeks.

Case Report

A 38-yr-old woman scheduled to undergo elective knee arthroscopy underwent spinal anesthesia while in the right lateral decubitus position at L2-L3, with 10 mg ropivacaine, 1% (Naropin; AstraZeneca, Mississauga, Ontario, Canada), and was made hyperbaric with addition of 0.5 ml dextrose, 10%. Spinal puncture was accomplished during the second attempt using a 25-gauge Whitacre needle, and the cerebrospinal fluid (CSF) was clear. There was no paresthesia. The patient remained in a lateral position until the sensory block to pin prick reached the T12 level during testing 1 min after the drug delivery. Soon after turning supine the patient reported severe low backache in the sacral area even before surgery started, which she attributed to the position. She refused administration of sedation or other analgesics because she wanted to observe surgery. Discomfort was present throughout surgery. Vital signs remained stable throughout the procedure. The sensory block reached a level of T4 bilaterally. Surgical duration was 41 min and the patient reported no pain or nausea in the postanesthesia care unit. The backache resolved during assumption of the supine position. She had no motor block in both legs on arrival in the postanesthesia care unit and the sensory block receded more than 75 min completely. She could pass urine 25 min after complete recession of sensory block.

At follow-up the morning after surgery, she reported moderate to severe headache and nausea, which improved when lying down. She also had neck pain but no auditory symptoms. She had severe backache, which worsened during coughing but denied having "sciatica" pain. She experienced some disequilibrium when she stood up. She gave a verbal reporting score of 30-40 for wound pain (on a scale of 0-100, 100 being the worst pain). She was afebrile and denied having any sensory motor disturbances in her lower limbs, blurring of vision, or photophobia. A provisional diagnosis of postdural puncture headache was made and she was advised to take regular doses of acetaminophen with codeine and Keterolac and drink lots of coffee. The follow-up on the second postoperative day revealed that her wound pain was 50-60 out of 100. The headache was moderate. She continued to have backache that worsened during coughing. On the third postoperative day, headache and surgical pain improved but she reported continuing backache that radiated to her buttocks, the back of both thighs, and her calves with no fever. On the fifth postoperative day she had significant pain radiating to her thighs and a severe ache in her calves and noted some numbness on the inner aspect of her soles. She was still afebrile. She had no bladder or bowel disturbance. A detailed examination was performed the following day and a neurosurgical consult was obtained to rule out disk herniation, epidural abscess, or epidural hematoma.

At examination she had no fever or photophobia and did not look ill. She had driven to the hospital herself. The straight leg-raising test was restricted to 45° because of pain in the back, thighs, and legs. Her neck was supple and cranial nerves were intact. Sensory examination showed normal sensation, except for the inner aspect of soles for which it was slightly reduced. Tendon reflexes were preserved; however, the left ankle was sluggish. Motor power was normal. A rectal examination was not performed. Magnetic resonance imaging of the spine showed mild bulging of the T10-T11 and L4-L5 disks, but protrusion or encroachment of neural structures was not obvious. There was no entrapment or abnormality noted in the L5 root. There was no evidence of epidural or spinal hematoma or abscess. A provisional diagnosis of TNS was determined. No therapeutic interventions were performed. The patient gradually recovered, and at 20 days after spinal anesthesia, she had only a mild ache in the sacrum with no radicular pain. This ache improved over a period of 6 weeks. The sensation in her foot returned to normal.

Discussion

Schneider *et al.*¹ initially brought TNS to the attention of the anesthesia community in 1993. Although the highest incidence was reported in patients who received spinal anesthesia with lidocaine (4-33%), it has been documented to occur after spinal anesthesia using bupivacaine (1.3%), mepivacaine, and tetracaine (1.6%). This incidence varies with the type of surgical procedure but is unaffected by baricity and concentration.⁵ TNS is considered to be a manifestation of neurotoxicity of some local anesthetics. Therefore, many anesthesiologists use procaine for ambulatory anesthesia, the duration of which can sometimes be inadequate if the surgery proceeds more than 1 h. Ropivacaine is less potent than bupivacaine, resulting in a lower incidence of motor blockade⁶ and thus may be an optimal anesthetic for ambulatory surgery. TNS has not been described after ropivacaine administration; however, McDonald *et al.* reported a higher incidence of backache in volunteers after administration of intrathecal ropivacaine. Unfortunately, this subset of volunteers were administered two spinal anesthetics 1 week apart, which could have contributed to backache. Gautier *et al.*⁴ used 0.2-0.35% ropivacaine for intrathecal administration, with no report of TNS, and we used a 1% solution diluted with dextrose to yield a final concentration of 0.66%. Whether this higher concentration is neurotoxic is not established.

The TNS symptoms in our patient were bilateral and of the same severity on both sides. Development of backache as soon as the drug was delivered intrathecally has not been reported in association with TNS. Larger studies are needed to determine the incidence of TNS after administration of intrathecal ropivacaine.

A number of clinical conditions can mimic TNS. Paraspinal muscle spasm caused by trauma potentially could mimic TNS but usually occurs early in the recovery period. Degenerative disk disease and postdural puncture headache can confound the clinical course, and the diagnosis of TNS seems to be one of exclusion. Although a majority of patients improve spontaneously, the symptoms can be significant enough to delay recovery from minor surgical procedures. In conclusion, we report the first case of TNS after administration of intrathecal ropivacaine, and only ongoing use of this drug will provide the true incidence of this complication after intrathecal ropivacaine administration.

References

- Schneider M, Ettl T, Kaufmann M, Schumacher P, Urwyler A, Hampf K, von Hochstetter A: Transient neurologic toxicity after hyperbaric subarachnoid anesthesia with 5% lidocaine. *Anesth Analg* 1993; 76:1154-7
- Horlocker TT, Wedel D: Neurologic complications of spinal and epidural anesthesia. *Reg Anesth Pain Med* 2000; 25:83-98

3. Van Kleef J, Veering B, Burm A: Spinal anesthesia with ropivacaine: A double-blind study on the efficacy and safety of 0.5% and 0.75% solutions in patients undergoing minor lower limb surgery. *Anesth Analg* 1994; 78:1125-30

4. Gautier Ph E, De Cock M, Van Steenberge A, Poth N, Lahaye-Goffart B, Bernard L, Hody J: Intrathecal ropivacaine for ambulatory surgery. *ANESTHESIOLOGY* 1999; 91:1239-45

5. Pollock JE, Liu SS, Neal JM, Stephenson C, Wylie C: Dilution of spinal lidocaine does not alter the incidence of transient neurologic symptoms. *ANESTHESIOLOGY* 1991; 90:445-50

6. McDonald SB, Liu SS, Kopacz DJ, Stephenson CA: Hyperbaric spinal ropivacaine: A comparison to bupivacaine in volunteers. *ANESTHESIOLOGY* 1999; 90:971-7

Anesthesiology 2000; 93:1539-41

© 2000 American Society of Anesthesiologists, Inc. Lippincott Williams & Wilkins, Inc.

Unexpected Hyperkalemia following Succinylcholine Administration in Prolonged Immobilized Parturients Treated with Magnesium and Ritodrine

Kosei Sato, M.D.,* Kimitoshi Nishiwaki, M.D., Ph.D.,† Naohiko Kuno, M.D., Ph.D.,‡ Kojiro Kumagai, M.D.,§ Hanae Kitamura, M.D.,|| Kayo Yano, M.D.,# Sakura Okamoto, M.D.,** Kaoru Ishikawa, M.D., Ph.D.,†† Yasuhiro Shimada, M.D., Ph.D.‡‡

MAGNESIUM sulfate and ritodrine have been used for many years to treat preterm labor. Patients receiving magnesium therapy are very sensitive to depolarizing and nondepolarizing neuromuscular blocking drugs.¹ The unexpected prolongation of the action of nondepolarizing neuromuscular blocking drugs in patients treated with magnesium has been reported.^{2,3} Therefore, these patients should not be "pretreated" with a nondepolarizing agent before receiving succinylcholine.^{4,5} Recently, we encountered three obstetric patients who were treated using continuous intravenous magnesium and ritodrine therapy. Cardiac arrest developed in the first patient and electrocardiographic abnormalities were seen concomitant with hyperkalemia in the others after anesthetic induction of intravenous anesthetics and succinylcholine.

Case Reports

Case 1

A 34-yr-old woman was transferred to the Japanese Red Cross Nagoya First Hospital at 19 weeks' 0 days' gestation. She conceived triplets by *in vitro* fertilization-embryo transfer and underwent Shirokar cervical cerclage at 9 weeks' gestation. Her first episode of vaginal bleeding occurred at 18 weeks' 5 days' gestation and she was referred to the hospital because of bleeding and uterine contractions.

* Assistant Professor, Department of Anesthesiology, Nagoya University School of Medicine, and Chief Anesthesiologist, Department of Anesthesiology, † Department Head of Anesthesiology, § || # ** Staff Anesthesiologist, Department of Anesthesiology, ‡ Staff Obstetrician, †† Division Head of Obstetrics, Department of Obstetrics and Gynecology, Japanese Red Cross Nagoya First Hospital. ‡‡ Professor and Chair, Department of Anesthesiology, Nagoya University School of Medicine.

Received from the Department of Anesthesiology, Nagoya University School of Medicine, Nagoya, Japan, and the Departments of Anesthesiology and Obstetrics and Gynecology, Japanese Red Cross Nagoya First Hospital, Nagoya, Japan. Submitted for publication March 23, 2000. Accepted for publication July 14, 2000. Support was provided solely from institutional and/or departmental sources. Presented in part at the 18th Annual Meeting of the Japan Society for Clinical Anesthesia, Matsuyama, Ehime, Japan, October 28-30, 1998.

Address reprint requests to Dr. Sato: Department of Anesthesiology, Nagoya University School of Medicine, 65 Tsurumai-cho, Showa-ku, Nagoya 466-8550, Japan. Address electronic mail to: sato@med.nagoya-u.ac.jp. Individual article reprints may be purchased through the Journal Web site, www.anesthesiology.org.

Key words: Acetylcholine receptors; cardiac arrest; depolarizing neuromuscular blocking drug; preterm labor up-regulation.

Results of tests for maternal serum C-reactive protein were positive and antibiotics and ritodrine (100 μ g/min) were started to control chorioamnionitis and uterine contractions. Nevertheless, supplementary administration of magnesium sulfate was necessary. Continuous intravenous administration of magnesium sulfate was started at 22 weeks' 5 days' gestation. The infusion rate of magnesium sulfate was adjusted to maintain the total magnesium concentrations in the plasma between 5.5 and 7.5 mg/dl.

Treatment was effective for 5 weeks, but finally the cervix started to open. At 25 weeks' 3 days' gestation, a decision was made to deliver one neonate and to try to recerclage the cervix during general anesthesia. The total dose of magnesium sulfate administered until that day was 2,221 g (over 20 days); total magnesium concentration was 9.0 mg/dl; and plasma potassium (K^+) and total calcium concentrations were 4.0 mm and 5.9 mg/dl, respectively. Plasma creatine kinase was 4,040 IU/l on that day. She was premedicated with atropine, sulfate (0.5 mg) and ranitidine hydrochloride (50 mg) intramuscularly. Anesthesia was induced using sodium thiamylal (250 mg) and succinylcholine (120 mg) intravenously, and the trachea rapidly was intubated. After induction, the patient suddenly became cyanotic and pulseless. The electrocardiography monitor showed ventricular fibrillation. Ventilation with oxygen and external cardiac compression was started immediately. After 45 min of external cardiac compression and intravenous administration of atropine sulfate, lidocaine, bicarbonate, calcium chloride, and epinephrine, the heart was defibrillated successfully on the seventh countershock. During this period, all three infants were delivered vaginally *via* vacuum delivery, to make it easier to execute cardiopulmonary resuscitation, and were taken care of by the neonatologists. During cardiopulmonary resuscitation, 25 min after the onset of cardiac arrest, arterial blood gas measurement was obtained and was within normal limits (table 1). The serum potassium concentration for that sample was 5.7 mm. After defibrillation, hemodynamics were stable and

Table 1. Arterial Blood Gas Analyses and Ionized Electrolytes during CPR in Case 1

	Value
pH	7.482
Paco ₂ (mmHg)	26.4
PaO ₂ (mmHg)	489.2
SaO ₂ (%)	100
Na ⁺ (mM)	132
K ⁺ (mM)	5.7
Ca ²⁺ (mM)	1.52

CPR = cardiopulmonary resuscitation; Paco₂ = arterial carbon dioxide tension; PaO₂ = arterial oxygen tension; SaO₂ = arterial oxygen saturation; Na⁺ = sodium; K⁺ = potassium; Ca²⁺ = calcium.

Table 2. Changes in Ionized Electrolytes before and after Succinylcholine Administration in Case 2

	Before	2 min	10 min	20 min
Na ⁺ (mM)	137	134	136	137
K ⁺ (mM)	4.0	6.3	5.3	4.7
Ca ²⁺ (mM)	0.74	0.74	0.84	0.88
Mg ²⁺ (mM)	1.03	0.99	0.91	0.94

Na⁺ = sodium; K⁺ = potassium; Ca²⁺ = calcium; Mg²⁺ = magnesium.

anesthesia was completed uneventfully. Postoperatively no adverse neurologic or electrocardiographic abnormalities developed.

Case 2

A 25-yr-old woman with a known twin gestation was admitted to the hospital at 23 weeks' 6 days' gestation with the diagnosis of preterm labor. Continuous intravenous administration of magnesium sulfate and ritodrine (200 µg/min) was started for the combined tocolytic action.

At 26 weeks' 3 days' gestation, a cesarean section was planned because of the diagnosis of acute fetal distress. The total dose of magnesium sulfate administered until that day was 1,734 g and total magnesium concentration in the plasma was 7.8 mg/dl. Plasma CK was 2,120 IU/l on that day. Consent to the serial measurements of blood electrolytes was obtained before induction of anesthesia. No premedication was administered. Anesthesia was induced using sodium thiamylal (200 mg) and succinylcholine (100 mg) intravenously, and the trachea rapidly was intubated. Whole blood ionized electrolytes were analyzed by use of NOVA Stat Profile Ultra (NOVA Biochemical, Waltham, MA). Within a few minutes of succinylcholine administration, the electrocardiogram showed elevated T waves. The electrocardiographic abnormalities developed rapidly. Two minutes later, a short period of ventricular tachycardia was observed. The K⁺ concentration reached 6.3 mM (table 2). Calcium chloride was injected and the electrocardiogram showed normal QRS complexes and T waves. The remainder of the anesthetic course was uneventful, and the patient's neurologic condition was unchanged postoperatively.

Case 3

A 28-yr-old woman with a history of bronchial asthma during childhood was admitted to the hospital at 25 weeks' 6 days' gestation with the diagnosis of a twin gestation and preterm labor. The intravenous administration of ritodrine (100 µg/min) was started on the day of admission. Two days later, continuous intravenous administration of magnesium sulfate also was started.

At 28 weeks' 3 days' gestation the patient, with the diagnosis of twin-twin transfusion syndrome, was scheduled to undergo cesarean section. The total dose of magnesium sulfate administered since admission was 1,759 g, and total magnesium concentration in the plasma was 5.3 mg/dl. Her plasma CK concentration was 630 IU/l on that day. Informed consent to undergo arterial cannulation and serial measurements of blood electrolytes was obtained before induction of anesthesia. The patient was premedicated with atropine sulfate (0.5 mg) and ranitidine hydrochloride (50 mg) intramuscularly. Anesthesia was induced using ketamine (60 mg) and succinylcholine (120 mg) intravenously, and the trachea rapidly was intubated. Serial electrocardiographic tracings, arterial blood sampling, and blood pressure recordings were performed. Within 2 min of administration of succinylcholine, plasma potassium concentration reached 7.2 mM (table 3) and the electrocardiogram showed widened QRS complexes and elevated T waves. Calcium chloride was injected, and within 10 min, the

Table 3. Changes in Arterial Blood Gas Analyses and Ionized Electrolytes before and after Succinylcholine Administration in Case 3

	Before	2.5 min	5 min	10 min	15 min
pH	7.443	7.365	7.365	7.384	7.390
Paco ₂ (mmHg)	31.8	43.1	42.6	39.8	38.1
PaO ₂ (mmHg)	422.4	312.5	314.2	115.9	106.2
SaO ₂ (%)	100	100	100	100	100
Na ⁺ (mM)	139	136	136	136	138
K ⁺ (mM)	4.9	7.2	6.9	6.5	5.8
Ca ²⁺ (mM)	0.93	1.02	0.97	1.19	0.98
Mg ²⁺ (mM)	1.00	1.03	0.97	0.98	0.78

Paco₂ = arterial carbon dioxide tension; Pao₂ = arterial oxygen tension; SaO₂ = arterial oxygen saturation; Na⁺ = sodium; K⁺ = potassium; Ca²⁺ = calcium; Mg²⁺ = magnesium.

electrocardiogram showed normal QRS complexes and T waves. The remainder of the anesthetic course was uneventful.

Discussion

The cardiac arrest seen in patient 1 was unusual because tracheal intubation was performed rapidly and smoothly, and the patient did not show remarkable hemodynamic changes before ventricular fibrillation. She had neither neuromuscular diseases nor severe infections. Arterial blood gas measurements, obtained during cardiopulmonary resuscitation, showed normal arterial blood-gas analysis results and a high potassium concentration. We believe that we excluded most of the common explanations for this type of cardiac arrest, with the exception of transient electrolyte abnormalities. Therefore, we measured the plasma concentrations of electrolytes before and after the induction of anesthesia in patients 2 and 3. Although the concentrations of calcium were low and of magnesium were high throughout the anesthetic induction because of magnesium infusion therapy, there were no remarkable changes in plasma electrolytes, with the exception of the potassium concentrations. Serious hyperkalemia occurred after injection of succinylcholine in patients 2 and 3.

Succinylcholine causes an increase in plasma potassium concentrations up to 1.0 mM; this level peaks within 2-5 min and quickly returns to a baseline value in healthy persons.⁶⁻⁸ This is a result of potassium efflux from skeletal muscles at the neuromuscular junction. Patients with burns, infections, or neuromuscular disease are at risk for massive hyperkalemia after succinylcholine injection.⁹ One explanation for this phenomena is that extrajunctional acetylcholine receptors have developed in these patients, so that potassium is released from the entire muscle instead of at the neuromuscular junction alone. This increase in potassium release is referred to as up-regulation of acetylcholine receptors.¹⁰

The administration of succinylcholine in immobilized patients may cause hazardous hyperkalemic response.¹⁰ All three of our patients were restricted to beds because

they received ritodrine and magnesium infusion for 2 to 3 weeks. It is likely that prolonged immobilization or bed rest contributed to the hyperkalemic response after the administration of succinylcholine in these patients.

It also has been reported that prolonged use of non-depolarizing neuromuscular blocking drugs, along with immobilization and disuse atrophy, predisposes the patient to hyperkalemia and cardiac arrest after administration of succinylcholine.¹¹ Continuous subliminal (sub-paralytic) competitive antagonism of acetylcholine receptors (*i.e.*, antagonism in the absence of immobilization) can induce a proliferation of acetylcholine receptors.¹¹ Magnesium has a direct depressant effect on skeletal muscle contraction. In addition, excess magnesium decreases acetylcholine release from motor nerve impulses, reduces the sensitivity of the motor end-plate to applied acetylcholine, and decreases the amplitude of the motor end-plate potential.¹² We speculate herein that the long-term use of magnesium, with associated immobilization and disuse atrophy, predisposed the patients to cardiac arrest (in patient 1) and severe hyperkalemia (in patients 2 and 3) in response to succinylcholine.

In all our patients, the plasma creatine kinase concentration was increased before anesthetic induction. Although its relation to the administration of magnesium and ritodrine is uncertain, an increased creatine kinase concentration may indicate the degeneration of skeletal muscle cells and predict hyperkalemia after succinylcholine administration.

Ritodrine is a selective β_2 -adrenergic agonist developed specifically for use as a uterine relaxant. Ritodrine can cause hypokalemia through movement of the potassium ions into the intracellular compartments. Preoper-

ative ritodrine therapy and abrupt cessation just before surgery may have caused an efflux of potassium ions from the intracellular compartments and exaggerated hyperkalemia after succinylcholine.

In conclusion, although succinylcholine is a first-line neuromuscular blocking drug for cesarean section, our experience suggests that succinylcholine should be used with extreme caution in patients who have been immobilized in bed and have had long-term exposure to magnesium and ritodrine.

References

1. Ghoneim MM, Long JP: The interaction between magnesium and other neuromuscular blocking agents. *ANESTHESIOLOGY* 1970; 32:23-7
2. Sinatra RS, Philip BK, Naulty JS, Ostheimer GW: Prolonged neuromuscular blockade with vecuronium in a patient treated with magnesium sulfate. *Anesth Analg* 1985; 64:1220-2
3. Kwan WF, Lee C, Chen BJ: A noninvasive method in the differential diagnosis of vecuronium-induced and magnesium-induced protracted neuromuscular block in a severely preeclamptic patient. *J Clin Anesth* 1996; 8:392-7
4. Glosten B: *Anesthesia for obstetrics*, Anesthesia, 5th edition. Edited by Miller RD. Philadelphia, Churchill Livingstone, 1999, pp 2024-68
5. Norris MC: *Obstetric Anesthesia*, 2nd edition. Philadelphia, Lippincott Williams & Wilkins, 1999, pp 518-20
6. Yentis SM: Succinylcholine and hyperkalemia. *Anaesth Intensive Care* 1990; 18:92-101
7. Mazze RI, Escue HM, Houston JB: Hyperkalemia and cardiovascular collapse following administration of succinylcholine to the traumatized patient. *ANESTHESIOLOGY* 1969; 31:540-7
8. Weintraub HD, Heisterkamp DV, Cooperman LH: Changes in plasma potassium concentration after depolarizing blockers in anaesthetized man. *Br J Anaesth* 1969; 41:1048-52
9. Gronert GA, Theye RA: Pathophysiology of hyperkalemia induced by succinylcholine. *ANESTHESIOLOGY* 1975; 43:89-99
10. Martyn JAJ, White DA, Gronert GA, Jaffe RS, Ward JM: Up-and-down regulation of skeletal muscle acetylcholine receptors. *ANESTHESIOLOGY* 1992; 76:822-43
11. Markewitz BA, Elstad MR: Succinylcholine-induced hyperkalemia following prolonged pharmacologic neuromuscular blockade. *Chest* 1997; 111:248-51
12. Mudge GH, Weiner IM: Agents affecting volume and composition of body fluids, Goodman and Gilman's *The Pharmacological Basis of Therapeutics*, 8th edition. Edited by Gilman AG, Rall TW, Nies AS, Taylor P. New York, Pergamon Press, 1990, pp 682-707

Anesthesiology 2000; 93:1541-4

© 2000 American Society of Anesthesiologists, Inc. Lippincott Williams & Wilkins, Inc.

Permanent Loss of Cervical Spinal Cord Function Associated with Interscalene Block Performed under General Anesthesia

Jonathan L. Benumof, M.D.*

PERFORMING an interscalene block (ISB) during general anesthesia (GA) for postoperative shoulder surgery analgesia is a common procedure. Although epidural,¹⁻³ sub-arachnoid,⁴⁻⁶ and motor nerve root⁷ injections have

been reported during the performance of ISB, there have been no cases reported in the peer-reviewed literature of injection of local anesthetic solution into the substance of the cervical spinal cord. Although injection of local anesthetic solution into the cervical spinal cord would be unlikely in awake patients, performing the block in anesthetized patients may increase the risk.

This report describes four cases in which the performance of ISB during GA was followed by total spinal anesthesia and extensive permanent loss of bilateral cervical spinal cord function, and in which magnetic resonance imaging (MRI) showed syrinx or cavity formation in the cervical spinal cord. Each of the patients in the cases was involved in a separate medical malpractice law

* Professor of Anesthesia.

Received from the Department of Anesthesiology, University of California-San Diego Medical Center, San Diego, California. Submitted for publication February 24, 2000. Accepted for publication July 19, 2000. Support was provided solely by the author.

Address reprint requests to Dr. Benumof: University of California-San Diego Medical Center, Department of Anesthesiology, 402 Dickinson Street, Mail Code 8812, San Diego, California 92104. Address electronic mail to: jbenumof@ucsd.edu. Individual article reprints may be purchased through the Journal Web site, www.anesthesiology.org.

Key words: Brachial plexus block; central cord syndrome; complications; injection; intraspinal cord; local anesthetic toxicity; paralysis; syrinx.

suit. In the first three cases the author was an expert witness, and in the fourth case the medical data was taken from the defense-expert timeline of clinical events and findings (obtained by interrogatory questioning of patient 2); in each case the relevant MRI was supplied by the plaintiff's attorney.

Case Reports

Case 1

The patient was a 39-yr-old woman, 172 cm, 109 kg, who presented for right shoulder arthroscopic repair of a rotator cuff tear. A cervical spine MRI 16 months before surgery was normal. Medical and surgical histories were unremarkable. After sedation with use of midazolam and methohexital administered in divided doses over 6 min to eliminate head and neck movement, the patient was unconscious but spontaneously breathing. The right interscalene groove was palpated and right upper extremity (RUE) muscle twitches were obtained *via* a 2-in (5.0 cm) 22-gauge Stimuplex (B. Braun Medical, Bethlehem, PA) needle at 0.81 mA. Alternating negative aspirations with 5-ml injections, a total of 40 ml of a solution containing 0.75% mepivacaine and 0.25% bupivacaine in 1:200,000 epinephrine was injected. Less than 30 s after the injection was completed, the patient became apneic, oxygen saturation as measured by pulse oximetry (Spo₂) decreased from 96% to 60%, blood pressure decreased by 25%, and heart rate was unchanged. The patient easily underwent ventilation *via* mask, was tracheally intubated, and stabilized within 2 min. The 45-min surgery was performed uneventfully while the patient underwent ventilation with positive pressure with 0.4% isoflurane in oxygen. Two and one half hours post-ISB, the patient opened her eyes to command and began spontaneous ventilation; 3 h post-ISB the patient was extubated. After extubation, the patient had complete loss of motor and sensory function of the RUE and allodynia and burning pain of the left upper extremity; the fully evolved neurologic deficit also included bilateral lower extremity weakness, in the right much more than in the left. Cervical spine MRI performed 3 weeks and 9 months post-ISB showed a syrinx or cavity in the central portion of the right half of the C4–C7 spinal cord (fig. 1).

Case 2

The patient was a healthy 52-yr-old woman, 155 cm, 86 kg, who underwent arthroscopic repair of a right rotator cuff tear during GA. At the end of the operation, and with the patient breathing spontaneously during GA, a right ISB was performed using a 2-in (5.0 cm) 22-gauge Stimuplex needle, 1.0 mA stimulation, and 20 ml bupivacaine, 0.25% (alternating negative aspirations with injections). After the injection, a decrease in blood pressure of 25% was responsive to 10 mg intravenous ephedrine, but the patient became apneic, was unresponsive to noxious stimuli, and had dilated pupils. One hour post-ISB, the patient awakened, and 2 hours post-ISB the patient was extubated. However, the patient had no motor or sensory function in the left upper extremity and had significant weakness of the RUE. MRI of the cervical spine 20 h post-ISB showed myelomalacia extending from C1–T1 and a 7 × 7 × 10 mm intradural, but extramedullary, right anterolateral mass at the T2 level, which slightly compressed the spinal cord. Spinal tap on postoperative day 3 showed intensely xanthochromic cerebral spinal fluid. Cervical spine MRI 25 months post-ISB showed one continuous C2–T1 intramedullary cervical spinal cord lesion and slight enlargement of the T2 extramedullary mass (fig. 2). The fully evolved neurologic deficit at 25 months consisted of weakness and atrophy of the upper extremities, in the left more than in the right, loss of pain and temperature in both upper extremities, preservation of touch, vibration and proprioception in both upper extremities, and preservation of motor and sensory function in both lower extremities. The T2 ex-

tramedullary mass was resected at 28 months post-ISB and was diagnosed as a meningioma; the patient's neurologic status was unchanged.

Case 3

A healthy 52-yr-old man, 167 cm, 93 kg, underwent an open repair of a 2-yr-old right rotator cuff tear during GA. After the completion of surgery, all anesthetics were discontinued. While the patient was still unconscious, a right ISB with a 1.5-in (3.75 cm) 25-gauge needle was thought to have been performed by "walking" the needle off the posterior aspect of the C6 transverse process and injecting 15 ml of a solution containing 1% lidocaine and 0.5% bupivacaine without epinephrine by alternating three negative aspirations with three 5-ml injections. During the ISB, patient coughing, straining, and neck movement with the needle *in situ* necessitated administration of 75 mg intravenous sodium thiopental and resumption of 1.0% isoflurane. After ISB, isoflurane was discontinued and the patient underwent suctioning and extubated. However, after 5–10 min of ventilation *via* mask, the patient remained apneic, unconscious, and unresponsive to noxious stimuli and the pupils were dilated fully. The patient was reintubated and taken to the intensive care unit. Approximately 1 h post-ISB the patient started to breathe spontaneously and open his eyes to command, and, 3 h post-ISB, the patient was extubated and awake and alert. However, he had no motor or sensory function in his RUE.

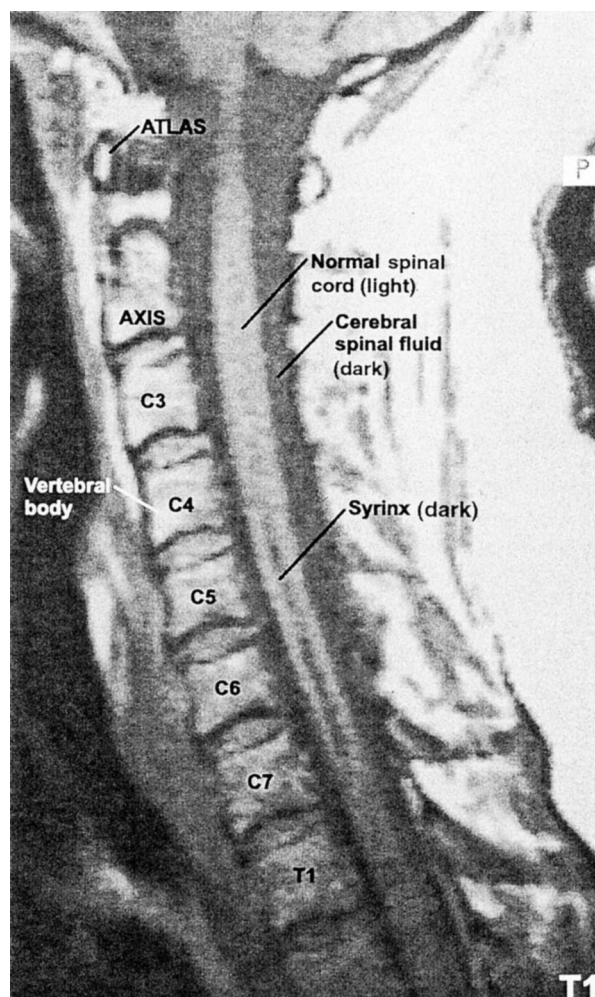


Fig. 1. Scan of the T1-weighted sagittal section of the cervical spinal cord magnetic resonance imaging performed 9 months post-interscalene block in patient 1 showing a syrinx or cavity in the central portion of the right half of the C4–C7 spinal cord.

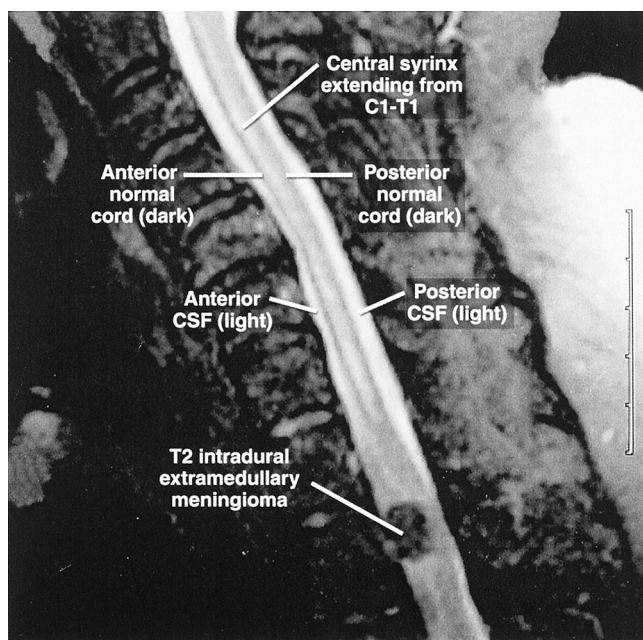


Fig. 2. Scan of the T2-weighted saggital section of the cervical spinal cord magnetic resonance imaging performed 25 months post-interscalene block in patient 2 showing one in-continuity C1-T1 intramedullary spinal cord lesion consisting of a central myelomalotic syrinx and a T2 intradural but extramedullary mass (during axial view the position of the mass was right anterolateral).

whereas the left upper extremity had a moderate decrease in finger and wrist strength. MRI of the cervical spine on postoperative day 7 showed extensive edema and hemorrhage (clotted blood) throughout the cervical spinal cord (fig. 3A). MRI at 15 months post-*ISB* showed a

syrinx in the central aspect of the right spinal cord extending the entire length of the cervical spinal cord (fig. 3B). The fully evolved motor and sensory deficits were improved slightly compared with the initial examination and were consistent with the location of the syrinxes in the cervical spinal cord.

Case 4

A 38-yr-old woman, 160 cm, 71 kg (body mass index = 27.8 kg), required arthroscopic repair of a right rotator cuff tear. The patient was in good health and had an unremarkable medical and surgery history. GA (propofol bolus and infusion, vecuronium, nitrous oxide, isoflurane) and the 100-min surgery were uneventful. During GA, a right *ISB* was performed with a 2-in (5.0 cm) 22-gauge Stimuplex needle, 1.0 ml nerve stimulation, and 35 ml bupivacaine, 0.5%, with 1:200,000 epinephrine injected in divided doses (alternating with negative aspirations). For the first 2.5 h after *ISB* the patient was apneic, remained unconscious and unreactive to painful stimuli, had dilated nonreactive 7-mm pupils, and was hemodynamically stable. Five hours post-*ISB*, the patient was extubated awake and alert; however, the patient had extensive loss of RUE motor and sensory function and left upper extremity burning pain and allodynia. Cervical spinal cord MRI at 18 months post-*ISB* showed central intramedullary hemorrhage extending to C5-C7 and at 14 months post-*ISB* showed myelomalacia and syrinx formation in most of the cervical spinal cord.

Discussion

In each of these four patients *ISB* performed during GA was followed by the same three in-series events: spinal anesthesia, loss of cervical spinal cord function, and radiologic evidence of severe cervical spinal cord damage. Several possible mechanisms are responsible for *ISB*-induced cervical spinal cord damage in these pa-

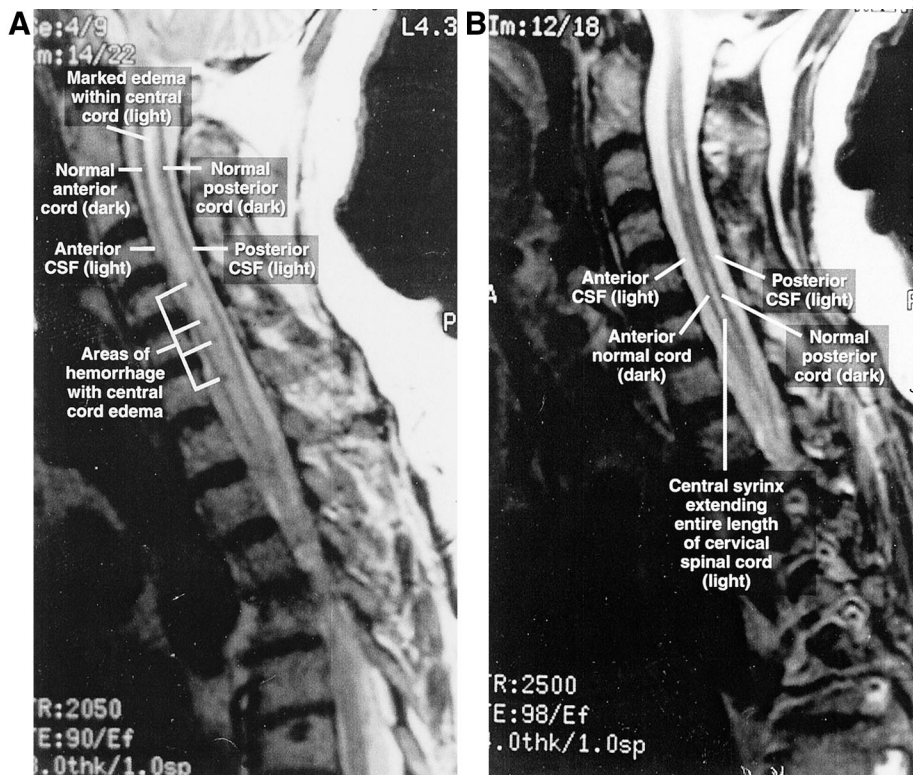


Fig. 3. (A) Scan of the T2-weighted saggital section of the cervical spinal cord magnetic resonance imaging performed on post-interscalene block day 7 in patient 3 showing marked edema and hemorrhage throughout the cervical spinal cord. (B) Scan of the T2-weighted saggital section of the cervical spinal cord magnetic resonance image taken 15 months after interscalene block in patient 3, showing a syrinx extending the entire length of the cervical spinal cord. CSF = cerebrospinal fluid.

Downloaded from http://ajphaphap.com/ at National Institute of Health Library on February 27, 2014

tients. First, there is an experimental basis for proposing peripheral intraneural injection and retrograde intraneural dissection of local anesthetic into the cervical spinal cord theory of causation,^{8,9} including increased toxicity of undiluted (with cerebrospinal fluid) local anesthetic.¹⁰ In addition, during GA a patient would be unable to protest the pain of an intraneural injection. However, the principle practical arguments against such a cause consist of the absence of damage to structures outside the cervical spinal cord and the technical improbability of achieving such an injection.^{11,12} Second, in patient 2, the T2 meningioma could have caused cephalad pooling of local anesthetic if the local anesthetic had gained access to the cerebrospinal fluid space. The principle arguments against pooling of local anesthetic above the T2 meningioma consist of absence of a rim lesion, absence of a T2 lesion, the presence of asymmetrical central cord damage, and the nontoxicity of 0.25% bupivacaine topically applied to the spinal cord.¹⁰

Third, in all four patients, all clinical and radiologic data are explained well by injection of local anesthetic solution directly into the substance of the cervical spinal cord at C6. Indeed, this cause explains why the lesions in all four patients are centered on C6. Although the tip of a 22-gauge needle may be expected to cause some damage to the spinal cord, most of the damage caused by direct injection of fluid into the spinal cord probably is a result of the phenomena of pressure and separation of cells or neurons, and the extent of neurologic damage is likely to be proportional to the volume of local anesthetic injected into the spinal cord.⁹⁻¹¹ The clinical symptomatology caused by the fluid injected into the substance of the cervical spinal cord depends on the path that the fluid follows away from the point of injection.

In patients 1 and 2 the principal argument against "intracord" injection was that a 1.5- to 2.0-in (3.75- to 5.00-cm) needle could not reach the spinal cord by passing through the C6 intervertebral foramen. However, four considerations make it probable that the needle could pass into the cervical spinal cord. First, indentation of the skin line and compression of the deeper tissue by palpation of the interscalene groove can shorten the skin-line-to-spinal-cord distance considerably. In addition, the interscalene groove can be palpated with much more force in a patient during GA than in an awake patient. Second, previous reports of injection of local anesthetic solution into the motor nerve root and axial subarachnoid space⁴⁻⁷ show that the tip of the needle can get very close to the cervical spinal cord. Third, the brachial plexus is very close to halfway between the skin line and cervical spinal cord.¹³⁻¹⁵ Because the distance from the interscalene groove skin line to the brachial plexus in the majority of patients is less than 1 in (2.5 cm), and in healthy patients is approximately 0.5 in (1.25 cm),¹²⁻¹⁵ it follows that the cervical spinal cord will be within 2 in (5.0 cm) of the skin line

in the majority of patients. Unfortunately, MRI in individual cases cannot be used to determine the IS-groove-to-spinal-cord distance because the lateral border of the neck at the C6 level is formed by the trapezius muscle, and the IS groove is well within (mesial to) the trapezius muscle, or the IS groove cannot be identified by MRI. Fourth, in patient 3, sudden and unexpected forceful movement of the patient's neck may have caused the 1.5-in (3.75 cm) needle to forcefully go through the C6 intervertebral foramen and penetrate the cervical spinal cord.

If the clinical and radiologic lesions in these four patients were caused by intracord injection of local anesthetic, there are several clinical lessons to be learned or relearned. The lessons include the following: GA can be considered as a relative contraindication for ISB, ISB needles greater than 1.0-1.25 in should not be inserted, ISB needles less than 1.5 in (< 3.75 cm) should be used, the physician should ensure the patient does not unexpectedly move, the ISB needle should have a definite caudad direction at the C6 level, and in obese patients landmarks may be obscure. With these lessons in mind, the risk of intracord injection during ISB should be minimized.

The author thanks attorneys Edwin Krieger, Thomas Ryan, Michael McNally, and Mark Kamitomo for assistance in obtaining the relevant MRIs, and neurologist doctors John Arrington, Colin Bramford, and Charles Kerber for accurate labeling of the MRIs.

References

1. Kumar A, Battit GE, Froese AB, Long MC: Bilateral cervical and thoracic epidural blockade complicating interscalene brachial plexus block: A report of two cases. *ANESTHESIOLOGY* 1971; 35:650-2
2. Scammell SJ: Inadvertent epidural anesthesia as a complication of interscalene brachial plexus block. *Anaesth Intensive Care* 1979; 7:56-7
3. Dutton R, Eckhardt W, Sunder N: Total spinal anesthesia after interscalene block of the brachial plexus. *ANESTHESIOLOGY* 1994; 80:939-41
4. Ross S, Scarborough C: Total spinal anesthesia following brachial plexus block. *ANESTHESIOLOGY* 1973; 39:458
5. Edde R, Deutsch S: Cardiac arrest after interscalene brachial plexus block. *Anesth Analg* 1977; 56:446-7
6. Passanante AN: Spinal anesthesia and permanent neurologic deficit after interscalene block. *Anesth Analg* 1996; 82:873-4
7. Barutell C, Vidal F, Raich M, Montero A: A neurological complication following interscalene brachial plexus block. *Anaesthesia* 1980; 35:365-7
8. French JD, Strain WH, Jones GF: Mode of extension of contrast substance injected into peripheral nerves. *J Neuropathol Exp Neurol* 1948; 7:47-58
9. Selander D, Sjostrand J: Longitudinal spread of intraneurally injected local anesthetics: An experimental study of the initial neural distribution following intraneural injections. *Acta Anaesthesiol Scand* 1978; 22:622-34
10. Selander D, Brattsand R, Lundborg G, Nordborg C, Olsson Y: Local anesthetics: Importance of mode of application, concentration and adrenaline for the appearance of nerve lesions. *Acta Anaesthesiol Scand* 1979; 23:127-36
11. Winnie AP: *Plexus Anesthesia: Perivascular Techniques of Brachial Plexus Block*, volume 1. New York, WB Saunders, 1993, pp 242-56
12. Selander D, Dhuner KG, Lundborg G: Peripheral nerve injury due to injection needles used for regional anesthesia. *Acta Anaesthesiol Scand* 1977; 21:182-8
13. Winnie AP: Interscalene brachial plexus block. *Anesth Analg* 1970; 49:455-6
14. *Gray's Anatomy*, 27th edition. Edited by Goss CM. Philadelphia, Lea and Febiger, 1959, p 428, figure 431
15. Grant JCB: *An Atlas of Anatomy*, 4th edition. Baltimore, Williams & Wilkins, 1956, figure 508

Severe Bilateral Corneal Injury Attributed to a Preservative-containing Eye Lubricant

Gerard R. Manecke, Jr., M.D.,* Dana P. Tannenbaum, M.D.,† Barbara E. McCoy, C.R.N.A.‡

TO prevent the cornea from drying during general anesthesia, ophthalmic ointment often is applied to the eyes. We report a case in which ophthalmic ointment containing the preservative chlorambutanol resulted in complete bilateral sloughing of the corneal epithelium.

Case Report

A 47-yr-old man presented for right acetabular osteotomy. History and physical examination were unremarkable, and he reported no allergies.

During anesthetic induction his eyes were shut. After an easy endotracheal intubation, the eyes were lubricated using a generous amount (enough to cover each globe) of fresh lubricant (Lubritears; Bausch & Lomb Pharmaceuticals, Tampa, FL) and taped shut. Administration of the anesthetic, which was primarily inhalational, proceeded uneventfully. Postoperatively, the patient reported blurred vision, which was assumed to result from residual eye lubricant.

The next day the patient reported of blurred vision, photophobia, bilateral eye pain, and headache. Ophthalmologic examination showed bilateral diminished visual acuity and conjunctival hyperemia. Fluorescein staining showed both corneal surfaces to be denuded of epithelium (smooth), with epithelial cells found only in the periphery. The diagnosis of diffuse chemical injury was determined. After irrigation with saline, bilateral protective ("bandage") contact lenses were applied. Topical antibiotics and preservative-free eye lubricant ("artificial tears") and topical nonsteroidal antiinflammatory drops were provided. The symptoms improved during the next 3 days, and 2 weeks after surgery his vision returned to normal. At follow-up ophthalmologic examination, the corneal epithelial defects were resolved.

At later evaluation of lubricant label, the preservative chlorambutanol was noted to be one of the ingredients. The hospital pharmacy had recently changed the eye lubricant from preservative free to one with preservative (chlorambutanol, 0.5%).

Discussion

Numerous *in vitro* and *in vivo* studies have shown that the corneal epithelium is sensitive to preservatives,

such as chlorambutanol and benzalkonium chloride. Scanning electron microscopy studies in rabbits have shown that twice daily administration of 0.5% chlorambutanol results in mild epithelial cell exfoliation.¹ The cytotoxicity of ophthalmic preservatives has been shown in tissue cultures,² with chlorambutanol being less toxic than benzalkonium chloride, chlorhexidine, or thimerosol.³ The toxicity is thought to be of minor clinical significance; however, eye irritation is a consequence of administration of preservative-containing eye drops.⁴

We know of no reported cases in which diffuse epithelial damage resulted from intraoperative corneal exposure to ophthalmic ointments. Furthermore, to our knowledge, ophthalmic ointment preservatives have not been discussed specifically in the anesthesiology literature. Two clinical studies have been performed that compared the use of ointments with controls (simply taping the eyes shut).^{5,6} In neither, however, are preservatives mentioned. A study that compared a paraffin (lipid-based) eye lubricant with a methocellulose solution (water-based) during surgery showed a high incidence of eyelid edema, conjunctival erythema, and blurred vision in the paraffin group.⁷ The authors postulated that the inhalational anesthetic (halothane) was concentrated in the lipid-based paraffin and was irritating to the eye. This theory has not been confirmed.

The cornea is particularly susceptible to damage during general anesthesia because of decreased tear production, decreased tear film stability, increased lagophthalmos (inadequate closure of eyelids), and loss of the Bell's Phenomenon (the natural "rolling up" of the eyes during sleep).⁸ Ocular injury has been reported to occur with 0.056% of anesthetics,⁹ the most common injury being corneal abrasion. Patients with corneal abrasion usually report severe pain in the immediate postoperative period, and discrete areas of corneal involvement are noted during examination using fluorescein. In cases of drying, a thin band of epithelial damage is present, corresponding to the area of exposure. Our patient, however, had complete bilateral loss of the corneal epithelial layer. There were no isolated areas of involvement and no discrete bands to suggest drying.

The treatment of patients with toxic corneal epithelial injury is supportive. The eyes are irrigated with normal

* Clinical Professor of Anesthesiology, † Nurse Anesthetist, Department of Anesthesiology, ‡ Resident in Ophthalmology, Department of Ophthalmology.

Received from the Departments of Anesthesiology and Ophthalmology, University of California, San Diego, California. Submitted for publication April 7, 2000. Accepted for publication July 24, 2000. Support was provided solely from institutional and/or departmental sources.

Address reprint requests to Dr. Manecke: Department of Anesthesiology, UCSD Medical Center, 200 West Arbor Drive, San Diego, California 92103-8770. Address electronic mail to: gmanecke@ucsd.edu. Individual article reprints may be purchased through the Journal Web site, www.anesthesiology.org.

Key words: Chlorambutanol; ocular injury; preservatives.

Downloaded from http://ajphaphisphair.com/ at National Institute of Health on February 20, 2014

Table 1. Blood Gas Parameters during Different Phases of Acetazolamide Therapy

	Case 1			Case 2			Case 3*		
	Before ACZ Therapy	During ACZ Therapy	After Discontinuation of ACZ	Before ACZ Therapy	During ACZ Therapy	After Discontinuation of ACZ	After 2 days ACZ Therapy	7 h after Starting Mechanical Ventilation	After Discontinuation of ACZ
pH	7.476	7.395	7.509	7.417	7.339	7.422	7.35	7.14	7.47
Paco ₂ (mmHg)	31.2	20.0	28.3	32.3	18.8	27.7	10	16.6	30
Pao ₂ (mmHg)	112.1	79.7	187.4	191.5	97.3	113	110	176.4	154
HCO ₃ ⁻ (mM)	23.0	13.9	22.5	20.6	9.9	17.9	5.9	5.5	24.8
SBE (mM)	-0.3	-9.2	-0.3	-3.3	-13.9	-5.9	-18.8	-22.1	-2.8
Sao ₂ (%)	98.5	96.2	99.6	99.5	96.8	98.3	97.6	98.8	98
RR (breaths/min)	15-16	40-44	18-22	15	36-40	20-24	50-55	15	16-18

* Control blood gas values are not available because the patient was otherwise healthy before deterioration.

ACZ = acetazolamide; Paco₂ = arterial carbon dioxide tension; Pao₂ = arterial oxygen tension; HCO₃⁻ = bicarbonate; SBE = standard base excess; Sao₂ = arterial oxygen saturation; RR = respiratory rate.

abolic acidosis resulting in hypocapnia and a normal pH (table 1). Metabolic acidosis was corrected with administration of a 7.5% sodium bicarbonate infusion, 100 ml every 6 h for 48 h, with repeated analyses of blood gas. The patient was normovolemic and his blood urea, serum creatinine, and serum Na⁺ and K⁺ concentrations were normal. With the discontinuation of acetazolamide therapy on the tenth postoperative day, metabolic acidosis and hyperventilation improved gradually during the next 6 days, and the patient was weaned from mechanical ventilation.

Case 3

A 42-yr-old woman with a diagnosis of neurocysticercosis presented with signs of increased intracranial pressure. She was treated with use of oral albendazole, intravenous dexamethasone, oral glycerol, and carbamazepine. Because her headache worsened despite continued therapy, oral acetazolamide therapy was started in a dosage of 250 mg every 8 h to decrease the intracranial pressure. During the next 2 days, she became febrile and delirious. Her temperature was 39.5°C and respiratory rate was 36 breaths/min. Empiric antibiotic therapy was started because of clinical suspicion of septicemia. Tachypnea and hyperventilation worsened during the ensuing 12 h. Blood gas analysis showed severe metabolic acidosis resulting in hypocapnia and a normal pH (table 1). After administration of 36 mg morphine and 20 mg intravenous diazepam, her lungs were mechanically ventilated in synchronized intermittent mandatory ventilation mode at a mandatory rate of 15 breaths/min, a pressure support of 8 cm H₂O, a positive end-expiratory pressure of 4 cm H₂O and an inspired oxygen fraction (FiO₂) of 0.5. Ensuing moderate hypotension was treated with dobutamine infusion for 8 h. The patient was normovolemic and blood urea, serum creatinine, and serum Na⁺ and K⁺ concentrations were normal. Repeated doses of sodium bicarbonate were administered to control the metabolic acidosis during the next 48 h. Simultaneously, acetazolamide therapy was discontinued. Metabolic acidosis improved during the ensuing 48 h and the patient's trachea was extubated on the third day of admission to the intensive care unit.

Discussion

In this study, we presented three patients with central nervous system disease treated with 250 mg acetazolamide every 8 h. In each patient, more severe metabolic acidosis developed than is usually caused by acetazolamide. In each case, appropriate compensatory hyperventilation and hypocapnia partially or completely nor-

malized arterial pH. All patients received acetazolamide in normal doses and none had any another predisposing factor.

The mechanism of this complication is difficult to explain. One possible explanation is that the central nervous system disease in these patients triggered hyperventilation, and acetazolamide may have had an enhanced ability to reduce plasma bicarbonate during these circumstances, resulting in dramatic metabolic acidosis. However, the partial pressure of carbon dioxide (Pco₂) and pH responses to metabolic acidosis in our patients are those described as normally expected compensation.⁶ Alternatively, lactic acidosis can be speculated to have compounded the acetazolamide-induced acid shift. There are no specific causes for lactic acidosis in our patients, with the exception of hypocapnia, which has been suggested to increase the lactic acid levels in blood.

Acetazolamide therapy causes metabolic acidosis by inhibiting reabsorption of HCO₃⁻ from renal tubules. In the brain, it causes CSF and extracellular fluid acidosis. The abrupt decrease of pH of the brain extracellular fluid is caused by a local increase of carbonic acid. In addition, acetazolamide also inhibits the conversion of carbon dioxide to HCO₃⁻ in erythrocytes. Thus, it increases brain Pco₂ and acidifies the brain extracellular fluid, which explains its ventilatory stimulus.^{7,8}

During systemic metabolic acidosis, carbonic anhydrase inhibition in the choroid plexus has been suggested to augment CSF acidosis.^{9,10} However, this hypothesis conflicts with the other evidence, which indicates that the decrease in pH is not caused by the choroid plexus but by the local increase of carbonic acid.⁷

Hyperventilation during acetazolamide therapy seems to have a complex cause. Systemic or CSF acidosis caused by this drug seems to be an important mechanism. In human volunteers, short- and long-term acetazolamide administration has been shown to cause hyperventilation through central and peripheral chemoreceptor mechanisms.¹¹ In cats, respiratory

stimulation has been reported, which is mediated through peripheral chemoreceptor mechanisms and the effect of acetazolamide on cerebral blood flow.¹²

Although the potential of acetazolamide to cause metabolic acidosis and hyperventilation has been shown in experimental animals and healthy volunteers, we are not aware of clinical reports of this complication in patients with cerebral disease without predisposing factors. Metabolic acidosis caused by acetazolamide usually is mild. Severe metabolic acidosis and respiratory alkalosis are seen only in patients with renal dysfunction³ or diabetes⁴ or in the elderly patients.⁵ None of our patients had these predisposing factors.

In all three patients, administration of acetazolamide had a temporal relation to the development of metabolic acidosis and hyperventilation. In patients 1 and 2, hyperventilation delayed weaning mechanical ventilation. In patient 3, severe hyperventilation necessitated administration of very high doses of sedatives and institution of mechanical ventilation. Cessation of acetazolamide therapy resulted in a trend toward correction of metabolic acidosis and hyperventilation; however, complete normalization occurred only after 2–6 days. Evidence from these cases also suggests that even normal doses of acetazolamide may precipitate severe metabolic acidosis in some patients.

Acetazolamide administration *per se* has been suggested to increase cerebral blood flow (CBF) *via* a mechanism that does not involve carbonic anhydrase.¹³ However, this evidence is not compelling because the authors did not account for carbonic acidosis in the brain. With long-term acetazolamide therapy, CBF returns to normal and the cerebral circulation has a normal response to carbon dioxide.¹⁴ This results from normal rates of excretion of metabolic H⁺ and HCO₃⁻ at abnormally high concentration gradients in the steady state after long-term acetazolamide therapy. The extent of hyperventilation seen in our patients might be predicted to cause cerebral vasoconstriction.¹⁵ Experimental evidence, on the contrary, showed that brain tissue PO₂ increased, not decreased, with acetazolamide.¹⁶ This is understandable because cerebral acidosis caused by acetazolamide also dilates cerebral vessels.

In conclusion, in patients with central nervous system disease without other known predisposing factors, severe metabolic acidosis may occur with normal doses of

acetazolamide. After discontinuation of the therapy, it may take more than 48 h for the metabolic acidosis and hyperventilation to be corrected. Therefore, acid–base status should be monitored closely in critically ill neurologic patients who are prescribed acetazolamide therapy. The chemistry in this field is complex and not understood well. More research is needed before the causes of this complication can be stated with certainty. No specific evidence implicates cerebral injury as the cause of hyperventilation in the patients described herein. It may be worthwhile to measure the lactate levels to further understand the problem. It would also be of interest to investigate subclinical renal or other mechanisms that might make some patients more susceptible than others to metabolic acidosis during acetazolamide therapy.

References

1. Prieto de Paula JM, Villamandos Nicas V, Cancelo Suarez P, del Portillo Rul A, Guillem Ares E, Prada Minguez A, Sanz de la Fuente H: Efficacy of acetazolamide treatment of patients with hypercapnia and superimposed metabolic alkalosis. *Rev Clin Esp* 1997; 197:237–40
2. DeBecker WA, Verbraecken J, Willemen M, Wittesaele W, DeCock W, Van deHeyning P: Central apnea index decreases after prolonged treatment with acetazolamide. *Am J Resp Crit Care Med* 1995; 151:87–91
3. Maisey N, Brown RD: Acetazolamide and symptomatic metabolic acidosis in mild renal failure. *Br Med J* 1981; 283:1527–8
4. Siklos P, Henderson RG: Severe acidosis from acetazolamide in a diabetic patient. *Curr Med Res Opin* 1970; 6:284–6
5. Lastnick G: Metabolic acidosis secondary to acetazolamide therapy, a possible hazardous side effect after prolonged use of acetazolamide in geriatric patients: A case report. *Ariz Med* 1975; 32:19–21
6. Schlichtig R, Grogono AW, Severinghaus JW: Human PaCO₂ and standard base excess compensation for acid-base imbalance. *Crit Care Med* 1998; 26:1173–9
7. Bickler PE, Litt L, Banville DL, Severinghaus JW: Effects of acetazolamide on cerebral acid-base balance. *J Appl Physiol* 1988; 65:422–7
8. Severinghaus JW, Hamilton FN, Cotev S: Carbonic acid production and the role of carbonic anhydrase in decarboxylation in brain. *Biochem J* 1969; 114:703–5
9. Javaheri S, Kennealy J, Runck CD, Loudon RG, Pine MB, Myers RE: Cerebrospinal fluid ions in metabolic acidosis in dogs: Effects of acetazolamide. *J Appl Physiol* 1986; 61:633–9
10. Herrera L, Kazemi H: CSF bicarbonate regulation in metabolic acidosis. Role of HCO₃⁻ formation in CNS. *J Appl Physiol* 1980; 49:778–83
11. Swenson ER, Hughes JM: Effects of acute and chronic acetazolamide on resting ventilation and ventilatory responses in man. *J Appl Physiol* 1993; 74:230–7
12. Wagenaar M, Teppema L, Berkenbosch A, Olievier C, Folgering H: Effect of low-dose acetazolamide on the ventilatory CO₂ response during hypoxia in the anaesthetized cat. *Eur Respir J* 1998; 12:1271–7
13. Hauge A, Nicolaysen G, Thoresen M: Acute effects of acetazolamide on cerebral blood flow in man. *Acta Physiol Scand* 1983; 117:233–9
14. Friberg L, Kastrup J, Rizzi D, Jensen JB, Lassen NA: Cerebral blood flow and end tidal PCO₂ during prolonged acetazolamide treatment in humans. *Am J Physiol* 1990; 258:H954–9
15. Gopinath SP, Robertson CS, Contant CF, Hayes C, Feldman Z, Narayan RK: Jugular venous desaturation and outcome after head injury. *J Neurol Neurosurg Psychiatr* 1994; 57:717–23
16. Cotev S, Lee J, Severinghaus JW: The effects of acetazolamide on cerebral blood flow and cerebral tissue PO₂. *ANESTHESIOLOGY* 1968; 29:471–7

Severe Neurological Impairment in an Infant after Nitrous Oxide Anesthesia

James K. McNeely, M.D.,* Bogdan Buczulinski, M.D.,† Diane R. Rosner, M.D.‡

THE myelodepressant and neurotoxic effects of nitrous oxide have been established.¹⁻³ Numerous case reports of adult patients have implicated nitrous oxide in the development of postoperative neurologic dysfunction in patients with undiagnosed vitamin B₁₂ deficiency.⁴⁻⁶ Vitamin B₁₂ deficiency is a rare condition in infants.⁷ To our knowledge, there is no reported case of an infant with nitrous oxide-induced exacerbation of vitamin B₁₂ deficiency. We describe a 6-month-old infant in whom severe metabolic acidosis and neurological impairment developed weeks after general anesthesia with nitrous oxide.

Case Report

A 6-month-old girl was seen for preoperative evaluation before scheduled gastrojejunostomy tube placement for correction of oral feeding difficulties secondary to neurologic impairment. The history obtained from the parents revealed a previously healthy infant who underwent uneventful 3-h general anesthesia for elective craniostomy repair at 4 months of age. At that time, preoperative findings were significant for scaphocephaly as seen during plain-film radiologic study. No neurologic defect was described, and hemoglobin concentration was 12.8 g/dl, with a mean corpuscular volume of 89 femtoliters (fl). Anesthesia for the sagittal craniotomy was maintained with administration of isoflurane, nitrous oxide, oxygen, rocuronium, and morphine. No blood products were necessary, and the patient was discharged after 2 days. Three weeks after the procedure, the parents noted a decrease in smiling and playfulness of the infant. They also thought she was somewhat "floppy." During the next 2 weeks, increased hypotonia developed in the infant. Her interest in feeding decreased and she required emergent admission to the hospital for marked tachypnea and lethargy. Examination revealed dehydration with a severe non-anion-gap acidosis, ketosis, and anemia. Arterial blood gas measurement, obtained with use of face mask oxygen in the emergency room showed a pH = 7.14, a carbon dioxide partial pressure of 7, an oxygen partial pressure of 167, and a bicarbonate concentration of 5; hemoglobin concentration was 7.8 g/dl, platelet count was 198 10³/μl, and mean corpuscular volume was 93 fl. Results of peripheral blood smear were positive for schistocytes and anisocytosis. The patient was stabilized with administration of intravenous fluids and admitted for further testing. Magnetic resonance imaging showed diffuse cerebral atrophy. Neurologic examination showed staring without tracking, decreased head control, and hypotonia. No evidence of sei-

zures was seen on the electroencephalogram. Serum testing showed increased proline and ethanols with decreased tryptophan, whereas urine organic acids showed high methylmalonic acid, propionic acid, and cystine-homocysteine levels. The serum vitamin B₁₂ concentration was less than 45 pg/ml (normal, 200-1100 pg/ml). Folate concentration was 15 ng/ml (normal, 1.5-20.5 ng/ml) with normal vitamin B₁₂ binding capacity.

The patient was diagnosed as being vitamin B₁₂ deficient, and treatment with intramuscular injections of vitamin B₁₂ was started (1,000 μg/day intramuscularly). Two weeks after the initiation of treatment serum Vitamin B₁₂ concentration was found to be moderately low: 170 pg/ml. Her neurologic condition stabilized and she was scheduled for elective gastrojejunostomy tube insertion and skin fibroblast biopsy. Anesthesia was induced and maintained with intravenous medications. Controlled ventilation was maintained with 100% oxygen delivered *via* a Mapleson D circuit. No nitrous oxide was present in the radiology procedure room. The patient made an uneventful recovery in the same room and was directly transferred to the nursing ward.

During subsequent questioning, the mother revealed that she was not a "strict" vegetarian, but she avoided dairy and meat products while breast-feeding. She did not use vitamin supplements. The mother's complete blood count and erythrocyte indices were normal; however, her serum vitamin B₁₂ concentration was moderately low at 172 pg/ml. At follow-up 3 months after the procedure, the patient was developmentally delayed, but with gradual improvement in activity. No follow-up electroencephalography or magnetic resonance imaging were performed. The patient was prescribed a daily vitamin B₁₂ supplementation. The primary cause of the vitamin B₁₂ deficiency is unidentified.

Discussion

We describe a case of severe neurologic impairment after administration of nitrous oxide general anesthesia in an infant. To date, at least nine cases of nitrous oxide-induced exacerbation of vitamin B₁₂ deficiency syndrome have been reported.⁶ However, none of these case reports involved an infant. As in the adult reports, clinical symptoms of neurologic impairment did not appear until several weeks after uneventful administration of nitrous oxide anesthesia.

Nitrous oxide irreversibly oxidizes the cobalt atom of vitamin B₁₂ such that the activity of two vitamin B₁₂-dependent enzymes, methionine synthetase and thymidylate synthetase, are decreased.⁸ Methionine synthetase converts homocysteine to methionine, which is necessary for the maintenance of the myelin sheath. Thymidylate synthetase is important for the formation of DNA. Inhibition of these enzymes can lead to the suppression of bone marrow and neurologic dysfunction. In adults, the earliest sign of vitamin B₁₂ deficiency usually is megaloblastic anemia caused by the rapid turnover of

* ‡ Assistant Professor of Anesthesiology, † CA-2 Resident in Anesthesiology.

Received from the Department of Anesthesiology, Medical College of Wisconsin, Milwaukee, Wisconsin. Submitted for publication May 16, 2000. Accepted for publication July 27, 2000. Support was provided solely from institutional and/or departmental sources.

Address reprint requests to Dr. McNeely: 3275 Hidden Hills Drive, Brookfield, Wisconsin 53005. Address electronic mail to: mcneelyj@excite.com. Individual article reprints may be purchased through the Journal Web site, www.anesthesiology.org.

Downloaded from www.anesthesiology.org on 07/27/2024

hematopoietic cells. However, neurologic involvement may be present in the absence of anemia, particularly if folic acid has been used.⁹ The peripheral nerves most commonly are involved, followed by the spinal cord and cerebral cortex, with clinical signs of neurologic dysfunction, such as paresthesia of the hands and legs, ataxia, and loss of memory.

In the pediatric literature, several congenital disorders of vitamin B₁₂-dependent metabolism were reported.¹⁰ These infants will present with failure to thrive, vomiting, unexplained severe metabolic acidosis, hypotonia, and developmental delay. The metabolism of methylmalonic acid usually is affected, with large amounts excreted in the urine. In addition to methylmalonic aciduria, varying degrees of pancytopenia and homocystinuria are found. Serum vitamin B₁₂ levels usually are less than 200 pg/ml. Magnetic resonance studies may show brain atrophy, which are signs of retarded myelination, with the frontal and temporal lobes affected most. Culture of skin fibroblasts may show reversible dysregulation of the mitochondrial adenosine triphosphatase synthetase. It has been suggested that the more severe brain changes associated with vitamin B₁₂ deficiency during infancy may be a result of the infant's rapid development of neuronal structures. These disorders usually respond to massive doses of B₁₂ (1,000 µg/day intramuscularly), but if undetected, death will usually occur in infancy.

In our case, the acute presentation of unexplained metabolic acidosis and neurologic deterioration, accompanied by an elevated mean corpuscular volume and thrombocytopenia was thought to be caused by nitrous oxide-induced exacerbation of a preexisting vitamin B₁₂ deficiency. The diagnosis of preexisting vitamin B₁₂ deficiency was supported by the findings of an increased mean corpuscular volume before craniostomy repair, coupled with the finding of a low maternal serum vitamin B₁₂ level.

Although adults depend on exogenous vitamin B₁₂, a deficient diet rarely is the cause of a deficiency state.⁵ Instead, gastric achlorhydria and decreased gastric secretion of intrinsic factor are more likely causes in adults. Other causes include postgastrectomy, intestinal bacterial overgrowth, and surgical disease or resection of the ileum. In the breast-fed infant the most common

cause of low serum vitamin B₁₂ is a maternal vitamin B₁₂ deficiency, especially in infants of vegan mothers.¹¹ Deficiency of intrinsic factor, disorders of absorption, inborn errors of transport, and intracellular use of vitamin B₁₂ also should be considered. In our case, the cause of the low serum vitamin B₁₂ was not established.

Our decision to avoid nitrous oxide for the second procedure was based on the concern that, despite large doses of daily vitamin B₁₂, the patient's serum levels remained abnormal. Experimental data suggests that the minimum duration and minimum exposure levels of nitrous oxide necessary to produce neurologic complications in humans is not known.¹² Consequently, the procedure was performed with use of an oxygen source, Mapleson D circuit, and intravenous anesthesia.

We conclude that the use of nitrous oxide in an infant with unexplained neurologic impairment possibly should be avoided, until vitamin B₁₂ deficiency can be ruled out. An infant that presents with an unexplained metabolic acidosis and neurologic defect several weeks after nitrous oxide general anesthesia should be evaluated for vitamin B₁₂ deficiency.

References

- O'Leary PW, Combs M, Schilling RF: Synergistic deleterious effect of nitrous oxide exposure and vitamin B₁₂. *J Lab Clin Med* 1985; 4:428-31
- Schilling RF: Is nitrous oxide a dangerous anesthetic for vitamin B₁₂ deficient subjects? *JAMA* 1986; 255:1605-6
- Riedel B, Fiskerstrand T, Refsum H, Ueland PM: Coordinate variations in methylmalonyl-CoA mutase and methionine synthase, and the cobalamin cofactors in human glioma cells during nitrous oxide exposure and the subsequent recovery phase. *Biochem J* 1999; 341:133-8
- Kinsell LJ, Green R: Nitrous oxide induced cobalamin deficiency. *Neurology* 1995; 45:1608-10
- Hadzic A, Glab K, Sanborn KV, Thys DM: Severe neurologic deficit after nitrous oxide anesthesia. *ANESTHESIOLOGY* 1995; 83:863-6
- Lee P, Smith I, Piesowicz A, Brenton D: Spastic paraparesis after anaesthesia. *Lancet* 1999; 353:554
- Rosenblath DS, Whitehead VM: Cobalamin and folate deficiency: Acquired and hereditary disorders in children. *Semin Hematol* 1999; 36:19-34
- Haurani FI, Kauh YS, Abboud EM: Methylcobalamin corrects the deleterious in vitro effect of nitrous oxide on thymidylate synthase. *Mol Cell Biochem* 1985; 65:153-7
- Stabler SP, Allen RH, Fried LP, Pahor M, Kittner SJ, Pennix BW, Guralnik JM: Racial differences in prevalence of cobalamin and folate deficiencies in disabled elderly women. *Amer J Clin Nutr* 1999; 70:911-9
- Russo P, Doyon J, Sonsino E, Ogier H, Saudubray JM: A congenital anomaly of vitamin B₁₂ metabolism: A study of three cases. *Hum Pathol* 1992; 23:504-11
- Kuhne T, Bubl R, Baumgartner R: Maternal vegan diet causing a serious infantile neurological disorder due to vitamin B₁₂ deficiency. *Eur J Pediatr* 1991; 150:205-8
- Sweeney B, Bingham RM, Amos RJ, Petty CA, Cole VP: Toxicity of bonmarrow in dentists exposed to nitrous oxide. *BMJ* 1985; 291:567-9