

Rhabdomyolysis following Cardiopulmonary Bypass and Treatment with Enoximone in a Patient Susceptible to Malignant Hyperthermia

Friedrich-Christian Riess, M.D.,* Marko Fiege, M.D.,† Sina Moshar, M.D.,‡ Heinz Bergmann, M.D.,§ Niels Bleese, M.D.,|| Joachim Kormann, M.D.,# Ralf Weißhorn, M.D.,† Frank Wappler, M.D.††

SEVERE hypercapnia, muscle rigidity, hyperthermia, and rhabdomyolysis characterize malignant hyperthermia (MH) in fulminant form.¹ However, during cardiac operations using cardiopulmonary bypass (CPB), typical symptoms of MH may not be present. We observed a patient undergoing aortic valve replacement, in whom severe postoperative rhabdomyolysis and arrhythmias developed after treatment with enoximone during CPB and cardioplegic arrest. Subsequently, *in vitro* contracture testing showed that the patient was susceptible to MH.

Case Report

A 48-yr-old man (weight, 92 kg; height, 169 cm) was scheduled to undergo aortic valve replacement. Family history was unremarkable. No allergies to medications were known. There was no history of surgery or anesthesia. Enalapril (Pres; Boehringer, Ingelheim, Germany) 10 mg/day was the only preoperative medication. Laboratory data were normal except for a γ glutamate transferase of 41 U/l (normal, < 28). Creatine kinase (CK) concentration was 53 U/l.

The patient received 2 mg flunitrazepam (Rohypnol; Hoffmann-La Roche, Basel, Switzerland) orally the evening before surgery and another 2 mg flunitrazepam and 0.3 mg clonidine (Catapresan; Boehringer) orally on the morning of surgery. Anesthesia was induced using 1 mg/kg intravenous propofol (Disoprivan; Zeneca, Plankstadt, Germany) and 25 μ g intravenous sufentanil (Sufenta; Janssen, Neuss, Germany), muscle relaxation was achieved using 0.2 mg/kg intravenous pancuronium bromide (Pancuronium; Curamed Schwabe, Karlsruhe, Germany).

Anesthesia was maintained using propofol ($4 \text{ mg} \cdot \text{kg}^{-1} \cdot \text{h}^{-1}$) and sufentanil ($0.5 \text{ } \mu\text{g} \cdot \text{kg}^{-1} \cdot \text{h}^{-1}$). The patient received 2 g cephazolin sodium (Gramaxin; Boehringer, Mannheim, Germany) intravenously. A membrane oxygenator (Quadrox; Jostra, Hirrlingen, Germany) was used together with a roller pump. The priming solution of CPB (1,600 ml) contained lactated Ringer's solution, mannitol (15%), and sodium bicarbonate, and 5,000 IU unfractionated heparin (Heparin Braun; Braun Melsungen, Melsungen, Germany) and aprotinin (Antagosan; Behringwerke AG, Marburg, Germany). Standard CPB was established with a flow rate of $2.5 \text{ l} \cdot \text{min}^{-1} \cdot \text{m}^{-2}$, which was reduced during hypothermia to $2.0 \text{ l} \cdot \text{min}^{-1} \cdot \text{m}^{-2}$ at 34.2°C (rectal temperature).

* Associate Professor of Cardiac Surgery, ‡ Resident, || Professor and Head, Department of Cardiac Surgery, § Staff Anesthesiologist, Department of Anesthesiology, # Anesthesiologist and Head, Department of Cardiac Anesthesiology, Albertinen-Hospital. † Staff Anesthesiologist, †† Associate Professor of Anesthesiology, Department of Anesthesiology, University-Hospital Eppendorf.

Received from the Departments of Cardiac Surgery, Anesthesiology, and Cardiac Anesthesiology, Albertinen-Hospital, Hamburg, Germany, and the Department of Anesthesiology, University-Hospital Eppendorf, Hamburg, Germany. Submitted for publication December 28, 1999. Accepted for publication May 24, 2000. Support was provided solely from institutional and/or departmental sources.

Address reprint requests to Dr. Riess: Department of Cardiac Surgery, Albertinen-Hospital, Suentelstrasse 11 a, 22457 Hamburg, Germany. Address electronic mail to: herzchirurgie@albertinen.de. Individual article reprints may be purchased through the Journal Web site, www.anesthesiology.org.

After implantation of a mechanical valve (Medtronic Hall; Medtronic, Minneapolis, MN), the ascending aorta was closed and the aortic cross-clamp removed. During reperfusion, the patient exhibited ST elevations, with maximal values of 12 mV in all leads. The left ventricle appeared to be ischemic and hypokinetic. A triple bypass was performed using saphenous grafts to the left anterior descending, first diagonal branch and the circumflex artery. The patient was then successfully weaned from CPB using a moderate dose of adrenalin ($1 \text{ } \mu\text{g}/\text{min}$) and 50 mg enoximone (Perfan; Hoechst, Bad Soden am Taunus, Germany). However, toward the completion of the operation, the urine became dark and the minute ventilation necessary to maintain normocapnia were increased from 8 to $14.2 \text{ l}/\text{min}$, whereas pH decreased to 7.19.

On the first postoperative day, a potassium concentration of 6 mmol/l and a CK concentration of 9,348 U/l, and an increase of creatinine concentration to 2.5 mg/dl were noted. Rectal temperatures remained normal. Ventricular arrhythmias and atrial fibrillation occurred on the second postoperative day, and administration of increasing amounts of intravenous adrenalin was necessary to achieve hemodynamic stability. A serum myoglobin concentration of 8,887 $\mu\text{g}/\text{l}$ was noted. There were no signs of compartment syndrome in any extremity. Because malignant hyperthermia was suspected, the patient was treated with 220 mg dantrolene (Dantrolen; Procter & Gamble Pharmaceuticals, Weiterstadt, Germany) intravenously. The hemodynamic profile of the patient improved, and catecholamine therapy could be discontinued. Because of renal impairment, hemofiltration was started and was continued for 19 days. On the third postoperative day, a second dose of 25 mg enoximone was administered. Shortly thereafter, partial pressure of carbon dioxide (Pco_2) increased to 48.3 mmHg during mechanical ventilation, and CK concentration increased to 9,348 U/l. This response was treated again with 220 mg dantrolene intravenously. Patient serum muscle enzyme concentrations gradually returned to normal, and he was discharged in good condition on the thirty-third postoperative day.

Five months postoperatively, the patient was examined for malignant hyperthermia susceptibility and other muscular diseases. After the patient had given informed consent, muscle biopsy was performed using regional anesthesia. The muscle bundle was excised carefully from the vastus lateralis muscle, and an additional small muscle sample was obtained for evaluation of histomorphologic changes.

The *in vitro* contracture tests (IVCTs) with halothane and caffeine were performed according to the protocol of the European Malignant Hyperthermia Group (EMHG).² The muscle bundle was dissected into eight strips. Only viable muscle samples (twitch response to supra-maximal electrical stimulation > 10 mN) were used. Two samples were tested with each drug. The muscle specimens of this patient developed abnormal contracture responses to 0.44 mm halothane and 2.0 mm caffeine, indicating susceptibility to MH. After administration of 1 μM ryanodine, an accelerated and increased contracture development was observed.³ The contracture test results are presented in table 1.

Two additional muscle samples were tested using enoximone. The IVCTs were performed with cumulative administration of enoximone in concentrations of 0.2, 0.4, 0.6, 0.8, 1.2, and 1.6 mm, and as a bolus administration of 0.6 mm enoximone, as described previously.⁴ The original tracings of the enoximone-IVCTs are shown in figure 1. In the

Table 1. Results of the *In Vitro* Contracture Tests with Halothane, Caffeine, and Enoximone in the MHS Patient and Normal Results in MHS and MHN Patients

Test Substance	Concentrations (mM)	Muscle Twitch at Start (mN)	Substance Concentration (Contracture \geq 2 mN) (mM)	Normal Values: Substance Concentration (Contracture \geq 2 mN) (mM)	
				MHS	MHN
Halothane (1)	0.11, 0.22, 0.44	208	0.44	\leq 0.44	$>$ 0.44
Halothane (2)	0.11, 0.22, 0.44	80	0.44	\leq 0.44	$>$ 0.44
Caffeine (1)	0.5, 1.0, 1.5, 2.0, 3.0, 4.0, 32.0	202	2.0	\leq 2.0	$>$ 2.0
Caffeine (2)	0.5, 1.0, 1.5, 2.0, 3.0, 4.0, 32.0	104	3.0	\leq 2.0	$>$ 2.0
Enoximone (cumulative)	0.2, 0.4, 0.6, 0.8, 1.2, 1.6	84	0.6	\leq 0.6	$>$ 0.6
Enoximone (bolus)	0.6	85	Contracture maximum 23.4 mN	Contracture \geq 2 mN	Contracture $<$ 2 mN

MHS = malignant hyperthermia-susceptible; MHN = malignant hyperthermia-normal.

IVCTs with cumulative enoximone administration, the muscle sample showed contracture development at a concentration of 0.6 mM enoximone. Moreover, a single bolus administration of 0.6 mM enoximone induced a contracture maximum of 23.4 mN. Both results are comparable with findings from MH-susceptible muscle fascicles in the different IVCTs with enoximone.⁵ Histomorphologic evaluation was performed for the additional muscle sample; all investigations of this muscle specimen (*e.g.*, morphometry, immunohistochemistry, fiber size, and ratio analysis) showed normal findings.

Preparation of DNA and oligonucleotides, genotyping, and detection of mutations in the ryanodine receptor gene were performed as described previously.⁶ Mutation screening led to the discovery of a substitution of A for G7297. The patient was heterozygous for this mutation. This mutation results in the substitution of arginine for

glycine in position 2433, which was shown to be associated with malignant hyperthermia.⁶

Discussion

In this unusual case, two MH-like episodes developed in a patient after cardiac operation with CPB and concomitantly after the administration of the phosphodiesterase-III (PDE-III) inhibitor enoximone. The patient was not administered any of the known trigger substances of MH,¹ such as volatile anesthetics or succinylcholine. None of the substances administered to the patient con-

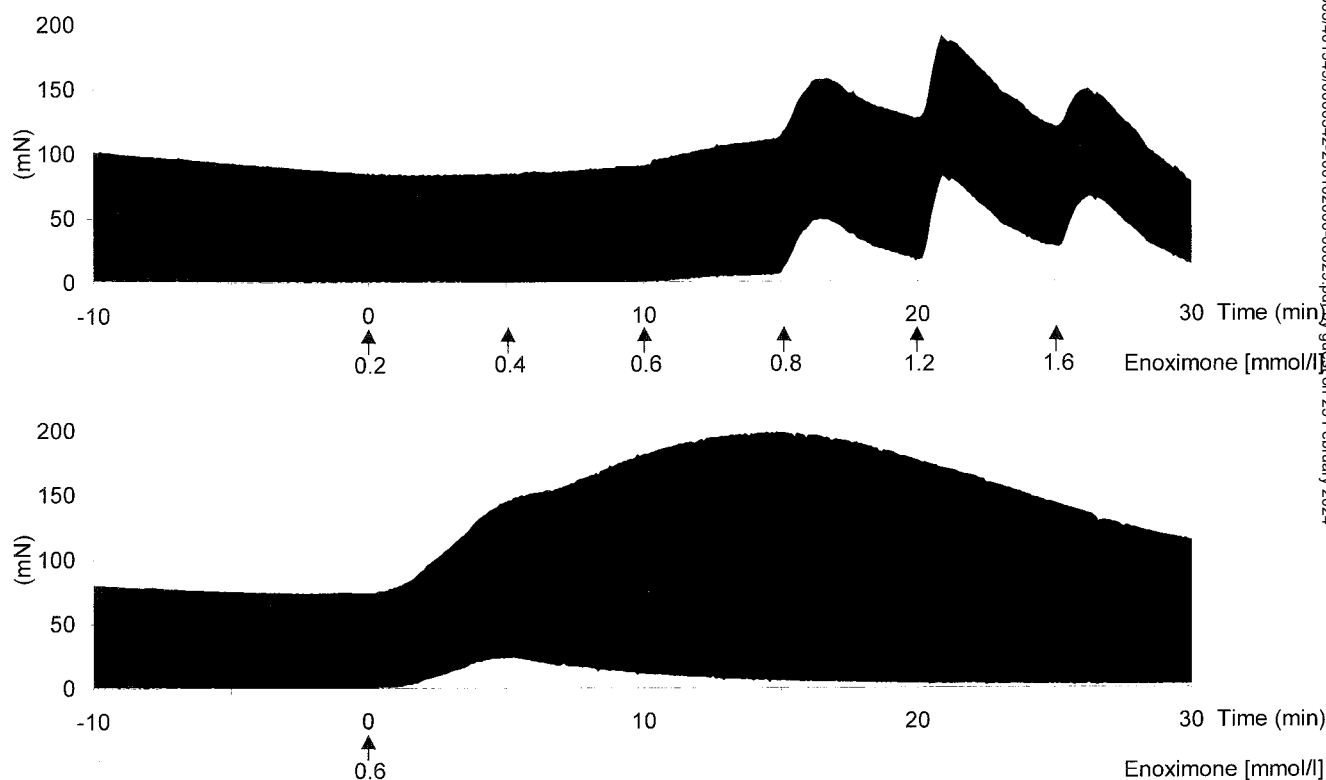


Fig. 1. Effects of cumulative administration (*upper*, 0.2–0.4–0.6–0.8–1.2–1.6 mM) and bolus administration (*lower*, 0.6 mM) of enoximone on contracture development in two skeletal muscle specimens of this malignant hyperthermia-susceptible patient. For normal values, see table 1.

tained 4-chloro-m-cresol, a preservative with MH-trigger potency.⁷ Both treatments with dantrolene were successful and the patient recovered completely. Five months later, susceptibility to MH was diagnosed by use of IVCTs with halothane and caffeine. The diagnosis was supported by the detection of the G7297A mutation, which is known to be associated with MH susceptibility. Furthermore, skeletal muscle specimens showed altered contracture responses in IVCTs with enoximone. Although the trigger mechanisms of the MH-like episodes in this patient remain unclear, it could be suggested that enoximone potentiated a current myotoxic reaction or maybe was the MH-triggering agent alone.

The PDE-III inhibitors are substances with receptor-independent, positive inotropic effects on cardiac muscle. PDE-III inhibitors act by decreasing the rate of cyclic adenosine monophosphate (cAMP) degradation. The cAMP activates protein kinase A, which results in altered transport rates of different intracellular calcium channels. In cardiac muscle cells, the main effect of PDE-III inhibition is an increased sarcoplasmic calcium release via the ryanodine receptor.^{8,9} Additionally, PDE-III-inhibiting compounds can sensitize the myofibrils to calcium and enhance the cardiac calcium release channel.

Phosphorylation of the skeletal muscle ryanodine receptor by intracellular PDE-III inhibition modulates the calcium release only slightly.⁹ However, previous studies have shown enoximone-induced contracture development in human skeletal muscles *in vitro*.^{4,5} These muscle contractures started at lower enoximone concentrations and were greater in preparations from MH-susceptible patients than from MH-normal patients. The authors suggested from their investigations that enoximone might be a trigger substance of MH. We performed IVCTs with enoximone in muscle preparations from our patient. In the two tests, the muscle specimens developed marked contractures at a concentration of 0.6 mM enoximone, which was comparable with the results from MH-susceptible patients in previous studies.^{4,5}

The cAMP system seems to play a role in pathogenesis of MH. In skeletal muscle cells from MH-susceptible patients, higher cAMP concentrations could be measured and compared with concentrations from MH-normal patients.¹⁰ Furthermore, during and after physical exercise, the cAMP concentrations in blood serum increased to a higher extent and were more prolonged in MH-susceptible than in MH-normal patients.¹¹ However, the triggering mechanism of MH, the defect in all human MH cases, and the variability of clinical presentation is not clear. Administration of PDE-III inhibitors to MH-susceptible patients might enhance intracellular release of Ca²⁺ and potentiate an MH crisis. However, MH is a heterogenous disorder, and possibly PDE-III inhibitors have an MH-trigger potency in some MH patients.

Rhabdomyolysis during or after CPB is not uncommon.^{12,13} Preoperative medication seems to be causative

with certain preparations. Hydroxymethylglutaryl-coenzyme A reductase inhibitors are substances with known myotoxic side effects, and several cases of rhabdomyolysis after CPB have been reported as a result of administration of hydroxymethylglutaryl-coenzyme A.¹² A retrospective analysis of 931 patients undergoing major cardiac surgery identified risk factors for rhabdomyolytic acute renal failure associated with surgical procedure.¹³ A correlation of rhabdomyolysis and direct femoral artery cannulation, arteriopathy, prolonged extracorporeal circulation, low cardiac output syndrome, and continuous intravenous infusion of epinephrine could be shown. A range of relevant causes of rhabdomyolysis during surgery has been identified.¹⁴

Although rhabdomyolysis can occur from various sources during CPB, the direct effect of enoximone in inducing contracture behavior in isolated skeletal muscle suggests that activation of an MH episode probably is a cause in this case. Further *in vivo* investigations should determine the MH trigger potency of enoximone. Administration of enoximone to MH-susceptible patients might be dangerous and should be performed with care.

References

- Gronert GA, Antognini JF, Pessah IN: Malignant hyperthermia, Anesthesiology 5th edition. Edited by Miller RD. New York, Churchill Livingstone, 2000, pp 1033-52
- Ørding H, Brancadoro V, Cozzolino S, Ellis FR, Glauber V, Gonano EF, Halsall PJ, Hartung E, Heffron JJ, Heytens L, Kozak-Ribbens G, Kress H, Krivosic Horber R, Lehmann-Horn F, Mortier W, Nivoche Y, Ranklev-Twetman E, Sigurdsson S, Snoeck M, Stieglitz P, Tegazzin V, Urwyler A, Wappler F: In vitro contracture test for diagnosis of malignant hyperthermia following the protocol of the European MH Group: Results of testing patients surviving fulminant MH and unrelated low-risk subjects. Acta Anaesthesiol Scand 1997; 41:955-66
- Wappler F, Roewer N, Köchling A, Scholz J, Steinfath M, Schulte am Esch J: In vitro diagnosis of malignant hyperthermia susceptibility with ryanodine-induced contractures in human skeletal muscles. Anesth Analg 1996; 82:1230-4
- Fiege M, Wappler F, Scholz J, von Richthofen V, Schulte am Esch J: Diagnosis of disposition to malignant hyperthermia by an in vitro contracture test with phosphodiesterase-III-inhibitor enoximone. Anästhesiol Intensivmed Notfall- und Schmerzther 1998; 33:557-63
- Fiege M, Wappler F, Scholz J, Weisshorn R, von Richthofen V, Schulte am Esch J: Effects of the phosphodiesterase-III-inhibitor enoximone on skeletal muscle specimens from malignant hyperthermia susceptible patients. J Clin Anesth 2000; 12:123-8
- Phillips MS, Khanna VK, De Leon S, Frodis W, Britt BA, MacLennan DH: The substitution of Arg for Gly2433 in the human skeletal muscle ryanodine receptor is associated with malignant hyperthermia. Hum Mol Genet 1994; 3:2181-6
- Wappler F, Scholz J, Fiege M, Kolodzie K, Kudlik C, Weisshorn R, Schulte am Esch J: 4-chloro-m-cresol is a trigger of malignant hyperthermia in susceptible swine. ANESTHESIOLOGY 1999; 90:1733-40
- Holmberg SRM, Williams AJ: Phosphodiesterase inhibitors and the cardiac sarcoplasmic reticulum calcium release channel: Differential effects of milrinone and enoximone. Cardiovasc Res 1991; 25:537-45
- Strand MA, Louis CF, Mickelson JR: Phosphorylation of the porcine skeletal and cardiac muscle sarcoplasmic reticulum ryanodine receptor. Biochim Biophys Acta 1993; 1175:319-26
- Willner JH, Cerri CG, Wood DS: High skeletal muscle adenylate cyclase in malignant hyperthermia. J Clin Invest 1981; 68:1119-24
- Staneć A, Stefano G: Cyclic AMP in normal and malignant hyperpyrexia susceptible individuals following exercise. Br J Anaesth 1984; 56:1243-6
- Waldhans S, Vogt S, Moosdorf R: Rhabdomyolysen nach Operationen mit Einsatz der Herz-Lungen-Maschine bei präoperativer Medikation mit HMG-CoA-Reduktasehemmern. Z Herz Thorax Gefäßschir 1998; 12:201-5
- Maccario M, Fumagalli C, Dottori V, Grasso AM, Agostini M, Parodi E, Pergolo A, Spagnolo S, Passerone G: The association between rhabdomyolysis and acute renal failure in patients undergoing cardiopulmonary bypass. J Cardiovasc Surg (Torino) 1996; 37:153-9
- Slater MS, Mullins RJ: Rhabdomyolysis and myoglobinuric renal failure in trauma and surgical patients: A review. J Am Coll Surg 1998; 186:693-716

Delayed Subdural Block after a Stellate Ganglion Block

Michael S. Leong, M.D.,* Sean Mackey, M.D., Ph.D.*

STELLATE ganglion blockade (SGB) is an accepted method to diagnose and treat patients with complex regional pain syndromes (CRPS) and other sympathetically mediated pain states.¹ At our institution, we use the anterior paratracheal technique described by Carron and Litwiller² commonly. By establishing contact with the transverse process of C6 (the Chassaignac tubercle), the risk of damage to the pleura and the vascular structures is reduced. Procedural complications can occur and include recurrent laryngeal nerve block, hematoma, brachial plexus motor blockade, phrenic nerve block, pneumothorax, vertebral artery injection, and subarachnoid and epidural injection and osteitis.¹

We report a case of a young woman with CRPS type 1 (or reflex sympathetic dystrophy) who developed neurologic symptoms of an incomplete spinal anesthetic 1 h after SGB.

Case Report

A 34-yr-old woman with CRPS type I of her right upper extremity presented for elective SGB. She had been treated since 1996 for CRPS, which followed an industrial injury in 1993. At the time of her initial examination, she had limited function of her right upper extremity, and her treatment during a 2-yr period of time included tricyclic antidepressants, intravenous lidocaine, and opiates, but little functional improvement was made. She did, however, obtain significant subjective pain relief with decreased swelling of her hand and arm for 3-5 months from intermittent SGBs using 0.25-0.5% bupivacaine (12-15 ml). Her medical history was unremarkable, and her medications included amitriptyline, hydrocodone-acetaminophen (5/500), and naproxen. Her weight and height were 89 kg and 86.5 cm, respectively. Preoperative blood pressure was 115/72 mmHg, and heart rate was 75 beats/min. Physical examination was notable for an anxious appearance, her right arm held close to her chest, and her elbow flexed 90°. Allodynia to light touch was present from her fingers to her elbow in a glove distribution.

After informed consent, a peripheral intravenous catheter was inserted in her left hand. Blood pressure, oxygen saturation (SpO₂), electrocardiography, and temperatures of the dorsum of each hand were monitored, and verbal feedback was maintained throughout the procedure. Sedation with 50 µg intravenous fentanyl and 2 mg intravenous midazolam was provided.

After sterile preparation of her neck with povidone-iodine (swab

sticks), the transverse process of C6 was identified easily by palpation, using the cricoid cartilage as a landmark. A 22-gauge A-beveled needle was inserted using the anterior paratracheal approach until contact with the periosteum was made. The needle was then withdrawn 1-2 mm, and, after negative aspiration, 3 ml bupivacaine, 0.25%, was injected. After 2 min and no hemodynamic or neurologic changes, needle contact with the periosteum was reestablished. After again withdrawing 1-2 mm and after negative aspiration, 5 ml bupivacaine, 0.25%, was injected. This maneuver was repeated once more until 1 ml bupivacaine, 0.25%, was injected. The patient was placed in sitting position, and the onset of right-sided Horner syndrome, a decrease in pain in the right hand and arm, and a 2°C increase in the right hand temperature from a baseline of 35°C were noted within approximately 10 min after completion of the procedure. During the next 4 min, blood pressure remained stable (systolic blood pressure, 120-130 mmHg; diastolic blood pressure, 60-75 mmHg); however, her pulse rate slowly increased from 65 to 102 beats/min. She noted no subjective changes. In anticipation for discharge from the hospital, the patient walked to the restroom and changed into her street clothes. When walking back to check out of the postanesthesia care unit (6 min after SGB), she reported dizziness and weakness in her right leg. She was placed on a gurney, and standard monitors were applied. Her initial blood pressure was 140/80 mmHg, and her pulse was 85 beats/min. During the next 3 min, she became progressively more confused, unresponsive to verbal commands, and diaphoretic. An episode of hypotension with a mean arterial pressure of 55 mmHg occurred, which was treated with 500 ml NaCl and intravenous ephedrine (16 mg). Her mental status cleared over the next several minutes. During this period, serial physical examinations revealed a progressive loss of strength and sensation in both lower extremities, the trunk, and the right upper extremity. The lower extremities were both flaccid, with loss of deep tendon reflexes. Her left upper extremity strength, sensation, and reflexes were normal. She reported mild dyspnea and being unable to move anything other than her left upper extremity, of which she had complete control. Her dystrophic right upper extremity was ranged gently, without evidence of discomfort. Spontaneous ventilation was maintained with adequate but shallow tidal volumes. A chest radiograph was obtained to evaluate for possible pneumothorax, revealing hypoventilated lungs but no other acute changes. Neurosurgical evaluation was obtained and agreed with our preliminary diagnosis of inadvertent centriaxial blockade from the SGB. A computed tomography scan of the head and a cervical spine magnetic resonance imaging were obtained to evaluate for possible intracranial process, vertebral artery vasospasm or injury, or cervical epidural hematoma. These images were evaluated as normal.

The patient was closely monitored for 3 h, with no changes in the level of the presumed block and with stable vital signs. She was admitted to an intermediate care hospital bed. Approximately 10 h after the SGB, she noted a gradual return of sensation and motor function in her extremities. The next morning, or 16 h after the SGB, her physical examination results were at baseline, and she was discharged home. She noted significant reduction in her CRPS for the next 4 months.

Discussion

Neurologic changes beginning 1 h after procedure have not been reported previously. After an extensive

* Assistant Professor of Anesthesiology.

Received from the Department of Anesthesiology, Division of Pain Management, Stanford University School of Medicine, Stanford, California. Submitted for publication September 20, 1999. Accepted for publication July 26, 2000. Support was provided solely from institutional and/or departmental sources.

Address reprint requests to Dr. Leong: Department of Anesthesiology, H-3586, Stanford University Medical Center, Stanford, California 94305. Address electronic mail to: msleong@stanford.edu. Individual article reprints may be purchased through the Journal Web site, www.anesthesiology.org.

workup, including diagnostic imaging studies, the possibility of a conversion reaction was considered. This diagnosis seemed unlikely because the patient allowed her affected arm to be moved throughout a normal range of motion, without any evidenced pain behavior. Further, she had no spontaneous movement of her lower extremities, absent deep tendon reflexes, and no response to noxious stimuli.

Few references have been published regarding conversion reactions in chronic pain patients. One case report involves a conversion reaction initially diagnosed as trigeminal neuralgia.³ The diagnosis of conversion reaction was determined after a response to edrophonium and after taking a global view of the total clinical course. Because our patient never had these responses to stellate blocks in the past and her neurologic symptoms resolved without any sequelae, the diagnosis of conversion reaction seems even more unlikely.

We believe this patient sustained a subdural injection. Mechanisms proposed by Bruyns *et al.*⁴ include the following: (1) improper needle placement directed intrathecally through the intervertebral foramen, (2) a dural cuff that may accompany a nerve root distal to the intervertebral foramen, and (3) a perineural injection that may diffuse back into the subarachnoid space. This last mechanism could account for a long onset time, would involve a depot of local anesthetic, and would necessitate a large dose to be clinically important. Wulf *et al.*⁵ have reported that 3 of 10 patients who were administered a stellate ganglion block with 10 ml bupivacaine, 0.5%, had maximum concentrations exceeding 2 $\mu\text{g}/\text{ml}$, which is more than the reported toxic concentration of 1.5 $\mu\text{g}/\text{ml}$. The dosage used in this case was 13 ml bupivacaine, 0.25%, which is well below a dosage that would normally cause toxic blood concentrations.

Subdural block may account for the time course and unusual symptoms consistent with a high central neuraxial block.⁶⁻⁸ The subdural space is a potential space between the dura and arachnoid membranes that contains a small amount of serous fluid and has been confirmed with clinical presentation *via* computed tomography and magnetic resonance imaging.^{8,9} Dorsal and lateral spread is seen more commonly with pathologic examination using intravenous contrast. Subsequently, more sensory and sympathetic block is noted than motor blockade. The onset of subdural blockade is 5-30 min after injection. Hypotension may be associated with subdural blockade and may be profound but is usually easier to treat than subarachnoid blockade.

The incidence of these late neurologic complications after SGB is unknown. It is unclear what signs or symptoms are predictive of possible neurologic complica-

tions. There has been a previous description of an inadvertent subdural stellate block with symptoms occurring suddenly, within 5 min of the procedure.⁴ Another case report involving subdural anesthesia after an interscalene block had a similar presentation but started 20 min after completion of injection.¹⁰ In our case, the symptoms occurred 45 min after the conclusion of the procedure.

Currently, our postrecovery period for SGB is 1 h. Standard monitoring, such as continuous electrocardiography, pulse oximetry, and intermittent noninvasive blood pressure monitoring, is essential. Nevertheless, no predictors were present for the profound sequelae this patient experienced. Patients who are administered stellate ganglion blocks are not discharged earlier than 1 h secondary to this incident. Each institution should make its own determination as to whether the added cost associated with extra postoperative recovery time is justified by the low incidence of this occurrence.

It is not known whether repeat stellate blockade can predispose a patient to the risk of subdural injections. Further, for difficult patients with redundant subcutaneous tissue, should more specific techniques, such as real-time magnetic resonance imaging, be used to track the accuracy of placement and spread of local anesthetics?¹¹⁻¹³

References

1. Breivik H, Cousins M, Löfström J: Sympathetic neural blockade of upper and lower extremity. *Neural Blockade in Clinical Anesthesia and Management of Pain*, 3rd edition. Edited by Cousins MJ, Bridenbaugh PO. Philadelphia, JB Lippincott, 1998, pp 411-47
2. Carron H, Litwiller R: Stellate ganglion block. *Anesth Analg* 1975; 54:567-70
3. Yokono A, Yokono S, Ogli K, Yamanobe K, Knodo A: A case of hysterical conversion manifested by pain in face and head. *Masui* 1991; 40:306-12
4. Bruyns T, Devulder J, Vermeulen H, De Colvenaer L, Rolly G: Possible inadvertent subdural block following attempted stellate ganglion blockade. *Arch Anaesthesia* 1991; 46:747-9
5. Wulf H, Maier C, Schele HA, Wabbel W: Plasma concentration of bupivacaine after stellate ganglion blockade. *Anesth Analg* 1991; 71:546-8
6. Reynolds F, Speedy H: The subdural space: The third place to go astray. *Anaesthesia* 1990; 45:20-3
7. Asato F, Nakatani K, Matayoshi Y, Katekawa Y, Chinen K: Development of a subdural motor blockade. *Anaesthesia* 1993; 48:46-9
8. Gershon R: Surgical anaesthesia for Caesarean section with a subdural catheter. *Can J Anaesth* 1996; 43:1068-71
9. McMenemin I, Sissons G, Brownridge P: Accidental subdural catheterization: Radiological evidence of a possible mechanism for spinal cord damage. *Br J Anaesth* 1992; 69:417-9
10. Tetzlaff J, Yoon H, Dilger J, Brems J: Subdural anesthesia as a complication of an interscalene brachial plexus block. *Reg Anesth* 1994; 19:357-9
11. Ralph C, Williams M: Subdural or epidural? Confirmation with magnetic resonance imaging. *Anaesthesia* 1996; 51:175-7
12. Hogan QH, Erickson SJ, Haddox JD, Abram SE: The spread of solutions during stellate ganglion block. *Reg Anesth* 1992; 17:78-83
13. Slappendel R, Thijssen, HO, Crul, BJ, Merx JL: The stellate ganglion in magnetic resonance imaging: A quantification of the anatomic variability. *ANESTHESIOLOGY* 1995; 83:424-6
14. Wallace MS, Milholland AV: Contralateral spread of local anesthetic with stellate ganglion block. *Reg Anesth* 1993; 18:55-9
15. Hogan QH, Erickson SJ: MR imaging of the stellate ganglion: Normal appearance. *Am J Roentgenol* 1992; 158:655-9

Volume of Air in a Lethal Venous Air Embolism

Thomas J. K. Toung, M.D.,* Mark I. Rossberg, M.D.,† Grover M. Hutchins, M.D.‡

THE morbidity and mortality rates from venous air embolism is determined by the volume of air entrained, the rate of entrainment, and the position and the cardiac status of the patient. As early as 1809, Nysten¹ estimated the lethal dose of air to be 40–50 ml in a small dog and 100–120 ml in a large dog. The exact amount, 7.5 ml/kg, however, was not determined in dogs until 1953 by Oppenheimer *et al.*² In 1963, Munson *et al.*³ demonstrated a lethal volume of only 0.55 ml/kg in rabbits. The lethal volume of air in an adult human is unknown but is estimated to range from 200 to 300 ml. These numbers are derived from the cases of fatalities reported by Martland,⁴ Yeakel,⁵ and Flanagan.⁶ We report herein a case of

Case Report

A 71-yr-old, 68 kg, 173-cm man was admitted to the hospital because of congestive heart failure. Treatment included administration of diuretics and digitalis. Physical examination showed that the patient had cardiomegaly, hepatomegaly, ascites, and pitting edema. A chest radiograph confirmed marked cardiomegaly and a heart scan showed pericardial effusion. In the radiology suite, the patient was placed in a semi-Fowler position. Standard monitoring of electrocardiography (ECG) and blood pressure was used. A subxyphoid pericardiocentesis was performed using a No. 14 Jelco intracath, yielding 175 ml serosanguinous fluid with a specific gravity of 1.015, an erythrocyte count of 74,000/mm³, and 145 leukocytes/mm³. Results of the culture and cytology studies of the fluid were negative. Five days later, repeat chest radiography showed reaccumulation of pericardial fluid. Repeat pericardiocentesis was attempted and abandoned after the withdrawal of 75 ml bloody fluid. Pericardiocentesis was performed again 5 days later. Four hundred sixty milliliters of bloody fluid was removed and 250–300 ml air were injected through the catheter for pneumopericardiography. A week later, repeat pericardiocentesis was performed in the radiology suite. Bloody fluid, 450 ml, was aspirated without difficulty. For pneumopericardiography, 200 ml air was injected over 3–5 s through the catheter without difficulty. However, almost immediately, the patient became restless, apneic, and opisthotonic. ECG showed marked depression of ST segments with varying degrees of atrioventricular block. The procedure was discontinued. The patient was intubated and external cardiac massage was started. Resuscitation was unsuccessful and the patient died.

Autopsy was performed 3 h after death. There were no postmortem changes in organs or tissue. Because of the possibility of air embolism,

water was placed between the skin flap and chest wall in the axillary region. No air escaped from either the right or the left pleura cavity. The pericardial cavity contained no air. There were 800 ml blood and several large blood clots in the pericardial cavity. Extensive fibrous adhesions existed between the pericardium and the epicardium. The right ventricle was distended with air. There were two fresh and three healing 1-mm slits grouped in a 1-cm radius in the serosal surface of the anterior myocardium of the right ventricle corresponding to the slit in the pericardium. The pericardial cavity was filled with water. When a hole was made in the anterior aspect of the pulmonary artery 1 cm above the pulmonary valve, air bubbles escaped. Both the right and the left ventricles were moderately enlarged because of hypertrophy. The foramen ovale was probe patent but was closed with a flap-like septum primum. Tricuspid valves were normal. No air was present on the left side of heart or the coronary arteries. Further dissection of the fixed gross specimen showed again needle-sized perforations on the external and internal surfaces of the right ventricle. There was a sinus tract through the myocardium, connecting the two perforations. Both lungs were emphysematous. No other specific lesions were recognized. The other organs, including the brain, were grossly and microscopically normal.

Discussion

The minimum volume of air lethal to human beings has not been established. Martland⁴ reported two fatal cases of venous air embolism that occurred during vaginal powder insufflation treatment for trichomonas infections. The total volume of air was estimated to be approximately 300 ml because six compressions of the insufflator bulb, the same number of compressions of the bulb used in the treatments, displaced 300 ml water. In the reported cases, both veins of the broad ligaments, the inferior vena cava, and the right side of the heart were distended and contained numerous air bubbles. Yeakel⁵ reported a case of lethal air embolism that occurred during blood transfusion *via* a pressurized, plastic, blood container. The exact amount of entrapped air in the bag that was forced into the patient's vein is unknown, but was estimated to be approximately 200 ml, based on retrospective experiments. Flanagan *et al.*⁶ reported a case of lethal complication of air embolism as a result of subclavian venipuncture. During Intracath insertion through a 14-gauge needle while the patient was in the semi-Fowler position, a rush of air was heard at the needle and the patient died within 5 min. To duplicate the clinical situation, the authors conducted an animal experiment. Based on their experiment, they found the volume flow rate of air able to be passed through a 14-gauge needle to be approximately 100 ml/s. Because it took only 1 to 2 s for insertion of the Intracath after the removal of the syringe from the needle, they estimated the

* Associate Professor, † Assistant Professor, Department of Anesthesiology and Critical Care Medicine, ‡ Professor, Department of Pathology.

Received from the Departments of Anesthesiology and Critical Care Medicine and Pathology, The Johns Hopkins Medical Institutions, Baltimore, Maryland. Submitted for publication May 1, 2000. Accepted for publication August 22, 2000. Support was provided solely from institutional and/or departmental sources.

Address reprint requests to Dr. Toung: The Johns Hopkins Medical Institutions, 600 North Wolfe Street, Meyer Building 8-134, Baltimore, Maryland 21287. Address electronic mail to: ttoung@jhmi.edu. Individual article reprints may be purchased through the Journal Web site, www.anesthesiology.org.

volume of air to be approximately 200 ml. Thus, all previous case reports are conjecture or attempts at an estimate of the volume of air that was introduced intravenously. In these reported cases, air entered through peripheral veins. Air bubbles were noted along the venous channels leading to the right side of the heart. The exact amount of air that caused the patient's death is probably less than the estimated amount.

The case presented herein is unique in that a known volume of air was introduced directly into the right ventricle, resulting in the death of the patient. Because no air was found in the pericardial cavity, one can assume that all air must have been injected directly into the right ventricle. Microscopically, no air bubbles were seen in the pulmonary vascular beds, coronary arteries, or cerebral arteries to indicate paradoxical air embolization. Only the right ventricle and pulmonary artery were distended and contained air bubbles. The proximate cause of death for this patient, therefore, is most likely a result of acute right ventricular outflow tract obstruction.

An important question relates to the effects of the patient's cardiac disease on the volume of air necessary to be considered lethal. Overdistension of the right ventricle and obstruction to pulmonary blood flow are the primary pathophysiologic causes of death as a result of

venous air embolism. It is possible that any impaired cardiac contractility in this patient may have decreased the volume of air necessary to produce cardiac arrest. Therefore, the lethal volume of air may be greater in adults with normal cardiac function.

In summary, estimates of 200–300 ml air have been reported to be lethal. This is the first report in an adult human to document an exact lethal volume of air, 200 ml (albeit in a patient with congestive heart failure), rather than to estimate retrospectively the lethal volume after the incident of fatal venous air embolism. It is still unclear whether this amount, 200 ml, represents the minimum volume of air considered to be lethal to healthy adult humans.

References

1. Green JS: On the air in the veins as a cause of death. *Am J Med Sci* 1864; 24:38–65
2. Oppenheimer MJ, Durant TM, Lynch P: Body position related to venous air embolism and associated cardiovascular-respiratory changes. 1953; 225:362–73
3. Munson ES, Merrick HC: Effect of nitrous oxide on venous air embolism. *ANESTHESIOLOGY* 1966; 27:783–7
4. Martland HS: Air embolism: fatal air embolism due to powder insufflation used in gynecological treatments. *Am J Surg* 1945; 68:164–9
5. Yeakel AE: Lethal air embolism from plastic blood-storage container. *JAMA* 1968; 204:267–9
6. Flanagan JP, Gradisar IA, Gross RJ, Kelly TR: Air embolus: A lethal complication of subclavian venipuncture. *N Engl J Med* 1969; 281:488–9

Anesthesiology 2001; 94:361–3

© 2001 American Society of Anesthesiologists, Inc. Lippincott Williams & Wilkins, Inc.

Ischemic Optic Neuropathy after Liver Transplantation

Piotr K. Janicki, M.D., Ph.D.,* Ram Pai, M.D.,† J. Kelly Wright, M.D.,‡ William C. Chapman, M.D.,‡
C. Wright Pinson, M.D., M.B.A.§

THE most commonly reported cause of sudden, devastating postoperative visual loss is anterior ischemic optic neuropathy (ION), resulting from decreased oxygen delivery to the optic nerves.¹ Postoperative blindness has been previously reported in association with pressure-induced eye-injury, arterial hypotension, low hematocrit concentration, and obstruction of venous outflow. One cause of venous obstruction, superior vena cava syndrome (SVCS), is a reported but uncommon complication of liver transplantation in patients with a history of central venous thrombosis, indwelling catheters, or peritoneovenous shunts.^{2–7}

* Associate Professor of Anesthesiology, † Assistant Professor of Anesthesiology, Department of Anesthesiology, *‡ Associate Professor of Surgery, § Professor of Surgery, Department of Surgery.

Received from the Departments of Anesthesiology and Surgery, Vanderbilt University Medical Center, Nashville, Tennessee. Submitted for publication June 12, 2000. Accepted for publication August 30, 2000. Support was provided solely from institutional and/or departmental sources.

Address reprint requests to Dr. Janicki: Department of Anesthesiology VUMC, 504 Oxford House, 1313 21st Avenue S., Nashville, Tennessee 37232-4125. Address electronic mail to: Piotr.Janicki@mcmail.vanderbil.edu. Individual article reprints may be purchased through the Journal Web site, www.anesthesiology.org.

Case Report

A 43-yr-old man with hepatitis C cirrhosis had intractable ascites and a history of repeated placement of peritoneojugular shunts and placement of a transjugular intrahepatic portosystemic shunt. At the time of liver transplantation, induction of anesthesia with thiopental, fentanyl, and succinylcholine was achieved, and femoral and radial arterial catheters were placed. Because of poor peripheral venous access, insertion of peripheral, larger bore catheters was not successful. Several attempts were necessary to place central lines. Ultimately, large-bore intravenous catheters (8.5 French) were inserted into both internal jugular veins and the subclavian veins. An oximetric pulmonary artery catheter was inserted through the right internal jugular catheter. Anesthesia was maintained with isoflurane, fentanyl, and pancuronium.

The transplant operation was uneventful until the third hour, when it was aborted (just before recipient hepatectomy) because malignancy within the donor organ was revealed by postmortem examination. Stable hemodynamic parameters recorded throughout the procedure included central venous pressure (8 to 9 mmHg), pulmonary artery pressure (22–25/10–15 mmHg), and cardiac index (3.2–4.0 l/m²). The administered fluids included 4 l of crystalloids, 1 l of 5% albumin, 4 units packed erythrocytes, and 4 units fresh frozen plasma. No antifibrinolytic agents were administered to the patient during the operation.

During the closure of the aborted transplantation, the previously placed, nonfunctional peritoneojugular shunt was removed by sliding the venous end from the subcostal incision. Swelling and cyanosis of

the patient's face and neck were noted thereafter. The positions of all intravenous catheters were reconfirmed by the ability to draw back blood easily. Intravenous fluid maintenance was limited, and the patient was placed in the 30° reverse Trendelenburg position. Postoperatively in the intensive care unit, the head, face, and upper extremities became markedly edematous and cyanotic. A diagnosis of acute SVCS was determined, and three of four larger bore catheters were removed; the right internal jugular pulmonary artery indwelling catheter was left in place. Doppler study revealed total occlusion of both subclavian veins and the left and right internal jugular veins and a clot in the superior vena cava (SVC). Because of the facial edema, the patient remained intubated in the surgical intensive care unit, and maintenance fluid was continued through a freshly inserted femoral catheter. The patient required intermittent use of vasopressors and β -blockers to control tachycardia. By the second postoperative day, the patient had become hemodynamically stable, but there was little improvement in the signs of SVCS.

A second liver allograft was identified, and liver transplantation was performed successfully 48 h later using the piggyback technique. Intravenous access for this procedure was secured through large-bore femoral vein catheters. The procedure proceeded routinely except for a 2-min extreme hypotensive episode (systolic blood pressure, 50–60 mmHg) because of acute blood loss, which was rapidly corrected with massive-volume resuscitation. Total blood loss was estimated to be approximately 6 l and during the procedure the patient received 12 l of crystalloids, 1 l albumin, 5%, 13 units packed erythrocytes, 10 units fresh frozen plasma, and 20 units platelets. The postoperative course initially was uneventful, and the patient was extubated on the third postoperative day. On the fourth postoperative day, the patient verbalized that he was unable to see, and examination showed for the first time that his pupils were fixed and dilated, with no reaction to light. Fundoscopic examination performed by the ophthalmology consultant showed bilaterally elevated, pale, and blurred optic disks. The retina in both disks was flat, and the macula and vessels seemed to be normal. Computed tomography of the head showed no evidence of acute intracranial hemorrhage or infarction. The ophthalmology consultant diagnosed the patient with bilateral anterior ION. Facial and upper extremity congestion and edema resolved as the patient recovered from the transplant procedure. Subsequent eye examinations showed no significant changes and that the patient was unable to see. The patient was discharged from the hospital on postoperative day 21, with complete bilateral blindness and resolving SVCS.

Discussion

In patients with recurrent ascites after peritoneovenous shunt placement, total and partial occlusion of the SVC is seen in 53 and 17% of patients, respectively.^{6,7} Patients with partial SVC obstruction may be asymptomatic preoperatively, but overt SVCS may develop after transplantation and placement of large-bore lines into the subclavian or jugular vein. Several cases of acute SVCS associated with peritoneovenous shunt have been reported in patients undergoing liver transplantation; however, without any alteration in vision in the postoperative period.^{2–5}

The most commonly reported cause of postoperative visual loss is acute optic nerve ischemia.¹ Visual loss as a result of ischemic injury to the optic nerve are labeled as anterior and posterior ION because these parts of the optic nerve have different blood supplies, different predisposing factors for injury, and varying clinical pic-

tures.¹ Anterior ION is characterized by sudden, progressive and painless visual-field deficit and defect in a pupillary light reaction, from a slight decrease in visual acuity to no light perception (as in the presented case). Ophthalmoscopic examination initially shows optic disk edema, which usually resolves in several weeks and is replaced by optic atrophy. There are vascular causes of postoperative loss of vision other than ION. Cortical blindness, retinal occlusion, and ophthalmic venous obstruction therefore should be excluded. Cortical blindness is characterized by loss of visual sensation with retention of papillary reaction to light and normal fundoscopic examination results. Computerized tomography or magnetic resonance imaging abnormalities in the parietal or occipital lobe confirm the diagnosis. Central retinal artery occlusion presents as painless, monocular blindness. Ophthalmoscopic examination of eyes with retinal artery occlusion shows a pale edematous retina, cherry-red spot at the fovea, and platelet-fibrin or cholesterol emboli in the narrowed retinal arterioles. Obstruction of venous drainage from the eye may occur intraoperatively when patient positioning results in external pressure on the eyes. In severe cases, ophthalmoscopic examination shows normal or dilated retinal arterioles, engorgement of the veins, and edema of the macula and the retina surrounding the optic disk. Another rare cause of postoperative blindness in liver transplantation is cyclosporine-induced neurotoxicity which results in usually reversible cortical blindness.⁸

Postoperative anterior ION is the result of multiple causes of decreased oxygen delivery. It is usually associated with hypotension and blood loss. However, often there are other contributing variables, such as venous obstruction or vascular abnormalities. In a recent retrospective study of 350 patients who experienced massive trauma, anterior ION developed in 2.6%, and there was a significant association among ION, massive fluid resuscitation, and prolonged ventilatory support.⁹ Importantly, most of the patients in this study and those in our study were placed in the supine position.

Increased venous pressure was cited previously as a contributor to postoperative anterior ION after head and neck surgery as a result of local obstruction of venous outflow.¹ It is speculated that changes in central venous pressure concomitant with changes in body position result in venous stasis in the drainage of the optical nerve. Patients with SVCS or predisposition to SVCS perhaps should be positioned in the reverse Trendelenburg position. The potential for SVC thrombosis and ION should be considered in patients with a history of peritoneovenous shunt placement.

References

1. Williams EL, Hart WM, Tempelhoff R: Postoperative ischemic optic neuropathy. *Anesth Analg* 1995; 80:1018–29

2. Kang Y, Videira R, DeWolf AM, Casavilla A, Freeman JA, Aggrwal S, DeRiso B: The superior vena caval syndrome during orthotopic liver transplantation: A complication of LeVeen shunt and venovenous bypass. *Transpl Proceed* 1991; 23:1998-9
3. Pinna AD, Sugitani A, Thistlethwaite P, Kang Y, Marongiu L, Todo S, Starzl TE, Fung JJ: Venous-right atrial bypass for superior vena thrombosis during orthotopic liver transplantation. *Transplantation* 1997; 15:471-2
4. Haussmann R, Motsch J, Otto G, Martin E: Acute jugular engorgement in liver transplantation: *Anesthetist* 1992; 41:702-3
5. Suriani RJ, Abel M: Acute superior vena cava syndrome resulting from inferior vena cava cross-clamping: *J Cardiothorac Vasc Anesth* 1997; 11:197-200

6. Smadja C, Tridard D, Franco D: Recurrent ascites due to central venous thrombosis after peritoneojugular (LeVeen) shunt. *Surgery* 1986; 100:535-41
7. Foley WJ, Elliott JP, Smith RF, Reddy DJ, Lewis JW Jr, Hageman JH: Central venous thrombosis and embolism associated with peritoneovenous shunts. *Arch Surg* 1984; 119:713-20
8. Wijdicks EF, Wiesner RH, Krom RA: Neurotoxicity in liver transplant recipients with cyclosporine immunosuppression. *Neurology* 1995; 45:1962-4
9. Cullinane DC, Jenkins JM, Reddy S, VanNatta T, Eddy VA, Bass JG, Schwartz M, Lavin P, Morris JA Jr: Anterior ischemic optic neuropathy: A complication after system inflammatory response syndrome. *J Trauma* 2000; 48:381-6

Anesthesiology 2001; 94:363-4

© 2001 American Society of Anesthesiologists, Inc. Lippincott Williams & Wilkins, Inc.

Cardiac Arrest and Myocardial Infarction Induced by Postpartum Intravenous Ergonovine Administration

Ban C. H. Tsui, M.D. M.S.C.,* Barbara Stewart, M.D., † Aingeal Fitzmaurice, M.D., ‡ Randall Williams, M.D. §

ERGONOVINE can induce coronary spasm and has been used in cardiac catheterization laboratories as a diagnostic agent for many years.^{1,2} This drug also precipitates acute myocardial infarction in some patients as a consequence of coronary spasm. However, although ergot derivatives are frequently administered by anesthesiologists on request by the obstetrician during cesarean delivery to promote uterine contractions, serious ischemic cardiac events related to ergonovine have rarely been described. We report a case of cardiac arrest and myocardial infarction induced by intravenous administration of ergonovine during cesarean delivery.

Case Report

A 34-yr-old Asian woman was admitted to the hospital after premature rupture of the membranes. She had no history of cardiovascular disease or migraine headache and denied coronary risk factors, including smoking, diabetes mellitus, and hypertension. Her exercise tolerance had been normal. After 15 h of labor induction with oxytocin infusion, her cervix dilated to only 8 cm. Cesarean delivery was therefore performed, using a spinal anesthetic of 10 mg hyperbaric bupivacaine, 0.75%, 20 μ g fentanyl, and 0.25 mg morphine. Despite oxytocin (10-IU bolus followed by continuous infusion), the uterus remained atonic after delivery. A single intravenous injection (0.25 mg) of ergonovine was given on a request by the obstetrician. Within minutes, the patient became unresponsive and severely bradycardic, progressing to asystole cardiac arrest followed by ventricular fibrilla-

tion during resuscitation. After successful resuscitation, the patient was transferred to a nearby tertiary referral center. The patient remained intubated and supported with a dopamine infusion.

At admission to the coronary care unit (1½ h after the event), her electrocardiogram showed an acute anterior infarct with inferior ST depression. To help guide therapeutic management, cardiac catheterization was performed urgently. Coronary angiography revealed diffuse spasm of left anterior descending and circumflex arteries, with subtotal occlusion in the principal diagonal branch of the left anterior descending coronary artery (fig. 1). The estimated left ventricular ejection fraction was 15%. The spasm was reversed with intracoronary injection of 200 μ g nitroglycerin. The patient was supported with an intraaortic balloon pump and inotropic infusions of dopamine, norepinephrine, and milrinone. After initial stabilization in the catheterization laboratory and before institution of an intravenous nitroglycerin, the patient had new onset ST changes compatible with inferoposterior injury on her electrocardiogram in the coronary care unit (4 h after the initial event). Intravenous nitroglycerin was administered with rapid resolution of ST-segment elevation. Her peak creatinine phosphokinase concentration was 2,763 U/l. The patient improved and underwent extubation 2 days later. Intraaortic balloon pump support and the inotropic agents were weaned the following day. On day 5, an echocardiogram revealed that the ejection fraction had improved to 45%. The patient was discharged from hospital on day 11, with normal neurologic status.

Discussion

Despite the frequency of usage of ergot derivatives cardiac complications related to this drug are rare. Little has been written about this complication by anesthesiologists, partly because the postpartum ischemic event precipitated by ergot derivatives can be overlooked easily because the occurrence is uncommon and its symptoms are often vague. Other than a paragraph discussion written by Mayer and Spielman in an obstetric anesthesia textbook edited by David Chestnut,³ there has not been a case report published in the anesthesiology literature discussing this complication. However, there are six cases of myocardial infarction after postpartum use of ergot derivatives reported in obstetric and cardiology journals.⁴⁻⁸

The normal response of coronary arteries to ergonovine is a diffuse 15-20% decrease in the luminal diame-

* Assistant Professor, Department of Anesthesiology and Pain Medicine, § Assistant Clinical Professor, Division of Cardiology, Department of Medicine, University of Alberta Hospitals. † Anesthesiologist, Department of Anesthesia, § Director, Coronary Care Unit, Royal Alexandra Hospital. ‡ Anesthesiologist, Department of Anesthesia, Caritas Health Group.

Received from the Department of Anesthesiology and Pain Medicine and the Division of Cardiology, Department of Medicine, University of Alberta Hospitals, Edmonton, Alberta, Canada; the Department of Anesthesia and the Coronary Care Unit, Royal Alexandra Hospital, Edmonton, Alberta, Canada; and the Department of Anesthesia, Caritas Health Group, Edmonton, Alberta, Canada. Submitted for publication June 22, 2000. Accepted for publication August 30, 2000. Supported in part by the Research Fund, Department of Anesthesiology and Pain Medicine, University of Alberta Hospitals.

Address reprint requests to Dr. Tsui: Department of Anesthesiology and Pain Medicine, University of Alberta Hospitals, Edmonton, Alberta T6G 2B7, Canada. Address electronic mail to: btsui@ualberta.ca. Individual article reprints may be purchased through the Journal Web site, www.anesthesiology.org.

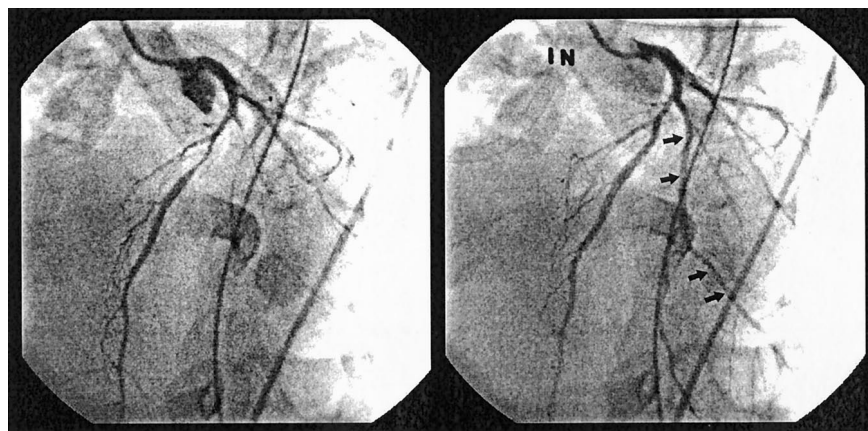


Fig. 1. Left coronary angiograms showing (left) diffuse spasm of left anterior descending and circumflex arteries with a subtotal occlusion in the principal diagonal branch of the left anterior descending coronary artery. (Right) Restoration of flow after intracoronary injection of nitroglycerin in the principal diagonal branch of the left anterior descending coronary artery (arrows).

ter.² Although the pathophysiology of severe coronary vasospasm is unclear, postulated risk factors include age greater than 30, smoking, alcohol use, and a history of migraines.⁴⁻⁸ In our case, the only factor that may have placed our patient at a higher risk is her age being greater than 30. It is worth noting that, including the present case, five of seven reported cases involved Asian women. This observation would be compatible with the higher incidence of variant angina in Asians *versus* whites.⁹ Although the pathogenesis has not been clarified, recent studies have reported also a higher incidence of induced coronary artery spasm after myocardial infarction in Asian compared with white patients.⁹ This indicates possible racial differences in the contribution of coronary vasospasm to the pathogenesis of acute myocardial infarction.

Intravenous administration of an ergot derivative has an almost immediate onset of action. When administered intramuscularly, the onset is within a few minutes.^{1,3} This rapid onset of action is shown in the two cases previously reported in which ischemia developed within 20 min after intramuscular administration.^{4,5} In the current patient, cardiac arrest occurred within minutes after intravenous injection, even though the dosage administered to our patient was within the recommended drug range. Perhaps a safer approach would be to give the drug in divided incremental intravenous doses.³ The administration of the drug should be stopped immediately if ischemic symptoms or electrocardiographic changes occur.

The early recognition and prompt treatment of coronary vasospasm-induced myocardial ischemia are important to preserve myocardial function. Nitroglycerin can be useful in reversing coronary vasospasm. In one case report, the prompt administration of sublingual nitroglycerin in a postpartum patient who experienced chest pain after administration of 0.2 mg intramuscular ergonovine resulted in a relatively benign course with rapid recovery.⁵ Therefore, it is our opinion that initial treatment should start with sublingual nitroglycerin if the patient is hemodynamically stable. Otherwise, ag-

gressive treatment, including intravenous nitroglycerin with appropriate inotropic drugs and intraaortic balloon pump support, should be considered for this potentially reversible complication. Cardiac catheterization with intracoronary injection of nitroglycerin is also useful. Although the exact duration of coronary vasospasm provoked by ergonovine has not been clarified in the literature, ergonovine-induced coronary vasospasm may last for hours, as was found with our patient, and may recur after initial resolution with nitroglycerin. Therefore, it is important to continue appropriate treatment and monitoring for an extended period.

This case shows the need for anesthesiologists to be aware of this rare but potentially life-threatening complication. Careful drug administration with proper monitoring, prompt evaluation, and treatment with nitroglycerin may prevent or reduce morbidity and mortality as cardiac risks of ergot derivatives.

References

1. de Groot AN, van Dongen PW, Vree TB, Hekster YA, van Roosmalen J: Ergot alkaloids: Current status and review of clinical pharmacology and therapeutic use compared with other oxytocics in obstetrics and gynaecology. *Drugs* 1998; 56:523-35.
2. Lange RA, Hillis LD: Assessment of cardiovascular function, Diagnostic and Therapeutic Cardiac Catheterization, 2nd edition. Edited by Pepine CJ, Hill JA, Lambert CR. Baltimore, Williams & Wilkins, 1994, pp 394-429
3. Mayer DC, Spielman FJ: Antepartum and postpartum hemorrhage, Obstetric Anesthesia: Principal and Practice. Edited by Chestnut DH. St. Louis, Mosby, 1994, pp 699-721
4. Taylor G, Cohen B: Ergonovine-induced coronary artery spasm and myocardial infarction after normal delivery. *Obstet Gynecol* 1985; 66:821-2
5. Liao J, Cockrill B, Yurchak P: Acute myocardial infarction after ergonovine administration for uterine bleeding. *Am J Cardiol* 1991; 68:823-4
6. Fujiwara Y, Yamanaka O, Nakamura T, Yokoi H, Yamaguchi H: Acute myocardial infarction induced by ergonovine administration for artificially induced abortion. *Jpn Heart J* 1993; 34:803-8
7. Ko WJ, Ho HN, Chu SH: Postpartum myocardium infarction rescued with an intraaortic balloon pump and extracorporeal membrane oxygenator. *Int J Cardiol* 1998; 63:81-4
8. Yaegashi N, Miura M, Okamura. Acute myocardial infarction associated with postpartum ergot alkaloid administration. *Int J Gynecol Obstet* 1999; 64:67-8
9. Pristipino C, Beltrame JF, Finocchiaro ML, Hattori R, Fujita M, Mongiardo R, Cianflone D, Sanna T, Sasayama S, Maseri A: Major racial differences in coronary constrictor response between Japanese and Caucasians with recent myocardial infarction. *Circulation* 2000; 101:1102-8

Decrease in T-wave Amplitude without Hemodynamic Changes after Intravascular Injection of an Epinephrine Test Dose

Makoto Tanaka, M.D.,* Toshiaki Nishikawa, M.D.†

INADVERTENT intravascular injection of large amounts of local anesthetic solutions intended for epidural anesthesia can result in potentially lethal cardiovascular or central nervous system toxicity.^{1,2} Thus, administration of an epidural test dose containing 10–15 μg epinephrine through an epidural catheter is common practice to diagnose intravascular injection of a local anesthetic solution.³

For detecting intravascular injection of an epinephrine-containing test dose, hemodynamic criteria have been used commonly.³ More recently, changes in T-wave amplitude in lead II electrocardiography have been implicated in intravascular injection in adult and pediatric patients.^{4,5} In this report, we describe a case of an elderly woman who had a decrease in T-wave amplitude with essentially unaltered systolic blood pressure (SBP) and heart rate (HR) after unintentional intravascular injection of unknown amount of the epinephrine test dose during combined epidural–general anesthesia.

Case Report

A 77-yr-old woman (American Society of Anesthesiologists physical status II; weight, 62 kg; height, 140 cm) presented for revision of total hip arthroplasty. Except for hypertension treated with 10 mg oral nifedipine four times daily and obesity (body mass index = 32), she was healthy, and her activities of daily life were not restricted. At admission, her blood pressure (BP) and HR were 130/70 mmHg and 66 beats/min, respectively. Physical and laboratory examinations, including serum electrolytes, yielded otherwise normal results, and electrocardiography showed regular sinus rhythm without significant ST-T-segment abnormalities.

She was administered premedication with 10 mg oral diazepam and 20 mg famotidine 90 min before induction of general anesthesia. A radial arterial catheter was placed after local anesthetic infiltration for subsequent BP measurements. With the patient in the right lateral decubitus position, a 20-gauge epidural catheter with multiple orifices was placed at the L4–L5 interspace using an 18-gauge Tuohy needle and a loss of resistance to saline technique. The tip of the catheter was advanced 5 cm into the epidural space without resistance or paresthesia. The patient then was turned to the supine position. After an aspiration test for blood and cerebrospinal fluid that yielded negative

results, 3 ml lidocaine, 1.5%, with 15 μg epinephrine (1:200,000) was injected through the catheter. After confirming negative responses in SBP, HR, and electrocardiographic morphology in lead II,^{3,4} an additional 10 ml of the same lidocaine–epinephrine solution was administered in divided doses. BP was initially 140/60 mmHg and gradually decreased to 110/54 mmHg, with a concomitant HR increase from 64 to 69 beats/min 15 min after injection, when sensory analgesia determined by a pin-prick method was below T10 bilaterally. General anesthesia then was induced with 100 μg intravenous fentanyl and 250 mg thiopental, and tracheal intubation was facilitated with 8 ml intravenous vecuronium. Her lungs were ventilated mechanically with 0.5–1.2% (inspired) sevoflurane and 67% nitrous oxide in oxygen while end-tidal carbon dioxide tension was maintained between 28 and 34 mmHg thereafter. The surgery commenced with the patient in the right lateral decubitus position and was uneventful until a reinforcing dose of the identical lidocaine–epinephrine solution was necessary, approximately 60 min after the initial dose. The aspiration test using a 20-ml syringe again yielded negative results for blood. Her BP and HR were 111/63 mmHg and 63 beats/min before injecting 3 ml of the test dose through the epidural catheter and remained 105–117/59–65 mmHg and 63–67 beats/min within the next 5 min after injection, respectively. However, a decrease in T-wave amplitude on a strip-chart was noted on the lead II electrocardiogram from 30 to 60 s after the test dose injection, and the T-wave morphology returned to the preinjection level in 2 min (fig. 1). Using a 1-ml syringe, frank blood could be aspirated freely. Arterial blood gas analysis and electrolytes after this event were unremarkable. Inspiratory concentration of sevoflurane was 1% at this time. Epidural anesthesia was halted thereafter and anesthesia was maintained using intravenous fentanyl, sevoflurane, and nitrous oxide, without event during the rest of the planned surgical procedure.

Discussion

Unrecognized intravascular injection of large amounts of local anesthetic solution is a significant hazard of epidural blockade. As seen in the current patient, vessel entry of the epidural catheter tip may occur not only during initial insertion, but also at any time during ongoing epidural therapy.⁶ Because reported frequency of vessel entry ranges from 0.2% to 11%,⁶ the earliest possible detection of the catheter migration is essential for preventing life-threatening cardiovascular or central nervous system complications. Although typical HR increases of 20 beats/min or more after the test dose injection have been regarded as a testing threshold in awake subjects,³ SBP increases of 15 mmHg or more seem to be more reliable during sevoflurane anesthesia.⁴ Similarly, a recent study has shown that a decrease in T-wave amplitude of 25% or more in lead II is at least as sensitive as the SBP criterion but more sensitive than the HR criterion when a fractional dose of the epinephrine-containing test dose is

* Associate Professor, † Professor and Chair.

Received from the Department of Anesthesia, Akita University School of Medicine, Akita, Japan. Submitted for publication June 9, 2000. Accepted for publication October 2, 2000. Support was provided solely from institutional and/or departmental sources.

Address reprint requests to Dr. Tanaka: Department of Anesthesia, Akita University School of Medicine, Hondo 1-1-1, Akita-shi, Akita-ken 010-8543, Japan. Address electronic mail to: mtanaka@med.akita-u.ac.jp. Individual article reprints may be purchased through the Journal Web site, www.anesthesiology.org.

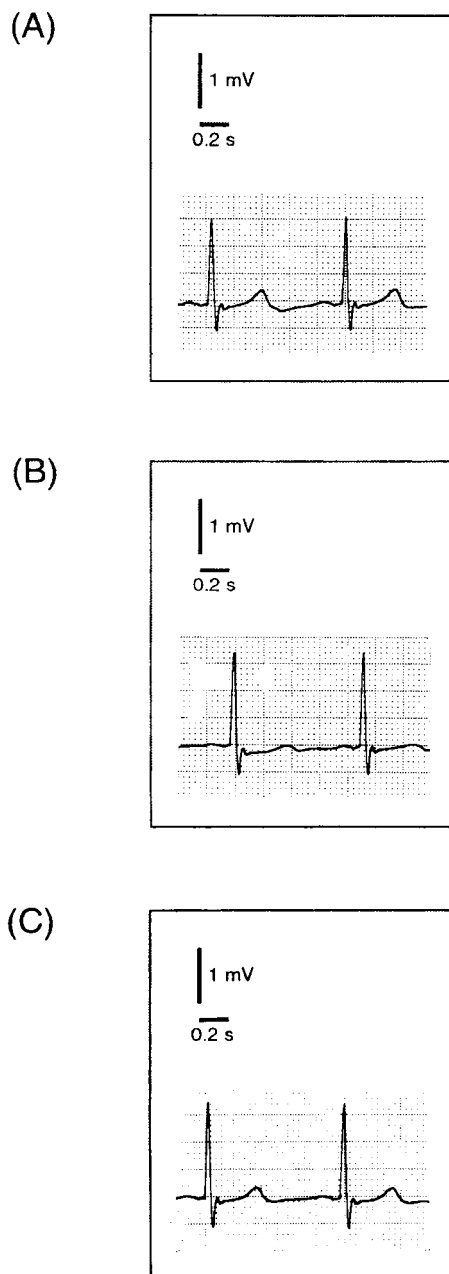


Fig. 1. Alteration of T-wave amplitudes in lead II of a 77-yr-old woman (A) before, (B) 30 s after, and (C) 2 min after the patient was administered an epidural test dose consisting of 3 ml lidocaine, 1.5%, and 15 μ g epinephrine (1:200,000) through an epidural catheter during combined epidural-general anesthesia using sevoflurane and nitrous oxide. T-wave amplitudes before, 30 s after, and 2 min after the test dose injection were 0.34, 0.13, and 0.27 mV, respectively.

injected intravenously.⁷ Although the use of T-wave morphology has been regarded only as an adjuvant diagnostic tool, virtually absent hemodynamic alterations and an easily detectable decrease in T-wave amplitude in the current patient indicate potential clinical usefulness of the T-wave criterion for the diagnosis of intravascular injection of the test dose during general anesthesia.

To the best of our knowledge, concomitant changes in

T-wave morphology with considerably attenuated or virtually absent hemodynamic responses associated with the intravascular test dose have not been reported previously in the literature. In our case, several factors may have contributed to the absence of significant hemodynamic changes. Advanced age and volatile anesthetics may have played a role in diminished HR response to the intravenous epinephrine.^{8,9} Even though we cannot exclude the possibility that preoperative oral nifedipine might have modified cardiovascular responses to the intravenous test dose, previous studies have shown that intravenous nifedipine did not alter epinephrine-induced BP and HR responses significantly in cats¹⁰ and that BP increase in response to psychological stimuli associated with increased plasma epinephrine concentration was not suppressed by nifedipine in hypertensive humans.¹ Although the reliability of HR response for detecting intravascular injection of the test dose is known to decrease in acutely β -blocked subjects,³ effects of other antihypertensive medications on hemodynamic change to and effectiveness of the intravenous test dose have not been addressed previously. In our case, a more likely explanation for the absence of SBP response may be that an amount of epinephrine inadvertently administered into the epidural vein was not sufficient to cause the plasma epinephrine concentration that produces α -adrenoceptor-mediated vasoconstriction and resultant BP increase. Because the current patient had a significant detectable decrease in T-wave amplitude, it is of important clinical relevance to determine the minimum effective epinephrine dose that should elicit reliable changes in T-wave morphology in various clinical circumstances.

In conclusion, our reported case indicates that close attention should be paid to electrocardiographic morphology immediately after the epidural test dose injection, especially when the patient is associated with factors that depress hemodynamic responses, such as advanced age and administration of concomitant general anesthetic.

References

1. Prince G, McGregor D: Obstetric test doses: A reappraisal. *Anaesthesiology* 1986; 41:1240-50
2. Matsumiya N, Dohi S, Takahashi H, Kondo Y, Naito H: Cardiovascular collapse in an infant after caudal anesthesia with a lidocaine-epinephrine solution. *Anesth Analg* 1986; 65:1074-6
3. Guinard JP, Mulroy MF, Carpenter RL, Knopes KD: Test doses: Optimal epinephrine content with and without acute beta-adrenergic blockade. *ANESTHESIOLOGY* 1990; 73:386-92
4. Tanaka M, Nishikawa T: A comparative study of hemodynamic and T-wave criteria for detecting intravascular injection of the test dose (epinephrine) in sevoflurane-anesthetized adults. *Anesth Analg* 1999; 89:32-6
5. Tanaka M, Nishikawa T: The efficacy of a simulated intravascular test dose in sevoflurane-anesthetized children: A dose-response study. *Anesth Analg* 1999; 89:632-7
6. Mulroy MF, Norris MC, Liu SS: Safety steps for epidural injection of local anesthetics: Review of the literature and recommendations. *Anesth Analg* 1997; 85:1346-56
7. Tanaka M, Nishikawa T: Comparison of heart rate and T-wave criteria for detecting intravascular injection of epinephrine test dose in anesthetized adults: A dose-response study (abstract). *ANESTHESIOLOGY* 1999; 91(suppl 3A):A918

8. Tanaka M, Nishikawa T: Efficacy of simulated intravenous test dose in the elderly during general anesthesia. *Reg Anesth Pain Med* 1999; 24:393-8
9. Stowe DF, Dujic Z, Bosnjak ZJ, Kalbfleisch JH, Kampine JP: Volatile anesthetics attenuate sympathomimetic actions on the guinea pig SA node. *ANESTHESIOLOGY* 1988; 68:887-94
10. Gurtu S, Mukerjee D, Shukla S: Evidence for a role of inhibition of

- sympathetic neurotransmission in the cardiovascular effects of intravenously administered verapamil. *Pharmacol Res* 1995; 31:383-6
11. Guazzi MD, Bartorelli A, Loaldi A, Moruzzi P, Fiorentini C: Calcium channel blockade with nifedipine reduces the systemic and the pulmonary vascular reactivity to adrenergic activation in hypertension. *J Hypertens Suppl* 1986; 4:S465-8

Anesthesiology 2001; 94:367-8

© 2001 American Society of Anesthesiologists, Inc. Lippincott Williams & Wilkins, Inc.

Coronary Artery Stenting before Noncardiac Surgery: More Threat Than Safety?

Martin N. Vicenzi, M.D.,* Dieter Ribitsch, M.D.,* Olef Luha, M.D.,† Werner Klein, M.D.,‡ Helfried Metzler, M.D.§

THE implantation of coronary artery stents subsequent to percutaneous transluminal coronary artery angioplasty became a novel procedure in interventional cardiology to increase the patency rates of the dilated arteries.^{1,2} Therefore, the anesthesiologist is faced increasingly with preoperative patients who have undergone previous stenting. Although intended to protect against new ischemic cardiac events during and after noncardiac surgery, there is only a single case report in the anesthesiology literature describing the successful perioperative course of a patient with a stent.³ In contrast, drastically increased perioperative morbidity and mortality have been reported recently.⁴

Case Report

A 64-yr-old man presented for nephrectomy because of a tumor of the kidney. Thirty-three days earlier, he had a non-Q-wave infarction. The echocardiogram was normal. Heparin (1,000 U/h), bisoprolol (5 mg/day), and acetylsalicylic acid (100 mg/day) comprised the initial treatment. Angiography on the day after the infarction (32 days before surgery) revealed a ruptured plaque causing an isolated 95% stenosis with thrombosis of the left anterior descending coronary artery. Percutaneous transluminal coronary artery angioplasty combined with stent implantation completely restored vessel lumen and blood flow. Administration of abciximab, ticlopidine, acetylsalicylic acid, and atorvastatin was initiated. The patient had been asymptomatic since then, had excellent treadmill test results, and lacked signs or symptoms of myocardial ischemia. Administration of bisoprolol, acetylsalicylic acid, and atorvastatin was continued.

Acetylsalicylic acid administration had been discontinued by the urologist 5 days before surgery and replaced by the low-molecular-weight heparin enoxaparin (40 mg subcutaneously once daily). Bisoprolol administration was continued until the morning of surgery. General anesthesia was induced with etomidate, fentanyl, and atracurium. The patient underwent intubation and mechanical ventilation, and anesthesia was maintained using nitrous oxide and isoflurane in

oxygen, supplemented by fentanyl and atracurium as needed. Nephrectomy lasted 210 min and was uneventful. Histology led to the diagnosis of renal cell carcinoma. After extubation, the patient was transferred to the postanesthesia care unit. Two hours later, he had sudden ST elevation (lead I, V1-V3), followed by ventricular fibrillation. The patient underwent defibrillation and reintubation. Intravenous epinephrine (2.5 mg) restored the circulation. Electrocardiographic tracings revealed a transmural, anterolateral myocardial infarction. The echocardiogram showed a large akinetic area with adhering thrombus. The ejection fraction was 40%, and troponin (initially 48, 12 h later 238 ng/ml) and cardiac enzymes were increased markedly. Continuous intravenous heparinization was initiated. Administration of bisoprolol and atorvastatin was continued. On the second postoperative day, angiographic reevaluation showed complete stent occlusion, which was redilated successfully to a 25% stenosis (figs. 1 and 2). Ticlopidine (250 mg twice daily for 4 weeks), fosinopril (angiotensin-converting enzyme inhibitor, 10 mg/day), and nicorandil (K-channel opener, 10 mg/day) were added. Eighteen hours after this percutaneous transluminal coronary artery angioplasty, major intestinal bleeding necessitated the transfusion of 5 units packed blood cells within the subsequent 48 h. Heparinization had to be discontinued until the intestinal bleeding ceased. After 15 days of hospitalization, the patient recovered. Three months and then 1 yr later, treadmill test results were normal, and the patient has been asymptomatic since then.

Discussion

This case report describes severe postoperative complications with cardiac arrest in a patient with coronary artery disease 32 days after stent implantation. Stents are placed to prevent myocardial ischemia and infarction. Tabuchi *et al.*³ reported an uneventful anesthesia and major surgery 2 months after a successful stent placement. No ischemic events and no bleeding complications occurred with the protection of titrated, unfractionated heparin.

Anticoagulation-antiplatelet therapy has to balance the risk of bleeding against the risk of coronary artery occlusion or stent restenosis.^{5,6} Major surgery activates the procoagulatory system. Coronary artery stents are thrombogenic and induce endothelial hyperplasia.^{7,8} Therefore, a drug regimen that is effective in the non-surgical situation may not be sufficiently anticoagulatory-antithrombotic or may induce severe bleeding in the perioperative setting.^{5,7}

However, more recently, Kaluza *et al.*⁴ described 11 cases of bleeding, 7 myocardial infarctions, and

* Assistant Professor, § Professor, Department of Anesthesiology and Intensive Care Medicine, † Assistant Professor, ‡ Professor, Department of Cardiology.

Received from the Departments of Anesthesiology and Intensive Care Medicine and Cardiology, University of Graz, Graz, Austria. Submitted for publication July 17, 2000. Accepted for publication October 2, 2000. Support was provided solely from institutional and/or departmental sources.

Address reprint requests to Dr. Vicenzi: Department of Anesthesiology and Intensive Care Medicine, University Hospital of Graz, Auenbruggerplatz 29, A-8036 Graz, Austria. Address electronic mail to: martin.vicenzi@kfunigraz.ac.at. Individual article reprints may be purchased through the Journal Web site, www.anesthesiology.org.

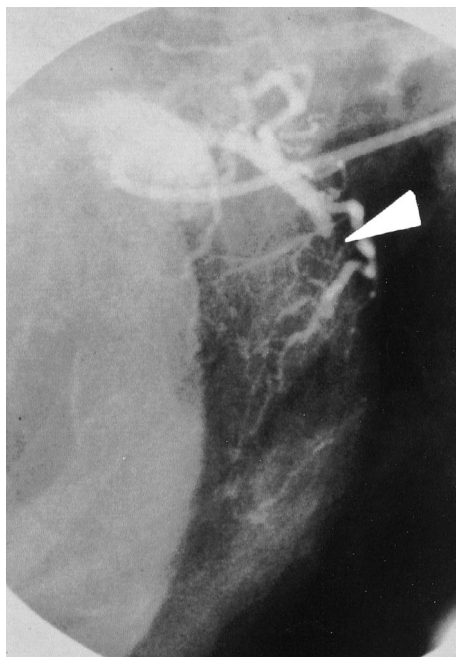


Fig. 1. Postoperative total occlusion of the left anterior descending coronary artery stent.

8 deaths in a retrospective assessment of 40 patients undergoing surgery after stenting. Early stent thrombosis was the major cause of mortality, and the majority of adverse events occurred within 2 weeks of stenting. These findings indicate that anticoagulation needed to prevent thrombosis may result in severe hemorrhagic complications or, alternatively, may be inadequate to prevent thrombosis. This appeared to be the situation with the current patient. The existing anticoagulant medications were not sufficient to prevent stent thrombosis, but, when more aggressive anticoagulation was instituted after surgery, a severe hemorrhagic complication occurred. Kaluza *et al.*⁴ suggested that delaying surgery for a longer period of time was prudent. However, the current report describes complications 32 days after stenting.

As a result, the safe waiting period is not known—if such a safe period exists at all. It seems that patients with stents may be at heightened risk of stent occlusion after surgery. If surgery is urgent, patients with recent stenting should be classified as high risk. They require titrated anticoagulatory therapy with tight and exact monitoring of myocardial ischemia and coagulation during the entire perioperative period. Close contact to an interventional cardiologic consultant is mandatory.

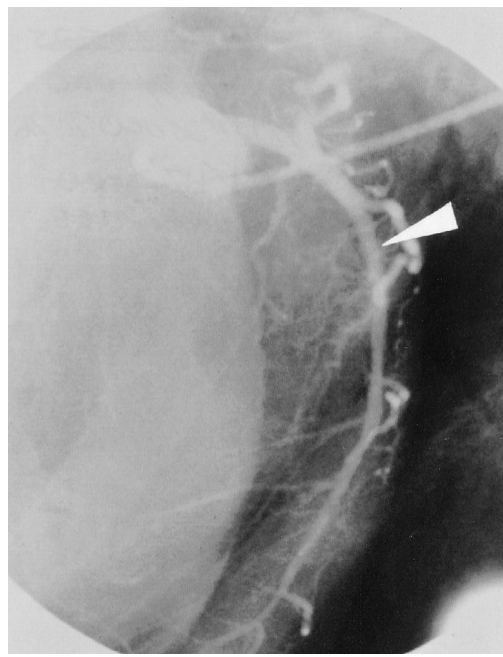


Fig. 2. Successful percutaneous transluminal coronary artery angioplasty redilatation of the occluded left anterior descending coronary artery stent.

References

1. Stone GW, Brodie BR, Griffin JJ, Costantini C, Morice MC, Goar FGS, Overl PA, Popma JJ, McDonnell J, Jones D, O'Neill WW, Grines CL: Clinical angiographic follow-up after primary stenting in acute myocardial infarction: The primary angioplasty in myocardial infarction (PAMI) stent pilot trial. *Circulation* 1999; 99:1548-54
2. Knight CJ, Curzen NP, Groves PH, Patel DJ, Goodall AH, Wright C, Clark D, Oldershaw PJ, Fox KM: Stent implantation reduces restenosis in patients with suboptimal results following coronary angioplasty. *Eur Heart J* 1999; 20:1783-9
3. Tabuchi Y, Nosaka S, Amakata Y, Takamitsu Y, Shibata N: Perioperative management for nephrectomy in a long-term hemodialysis patient with anticoagulants for coronary stent. *Masui* 1998; 47:720-5
4. Kaluza GL, Joseph J, Lee JR, Raizner ME, Raizner AE: Catastrophic outcome of noncardiac surgery soon after coronary stenting. *J Am Coll Cardiol* 2000; 35:1288-95
5. Urban P, Macaya C, Rupprecht HJ, Kiemencij F, Emanuelsson H, Fontanel A, Pieper M, Wesseling T, Sagnard L: Randomized evaluation of anticoagulation versus antiplatelet therapy after coronary stent implantation in high-risk patients: The multicenter aspirin and ticlopidine trial after intracoronary stenting (MATTIS). *Circulation* 1998; 98:2126-32
6. Bauters C, Lablanche JM, Van Belle E, Niculescu R, Meurice T, Mc Fadden EP, Bertrand ME: Effects of coronary stenting on restenosis and occlusion after angioplasty of the culprit vessel in patients with recent myocardial infarction. *Circulation* 1997; 96:2854-8
7. Ellis SG, Efron MB, Gold HK, Leon MB, Popma JJ, Serruys P, Colombo A, Cohen N, Juran N, Werner W, Heuser RR, Spooner S, Rihal CS, Fox R, Leon MB, Brennan J, Ricci D, Fox R, Teirstein PS, Norman S, Morris N, Zidar J, Rund M: Acute platelet inhibition with abciximab does not reduce in-stent restenosis (ERASER study). *Circulation* 1999; 100:799-806
8. Kornowski R, Hong MK, Virmani R, Jones R, Vodovotz Y, Leon MB: Granulomatous 'foreign body reactions' contribute to exaggerated in-stent restenosis. *Coron Artery Dis* 1999; 10:9-14

Anesthesiology 2001; 94:369-71

© 2001 American Society of Anesthesiologists, Inc. Lippincott Williams & Wilkins, Inc.

Fatal Thrombosis Associated with a Hemi-Fontan Procedure, Heparin-Protamine Reversal, and Aprotinin

Stephanie W. Heindel, M.D.,* Michael R. Mill, M.D.,† Eugene B. Freid, M.D.,‡ Robert D. Valley, M.D.,§ Gilbert C. White II, M.D.,|| Edward A. Norfleet, M.D.#

THIS report describes a fatal thrombotic complication after revision of a hemi-Fontan procedure. The potential dangers of drug interactions that alter the coagulation cascade during cardiopulmonary bypass are discussed.

Case Report

The patient was an 11-month-old, 8.3-kg infant with complex single-ventricle physiology consisting of double-inlet left ventricle, tricuspid atresia, L-transposition of the great arteries, hypoplastic aortic arch, and ductal-dependent systemic circulation. The child initially underwent a Damus-Kaye-Stancil procedure, repair of a hypoplastic aortic arch, and placement of a right modified Blalock-Taussig shunt at 3 weeks of age. At 11 months of age, the patient underwent a hemi-Fontan procedure and takedown of the Blalock-Taussig shunt. Postoperatively, echocardiography showed a baffle leak from the superior vena cava to the right atrium. The patient returned to surgery for baffle revision. The patient was administered aprotinin (30,000 Kallikrein inhibitor units [KIU]/kg body weight intravenously and 30,000 KIU/kg added to the cardiopulmonary bypass circuit, similar to the protocol described by Dietrich *et al.*¹). Continuous infusion of aprotinin was not used. The patient was anticoagulated with 300 U/kg body weight heparin, and cardiopulmonary bypass was initiated. A trabeculation was found to be the source of the leak, and the atrial patch was repaired. During cardiopulmonary bypass, additional heparin was administered as needed to maintain a kaolin activated clotting time in excess of 480 s. Activated clotting times were obtained every 30 min and were greater than 480 s, except for one, which was 408 s, just before the termination of cardiopulmonary bypass. The patient was administered an additional 500 U heparin. A follow-up activated clotting time was not obtained because bypass was discontinued shortly thereafter. Cardiopulmonary bypass was discontinued successfully with stable systemic oxygen saturation and good ventricular function as shown by transesophageal echocardiography. Protamine was administered *via* the right internal jugular vein central venous catheter. Initially, 8 mg protamine (one third of the calculated required dose of 3 mg/kg body weight) was administered. Suddenly, transesophageal echocardiography revealed multiple echo-dense structures in the heart (fig. 1). Initially, these intracardiac, echo-dense structures were worm-like in appearance, but these images were not recorded. Acutely, the patient became hypotensive, and the ECG showed ST-segment elevation. Heparin was readministered, and cardiopulmonary bypass

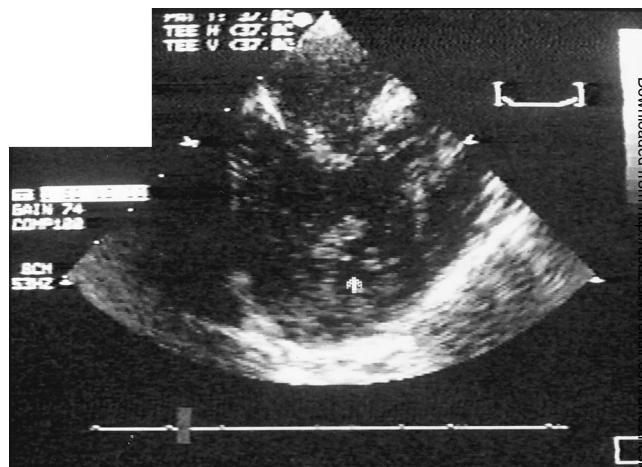


Fig. 1. Transesophageal echocardiographic image of the patient's left atrium and single ventricle with thrombus in the ventricle and adjacent to the mitral valve (arrows).

was reinitiated. Tissue plasminogen activator was administered (0.06 mg/kg load, followed by $0.7 \text{ mg} \cdot \text{kg}^{-1} \cdot \text{h}^{-1}$ for 1 h, then $0.25 \text{ mg} \cdot \text{kg}^{-1} \cdot \text{h}^{-1}$ for an additional 2 h) in an attempt to reverse the systemic thrombosis. The patient was again weaned from cardiopulmonary bypass. However, because of the persistent loss of the femoral arterial waveform and the onset of systemic acidosis and anuria, we suspected abdominal aortic thrombi. Thrombectomy of the abdominal aorta was performed with return of good distal perfusion and urine output. Despite maximal inotropic support, the patient remained hypotensive and hypoxic with poor ventricular function. Extracorporeal membrane oxygenation was initiated. The initial coagulation results after the patient's catastrophic systemic thrombosis were significant for a prothrombin time greater than 90 s, an activated partial thromboplastin time greater than 150 s, a thrombin clot time greater than 90 s, a fibrinogen of 48 mg/dl, fibrinogen D-dimers greater than 2,000 ng/ml, and an antithrombin III (AT III) concentration 16% of normal. After approximately 48 h of extracorporeal membrane oxygenation support, the child had ongoing coagulopathy and evidence of an intracranial hemorrhage. At the parents' request, support was withdrawn. A limited autopsy had findings consistent with an intracranial hemorrhage.

* Resident, || Professor of Medicine, # Professor and Executive Vice Chair, Department of Anesthesiology, † Professor of Surgery and Chief, Division of Cardiothoracic Surgery, ‡ Associate Professor of Anesthesiology, § Associate Professor of Anesthesiology and Chief, Division of Pediatric Anesthesiology.

Received from the Department of Anesthesiology, University of North Carolina School of Medicine, Chapel Hill, North Carolina. Submitted for publication June 1, 2000. Accepted for publication October 4, 2000. Supported by the University of North Carolina School of Medicine and Dr. Heindel.

Address reprint requests to Dr. Heindel: Anesthesia Service of Eugene, P.C., 1200 Hilyard Street, Suite S-410, Eugene, Oregon 97401-8122. Address electronic mail to: stephh@uswest.net. Individual article reprints may be purchased through the Journal Web site, www.anesthesiology.org.

Discussion

We hypothesize that the etiology of the thrombi formation was multifactorial: a divided venous circulation, a relatively low flow state in the pulmonary circulation, the administration of aprotinin, heparin-protamine reversal, and possibly AT III deficiency. The patient's hemi-

Fontan anatomy resulted in a divided venous circulation. For thrombi to return to the systemic ventricle, the thrombi would have to originate in the inferior vena cava system, in the pulmonary veins, or in the heart itself. We think the most likely site of origination of the thrombi was in the pulmonary veins. Before the appearance of the thrombi, cardiac function was good, making intracardiac formation of clots unlikely. The temporal correlation between clot formation and the infusion of protamine through the right internal jugular vein coupled with the relative degree of lower flow in the pulmonary circulation could provide conditions conducive to thrombi formation.

The use of aprotinin favoring a procoagulant state must be considered. Aprotinin has many potential benefits. Aprotinin reduces blood loss after cardiac surgery in children¹⁻³ and may ameliorate the inflammatory effects of cardiopulmonary bypass.⁴ In a review of patients undergoing Fontan and bidirectional cavopulmonary shunt procedures, aprotinin use was associated with a decrease in the early postoperative transpulmonary gradient.⁵

Despite the significant benefits of using aprotinin, potential complications exist. A hypercoagulable state may result from aprotinin because of its ability to inhibit plasmin, block the fibrinolytic system, inhibit the intrinsic coagulation system, and reduce thrombin formation.⁶ Studies have suggested an association between the use of aprotinin and an increased rate of vein graft occlusion after coronary artery surgery.⁷ Aprotinin has been associated with unexpected formation of thrombi on pulmonary artery catheters.⁸ Thrombotic episodes associated with aprotinin have occurred in children undergoing repair of congenital heart defects, as well.²

Reports have assessed the influence of deep hypothermia and circulatory arrest (DHCA) and aprotinin on coagulation in adults. In these studies, there is speculation that the cessation of blood flow or the reduction of blood flow combined with hypothermia led to activation of the coagulation system with adverse consequences. Sundt *et al.*⁹ compared patients undergoing aortic surgery using DHCA treated with aprotinin to those patients undergoing similar procedures not treated with aprotinin. Patients treated with aprotinin had a greater incidence of renal dysfunction, myocardial infarction, and death. Platelet-fibrin thrombi were present in multiple organs of those patients treated with aprotinin who had the morbid consequences of myocardial infarction or failure, stroke, or renal dysfunction. Sundt *et al.*⁹ proposed that, in the special situation of profound hypothermia with low flow or circulatory arrest, the use of aprotinin may predispose to disseminated intravascular coagulopathy, possibly by aprotinin's ability to inhibit protein C. However, Dietrich and Mossinger¹⁰ reported that in more than 500 children, 60% of whom were exposed to DHCA, there were no thromboembolic com-

plications. They concluded that DHCA does not constitute a contraindication to the use of aprotinin, at least in the pediatric population. Although the patient we describe was not exposed to DHCA, conditions in the pulmonary venous system in the current patient would be similar to those encountered systemically during DHCA.

A low plasma AT III concentration in our patient may have been a factor to favor a procoagulant state. AT III deficiency was present after thrombi formation, but a unit of fresh frozen plasma was added to the pump prime, possibly correcting a preoperative AT III deficiency, if it existed.

The temporal relation between the dosing of protamine and the formation of thrombi is remarkable because the formation of intravascular thrombi after heparin reversal is rare. A low-flow state in the pulmonary venous system, coupled with the use of aprotinin and possibly a low AT III concentration, may provide conditions that would result in the formation of thrombi after heparin-protamine reversal. Aprotinin may mask inadequate heparinization *via* its ability to prolong the activated clotting time.^{11,12} There are reports suggesting that inadequate heparinization may result in diffuse intravascular coagulation syndromes during cardiopulmonary bypass when aprotinin is used.¹³

In summary, we present a case of a fatal thrombotic complication after cardiopulmonary bypass in an infant with complex heart disease. We hypothesize that the administration of protamine through the right internal jugular vein in a patient with hemi-Fontan anatomy may be a dangerous practice that, when coupled with a relatively low-flow state in the pulmonary venous system, may contribute to the formation of thrombosis in the pulmonary veins. The use of aprotinin and possibly low plasma AT III concentration could further contribute to a procoagulant state. Despite the benefits observed in open-heart surgery patients after the use of aprotinin, the use of aprotinin may not be without serious complications under certain conditions.

References

1. Dietrich W, Mössinger H, Spannagl M, Jochum M, Wendt P, Barankay A, Meisner H, Richter JA: Hemostatic activation during cardiopulmonary bypass with different aprotinin dosages in pediatric patients having cardiac operations. *J Thorac Cardiovasc Surg* 1993; 105:712-20
2. Penkoske P, Entwistle L, Marchak B, Seal R, Gibb W: Aprotinin in children undergoing repair of congenital heart defects. *Ann Thorac Surg* 1995; 60: S529-32
3. D'Errico C, Shayevitz J, Martindale S, Mosca R, Bove E: The efficacy and cost of aprotinin in children undergoing reoperative open heart surgery. *Anesth Analg* 1996; 83:1193-9
4. Westaby S: Aprotinin in perspective. *Ann Thorac Surg* 1993; 55:1033-41
5. Tweddell J, Berger S, Frommelt P, Pelech A, Lewis D, Fedderly R, Frommelt M, McManus T, Mussatto K, Kessel M, Litwin B: Aprotinin improves outcome of single-ventricle palliation. *Ann Thorac Surg* 1996; 62:1329-36
6. Robert S, Wagner B, Boulanger M, Richer M: Aprotinin. *Ann of Pharmacotherapy* 1996; 30:372-80

7. van der Meer J, Hillege H, Ascoop C, Dunselman P, Mulder B, van Ommen G, Pfisterer M, van Gilst W, Lie K: Aprotinin in aortocoronary bypass surgery: Increased risk of vein-graft occlusion and myocardial infarction? Supportive evidence from a retrospective study. *Thromb Haemost* 1996; 75:1-3
8. Bohrer H, Fleischer F, Lang J, Vahl C: Early formation of thrombi on pulmonary artery catheters in cardiac surgical patients receiving high-dose aprotinin. *J Cardiothorac Anesth* 1990; 4:222-5
9. Sundt T, Kouchoukos N, Saffitz J, Murphy S, Wareing T, Stahl D: Renal dysfunction and intravascular coagulation with aprotinin and hypothermic circulatory arrest. *Ann Thorac Surg* 1993; 55:1418-24
10. Dietrich W, Mossinger H: The use of aprotinin in pediatric cardiopulmonary bypass, *Blood Conservation with Aprotinin*. Edited by Pifarre R. Philadelphia, Hanley & Belfus, 1995, pp 275-86
11. Wang J-S, Lin C-Y, Hung W-T, Thisted R, Karp R: In vitro effects of aprotinin on activated clotting time measured with different activators. *J Thorac Cardiovasc Surg* 1992; 104:1135-40
12. Wang J-S, Lin C-Y, Hung W-T, Karp R: Monitoring of heparin induced anticoagulation with kaolin-activated clotting time in cardiac surgical patients treated with aprotinin. *ANESTHESIOLOGY* 1992; 77:1080-4
13. Feindt P, Seyfert U, Volkmer I, Huwer H, Kalweit G, Gams E: Is there a phase of hypercoagulability when aprotinin is used in cardiac surgery? *Eur J Cardiothorac Surg* 1994; 8:308-14