

Subcutaneous Paravertebral Block for Renal Colic

Sergei Nikiforov, M.D.,* Arthur J. Cronin, M.D.,† W. Bosseau Murray, M.B., Ch.B.,‡ Virginia E. Hall, M.D.§

WE report the successful treatment of renal colic using a paravertebral subcutaneous injection of local anesthetic. The mechanism for this analgesia is unclear, but it is possibly best explained by Melzac and Wall's "gate theory" of pain. The chief limitation of this therapy is its short duration.

Case Report

A 26-yr-old woman, with an intrauterine pregnancy at 29 ½ weeks' gestation, presented to the emergency room of The Milton S. Hershey Medical Center reporting severe pain in the right flank. Abdominal ultrasound did not show a renal or ureteral calculus, but delayed contrast filling of the right urinary collecting system seen on an abdominal computed tomography scan was consistent with right ureteral obstruction. The patient was admitted to the obstetrics ward for pain control and observation, with plans to perform percutaneous nephrostomy if the ureteral obstruction did not resolve.

Despite administration of 150 mg meperidine and 8 mg morphine intravenously over a 4-h period, the patient reported persistent severe pain, prompting consultation with the Acute Pain Management Service. The Acute Pain Management Service performed a subcutaneous paravertebral field block in the following manner. The patient was placed in the left lateral decubitus position. Using the inferior angle of the scapula and the iliac crest as landmarks for T7 and L4 spinal levels, respectively, the T10 and L2 spinous process were identified. After sterile preparation of the skin, a continuous subcutaneous weal of 2% lidocaine (6 ml) was created 4 cm to the right of midline, extending between T10 and L2 using a ½-in 25-gauge needle (fig. 1).

Before the injection, the patient reported her pain as 10 of 10 according to the visual analog scale (VAS). Five minutes after the injection, the pain was 2 of 10, and 5 min later it was 0 of 10. The patient was pain free for 2 h. Pain gradually returned, and the block was repeated when the pain score reached 7 of 10. For the second block, 6 ml bupivacaine, 0.25%, was infiltrated. Again the pain score decreased to 0 of 10 for 2 h. When the pain score reached 6 of 10, intravenous meperidine (75 mg) was administered to the patient. Two hours later, with a pain score of 1 or 2 of 10, the patient was brought to the radiology department for percutaneous nephrostomy, which was unsuccessful because of an inability to access the renal pelvis. Then, the patient was brought to the operating room for cystoscopy with ureteroscopy and ureteral stent placement during spinal anesthesia. The next day the patient was discharged free of pain with the ureteral stent in place.

* Resident, † Assistant Professor, ‡ Professor, Department of Anesthesiology, § Associate Professor, Department of Obstetrics and Gynecology.

Received from the Department of Anesthesiology, The Milton S. Hershey Medical Center, The Pennsylvania State University College of Medicine, Hershey, Pennsylvania. Submitted for publication June 19, 2000. Accepted for publication September 26, 2000. Support was provided solely from institutional and/or departmental sources.

Address reprint requests to Dr. Cronin: Department of Anesthesiology, H187, The Milton S. Hershey Medical Center, The Pennsylvania State University College of Medicine, 500 University Drive, P.O. Box 850, Hershey, PA 17033-0850. Address electronic mail to: acronin@psu.edu. Individual article reprints may be purchased through the Journal Web site, www.anesthesiology.org.

Discussion

We have presented a short-lived but simple, inexpensive, low-risk, and effective technique for treating pain associated with renal colic. In the United States, standard treatment for renal colic pain is administration of intravenous opioid or ketorolac.¹ Side effects of nausea, pruritus, and smooth muscle spasm limit the usefulness of opioids, and the renal and gastrointestinal side effects of ketorolac are unacceptable in some patients.^{2,3} Alternatively, neuraxial blockade using an epidural catheter provides excellent continuous analgesia and has the advantage of the possible use of the catheter for surgical anesthesia if a stone must be extracted or destroyed. The small but real risk associated with placement of an epidural catheter and the side effects of epidural analgesia must be considered because 64% of pregnant patients with renal colic pass stones spontaneously.⁵ Although the pain relief after each paravertebral injection was superior to that provided by opioids and although the injection had no side effects, the relief lasted only 2 h. This short therapeutic effect was a limitation of the technique in this patient, but permanent results are obtained in some patients in whom pain is caused by ureteral spasm.⁶ The proposed mechanism for this long-lasting effect is the relief of pain-induced ureteral spasm and subsequent passage of the ureteral stone.

The mechanism whereby subcutaneous infiltration of local anesthetic blocks the pain of ureteral colic is unknown. Although the neural structure that carries the nociceptive information of renal colic from the kidney or ureter to the spinal cord and thence to the brain has not been defined clearly, the sensory innervation of the kidney and ureter occurs *via* diffusely organized renal testicular (ovarian), and hypogastric plexuses. Afferent fibers travel with the sympathetic nerves and enter the spinal cord at the T10-L2 spinal nerves.⁷ It is difficult to conceive of a mechanism whereby this neural pathway could be blocked directly by local anesthetic that infiltrated the paravertebral subcutaneous tissue. More complicated neural circuitry must be postulated to account for the therapeutic success of the block. The duration and quality of the pain relief achieved by infiltration of 2% lidocaine and 0.25% bupivacaine were indistinguishable. If we had administered very different doses of local anesthetic, we would be able to comment on the probable mechanism of action of the drug when used in this manner. However, evidence from other studies shows that subcutaneous infiltration of water relieved renal colic, myofascial pain, and back pain during labor.^{8,9}

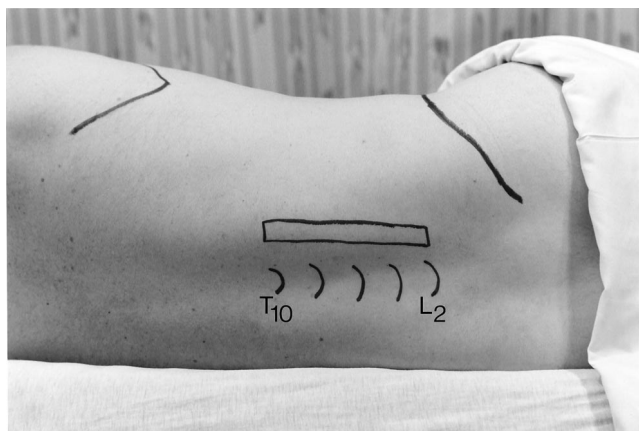


Fig. 1. The landmarks (angle of the scapula, processus spinosus, and iliac crest) for locating the T10–L2 paravertebral region are identified. Subcutaneous infiltration was performed in the region demarcated by the rectangle.

Subcutaneous field block for treatment of renal colic, as used in this patient, was described in the Soviet medical literature^{6,10} and is part of the standard medical practice in Russia. These descriptions report equally successful results using saline or local anesthetic infiltration. Indeed, acupuncture using needle insertion points in the paraspinous lower thoracic and upper lumbar area has been reported to control renal colic.^{11,12} In addition to having centuries' worth of evidence that supports the findings of its effectiveness for the treatment of renal colic, acupuncture in this application is supported by the "gate theory" of pain.¹³ According to this theory, dermatomal activity in primary afferent fibers generated by performing the block or by inserting acupuncture needles would stimulate inhibitory circuits in the superficial laminae of the dorsal horn. These inhibitory neurons would prevent the transmission of nociceptive pri-

mary afferent activity from these dermatomes (the C fibers) to either local reflex arcs or ascending pain pathways. This case report supports the investigation findings regarding the effectiveness of alternative therapies for the short-term relief of renal colic pain.

The authors thank Fredrick K. Orkin, M.D., the Department of Anesthesiology, for photographic assistance; Lihua Xu, M.D., L.Ac., the Department of Internal Medicine, for assistance with traditional Chinese medicine; and Daniel P. Williams, D.O., the Department of Anesthesiology, Carol C. Coulson, M.D., the Department of Obstetrics and Gynecology, and Thomas J. Rohner Jr., M.D., the Department of Urology, for review of this manuscript. All are affiliated with The Milton S. Hershey Medical Center, The Pennsylvania State University College of Medicine, Hershey, Pennsylvania.

References

1. Feldman HI, Kinman JL, Berlin JA, Hennessy S, Kimmel SE, Farrar J, Carso JL, Strom BL: Parenteral ketorolac: The risk for acute renal failure. *Ann Intern Med* 1997; 126:193–9
2. Larkin GL, Peacock WF 4th, Pearl SM, Blair GA, D'Amico F: Efficacy of ketorolac tromethamine versus meperidine in the ED treatment of acute renal colic. *Am J Emerg Med* 1999; 17:6–10
3. Strom BL, Berlin JA, Kinman JL, Spitz PW, Hennessy S, Feldman H, Kimmel SE, Carson JL: Parenteral ketorolac and risk of gastrointestinal and operative site bleeding: a postmarketing surveillance study. *JAMA* 1996; 275:376–82
4. Ready LB, Johnson ES: Epidural block for treatment of renal colic during pregnancy. *Can Anaesth Soc J* 1981; 28:77–9
5. Parulkar BG, Hopkins TB, Wollin MR, Howard PJ Jr, Lal A: Renal colic during pregnancy: A case for conservative treatment. *J Urol* 1998; 159:365–8
6. Rossikhin VV: Effectiveness of M.N: Astvatsurov's block for renal colic. *Klin Khir* 1978; 2:74–5
7. Snell RS: *Clinical Anatomy for Medical Students*, 2nd edition. Boston, Little Brown and Company, 1995, pp 226–8
8. Byrn C, Borenstein P, Linder LE: Treatment of neck and shoulder pain in whip-lash syndrome patients with intracutaneous sterile water injections. *Acta Anaesthesiol Scand* 1991; 35:52–3
9. Labrecque M, Nouwen A, Bergeron M, Rancourt JF: A randomized controlled trial of nonpharmacologic approaches for relief of low back pain during labor. *J Fam Pract* 1999; 48:259–63
10. Puterman NS: Treatment of the renal colic. *Vestn Khir Im I I Grek* 1973; 110:113–4
11. Lee YH, Lee WC, Chen MT, Huang JK, Chung C, Chang LS: Acupuncture in the treatment of renal colic. *J Urol* 1992; 147:16–8
12. Zhang E: *Chinese Acupuncture and Moxibustion*. Shanghai, Publishing House of Shanghai University of Traditional Chinese Medicine, 1996, pp 516–
13. Wall PD, Melzak R: *Textbook of Pain*, 3rd edition. New York, Churchill Livingstone, 1994, p 1191

Anesthesiology 2001; 94:532–4

© 2001 American Society of Anesthesiologists, Inc. Lippincott Williams & Wilkins, Inc.

Life-threatening Upper Airway Obstruction after Tongue Base Surgery

Joseph W. Szokol, M.D.,* Barry L. Wenig, M.D.,† Glenn S. Murphy, M.D.,‡ Elizabeth Drezek, C.R.N.A.§

ANESTHESIOLOGISTS are faced with myriad surgical procedures designed to alleviate sleep-disordered

breathing in patients with obstructive sleep apnea (OSA). The main concern in caring for these patients is the potential difficult airway in many of these patients and also the comorbidities caused by OSA. We report a case of immediate postoperative airway obstruction that necessitated emergency cricothyrotomy after performance of a relatively new procedure called tongue suspension or tongue base surgery.¹

Case Report

The patient is a 48-yr-old man who presented to the operating room for tongue suspension for OSA. The patient underwent laser surgery

* Assistant Professor of Anesthesiology and Vice Chairman, † Professor, ‡ Assistant Professor of Anesthesiology, Department of Anesthesiology, Evanston Northwestern Healthcare, Northwestern University Medical School. § Department of Anesthesiology, Evanston Northwestern Healthcare.

Received from the Department of Anesthesiology, Evanston Northwestern Healthcare, Evanston, Illinois, and the Department of Anesthesiology, Northwestern University Medical School, Chicago, Illinois. Submitted for publication July 14, 2000. Accepted for publication October 4, 2000. Support was provided solely from institutional and/or departmental sources.

Address reprint requests to Dr. Szokol: Department of Anesthesiology, 2650 Ridge Avenue, Evanston, Illinois 60201. Address electronic mail to: Szokol@nwu.edu. Individual article reprints may be purchased through the Journal Web site, www.anesthesiology.org.

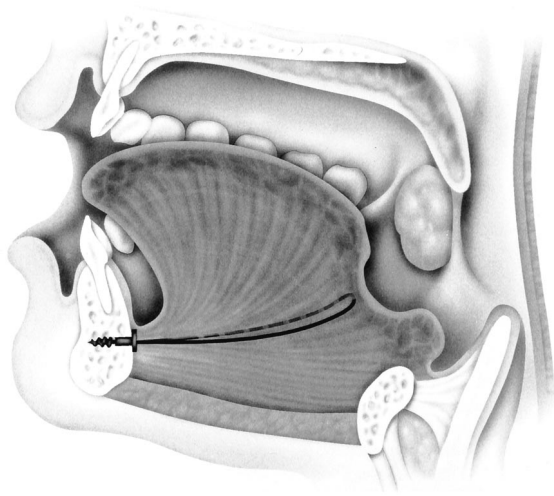


Fig. 1. Soft tissue-to-bone anchor in the mandible with attached suture pulling the tongue forward.

6 weeks previously to reduce redundant pharyngeal tissues. This was accomplished without improvement of his symptoms.

The patient had used a continuous positive airway pressure mask at home without relief of symptoms. The patient had a history of hypertension and gastroesophageal reflux disease (GERD). He weighed 155 kg and was 70 in tall. Airway examination consisted of a Mallampati I, which showed good range of motion of his cervical spine and adequate thyromental distance. The patient was taken to the operating room, and standard monitors were applied. In the operating room, 2 mg midazolam was administered to the patient in 1-mg aliquots. His right naris was anesthetized with 4 ml cocaine, 4%. Then, an induction of 150 mg propofol was administered, followed by 140 mg succinylcholine. A 7.0 wire-reinforced tube was passed easily through the right naris, but the vocal cords could not be identified using a Macintosh No. 3 blade. Oxygen saturation decreased to 90%, and mask ventilation with jaw thrust and an oral airway was difficult to perform. A Miller No. 3 was inserted into his mouth and a grade 1 visualization of the vocal cords was achieved. An 8.0 endotracheal tube was passed through his mouth and then past the vocal cords. At the request of the surgeon, the wire-reinforced tube was reinserted into the right naris and passed through the vocal cords as the 8.0 endotracheal tube was removed.

Afterward, the patient underwent tongue suspension surgery. The surgery was uneventful. At the conclusion of surgery, administration of the anesthetic agent (isoflurane) was discontinued. The patient was returned to spontaneous ventilation, and then was reversed with neostigmine and glycopyrolate. Negative inspiratory force of the patient was greater than 40 cm H₂O, tidal volume was greater than 500 ml, sustained head lift lasted 5 s, and the patient followed commands. The patient was then extubated. He was able to take three breaths in which stridor was heard and then complete airway occlusion occurred. The patient could not undergo ventilation *via* mask with an oral airway or by two-handed mask ventilation. Oral intubation was impossible because of redundant and swollen oropharyngeal tissues. A No. 4 laryngeal mask airway was introduced into the patient's mouth, through which assisted ventilation was possible but difficult. Oxygen saturation was maintained in the low 80 range. The decision was made to perform emergency cricothyrotomy. Subsequent direct laryngoscopy showed a markedly swollen epiglottis and grossly edematous laryngeal and hypopharyngeal tissue.

Postoperative radiography was consistent with pulmonary edema secondary to negative-pressure pulmonary edema. Initial blood gas at 100% oxygen showed a partial pressure of arterial oxygen (PaO₂) of 78, which, with 10 cm positive end expiratory pressure, increased to a

PaO₂ of 91 at 60% oxygen. Oxygenation improved the next morning; PaO₂ was 106 at 40% oxygen.

Two days later, the patient was brought to the operating room for direct laryngoscopy and possible oral intubation. The examination showed a markedly swollen epiglottis and redundant supraglottic tissues. The vocal cords were not viewable. The decision was made to perform tracheostomy with cricothyrotomy. Hospital course was uneventful and the patient was discharged on the eighth postoperative day. Two weeks later, the tracheostomy was closed. Significant subjective improvement was seen in the sleep apnea, and the patient no longer required the use of a continuous positive airway pressure mask.

Discussion

Surgical correction of OSA using uvulopalatopharyngoplasty has shown a high failure rate.² Several surgical techniques are available for the treatment of OSA that are directed at relieving the tongue base collapse. These include midline glossectomy, mandibular advancement limited mandibular osteotomies with genioglossal advancement, and hyoid bone suspension. These surgical approaches are available because 80% of patients with OSA have an obstruction at the retropalatal segment of the mouth, and 50% of these patients also have an obstruction at the retroglottal segment.³ The technique of using a suspension screw to support the base of the tongue was first presented at the American Academy of Otolaryngology-Head and Neck Surgery annual meeting in 1998.⁴

The technique of tongue advancement or tongue base stabilization involves the use of a soft tissue-to-bone anchor inserted intraorally in the mandible with an attached suture that is passed through the tongue. The suture loop causes traction on the tongue base (fig. 1). By pulling the tongue forward and creating a small indentation at the base of the tongue, this technique might be used as part of a multimodal attempt at alleviating the symptoms of OSA in patients in whom a significant portion of disease was caused by tongue displacement. Initial results of the procedure have been positive. In a recent study,⁵ 16 patients underwent the procedure. Two patients had short-term complications related to pain and infection, and the procedure was reversed. These patients were excluded from the data analysis. Of the 14 other patients, varying rates of improvement in snoring were seen, and a statistically significant decrease of 53% in mean respiratory distress index was noted in all patients. However, this study had a short follow-up time of 6 months, and patients with severe obesity, as was the case with our patient, were excluded from the study. There were no cases of postoperative airway compromise.

Possible causes of airway obstruction in the current patient include soft tissue obstruction, laryngospasm, a foreign body, or an allergic reaction. Laryngospasm was not a possibility because before direct laryngoscopy and after cricothyrotomy neuromuscular blocking agents were administered to the patient, which should have

relieved laryngospasm. Also, no foreign body was found. The swollen tissues might have been caused by an allergic reaction, but the patient had no other symptoms indicating an allergic reaction. The fact that the airway was manipulated during tongue suspension would indicate that this was the cause of the airway swelling in the current patient.

In conclusion, the anesthesiologist is faced with many procedures directed at relieving airway obstruction in patients with OSA. We report a case in which performance of a new procedure directed at alleviating the obstruction at the tongue base resulted in immediate postoperative life-threatening airway obstruction, necessitating emergency cricothyrotomy. Anesthesiologists must be prepared to deal with potential airway obstruction in patients with OSA and take measures to safeguard

the airway. These methods might include delayed extubation, use of an endotracheal tube changer, or otolaryngologist standby for possible establishment of an emergency surgical airway.

References

1. DeRowe A, Woodson T: A minimally invasive technique for tongue base stabilization in obstructive sleep apnea. *Otolaryngol Head Neck Surg* 2000; 11:41-6
2. Shepard JW, Olsen KD: Uvulopalatopharyngoplasty for the treatment of obstructive sleep apnea. *Mayo Clin Proc* 1990; 65:1260-67
3. Kuna ST: Anatomy and physiology of upper airway obstruction, *Principles and Practice of Sleep Medicine*, 3rd edition. Edited by Kryger MH, et al. Philadelphia, Saunders, 2000, pp 840-58
4. Coleman J, Bick PA: Suspension sutures for the treatment of obstructive sleep apnea and snoring. *Otolaryngol Clin North Am* 1999; 32:277-85
5. DeRowe A, Gunther E, Fibbi A, Lehtimaki K, Vahatalo K, Maurer J, Ophir D: Tongue-base suspension with a soft tissue-to-bone anchor for obstructive sleep apnea: Preliminary clinical results of a new minimally invasive technique. *Otolaryngol Head Neck Surg* 2000; 122:100-3

Anesthesiology 2001; 94:534-6

© 2001 American Society of Anesthesiologists, Inc. Lippincott Williams & Wilkins, Inc.

Postoperative Neuropathy following Fascia Iliaca Compartment Blockade

Arthur Atchabahian, M.D.,* Anthony R. Brown, M.B., Ch.B.†

THE fascia iliaca compartment block¹ has been used to provide postoperative analgesia after knee and hip surgery.²⁻⁴ This nerve block may be performed before induction, during the course of anesthesia, or after emergence. The safety of performing regional anesthesia in an anesthetized adult patient has been questioned. It is essential that every effort be made to minimize the potential for nerve damage because the warning signs of paresthesia or pain are lost during injection. Use of a fascia iliaca compartment block rather than a traditional (three-in-one) femoral nerve block should provide an additional margin of safety because the needle is inserted in an area distant from the femoral nerve and vessels. We report a case in which a patient underwent a fascia iliaca compartment block at completion of surgery during spinal anesthesia and in which hypoesthesia subsequently developed, and resolved after 8 days, in the distribution of the femoral nerve.

Case Report

A 78-yr-old woman with a history of degenerative joint disease was scheduled to undergo left total hip replacement. Medical history was positive for hypertension, mild mitral regurgitation, paroxysmal atrial

fibrillation, chronic active hepatitis, and hypothyroidism. The patient had no history of diabetes and no preexisting neuropathy.

She received an L3-L4 spinal anesthetic, which consisted of 15 mg isobaric bupivacaine, 0.5%, and 25 μ g fentanyl. The surgical procedure was uneventful. The patient received 3 mg midazolam and 150 μ g fentanyl intravenously during the 3-h procedure. At completion of the surgical procedure, a left fascia iliaca compartment block was performed, as described by Dalens *et al.*,¹ to block the femoral and the lateral femoral cutaneous nerves. The injection is administered approximately 1 cm below the inguinal ligament, at the junction of the lateral third and the medial two thirds of a line that joins the pubic spine to the anterior superior iliac spine (fig. 1A). After the short bevel needle traverses the skin, two "pops" are felt. The first corresponds to the fascia lata, the second to the fascia iliaca (fig. 1B). A loss of resistance then is experienced. Forty milliliters of bupivacaine, 0.5%, was injected without untoward effects. The patient was admitted to the postanesthesia care unit.

After resolution of the spinal anesthetic, the anterior, medial, and lateral aspects of the left thigh remained anesthetized, indicating successful fascia iliaca compartment block. The patient reported mild left hip pain (visual analog scale score, 2 or 3) that was controlled readily using oral analgesics.

Twenty-four hours later, the patient continued to exhibit complete anesthesia over the anterior thigh. No hypoesthesia was found in the areas innervated by the lateral femoral cutaneous nerve (*i.e.*, lateral aspect of the thigh) or by the obturator nerve (*i.e.*, medial aspect of the knee.) Motor strength of the quadriceps muscle seemed to be decreased; however, accurate evaluation was hindered by postoperative pain. No decrease was noted in muscular strength of the adductor muscle group. There was no tight dressing or hematoma. Hypoesthesia resolved over the ensuing week, with complete resolution occurring on the eighth postoperative day. Because of the rapid resolution of the neuropathy, a neurologist was not consulted.

Discussion

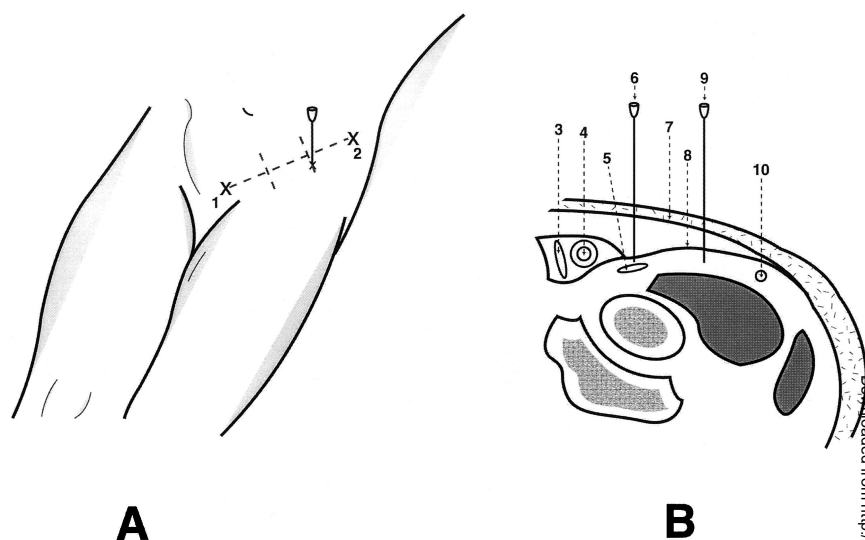
Numerous advantages have been attributed to regional *versus* general anesthesia for lower limb surgery, includ-

* Resident, †Associate Professor.

Received from the Department of Anesthesiology, College of Physicians and Surgeons, Columbia University, New York, New York. Submitted for publication May 22, 2000. Accepted for publication October 12, 2000. Support was provided solely from institutional and/or departmental sources.

Address reprint requests to Dr. Brown: Department of Anesthesiology, M4-446, The New York-Presbyterian Hospital, 622 West 168th Street, New York, New York 10032. Address electronic mail to: arb6@columbia.edu. Individual article reprints may be purchased through the Journal Web site, www.anesthesiology.org.

Fig. 1. (A) The fascia iliaca compartment block. The needle is inserted perpendicular to the skin, 1 cm caudal to the inguinal ligament at the junction of the lateral one third and the medial two thirds of a line that joins the pubic spine (1) to the anterior superior iliac spine (2). (B) Transverse view at the midinguinal ligament level. (3) Femoral vein; (4) femoral artery; (5) femoral nerve; (6) needle insertion for a femoral or three-in-one nerve block; (7) fascia lata; (8) fascia iliaca; (9) needle insertion for a fascia iliaca compartment block; (10) lateral femoral cutaneous nerve.



ing prolonged postoperative pain control. However, there is controversy whether performing regional anesthesia is safe in an anesthetized adult patient (in the current case, we performed a fascia iliaca compartment block in a patient during spinal anesthesia) and whether the benefits outweigh the risks, as they do in pediatric anesthesia.⁵

Results of numerous studies have supported the belief that pain or paresthesia during needle placement or injection is a warning sign of potential nerve damage.^{6,7} Use of a peripheral nerve stimulator permits the induction of regional anesthesia in an anesthetized patient. It does not eliminate the risk of anesthesia-related nerve damage.^{8,9} Moreover, it is unnecessary to perform a fascia iliaca compartment block.³

There are reports of neurologic complications after femoral nerve blockade, but none to our knowledge after fascia iliaca compartment block. Dalens *et al.*¹ described the use of this block in children, followed by subsequent reports of its use in adults.¹⁰ In addition, a continuous catheter technique has been used to provide prolonged postoperative analgesia.³ When using a nerve block for postoperative analgesia after total hip replacement, a fascia iliaca compartment block provides more reliable blockade of the lateral femoral cutaneous nerve than does a three-in-one block. This results in more effective analgesia in the area of the skin incision.¹⁰

The point of needle insertion should be distant from the course of the femoral nerve; therefore, we performed a fascia iliaca compartment block rather than a femoral nerve block in an anesthetized patient. The needle insertion point is approximately midway between the femoral artery and the anterior superior iliac spine, *i.e.*, approximately 4 cm lateral to the artery in an average-sized person. It is our practice to identify these two landmarks (and hence the position of the femoral nerve immediately lateral to the femoral artery) as a safeguard to avoid inadvertent insertion of the needle in

the direction of the nerve. The width of the femoral nerve at this level is 9–4 mm,¹¹ which makes it unlikely but not impossible³ that the needle is inserted into the lateral aspect of the nerve.

The femoral nerve is derived from the dorsal branches of the second, third, and fourth lumbar ventral rami. It descends initially within the substance of the psoas muscle, emerges from its lower lateral border, and descends to enter the thigh deep into the inguinal ligament, in the groove between the psoas and the iliacus muscles, immediately lateral to the femoral artery. The fascia iliaca separates the nerve from the femoral vessels. Slightly before or at the entrance to the femoral triangle, the femoral nerve separates into numerous branches that supply the muscles and skin of the anterior thigh, knee, and hip joints.¹² Some of the branches of the femoral nerve to the sartorius muscle and neighboring skin depart from the main trunk of the nerve as it emerges under the inguinal ligament.¹¹

We believe that there are three explanations for the transient neuropathy experienced by the patient: (1) incorrect identification of the point of needle insertion; (2) a normal anatomic variation, leading to unanticipated needle contact with the nerve, or (3) related to the surgery rather than the anesthesia. Incorrect identification is unlikely because the landmarks were identified easily (inguinal ligament, femoral artery, and anterior superior iliac spine) and clearly marked before block performance. Postoperative neuropathies associated with hip surgery have been reported; however, usually these involve the sciatic rather than the femoral nerve.^{13,14} This case is a reminder that, although we chose a fascia iliaca compartment block to limit the risk of nerve damage, injury still may occur.

References

1. Dalens B, Vanneville G, Tanguy A: Comparison of the fascia iliaca compartment block with the 3-in-1 block in children. *Anesth Analg* 1989; 69:705–13

2. Allen H, Liu S, Ware P, Nairn CS, Owens BD: Peripheral nerve blocks improve analgesia after total knee replacement surgery. *Anesth Analg* 1998; 87:93-7
3. Longo S, Williams D: Bilateral fascia iliaca catheters for postoperative pain control after bilateral total knee arthroplasty: a case report and description of a catheter technique. *Reg Anesth* 1997; 22:372-7
4. Williams D, Longo S, Cronin A: Continuous lumbar plexus analgesia via the fascia iliaca compartment after total hip arthroplasty. *Am J Anesth* 1998; 25: 177-80
5. Giaufre E, Dalens B, Gombert A: Epidemiology and morbidity of regional anesthesia in children: a one-year prospective survey of the French-Language Society of Pediatric Anesthesiologists. *Anesth Analg* 1996; 83:904-12
6. Selander D, Dhunér K-G, Lundborg G: Peripheral nerve injury due to injection needles used for regional anesthesia: an experimental study of the acute effects of needle point trauma. *Acta Anaesth Scand* 1977; 21:182-8
7. Selander D, Edshage S, Wolff T: Paresthesiae or no paresthesiae? Nerve lesions after axillary blocks. *Acta Anaesth Scand* 1979; 23:27-33

8. Moore D, Mulroy M, Thompson G: Peripheral nerve damage and regional anaesthesia. *Br J Anaesth* 1994; 73:435-6
9. Passannante A: Spinal anesthesia and permanent neurologic deficit after interscalene block. *Anesth Analg* 1996; 82:873-4
10. Capdevila X, Biboulet P, Bouregba M, Barthelet Y, Rubenovitch J, d'Athis F: Comparison of the three-in-one and fascia iliaca compartment blocks in adults: clinical and radiographic analysis. *Anesth Analg* 1998; 86:1039-44
11. Vloka J, Hadzic A, Drobnik L, Ernest A, Reiss W, Thys DM: Anatomical landmarks for femoral nerve block: a comparison of four needle insertion sites. *Anesth Analg* 1999; 89:1467-70
12. Brown D. Lower extremity anatomy, Atlas of Regional Anesthesia. Edited by Brown D. Philadelphia, WB Saunders, 1992, pp 63-72
13. DeHart M, Riley N Jr: Nerve injuries in total hip arthroplasty. *J Am Acad Orthop Surg* 1999; 7:101-11
14. Unwin A, Scott J: Nerve palsy after hip replacement: medicolegal implications. *Int Orthop* 1999; 23:133-7

Anesthesiology 2001; 94:536-8

© 2001 American Society of Anesthesiologists, Inc. Lippincott Williams & Wilkins, Inc.

Metabolic Acidosis Associated with a New Formulation of Propofol

Ahmed E. Badr, M.D.,* George Mychaskiw II, D.O.,† John H. Eichhorn, M.D.‡

PROPOFOL is used for the intravenous induction of anesthesia and for sedation in the intensive care unit. Two formulations of propofol are available in the United States: Diprivan brand (Zeneca Pharmaceuticals, Wilmington, DE) and Propofol (Baxter Pharmaceutical Products, Inc., New Providence, NJ). The formulary of the University of Mississippi School of Medicine recently changed from the Zeneca product to the Baxter product for economic reasons. We report a case of severe metabolic acidosis associated with the new product.

Case Report

A 21-yr-old, 70-kg woman with a left hemispheric arteriovenous malformation presented to the emergency room intubated and unresponsive after reporting headaches and increased right-sided weakness. She was admitted to the neurosurgery service and treated using phenytoin, mannitol, and dexamethasone, and ventriculostomy was performed. Cerebral angiography showed a diffuse, left parietal arteriovenous malformation with hemorrhage from the anterior communicating and middle cerebral arteries. The arteriovenous malformation was embolized, and the patient was treated during deep propofol sedation and hypothermia to 34°C, with reevaluation in 3 or 4 days. An infusion of the Baxter brand propofol was started at 75 $\mu\text{g} \cdot \text{kg}^{-1} \cdot \text{min}^{-1}$ and increased to 150 $\mu\text{g} \cdot \text{kg}^{-1} \cdot \text{min}^{-1}$. Initial measurement of arterial blood gas showed a pH of 7.32, with a partial pressure of carbon dioxide (PCO_2) of 42.7 mmHg (all values corrected to 37°C) and bicarbonate (HCO_3) concentration of 22.3 mm (calculated). After 6 h, pH was 7.44, with a PCO_2 of 29, but the HCO_3 had decreased to 19.7. By 12 h, pH was 7.35, HCO_3 was 17.6, and a base excess of -6.1 mEq

was measured. The patient continued to become increasingly acidotic and was treated with intravenous sodium bicarbonate. Additionally she deteriorated hemodynamically, requiring 10 $\mu\text{g} \cdot \text{kg}^{-1} \cdot \text{min}^{-1}$ dopamine for blood pressure support. The source of acidosis was unclear and thought to be related to hypothermia, hypovolemia, or sepsis. Renal function was normal, with a urine output less than 1 $\text{ml} \cdot \text{kg}^{-1} \cdot \text{h}^{-1}$ and serial creatinine measurements within normal limits. Central venous pressure was maintained in the range of 8-10 mmHg. Arterial blood gas measurement was done approximately 48 h after initiation of the propofol infusion showed a pH of 7.12, PCO_2 of 24, an HCO_3 of 7.9, and a base excess of -19.1. These abnormalities persisted despite aggressive use of sodium bicarbonate. Serum lactate measurement was not performed until 50 h after admission. This showed an increased level of 7.3 mm, which continued to increase to a level of 14 to 15 mm during the propofol infusion and decreased to 8.9 mm after discontinuation of the infusion, and again increased to 14.2 mm just before the patient died. Serum chloride concentration was consistently in the range of 107-115 mm. It was speculated that perhaps the new formulation of propofol could be contributing to the problem and the infusion was discontinued. Within 4 h, arterial blood gas improved and in 12 h pH was 7.37, PCO_2 was 24, HCO_3 was 17, and base excess was -4.5 (fig. 1). The patient also improved hemodynamically, and the administration of dopamine was discontinued. Unfortunately, the patient's neurologic condition continued to deteriorate, followed by a recrudescence of hemodynamic instability (fig. 2). A pulmonary artery catheter was inserted, and pulmonary artery pressures were seen to rapidly increase and cardiac output to decrease, consistent with the patient's overall decline. The patient was pronounced brain dead the next day.

Discussion

Propofol has been used in the intensive care population as a short-acting sedative hypnotic agent administered easily by continuous intravenous infusion. At sedative dose rates (10-50 $\mu\text{g} \cdot \text{kg}^{-1} \cdot \text{min}^{-1}$), it has the advantage of rapid elimination despite prolonged administration, thereby allowing neurologic examinations at frequent intervals and facilitating the weaning of the patient from ventilatory support. Doses necessary for electroencephalographic burst suppression (100-

* Assistant Professor of Anesthesiology and Neurosurgery, † Associate Professor of Anesthesiology, Surgery, and Physiology, ‡ Professor of Anesthesiology.

Received from the Department of Anesthesiology, University of Mississippi School of Medicine, Jackson, Mississippi. Submitted for publication July 6, 2000. Accepted for publication October 13, 2000. Support was provided by the Department of Anesthesiology, University of Mississippi Medical Center.

Address reprint requests to Dr. Mychaskiw: University of Mississippi Medical Center, 2500 North State Street, Jackson, Mississippi 39216-4505. Address electronic mail to: gmychaskiw@anesthesia.umsmed.edu. Individual article reprints may be purchased through the Journal Web site, www.anesthesiology.org.

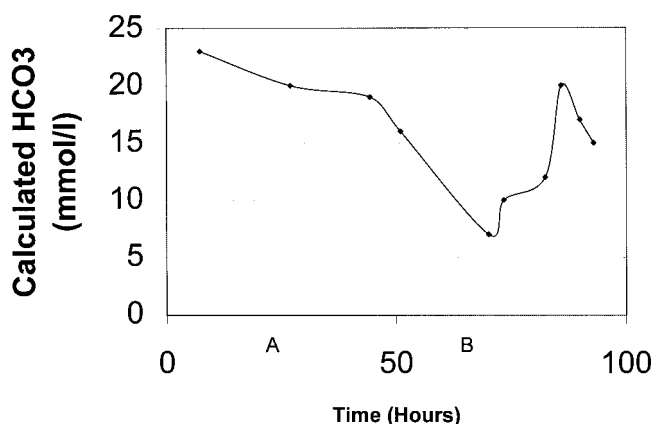


Fig. 1. Patient bicarbonate concentration (HCO_3^- ; calculated from arterial blood gas) versus time. Propofol infusion started at point A and discontinued at point B.

$200 \mu\text{g} \cdot \text{kg}^{-1} \cdot \text{min}^{-1}$) use substantial volumes of propofol, but still offer rapid neurologic examination after discontinuation. At the University of Mississippi School of Medicine, we have not experienced hemodynamic or metabolic derangement associated with use of the Diprivan brand of propofol.

Several difficulties have occurred with the use of propofol, both in the United States and abroad. Initially, there was significant concern regarding its lipid emulsion preparation and ability to support bacterial growth.¹ After extensive education of healthcare professionals about the safe handling of propofol and performing the aseptic technique, this is less of an issue. The nature of the emulsion also has produced numerous reports of pain during injection and patient discomfort,² which again has largely been resolved by addition of lidocaine and other local anesthetics by practitioners to the solution before administration. Most recently, the new preparation of propofol by Baxter has been criticized because of the use of sulfite preservative,³ which may pose a risk of allergic reactions in susceptible patients. This preparation has the advantage, however, of lower cost than the Diprivan brand in many markets and has been chosen by some hospital pharmacies on this basis. Propofol was criticized widely in the United Kingdom and Canada in the late 1990s as a sedative for children in the intensive care unit.⁴⁻⁷ Despite some studies that showed the safety of propofol,^{8,9} numerous reports of unexplained metabolic and lactic acidosis and cardiovascular collapse were published. As a result, propofol sedation of children in the intensive care unit was associated with these complications. The children described were aged 3-12 yr. The use of propofol infusion for the sedation of children in the intensive care unit is controversial.

Diprivan brand¹⁰ of propofol emulsion has a pH of 7.5-8.0, whereas the Baxter¹¹ formulation has a pH of 4.5-6.4. In the current case, the patient's clinical change after discontinuation of the Baxter solution suggests that

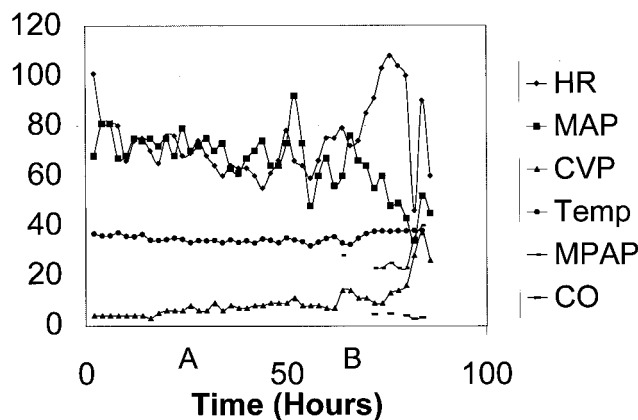


Fig. 2. Patient hemodynamic data versus time. Propofol infusion started at point A and discontinued at point B. A pulmonary artery catheter was not inserted until late in the course of the patient's illness.

this formulation caused her metabolic acidosis. Contributing factors may have been hypothermia, mild hypovolemia, and administration of the greater, neuroprotective dose of propofol rather than the lesser dose used for routine sedation. We estimate that, at a electroencephalographic burst suppression dose of $150 \mu\text{g} \cdot \text{kg}^{-1} \cdot \text{min}^{-1}$ the patient received approximately 3,000 ml propofol over 48 h. In the current case, lactate concentration measurements were not obtained until relatively late in the patient's course, decreasing their diagnostic value. Similarly, pulmonary artery catheterization was not performed until the patient was moribund, but central venous pressure values obtained earlier suggested adequate vascular volume and cardiac performance. It is interesting to speculate about the formulation of propofol used in the children described in the UK case reports. It is reasonable to assume that an exogenous acid load would be tolerated more poorly in a pediatric population and would present the clinical picture described, but the actual formulation used in the UK cases is unclear. The acid load received from an unbuffered solution is usually insignificant, but may contribute to metabolic acidosis and multiple other factors, such as hypothermia and hypovolemia, in a critically ill patient. This is the first case report of metabolic acidosis associated with propofol infusion in an adult. In summary, we present a case in which severe metabolic acidosis developed in an adult patient after the initiation of an infusion of a new brand of propofol. The acidosis resolved after discontinuation of the infusion.

References

1. Arduino MJ, Bland LA, McAllister SK, Aguero SM, Villarino ME, McNeil MM, Jarvis WR, Favero MS: Microbial growth and endotoxin production in the intravenous anesthetic propofol. *Infect Control Hosp Epidemiol* 1991; 12:535-9

2. Johnson RA, Harper NJ, Chadwick S, Vohra A: Pain on injection of propofol: Methods of alleviation. *Anaesthesia* 1990; 45:439-42
3. Langevin PB: Propofol containing sulfite: Potential for injury. *Chest* 1999; 116:1140-1
4. Cray SH, Robinson BH, Cox PN: Lactic acidemia and bradyarrhythmia in a child sedated with propofol. *Crit Care Med* 1998; 26:2087-92
5. Hanna JP, Ramundo ML: Rhabdomyolysis and hypoxia associated with prolonged propofol infusion in children. *Neurology* 1998; 50:301-3
6. Parke TJ, Stevens JE, Rice AS, Greenaway CL, Bray RJ, Smith PJ, Waldmann CS, Verghese C: Metabolic acidosis and fatal myocardial failure after propofol infusion in children: Five case reports. *Br Med J* 1992; 305:613-6
7. Bray RJ: Propofol infusion syndrome in children. *Paediatr Anaesth* 1998; 8:491-9
8. Pepperman ML, Macrae D: A comparison of propofol and other sedative use in paediatric intensive care in the United Kingdom. *Paediatr Anaesth* 1997; 7:143-53
9. Matrin PH, Murthy BV, Petros AJ: Metabolic, biochemical and haemodynamic effects of infusion of propofol for long term sedation of children undergoing intensive care. *Br J Anaesth* 1997; 79:276-9
10. Diprivan [package insert]. Wilmington, DE: Zeneca Pharmaceuticals; 2000
11. Propofol injectable emulsion 1% [package insert]. Deerfield, IL: Baxter Healthcare Corporation; 2000