

## Continuous Venovenous Hemofiltration for the Immediate Management of Massive Rhabdomyolysis after Fulminant Malignant Hyperthermia in a Bodybuilder

Michael R. Schenk, M.D.,\* Dieter H. Beck, M.D., D.E.A.A., E.D.I.C., D.A., D.T.M. & H.,\* Max Nolte, M.D.,† Wolfgang J. Kox, M.D., Ph.D., F.R.C.P.‡

WE report a case of unsuspected fulminant malignant hyperthermia (MH) complicated by life-threatening hyperkalemia and massive rhabdomyolysis, which were managed successfully by early institution of continuous venovenous hemofiltration (CVVH). In addition, we describe the kinetics of myoglobin elimination during prolonged hemofiltration.

### Case Report

A 35-yr-old (100-kg) white man was admitted to the emergency room with history and clinical signs consistent with the diagnosis of peritonsillar abscess. Axillary temperature was 36.5°C; leukocyte count was 15,900/ $\mu$ l. Medical history and physical examination results were unremarkable. The patient regularly performed bodybuilding training but did not report intake of any anabolic drugs or dietary supplements. He had no previous anesthetic exposure and no family history of adverse reactions to anesthesia.

Abscess drainage and tonsillectomy were performed during general anesthesia. Anesthesia was induced with propofol (3 mg/kg) and fentanyl (1.5  $\mu$ g/kg). Rocuronium (0.4 mg/kg) was used for tracheal intubation. At the time of induction of anesthesia, all vital signs were within normal limits. Anesthesia was maintained with 60% nitrous oxide and isoflurane (1-2 vol %) in oxygen using a circle system with carbon dioxide absorber. The patient underwent mechanical ventilation. Ten minutes after induction, a sinus tachycardia of 140 beats/min developed; arterial blood pressure increased to 170/90 mmHg. Five minutes later, the capnograph readings increased from 35 to 70 mmHg, accompanied by an increase in body temperature from 36.9 to 38.9°C. Mechanical ventilation became increasingly impeded by the rigidity of the thoracic cage. Arterial oxygen saturation decreased to 80%. There was extreme muscle rigidity in the upper extremities, with hyperflexion in elbow and wrist joints, and hyperextension of the lower limbs. The diagnosis of MH was made. Anesthetic vapors were discontinued immediately, and ventilation with 100% oxygen was commenced.

Sodium bicarbonate (150 mmol) and 100 g glucose with 20 IU rapid-acting insulin and mannitol (1 g/kg) were administered, and within 25 min, 480 mg intravenous dantrolene had been administered. Arterial blood gases, obtained 20 min after induction, showed severe acidemia and hyperkalemia: pH, 6.94; arterial partial pressure of carbon dioxide ( $P_{CO_2}$ ),

126 mmHg; base excess, -11.9 mm; standard bicarbonate, 15.4 mm;  $K^+$ , 6.4 mm;  $Ca^{2+}$ , 0.97 mm. Administration of sodium bicarbonate, glucose, and insulin was repeated. Despite fluid therapy with colloids (1,500 ml hydroxyethyl starch, 6%; 2,000 ml gelatine, 3.5%), the patient became hypotensive. Ventricular bradyarrhythmia with heart rate less than 35 beats/min developed, which responded to intravenous increments of 1 mg epinephrine and 4 g calcium gluconate. At that time, the serum potassium concentration was 8.6 mm. Central venous and double-lumen hemofiltration catheters were inserted, and continuous infusion of epinephrine (0.3  $\mu$ g  $\cdot$  kg<sup>-1</sup>  $\cdot$  min<sup>-1</sup>) was commenced. Catheterization of the bladder revealed an intense discoloration of the urine, suggestive of massive myoglobinuria.

The patient was transferred to the intensive care unit 90 min after induction of anesthesia. He underwent mechanical ventilation; heart rate and blood pressure were 135 beats/min and 90/60 mmHg, respectively. Epinephrine was infused at a rate of 1.5  $\mu$ g  $\cdot$  kg<sup>-1</sup>  $\cdot$  min<sup>-1</sup>. CVVH was started immediately. After 8 h, acid-base and electrolyte disturbances had improved (pH, 7.31;  $K^+$ , 4.3 mm;  $Ca^{2+}$ , 1.45 mm;  $PCO_2$ , 32.8 mmHg; base excess, -9.1 mm; standard bicarbonate, 15.9 mm). He was hemodynamically stable, but acute oliguric renal failure developed. The patient was extubated 5 days after the event. He was discharged to the ward after 40 days without any neurologic sequelae but with markedly reduced muscle mass (weight loss, 20 kg) and generalized muscle weakness. Renal function was still impaired (serum creatinine concentration, 2.9 mg/dl), but no further renal replacement therapy was required.

Malignant hyperthermia susceptibility was confirmed by *in vitro* contracture tests 4 months after the reaction. Testing was performed according to the protocol of the European Group of Malignant Hyperpyrexia<sup>1</sup> at the MH reference laboratory, Department of Anesthesiology, University of Leipzig, Leipzig, Germany. *In vitro* contracture occurred at halothane and caffeine concentrations of 0.5 vol % and 0.5 mM, respectively.

Maximal plasma concentrations of myoglobin (278,000  $\mu$ g/l) and creatinine kinase (106,800 IU/l) occurred within 24 h after surgery. CVVH was used for 28 consecutive days. After an initial increase, myoglobin plasma concentrations ( $C_s$ ) decreased by 25% per day during the first 5 days of CVVH and by almost 50% daily thereafter. Myoglobin concentrations reached a steady state after 14 days but remained increased (~1,000  $\mu$ g/l), despite continuation of hemofiltration for another 14 days. Changes in myoglobin concentrations were paralleled by almost identical changes in creatinine kinase plasma concentrations (fig. 1).

We used a BM11/14 pump<sup>®</sup> (Baxter, Ettlingen, Germany) and a bicarbonate-based replacement solution containing 1.1 g/l glucose and 2.0 mmol potassium (HF-Bic35/HF-EL210<sup>®</sup>; Fresenius, Bad Homburg, Germany). The hemofilter was a 1.1 m<sup>2</sup> polyamide S-membrane polyflux 11S<sup>®</sup> (Gambro, Hechingen, Germany). Blood flow and ultrafiltrate (UF) rates were 120 ml/min and 1.8 l/h, respectively. Replacement fluid was infused after dilution at a rate that matched the hourly ultrafiltration. Myoglobin concentrations in the ultrafiltrate ( $C_{UF}$ ), measured on the second day and 24 h later, were greater than 100,000  $\mu$ g/l on both occasions. More accurate measurements would have necessitated further dilution and were not provided by the laboratory. The estimated minimal sieving coefficients ( $C_{UF}/C_s$ ) for myoglobin were 0.36 and 0.37, respectively. The minimal amount of myoglobin removed by CVVH was 4.3 g/day (removed myoglobin =  $C_{UF} \times UF \times 24$  h).

\* Staff Anesthesiologist, † Resident, ‡ Professor of Anesthesiology and Critical Care Medicine and Chairman.

Received from the Department of Anesthesiology and Intensive Care Medicine, Charité University Hospital, Humboldt University Medical School, Berlin, Germany. Submitted for publication July 11, 2000. Accepted for publication December 4, 2000. Support was provided solely from institutional and/or departmental sources.

Address reprint requests to Dr. Schenk: Universitätsklinik für Anaesthesiologie und Operative Intensivmedizin der Charité, Schumannstrasse 20-21, D-10117 Berlin, Germany. Address electronic mail to: michael.schenk@charite.de. Individual article reprints may be purchased through the Journal Web site, www.anesthesiology.org.

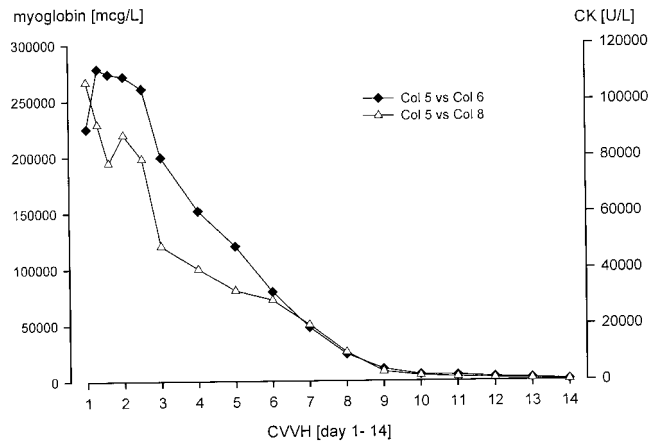


Fig. 1. Myoglobin (solid diamonds) and creatinine kinase (CK; open triangles) plasma concentrations during the first 14 consecutive days of continuous veno-venous hemofiltration (CVVH).

## Discussion

Increased muscle mass and potentially greater susceptibility of hypertrophic skeletal muscle cells may have contributed to the massive rhabdomyolysis in this patient. The use of anabolic drugs or dietary supplements is common among bodybuilders. Our patient strongly denied the intake of any of these substances but this possibility cannot be excluded definitely. The coexisting infection and the possible intake of such substances could have influenced muscle metabolism and could have further aggravated the severity of the MH reaction.

Peak myoglobin concentrations of 278,000  $\mu\text{g/l}$  were far higher than those reported in other cases of severe nontraumatic rhabdomyolysis without renal impairment. In a 26-yr-old male, peak concentrations of 55,000  $\mu\text{g/l}$  were reported.<sup>2</sup> In a 13-yr-old boy, maximal serum and urinary concentrations were 58,000 and 446,000  $\mu\text{g/l}$ , respectively. Serum myoglobin concentrations decreased rapidly to 180  $\mu\text{g/l}$  on day 5 after the MH reaction but remained increased for another week. By contrast, urinary concentrations returned to normal 2 days after the event.<sup>3</sup> This pattern suggests a two-phase elimination. Rapid renal excretion continues until a threshold is reached, followed by slow elimination, which also may involve extrarenal clearance mechanisms.<sup>4</sup>

In contrast to conventional hemodialysis,<sup>5,6</sup> hemofiltration is effective in removing larger-molecular-weight substances, such as myoglobin (17,000 Da). In an animal model (swine), 4 g equine myoglobin were administered intravenously. Within 6 h, 17 and 24% of the administered dose was removed by CVVH with ultrafiltrate rates of 1.8 and 2.9 l/h, respectively. Countercurrent dialysate flow (1 l/h) did not further improve myoglobin elimination.<sup>7</sup>

In the current patient, myoglobin was eliminated effectively by CVVH. Decreasing myoglobin release and

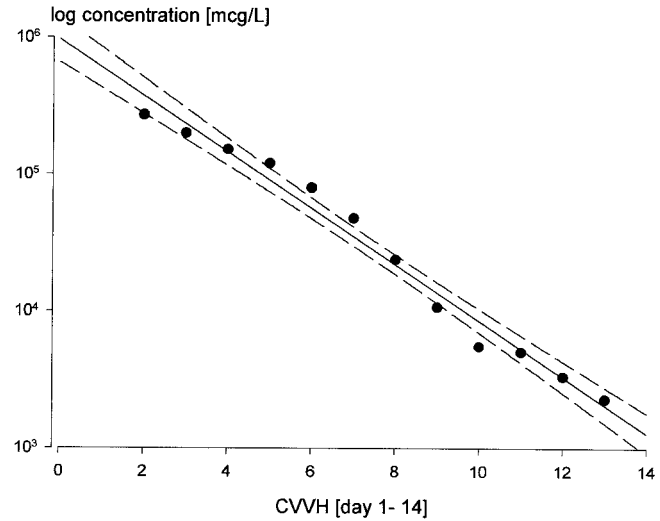


Fig. 2. Semi-logarithmic plot of myoglobin plasma concentrations versus time during the first 14 consecutive days of continuous veno-venous hemofiltration (CVVH). The solid line is the regression line; the dashed curves represent the 95% confidence interval of the regression. Regression coefficient  $r^2 = 0.90$ ,  $P < 0.001$ , analysis of variance.

extrarenal clearance mechanisms may have further contributed to the rapid decrease of myoglobin concentrations.<sup>4</sup> Initially, at least 4.3 g myoglobin were removed daily. The actual substance removal and the corresponding sieving coefficients were probably much higher because ultrafiltrate concentrations almost certainly exceeded 100,000  $\mu\text{g/l}$  by far. Bellomo *et al.*<sup>8</sup> reported myoglobin removal of 1.8 g/day in three patients with rhabdomyolysis who underwent continuous hemodiafiltration. Amyot *et al.*<sup>9</sup> showed the efficacy of CVVH in a patient with myoglobin plasma concentrations of 92,000  $\mu\text{g/l}$ ; 700 mg myoglobin was removed in 33 h, using a 0.9- $\text{m}^2$  AN69 filter (UF, 2-3 l/h). The sieving coefficients for myoglobin were 0.4-0.6.

The semi-logarithmic plot of myoglobin plasma concentrations versus time is characteristic of first-order elimination kinetics (fig. 2). A constant fraction of free myoglobin was removed daily until a steady state was reached after 14 days of hemofiltration. Thereafter, myoglobin concentrations remained almost unchanged although hemofiltration was continued, which confirms that moderately increased myoglobin plasma concentrations are not lowered effectively by hemodialysis or hemofiltration.<sup>4,10</sup> This may be attributed to the binding of myoglobin to plasma proteins and an ongoing liberation from damaged muscle cells.

The pore size of hemofilter membranes usually allows the passage of particles up to a molecular weight of 20,000 Da.<sup>10</sup> Excessive release of myoglobin may exhaust the binding capacity of plasma proteins. The free, unbound myoglobin fraction is readily cleared by filtration until most of the circulating myoglobin is protein bound and no longer freely filtrable. In the current patient, this may have occurred at concentrations of ap-

proximately 1,000  $\mu\text{g/l}$ . Similar clearance mechanisms may be present in severe rhabdomyolysis without renal failure,<sup>2,3</sup> although the threshold for myoglobin filtration may be different.

We consider hemofiltration a valuable therapeutic option in the initial management of severe cases of rhabdomyolysis. Besides the treatment of life-threatening hyperkalemia and acid-base disturbances, early institution of CVVH results in a rapid reduction of the circulating, free myoglobin. The potentially beneficial effects of early CVVH on outcome from acute myoglobinuric renal failure remain to be established.

## References

1. European Malignant Hyperpyrexia Group: A protocol for the investigation of malignant hyperpyrexia susceptibility. *Br J Anaesth* 1984; 56:1267-9

2. Fierobe L, Nivoche Y, Mantz J, Elalaoui Y, Veber B, Desmots JM: Perioperative severe rhabdomyolysis revealing susceptibility to malignant hyperthermia. *ANESTHESIOLOGY* 1998; 88:263-5

3. Laurence AS, Vanner GK, Collins W, Hopkins PM: Serum and urinary myoglobin following an aborted malignant hyperthermia reaction. *Anaesthesia* 1996; 51:958-61

4. Hällgren R, Karlsson FA, Roxin LE, Venge P: Myoglobin turnover-influence of renal and extrarenal factors. *J Lab Clin Med* 1978; 91:246-54

5. Winterberg B, Ramme K, Tenschert W, Winterberg G: Hemofiltration in myoglobinuric acute renal failure. *Int J Artif Organs* 1990; 13:113-6

6. Nicolau DP, Feng YJ, Wu AH, Bernstein SP, Nightingale CH: Evaluation of myoglobin clearance during continuous hemofiltration in a swine model of acute renal failure. *Int J Artif Organs* 1996; 19:578-81

7. Nicolau D, Feng YS, Wu AH, Bernstein SP, Nightingale CH: Myoglobin clearance during continuous veno-venous hemofiltration with or without dialysis. *Int J Artif Organs* 1998; 21:205-9

8. Bellomo R, Daskalakis R, Parkin G, Boyce N: Myoglobin clearance during acute continuous hemodiafiltration. *Intensive Care Med* 1991; 17:509

9. Amyot SL, Leblanc M, Thibeault Y, Geadah D, Cardinal J: Myoglobin clearance and removal during continuous venovenous hemofiltration. *Intensive Care Med* 1999; 25:1169-72

10. Hart PM, Feinfeld DA, Briscoe AM, Nurse HM: The effect of renal failure and hemodialysis on serum and urine myoglobin. *Clinical Nephrology* 1982; 18:141-3

Anesthesiology 2001; 94:1141-3

© 2001 American Society of Anesthesiologists, Inc. Lippincott Williams & Wilkins, Inc.

## Intraventricular Administration of Morphine and Clonidine

Michael S. Leong, M.D.,\* John F. Calabrese, M.D., Ph.D.,† Gary Heit, M.D., Ph.D.‡

CLONIDINE is used extensively now for treatment of intractable neuropathic pain conditions. In the United States, it is approved for epidural application and also has been used intrathecally for treatment of chronic cancer<sup>1</sup> and noncancer pain, often in combination with morphine.

Intraventricular analgesics are one of the last resorts of pain management. An intraventricular administration system allows the direct application of morphine to the brainstem and mid brain areas for maximal supraspinal analgesia. This system has been effective in treating head and neck cancer pain. This case report shows the use of combination therapy, specifically morphine and clonidine, to provide pain relief to patients for whom most typical pain therapies have failed.

mandible and right temporal area developed. Initially, he was treated with opioids, which provided some analgesia. However, with tumor possession and the development of radiation neuritis, his pain worsened.

His treatment now includes carbamazepine, intravenous lidocaine, oral morphine, and levorphanol. A pain cocktail was started, consisting of levorphanol, carbamazepine, and thioridazine. Adverse effects became more prominent, including sedation and cognitive changes.

Because of failure of conservative treatment, a temporary intraventricular catheter was placed on April 16, 1999. His initial rate of intraventricular morphine was 10.4  $\mu\text{g/h}$ . His pain cocktail was discontinued, and he required no breakthrough medications. The intraventricular morphine infusion was increased to 12  $\mu\text{g/h}$ , and the patient reported a pain level of 3 of 10 on a visual analog scale. The intraventricular catheter was connected to a Medtronic SynchroMed EL pump (Minneapolis, MN) on April 19, 1999, and he was discharged from the hospital on April 21, 1999.

The patient experienced rapidly increasing facial pain, which necessitated two hospital stays for monitoring and dosage adjustment. He was readmitted May 20, 1999, for a 50- $\mu\text{g}$  bolus of intraventricular morphine and an increase in rate to 40  $\mu\text{g/h}$ . The next day, a 100- $\mu\text{g}$  bolus was administered and the infusion was increased to 50  $\mu\text{g/h}$ . Finally, the patient had 0.5  $\mu\text{g/h}$  intraventricular clonidine added to his morphine infusion of 50  $\mu\text{g/h}$ , with significant improvement of analgesia. He was discharged on May 24, 1999, with the intraventricular morphine and clonidine infusions. At his follow-up neurosurgical appointment, he reported a 2 of 10 pain level by visual analog scale, as compared with his preoperative level of 9 of 10. He also had markedly reduced sedation.

Follow-up examination showed that the patient remained stable on the same dosage of intraventricular morphine and clonidine for the next 3 months until his death. The morphine elixir was the only adjuvant medication, used at 10 mg every 6 h.

## Case Reports

### Case 1

A 60-yr-old man was evaluated at the Stanford Pain Center, Stanford, California, in January 1999 for treatment of intractable facial pain. He had been diagnosed in April 1997 with squamous cell carcinoma of his right tonsil. He underwent radiation therapy, but pain radiating to his

\* Assistant Professor of Pain Management, † Resident in Anesthesiology, ‡ Assistant Professor in Neurosurgery.

Received from the Department of Anesthesiology, Pain Management Services, Stanford University School of Medicine, Stanford, California. Submitted for publication September 16, 1999. Accepted for publication January 4, 2001. Support was provided solely from institutional and/or departmental sources.

Address reprint requests to Dr. Leong: Department of Anesthesiology, H-3586, Stanford University Medical Center, Stanford, California 94305. Address electronic mail to: msleong@stanford.edu. Individual article reprints may be purchased through the Journal Web site, www.anesthesiology.org.

### Case 2

A 51-yr-old woman was diagnosed with infiltrating ductal carcinoma of the left breast with brain metastasis after modified radical mastec-

tomy, radiation, and chemotherapy in 1999. Subsequently, chronic lymphedema and pain secondary to brachial plexus compression developed from her left shoulder to her hand. Previous therapies included ketorolac, long-acting opioids, and gabapentin. A morphine infusion produced minimal improvement in analgesia.

The patient was transferred to Stanford Hospital, Stanford, California, for examination for surgical tumor debulking. She presented with a pain level of 10 of 10 on a visual analog scale and loss of left arm motor function. Passive range of motion exacerbated the patient's pain. Morphine patient-controlled analgesia was started with adjuvant therapies, including ketorolac, lorazepam, and trazodone for sleep. Gabapentin also was increased to a dose of 600 mg three times daily. Twelve hours later, the patient reported increasing left arm pain.

Mass compression of left cervicobrachial region and metastatic compromise of cervical bony structures precluded placement of a cervical epidural or intrathecal catheter. Surgical debulking was determined not to be beneficial. Multilevel dorsal root entry zone lesions were considered, but after consultation between the pain service and neurosurgery, a temporary intraventricular catheter was placed. An intraventricular morphine infusion was started at 10  $\mu\text{g}/\text{h}$ . The patient reported significant pain reduction. The intraventricular infusion was increased to 20  $\mu\text{g}/\text{h}$ , with no apparent adverse effects. An increased passive range of motion associated with reduced pain also was shown. However, increasing the morphine infusion to 30  $\mu\text{g}/\text{h}$  on the third day caused confusion and disorientation. This cognitive impairment resolved after decreasing the intraventricular morphine infusion to 20  $\mu\text{g}/\text{h}$ .

The intraventricular infusion then was reformulated to include clonidine. It was restarted with morphine at 20  $\mu\text{g}/\text{h}$  and clonidine at 0.05  $\mu\text{g}/\text{h}$ . Twelve hours after morphine-clonidine infusion, the patient reported significant pain reduction to 0 of 10 on the visual analog scale and demonstrated an increase in passive range of motion with no incident pain. The patient showed none of the previously observed disorientation in regard to place and time. She was conversant and coherent. Mild sedation resolved over the next 2 days. Her infusion was adjusted to a rate of intraventricular morphine at 20  $\mu\text{g}/\text{h}$  and clonidine at 0.1  $\mu\text{g}/\text{h}$ . The patient's improved condition was sustained, and a permanent intraventricular infusion pump was surgically placed. She was discharged to a care facility. The patient remained comfortable and continued to receive the same rates of morphine and clonidine *via* the intraventricular pump, with no additional doses of breakthrough oral opioids until her death on November 15, 2000.

## Discussion

Intraventricular medications for cancer pain have been used since the early 1980s.<sup>2-4</sup> By placing an intraventricular catheter, smaller amounts of analgesics can be placed at supraspinal sites without hepatic metabolism or interference of the blood-brain barrier. Moreover, intraventricular administration seems more effective than intrathecal administration for head and neck cancer.

Morphine has specific effects at a supraspinal level, including the periaqueductal gray, mesencephalon, dorsal raphe nucleus, and locus coeruleus.<sup>5</sup> More recent studies have shown that the concentration of morphine for intraventricular administration are approximately 10 times less than those required for intrathecal administration.<sup>6</sup> In a larger intraventricular study with 90 cancer pain patients, a typical starting dosage was 0.25 mg/24 h, increasing to 1 mg daily by 0.25 mg increments.<sup>7</sup> Initial intraventricular bolus doses are usually 0.05-0.1 mg.

The application of clonidine for intraventricular admin-

istration in humans has not been reported. Clonidine clearly has supraspinal actions at the nucleus tractus solitarius and locus coeruleus to decrease sympathetic drive. The analgesic effects of clonidine seem to be direct activation at spinal  $\alpha_2$  receptors and do not seem to be mediated by the rostroventromedial medulla.<sup>8</sup> Adverse effects, such as sedation and hypolocomotion in animal models, seem to be caused by direct action at the locus coeruleus.<sup>9</sup> Clonidine has coanalgesic effects with opiates and local anesthetics when administered intrathecally and epidurally.<sup>10,11</sup> Clinical effects, particularly hypotension and sedation, can occur with intrathecal boluses as small as 30  $\mu\text{g}$ . Common intrathecal infusion rates range from 10 to 400  $\mu\text{g}/\text{day}$ . The chronic pain patients we have studied usually have had an initial infusion range of 1-5  $\mu\text{g}/\text{h}$ .

The relative potency of clonidine in the neuraxis is controversial. A recent study suggests that intrathecal clonidine is approximately 10 times more potent than epidural clonidine for acute noxious stimulation.<sup>12</sup> Although clonidine and morphine are different pharmacologic agents, we estimated a relative potency of intraventricular clonidine to be approximately 10 times that of intrathecal clonidine because intraventricular morphine is 10 times that of intrathecal morphine. The mechanism of analgesia from intraventricular clonidine is unclear. In the first patient, direct activation of  $\alpha_2$  receptors at the trigeminal nerve may have been the site of coanalgesia. In the second patient, activation at the trigeminal nerve for analgesia seems less likely.

These case reports show the usage of multiple agents for pain management, particularly intraventricular clonidine. Combinations of intrathecal infusions for the treatment of chronic pain or cancer pain conditions are becoming much more prevalent. Clonidine seems to be an excellent coanalgesic when opioids need to be increased rapidly and repeatedly to provide analgesia for a fluctuating cancer pain condition. Furthermore, combination therapy helps to minimize adverse effects from either agent.

Clearly, the usage of an intraventricular pump infusing morphine and clonidine should be reserved for intractable and drastic cancer pain conditions. Clonidine has not been approved for intrathecal or intraventricular usage, but the preservative-free mixture should have adverse effects only related to dosing. Intraventricular administration systems can be powerful and effective tools in providing analgesia for severe pain states. Moreover, both patients' adverse effects were minimized such that they could have improved interaction with their families and more meaningful use of their remaining time.

## References

1. Eisenach J, DuPen S, Dubois M, Miguel R, Allin D: Epidural Clonidine Study Group: Epidural clonidine analgesia for intractable cancer pain. *Pain* 1995; 61:391-9

2. Leavens M, Stratton-Hill C, Cech D, Weyland J, Weston J: Intrathecal and intraventricular morphine for pain in cancer patients: Initial study. *J Neurosurg* 1982; 56:241-5
3. Lenzi A, Galli G, Gandolfini M, Marini G: Intraventricular morphine in paraneoplastic painful syndromes in the cervicofacial region: Experience in thirty-eight cases. *Neurosurgery* 1985; 17:6-11
4. Lobato R, Madrid J, Fatela L, Rivas J, Lamas E: Intraventricular morphine for control of pain in terminal cancer patients. *J Neurosurg* 1983; 59:627-33
5. Yaksh T: Pharmacology of the pain processing system, *Interventional Pain Management*. Edited by Waldman SD, Winnie AP. Philadelphia, WB Saunders, 1996, pp 19-32
6. Schultheiss R, Schramm J, Neidhardt J: Dose changes in long and medium-term intrathecal morphine therapy of cancer pain. *Neurosurgery* 1992; 31:664-70
7. Karavelis A, Foroglou G, Selviaridis P, Fountzilias G: Intraventricular admin-

istration of morphine for control of intractable cancer pain in 90 patients. *Neurosurgery* 1996; 39:57-62

8. Jonkman F, Man P, Thoolen M, Zwieten P: Location of the mechanism of the clonidine withdrawal tachycardia in rats. *J Pharm Pharmacol* 1985; 37:580-2
9. Pertovaara A, Hamalainen M, Kauppila T, Mecke E, Carlson S: Dissociation of the alpha-2 adrenergic antinociception from sedation following microinjection of medetomidine into the locus coeruleus in rats. *Pain* 1994; 57:207-15
10. Maze M, Tranquilli W: Alpha-2 adrenoceptor agonists: Defining the role in clinical anesthesia. *ANESTHESIOLOGY* 1991; 74:581-605
11. Eisenach J, Kock M, Klimscha W: Alpha-2 adrenergic agonists for regional anesthesia: A clinical review of clonidine. *ANESTHESIOLOGY* 1996; 85:655-74
12. Eisenach J, Hood D, Curry R: Relative potency of epidural to intrathecal clonidine differs between acute thermal pain and capsaicin-induced allodynia. *Pain* 2000; 84:57-64

*Anesthesiology* 2001; 94:1143-7

© 2001 American Society of Anesthesiologists, Inc. Lippincott Williams & Wilkins, Inc.

## Intraoperative Seizures in Cardiac Surgical Patients Undergoing Deep Hypothermic Circulatory Arrest Monitored with EEG

Albert T. Cheung, M.D.,\* Stuart J. Weiss, M.D., Ph.D.,\* Glenn Kent, B.S.,† Alberto Pochettino, M.D.,‡ Joseph E. Bavaria, M.D.,§ Mark M. Stecker, M.D., Ph.D.¶

SEIZURES may occur during general anesthesia in patients undergoing operations who are at risk for brain injury. Neuromuscular blockade as part of the general anesthetic eliminates the clinical manifestations of intraoperative seizures, making them impossible to diagnose without electroencephalographic monitoring. Intraoperative seizures may be followed by a prolonged postictal state manifested by confusion and altered responsiveness. Thus, it is possible that unrecognized intraoperative seizures may contribute to postoperative alterations in mental status. Although clinically evident postoperative seizures have been reported to occur in only 0.38% of patients undergoing coronary artery bypass grafting, the rate of postoperative altered mental status was much higher, approximately 2.6%.<sup>1</sup> Despite a reported case of a patient who experienced a witnessed generalized tonic-clonic seizure during cardiac surgery, the true incidence of seizures during cardiac operations has been difficult to ascertain.<sup>2</sup> The purpose of this report was to estimate the frequency and attempt to determine the causes of intraoperative seizures identified in cardiac and noncardiac surgical patients who required electroencephalographic monitoring during operation.

### Methods

From January 1995 through February 2000, the records of all patients scheduled to undergo intraopera-

tive encephalographic monitoring at the Hospital of the University of Pennsylvania, Philadelphia, Pennsylvania, were entered into a research database in a protocol approved by the University of Pennsylvania Institutional Review Board. A retrospective review of this database was performed to determine the frequency of electrographic seizures on the scalp electroencephalogram. In most cases, a 16-channel electroencephalogram was recorded with gold cup electrodes placed with the collodion technique according to the standard international 10-20 system of electrode placement. In many patients undergoing surgery for intracerebral aneurysms, the F8, F4, F7, and F3 electrode locations could not be monitored because they would have interfered with the surgical field. In some emergent cases, sterile subdermal electrodes were used, or a reduced number of recording electrodes were used to record the scalp electroencephalogram.

The criteria used to define seizure activity on the electroencephalographic recordings were based on ictal patterns on the electroencephalogram that have been established to correlate with clinical seizures in epileptic patients.<sup>3-4</sup> Electroencephalographic seizure patterns included generalized spike and wave activity, repetitive rapid spiking that changed in frequency and location over 20-300 s, or focal or generalized buildup of fast activity that evolved over time into generalized spike discharges. The diagnosis of electroencephalographic seizure was made only if one of the established electroencephalographic seizure patterns evolved continuously in frequency and amplitude over more than 20 s. This definition was used to distinguish electroencephalographic seizure activity from interictal electroencephalographic patterns, such as isolated, randomly occurring focal spikes or sharp waves that can sometimes be observed during general anesthesia. All electroencephalo-

\* Associate Professor, Department of Anesthesiology, † Research Assistant, § Associate Professor, Department of Neurology, ‡ Assistant Professor, ¶ Associate Professor, Department of Cardiothoracic Surgery.

Received from the Departments of Anesthesiology, Neurology, and Surgery, University of Pennsylvania, Philadelphia, Pennsylvania. Submitted for publication October 17, 2000. Accepted for publication January 4, 2001. Support was provided solely from institutional and/or departmental sources.

Address reprint requests to Dr. Cheung: Department of Anesthesia, Dulles 7, University of Pennsylvania, 3400 Spruce Street, Philadelphia, Pennsylvania 19104. Address electronic mail to: cheungal@mail.med.upenn.edu. Individual article reprints may be purchased through the Journal Web site, www.anesthesiology.org.

**Table 1. Distribution of Cases and Seizure Frequency**

Procedure	Number Monitored	Number of Seizures
Cervical carotid artery	527	0 (0%)
504 Endarterectomy		
8 Carotid body tumors		
9 Carotid subclavian bypasses		
3 Aortocarotid bypasses		
2 Neck dissection with carotid occlusion		
1 Balloon angioplasty		
Intracranial aneurysm	140	0 (0%)
46 Middle cerebral		
6 Basilar		
39 Anterior communicating		
36 Carotid-ophthalmic		
3 External carotid-internal carotid bypass		
1 Pericallosal artery		
13 Other		
Aortic surgery with CPB and DHCA (13% emergent operations)	168	3 (1.8%)
Cardiac surgery using CPB without DHCA	33	0 (0%)
CABG or valve repair alone		
CABG or valve repair-replace and CEA	37	0 (0%)
Pulmonary thromboembolectomy with DHCA	9	1 (11%)
Total	914	4 (0.4%)

$\chi^2 = 33.8$ ;  $df = 5$ ;  $P < 0.0001$  for  $5 \times 2$  contingency table.

CPB = cardiopulmonary bypass; DHCA = deep hypothermic circulatory arrest according to the methods described previously<sup>5-6</sup>; CABG = coronary artery bypass grafting; CEA = carotid endarterectomy.

graphic recordings were interpreted by a board-certified electroencephalographer.

All thoracic aortic operations (table 1) were performed using cardiopulmonary bypass (CPB) and deep hypothermic circulatory arrest with retrograde cerebral perfusion according to a standardized protocol used at the University of Pennsylvania.<sup>5-6</sup> In brief, deliberate hypothermia was induced by keeping the temperature gradient between the blood and heat exchanger in the CPB circuit at 10°C or lower. Arterial blood gas tensions were managed using alpha-stat. Deep hypothermic circulatory arrest was instituted after 3 min of sustained electrocerebral silence by electroencephalography. Retrograde cerebral perfusion was performed with oxygenated blood infused into the superior vena cava at a pressure of 25 mm Hg or less. Rewarming after deep hypothermic circulatory arrest was started gradually after reinstatement of antegrade cerebral perfusion on CPB by keeping the temperature gradient between the blood and heat exchanger 10°C or lower without allowing the nasopharyngeal temperature to exceed 37.5°C.

### Case Reports

Intraoperative seizures were identified in 4 of a total of 914 patients who had intraoperative electroencephalographic monitoring (table 1).

#### Case 1

The patient was a 62-yr-old man presenting for repair of a descending aortic dissection. The patient had experienced transient confusion

after the repair of a previous Stanford type A aortic dissection. He had a history of hypertension and cocaine use but no previous seizures. Versed, fentanyl, and pancuronium were used to induce general anesthesia. Anesthesia was maintained with fentanyl and isoflurane, 0.3–0.5%. The preinduction and postinduction electroencephalographic recordings showed diffuse slowing but no focal or epileptiform abnormalities. Three minutes after initiation of CPB, lidocaine, 200 mg intravenous bolus, was administered into the venous reservoir of the bypass circuit without incident. The patient was cooled to a nasopharyngeal temperature of 14.5°C, during which time the electroencephalogram showed typical changes associated with cooling (fig. 1A) before the appearance of electrocerebral silence. The patient underwent 57 min of hypothermic circulatory arrest with retrograde cerebral perfusion. After reinstatement of CPB and active rewarming, continuous electroencephalographic activity was seen 55 min later. Shortly thereafter (pH, 7.37; arterial carbon dioxide tension (Paco<sub>2</sub>), 46 mm Hg; arterial oxygen tension (PaO<sub>2</sub>), 209 mm Hg; isoflurane concentration, 0.3%; nasopharyngeal temperature, 32°C), generalized spikes were seen on the electroencephalogram, followed by generalized seizure activity on the electroencephalogram (fig. 1B). There was no response to 5 mg intravenous versed, but 150 mg intravenous thiopental terminated the seizures. Lidocaine, 200 mg, was administered later in the procedure without recurrence of seizures. No further seizures were seen, despite electroencephalographic monitoring at bedside in the surgical intensive care unit. The patient experienced transient postoperative confusion but eventually recovered. Six hours after the last dose of lidocaine, lidocaine concentration was 1.3 µg/ml.

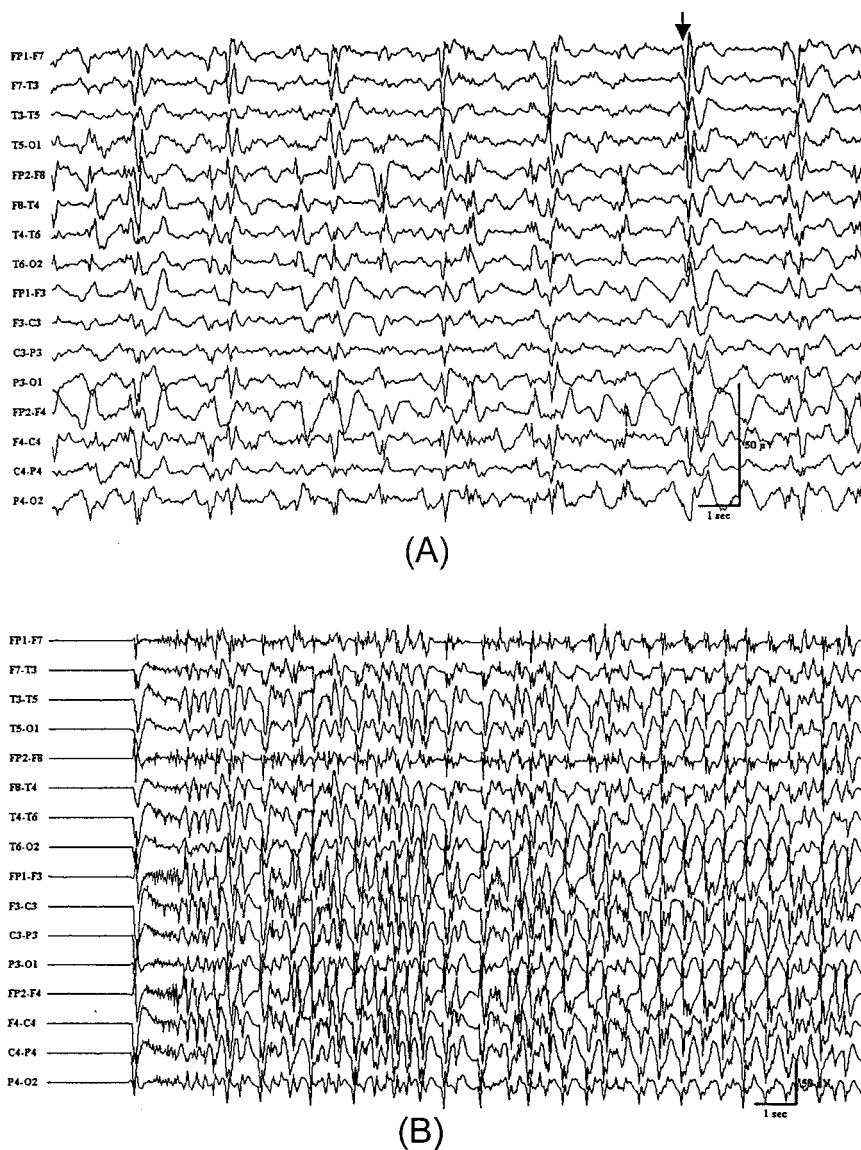
#### Case 2

The patient was a 61-yr-old man with a history of hypertension and smoking who presented for an acute Stanford type A dissection. He underwent graft reconstruction of the ascending aorta, aortic valve resuspension, and hemiarth replacement. Fentanyl, pancuronium, and versed were used to induce general anesthesia. Baseline electroencephalographic recording showed rare left temporal sharp waves. After CPB was initiated, active cooling was begun. Before ventricular fibrillation, 200 mg lidocaine, 2 g MgSO<sub>4</sub>, and 250 mg methylprednisolone were infused into the venous reservoir of the bypass circuit. Within 2 min, at a nasopharyngeal temperature of 31°C and an inhaled isoflurane concentration of 0%, left and right temporal sharp waves appeared. Generalized electrographic seizure activity, which was most prominent over the left temporal region, followed (fig. 2) and then terminated spontaneously, although right and left temporal sharp waves persisted even after the administration of 100 mg intravenous thiopental. The plasma lidocaine concentration 20 min after the bolus was 3.3 µg/ml. After hypothermic circulatory arrest, the electroencephalogram returned to normal, although left temporal sharp waves persisted. There were no postoperative seizures or neurologic deficits at follow up.

#### Case 3

The patient was a 50-yr-old man with a history of an anterior wall myocardial infarction, coronary artery disease, congestive heart failure, and pulmonary emboli. Preoperatively, the patient was confused, but neurologic examination was nonfocal. Baseline electroencephalographic recording showed diffuse slowing but no epileptiform abnormalities. The patient underwent pulmonary thromboembolectomy using hypothermic circulatory arrest with retrograde cerebral perfusion. After 6 min of initiating cooling during CPB, 200 mg intravenous lidocaine, along with 1 g intravenous methylprednisolone and 1 g intravenous MgSO<sub>4</sub>, was administered into the venous reservoir. Within 2 min, electrical seizure activity appeared bilaterally and re-

**Fig. 1. (A)** Typical electroencephalographic pattern associated with the onset of cooling. The arrow indicates a periodic complex that was commonly observed during deliberate hypothermia.<sup>5</sup> **(B)** Electroencephalogram from case 1 showing electroencephalographic seizure activity.



solved quickly after the administration of 50 mg intravenous thiopental. The seizure occurred during CPB soon after the initiation of deliberate hypothermia at a nasopharyngeal temperature of 31°C with an inhaled isoflurane concentration of 0%. No further seizures were observed. Postoperatively, the patient remained confused.

#### Case 4

The patient was a 74-yr-old woman with a large leaking distal aortic arch and a Crawford type II thoracoabdominal aortic aneurysm. Surgery was performed emergently. After induction of general anesthesia, the electroencephalogram was symmetric. CPB with active cooling was initiated. Lidocaine, 200 mg, was administered intravenously into the CPB circuit when the nasopharyngeal temperature was 34.3°C and the inhaled isoflurane concentration was 0%. This was followed by generalized electrographic seizure activity. The seizure activity was terminated with 5 mg intravenous versed. Hypothermic circulatory arrest with retrograde cerebral perfusion was instituted and lasted 40 min at a nasopharyngeal temperature of 11°C. The electroencephalogram recovered normally, and the patient had no postoperative neurologic deficits.

#### Discussion

The overall incidence of seizures during surgical procedures in a selected population of patients undergoing operations with electroencephalographic monitoring was 0.4%. All cases of intraoperative electroencephalographic seizure activity occurred in a high-risk subgroup of cardiac surgical patients undergoing thoracic aortic reconstruction with hypothermic circulatory arrest. No intraoperative seizures were observed in the noncardiac surgery patient population.

The case studies of patients with intraoperative seizures suggested two specific risk factors for intraoperative seizures. One factor was the administration of high dose lidocaine boluses into the CPB circuit. In three of the four cases, there was a temporal relation between the administration of lidocaine into the CPB circuit and the onset of seizures. Lidocaine has been a recognized cause of drug-

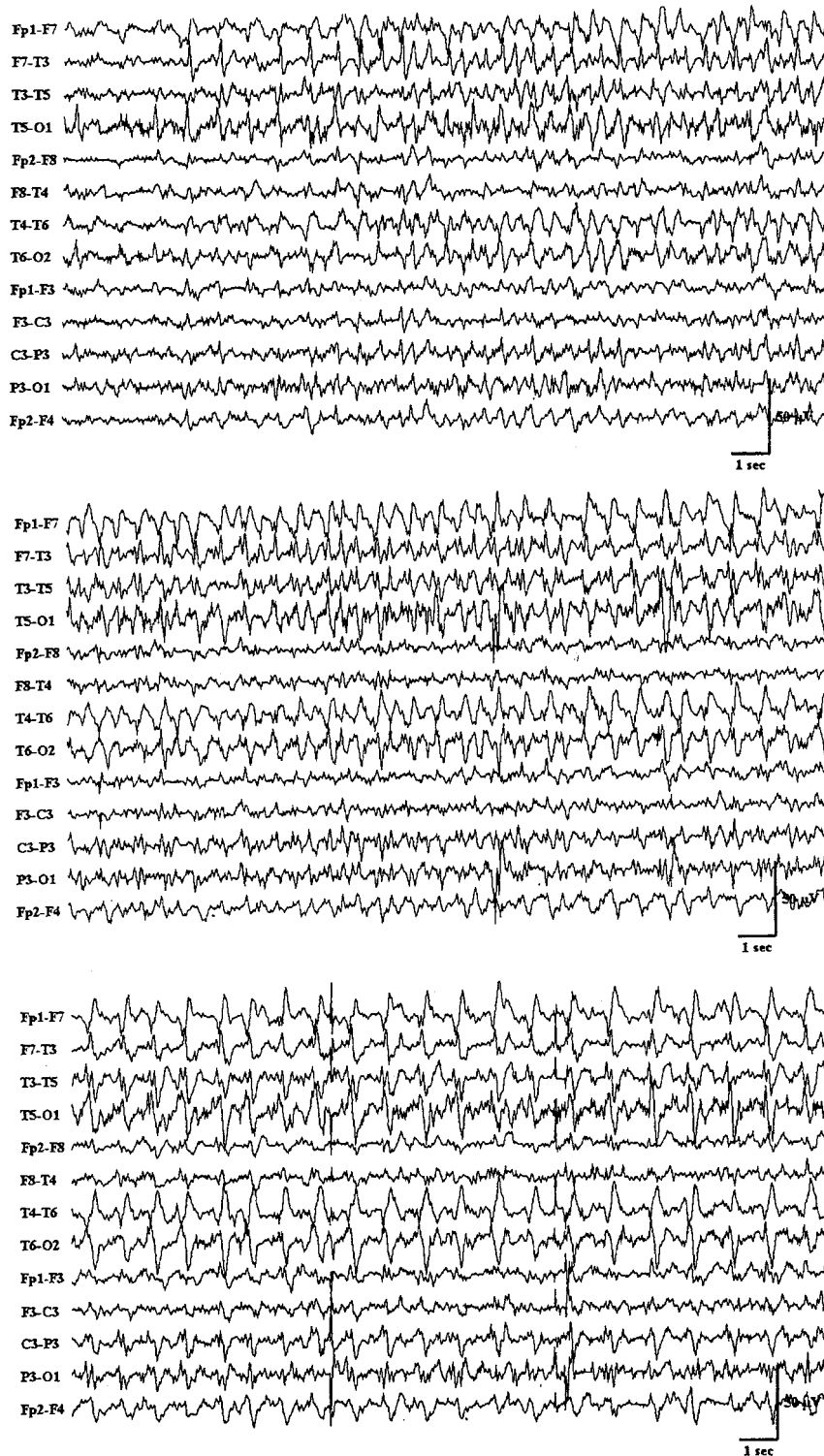


Fig. 2. Serial electroencephalographic tracings from case 2 showing the appearance of periodic complexes over the left hemisphere that evolved in frequency and location over time consistent with seizure activity.

induced seizures and was the cause of approximately 6% of all drug-induced seizures in one study.<sup>7-8</sup> In studies of regional anesthesia with local anesthetics, seizures occurred in 0.025–0.1% of patients.<sup>9-10</sup> A higher frequency of seizures in the cardiac surgical population may be explained by the rapid transient of lidocaine directly infused into the arterial system. Although the pharmacokinetics of intravenous lidocaine have not been shown to be affected

by CPB, direct bolus administration of the drug into the venous reservoir of the CPB circuit may not have allowed time for redistribution, equilibration, or metabolism, resulting in excessively high intraarterial lidocaine concentrations *via* the arterial limb of the perfusion circuit.<sup>11</sup> Direct exposure of the brain to high arterial lidocaine concentrations may have precipitated the seizures. In fact, one case report showed that as little as 40 mg infused directly



in the carotid artery caused electroencephalographic slowing and the appearance of epileptiform discharges.<sup>12</sup> However, in the awake patient, as little as 5 mg lidocaine administered into the carotid artery was sufficient to cause a convulsion.<sup>13</sup>

The second important factor predisposing patients to intraoperative seizures was preexisting neurologic injury. At least three of the patients who had intraoperative seizure activity had some evidence of neurologic injury before the seizure. The patient in case 1 had a previous aortic surgical procedure involving deep hypothermic circulatory arrest that was complicated by prolonged confusion. The patient in case 2 had left temporal sharp waves on the baseline electroencephalographic trace. The patient in case 3 had preoperative confusion. In addition to preexisting neurologic injury, the recognized risk of neurologic injury during surgery is high in thoracic aortic operations and pulmonary thromboembolotomies that require hypothermic circulatory arrest.<sup>10-11</sup> The presence of intraoperative neurologic injury was unlikely to be the only factor causing intraoperative seizures because seizures were not detected in any of the neurosurgical patients undergoing aneurysm surgery, many of whom had preexisting neurologic injury or were at high risk of having at least transient intraoperative brain injury. The anesthetic technique also may have been a factor because the inhaled anesthetic concentration was low or 0 at the time of the event in the majority of patients who had intraoperative seizures.

In conclusion, the incidence of intraoperative seizures was rare and too infrequent to implicate the postictal state as a cause for postoperative confusion. Bolus ad-

ministration of lidocaine into the CPB circuit in patients at risk for neurologic injury seemed to explain the majority of intraoperative seizures that were observed. Slow infusion of lidocaine into the CPB circuit or intravenous administration of the drug may decrease the risk of intraoperative seizures.

## References

1. Roach GW, Kanchuger M, Mangano CM, Newman M, Nussmeier N, Wolman R, Aggarwal A, Marschall K, Graham SH, Ley C: Adverse cerebral outcomes after coronary artery bypass surgery. *N Engl J Med* 1996; 335:1857-63
2. Lee DL, Ayoub C, Shaw RK, Fontes ML: Grand mal seizure during cardiopulmonary bypass: probable lidocaine toxicity. *J Cardiothorac Vasc Anesth* 1999; 13:200-2
3. Niedermeyer E: Clinical relevance of EEG signals in epilepsies, *Handbook of Encephalography and Clinical Neurophysiology of Epilepsy*, Vol 4, Revised Series. Edited by Wada JA, Ellingson RJ. New York, Elsevier, 1990, pp 237-61
4. Gastaut H, Tassarini CA: Ictal discharges in different types of seizures, *Handbook of Electroencephalography and Clinical Neurophysiology*, Vol 13. Edited by Redmond A. New York, Elsevier, 1975, pp 13a-20-13a-39
5. Stecker MM, Cheung AT, Pochettino A, Kent G, Patterson T, Weiss SJ, Bavaria JE: Deep hypothermic circulatory arrest: I. Effects of cooling on EEG and evoked potentials. *Ann Thorac Surg* 2001; 71:14-21
6. Stecker MM, Cheung AT, Pochettino A, Kent G, Patterson T, Weiss SJ, Bavaria JE: Deep hypothermic circulatory arrest: II. Changes in EEG and evoked potentials during rewarming. *Ann Thorac Surg* 2001; 71:22-8
7. Messing RO, Closson RG, Simon RP: Drug-induced seizures: A 10-year experience. *Neurology* 1984; 34:1582-6
8. Modica PA, Tempelhoff R, White PF: Pro- and anticonvulsant effects of anesthetics (part II). *Anesth Analg* 1990; 70:433-44
9. Auroy Y, Narchi P, Messiaha A, Litt L, Rouvier B, Samii K: Serious complications related to regional anesthesia: Results of a prospective study in France. *ANESTHESIOLOGY* 1997; 87:479-86
10. Brown DL, Ransom DM, Hall JA, Leicht CH, Schroeder DR, Offord KP: Regional anesthesia and local anesthetic induced systemic toxicity: Seizure frequency and accompanying cardiovascular changes. *Anesth Analg* 1995; 81:321-8
11. Schiavello R, Mezza A, Feo L, Sciarra M, Monaco C: Compartment analysis of lidocaine kinetics during extracorporeal circulation. *J Cardiothorac Vasc Anesth* 1988; 2:290-6
12. Perkins WJ, Lanier WL, Sharbrough FW: Cerebral and hemodynamic effects of lidocaine accidentally injected into the carotid arteries of patients having carotid endarterectomy. *ANESTHESIOLOGY* 1988; 69:787-90
13. Stoneham MD, Bree SEP: Epileptic seizure during awake carotid endarterectomy. *Anesth Analg* 1999; 89:885-6