

Intravenous Clonidine Use in a Neonate Experiencing Opioid-induced Myoclonus

Brenda C. McClain, M.D.,* Luke A. Probst, B.S.Pharm.,† Emese Pinter, M.D.,‡ Maximilian Hartmannsgruber, M.D.§

USE of clonidine in the management of pain and opioid taper is well-established for adults. Various treatment modalities have been described, ranging from abrupt opioid cessation with clonidine substitution¹ to gradual taper with clonidine as an adjunct.² Oral administration of clonidine in neonatal abstinence syndrome has been cited as safe and effective.³ Short-term use of intravenous clonidine for sedation in children has been recently reported in the literature.⁴ This report describes prolonged and continuous use of intravenous clonidine in the management of opioid-induced myoclonus and opioid taper in a neonate.

Case Report

The patient is a 4.0-kg, 96-day-old male infant whose opioid requirements increased over the first 64 days of life from 0.05 to 25 mg · kg⁻¹ · d⁻¹ of morphine equivalents. The infant was born at 36 weeks' gestation with a gastroschisis too large for complete closure at birth that consequently required staged repair. Mechanical ventilation *via* an endotracheal tube had been required since birth. Episodes of hypoxia, agitation, and respiratory distress necessitated the intermittent administration of neuromuscular blockade for effective ventilation. The patient's intolerance of mechanical ventilation persisted despite the addition of intravenous lorazepam at 0.1 mg/kg every 6 h. Ongoing agitation was assessed by an 11-point (0-10) Yale modification of the CRIES scale⁵ (CRIES-Mod) for differentiating agitation from air hunger. By day 54 of life, the morphine dose was 21.5 mg · kg⁻¹ · d⁻¹. The patient was switched to 20 mg methadone every 6 h, which was increased to 25 mg every 6 h on day 56 of life, but the patient remained agitated and had hourly bouts of desaturation to as low as 74%. The CRIES-Mod score was 9.

The Pediatric Pain Management Service was consulted on day 64 of life. At the time of consultation, the infant displayed bouts of clonic arm activity and facial twitching that temporally coincided with each mechanical breath. Ventilatory settings were as follows: peak inspiratory pressure = 40 cm H₂O; positive end-expiratory pressure = 5 cm H₂O; intermittent mandatory ventilation = 28; and fraction of inspired oxygen (F_{IO₂}) = 0.9. This achieved an oxygen saturation measured by pulse oximetry (Sp_{O₂}) between 81 and 94%. Seizure activity was ruled out by electroencephalography.

The Pain Management Service proposed that the agitation was not likely to be due to withdrawal or opioid tolerance but represented opioid-induced myoclonus. The use of oral clonidine to decrease the patient's opioid requirements was not an option because of persistent sanguineous drainage from the ileostomy. Informed consent for intravenous clonidine was obtained from the mother because this was our first use of Duraclon (Roxane Laboratories, Inc., Columbus, OH) as a parenteral agent. Pharmacokinetic data of intravenous clonidine in children and neonates are not available; therefore, the intravenous doses were based on the existing adult experience.⁶

A loading dose of 1 μg/kg injectable clonidine was administered to the patient, followed by a continuous infusion at 0.3 μg · kg⁻¹ · h⁻¹. The infant was noted to have less facial grimacing and decreased agitation at 8 h after initiation of the infusion, and at hour 24 of the continuous clonidine infusion, he tolerated weaning of F_{IO₂} to 0.7. Next, methadone was reduced to 15 mg every 6 h for a 24-h period and was then further reduced to 10 mg every 6 h. On day 4 of the clonidine infusion, the infant became more agitated. A 0.5-μg/kg intravenous bolus of clonidine was administered, the infusion was increased to 0.35 μg · kg⁻¹ · h⁻¹, and agitation decreased. On day 7 of the clonidine infusion, the infant's heart rate decreased from 150 beats/min to 110 beats/min without significant change in blood pressure or level of alertness (fig. 1). On day 10 of clonidine treatment, tachycardia and diaphoresis developed approximately 48 h after the last reduction in methadone. A 1.0-μg/kg intravenous bolus of clonidine was administered over 30 min, and the clonidine infusion rate was increased to 0.4 μg · kg⁻¹ · h⁻¹. The infant remained alert, his agitation subsided, heart rate and blood pressure normalized, and the diaphoretic episode resolved. Methadone taper continued every 3-5 days such that by day 89 of life, he was receiving 2.0 mg every 6 h intravenously, or 10% of the initial intravenous dose (fig. 2).

Gastrointestinal function improved, and the patient underwent extubation on day 90 of life. The sanguineous drainage from the ileostomy site resolved, enteral feeding was initiated and tolerated, and conversion to oral agents became possible. Because abrupt cessation of clonidine administration after prolonged exposure is not recommended, the clonidine infusion rate was reduced by 50% at the time of the initial oral clonidine dose of 10 μg. Oral clonidine was then scheduled for administration every 6 h. The clonidine infusion was stopped at the time of the second oral clonidine administration. Oral clonidine was gradually reduced until completion of the opioid taper.

Discussion

We have demonstrated the effective application of prolonged intravenous infusion of clonidine in the management of neonatal agitation and opioid-induced myoclonus. Clonidine, an α₂ agonist, acts at several locations, including the dorsal horn and cerebral cortex, and causes a central decrease in sympathetic outflow with subsequent dose-dependent sedation. The causes of agitation in infants with extended exposure to opioids are not clearly identified. Such presentation is often treated as evidence of withdrawal or inadequate analgesia. The physical signs of opioid abstinence syndrome and opioid-induced myoclonus with hyperalgesia are similar. Both

* Associate Professor of Anesthesiology and Pediatrics and Director of Pediatric Pain Management Services, Departments of Anesthesiology and Pediatrics, † Pharmacist, Pharmacy Department, ‡ Assistant Professor, Newborn Special Care Unit, § Assistant Professor of Anesthesiology, Department of Anesthesiology.

Received from the Departments of Anesthesiology and Pediatrics, Yale New Haven Children's Hospital, Yale University School of Medicine, New Haven, Connecticut. Submitted for publication October 9, 2000. Accepted for publication February 16, 2001. Support was provided solely from institutional and/or departmental sources.

Address reprint requests to Dr. McClain: Department of Anesthesiology, Yale School of Medicine, 333 Cedar Street, TMP-3, P.O. Box 208051, New Haven, Connecticut 06520-8051. Address electronic mail to: brenda.mcclain@yale.edu. Individual article reprints may be purchased through the Journal Web site, www.anesthesiology.org.

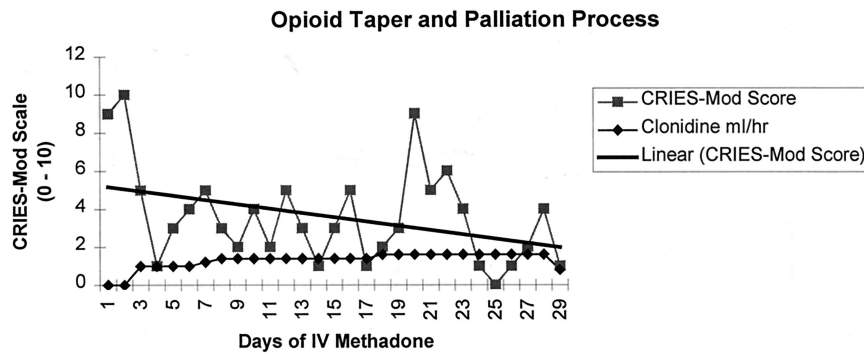


Fig. 1. The CRIES-Mod trend line displays ongoing overall decimation of agitation and pain behavior throughout the methadone taper.

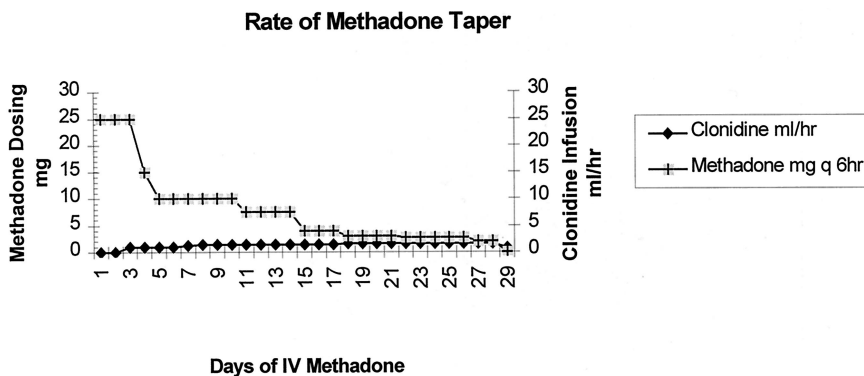


Fig. 2. A methadone taper of 25% or greater was tolerated every 3–5 days without relapse or need for cessation of the opioid taper.

syndromes present with signs of hyperexcitability. Therefore, further delineation of the etiology of myoclonus as seen in a neonatal intensive care setting is needed, especially in infants with prolonged opioid exposure. Withdrawal in the presence of increasing opioid doses can be excluded from the differential diagnosis. This should hold especially true for patients without prenatal opioid exposure.

Morphine-induced myoclonus is usually accompanied by hyperalgesia or a lowering of the pain threshold, presumably due to analgesic effects of the metabolite morphine-3-glucuronide (M3G).^{7,8} M3G leads to increased pain responsiveness to nonnoxious stimuli. Additionally, myoclonus and hyperalgesia have been described as adverse effects of pain management with chronic administration of other opioids, such as hydromorphone.⁹

The first aim in the management of myoclonus is to stop motor agitation. Next, reduction in opioid dose is performed. Suggested treatments of adverse effects seen with high opioid requirements include switching opioids, coadministration of benzodiazepines, or adding opioid-sparing agents, such as α_2 agonists (e.g., clonidine or dexmedetomidine).³

The use of oral clonidine in neonates has been established for the management of opioid withdrawal.³ Intravenous clonidine is a viable alternative when oral intake is not possible. The use of intravenous clonidine in children was first described in the management of a child with severe burns.¹⁰ Ambrose *et al.*⁴ described the use of continuous infusions of clonidine and midazolam for sedation in critically ill children for up to 9 days. Our

report corroborates these findings and demonstrates persistent cardiovascular tolerance for 26 days.

The continuous intravenous administration of clonidine allowed titration of sedation and facilitated execution of the methadone taper. In conclusion, we have demonstrated that clonidine is an effective treatment for recalcitrant agitation and myoclonus. Further study is needed to document the possible prevalence of opioid-induced hyperalgesia in neonates who experience prolonged opioid exposure.

References

1. Fishbain DA: Drug detoxification protocols, Handbook of Pain Management, 2nd edition. Edited by Tollison CD. Baltimore, Williams & Wilkins, 1994, pp 224–36
2. Spencer L, Gregory M: Clonidine transdermal patches for use in outpatient opiate withdrawal. *J Subst Abuse Treat* 1989; 6:113–7
3. American Academy of Pediatrics Committee on Drugs: Neonatal drug withdrawal (RE9746). *Pediatrics* 1998; 101:1079–88
4. Ambrose C, Sale S, Howells R, Bevan C, Jenkins I, Weir P, Wolf A: Intravenous clonidine infusion in critically ill children: Dose-dependent sedative effects and cardiovascular stability. *Br J Anaesth* 2000; 84:794–6
5. Bildner J, Krechel SW: Increasing staff nurse awareness of postoperative pain management in the NICU. *Neonatal Netw* 1996; 15:11–6
6. Bernard JM, Lagarde D, Souron R: Balanced postoperative analgesia: Effect of intravenous clonidine on blood gases and pharmacokinetics of intravenous fentanyl. *Anesth Analg* 1994; 79:1126–32
7. Ferris David J: Controlling myoclonus after high-dosage morphine infusions. *Am J Health Syst Pharm* 1999; 56:1009–10
8. Faura CC, Olaso MJ, Cabanes CG, Horga JF: Lack of morphine-6-glucuronide antinociception after morphine treatment Is morphine-3-glucuronide involved? *Pain* 1996; 65:25–30
9. Sylvester R, Levitt R, Steen P: Opioid-induced muscle activity: implications for managing chronic pain. *Ann Pharmacother* 1995; 29:1118–21
10. Lyons B, Casey W, Doherty P, McHugh M, Moore KP: Pain relief with low-dose intravenous clonidine in a child with severe burns. *Intensive Care Med* 1996; 22:249–51

Fatal Hepatitis Associated with Isoflurane Exposure and CYP2A6 Autoantibodies

Jackie L. Martin, M.D.,* Mark T. Keegan, M.B., M.R.C.P.I.,† Gurinder M. S. Vasdev, M.B., B.S., F.R.C.A.,‡
Scott L. Nyberg, M.D., Ph.D.,§ Mohammed Bourdi, Ph.D.,|| Lance R. Pohl, Pharm.D., Ph.D.,# David J. Plevak, M.D.**

SINCE the introduction of halothane into clinical practice, fluorinated volatile anesthetics have been associated with liver injury. Although the mechanism of the liver injury caused by fluorinated volatile anesthetics has not been established, evidence suggests it may be due to the oxidative metabolism of these drugs by hepatic cytochrome P450s (CYP) to form immunogenic acylated hepatic protein conjugates.¹ In susceptible patients, these modified proteins are believed to induce the formation of pathogenic antibodies and T cells directed against antigenic determinants of these proteins in either their native (autoantigens) or acyl-modified states (neoantigens). We report a case of fulminant hepatic failure and death in association with isoflurane anesthesia 22 yr after previous exposure to enflurane. High concentrations of CYP2A6 autoantibodies were detected in the serum of the patient.

Case Report

A 55-yr-old obese woman was admitted to the hospital after experiencing right upper quadrant pain. The patient's general health had been good, and there was no history of liver or gastrointestinal problems. She had never received a blood transfusion, she denied intravenous drug use, and she had no history of alcohol use and no recent history of travel or exposure to hepatotoxins. Her only medications were estrogen and progesterone supplements. She had no known allergies. Twenty-two years previously, she had a tubal ligation during general anesthesia with enflurane, which was complicated by persistent postoperative nausea and vomiting.

Abdominal ultrasonography showed cholelithiasis. Endoscopic retrograde cholecystopancreatography was consistent with recent pas-

sage of a stone through the ampulla of Vater. Serum biochemical analysis revealed the following: lipase, 1,271 (reference, 56-239) U/l; amylase 252 (35-115) U/l; total bilirubin, 0.7 (0.1-1.1) mg/dl; direct bilirubin, 0.2 (0-0.3) mg/dl; alkaline phosphatase, 206 (90-234) U/l; increased aspartate transaminase, 84 (12-31) U/l; and alanine aminotransferase concentration, 74 (9-29) U/l. The patient's international normalized ratio was 1.0. A diagnosis of acute biliary pancreatitis was made, and the patient underwent laparoscopic cholecystectomy during general anesthesia. The anesthetic regimen included intubation with sodium thiopental and succinylcholine followed by isoflurane in air-oxygen, fentanyl citrate, cisatracurium, and ondansetron. Anesthesia continued without incident. Specifically, there were no episodes of perioperative hypoxemia or hypotension. At surgery, the biliary anatomy was normal, and evidence of moderate inflammation of the gallbladder was noted. The patient's immediate postoperative course was remarkable only for abdominal pain and nausea. Liver function tests on the day after surgery showed a total bilirubin concentration of 0.8 mg/dl and an aspartate transaminase concentration of 108 U/l. Discharge from the hospital was delayed by 1 day because of nausea, but the patient went home 3 days after surgery.

One day after discharge, the patient returned to the hospital, reporting nausea, vomiting, abdominal and back pain, tachypnea, and diaphoresis. Laboratory examination revealed the following: total bilirubin, 14.3 mg/dl; direct bilirubin, 8.0 mg/dl; aspartate transaminase, 14,493 U/l; alanine aminotransferase, 6,564 U/l; alkaline phosphatase, 691 U/l; and international normalized ratio, 5.6. Her blood pH was 7.09, with a base deficit of -22 mEq/l. Her lactate concentration was 18.6 (reference, 0.93-1.65) mm, and amylase and lipase concentrations were only mildly increased at 750 and 612 U/l, respectively. The abdominal computed tomography scan and abdominal radiograph were normal. Hepatic ultrasonography revealed normal hepatic vasculature. A diagnosis of fulminant hepatic failure was made, and the patient was admitted to the intensive care unit where, shortly thereafter, stage three hepatic encephalopathy developed. Her trachea was intubated, mechanical ventilation was initiated, and an intracranial pressure monitor was placed. The option of liver transplantation was discussed with the family and was declined.

Investigations for a cause of the fulminant hepatic failure included the following: normal or negative serum ceruloplasmin; anti-smooth muscle, antimitochondrial, and antinuclear antibodies; α 1 antitrypsin, anti-hepatitis A virus immunoglobulin (Ig) M, anti-hepatitis C virus, human immunodeficiency virus, and human T-cell lymphotropic virus screening; and cytomegalovirus IgM. Her anti-Epstein-Barr nuclear antigen was positive, but her anti-viral capsid antigen-IgM was negative. The IgG and IgM varicella zoster titers were low. Her anti-hepatitis B surface antigen was positive, but the rest of her B serology was negative. Her acetaminophen concentration was 18 (reference, < 50) μ g/ml. The patient had taken Extra Strength Tylenol tablets (McNeil Consumer Products Co., Ft. Washington, PA) on the day of discharge from the hospital and on the morning of readmission. Her family did not believe that she exceeded the recommended dosage, and the acetaminophen concentration was determined from a sample taken less than 12 h after the last dose. Serum iron concentration was increased at 203 (35-145) μ g/dl, and she had a low total iron binding capacity of 208 (250-400) μ g/dl. Continuous hemofiltration for renal failure was started. Ten days after cholecystectomy, the patient's family

* Associate Professor, Department of Anesthesiology and Critical Care Medicine, Johns Hopkins Medical Institutions, and Adjunct Investigator, Molecular and Cellular Toxicology Section of the Laboratory of Molecular Immunology, National Heart, Lung, and Blood Institute, National Institutes of Health. † Assistant Professor, Department of Anesthesiology, Division of Critical Care, ‡ Associate Professor, ** Professor, Department of Anesthesiology, § Associate Professor, Department of Surgery, Mayo Clinic. || Research Fellow, # Section Chief, Molecular and Cellular Toxicology, Section of the Laboratory of Molecular Immunology, National Heart, Lung, and Blood Institute, National Institutes of Health.

Received from the Department of Anesthesiology and Critical Care Medicine, Johns Hopkins Medical Institutions Baltimore, Maryland; the Departments of Anesthesiology and Surgery, Mayo Clinic, Rochester, Minnesota; and the Laboratory of Molecular Immunology, National Heart, Lung, and Blood Institute, National Institutes of Health, Bethesda, Maryland. Submitted for publication August 30, 2000. Accepted for publication February 20, 2001. Support was provided solely from institutional and/or departmental sources. Parts of this work were presented as a poster at the Midwest Anesthesia Residents' Conference, Columbus, Ohio, April 17, 1999.

Address reprint requests to Dr. Plevak: Department of Anesthesiology, Mayo Clinic, 200 First Street SW, Rochester, Minnesota 55905. Address electronic mail to: plevak.david@mayo.edu. Individual article reprints may be purchased through the Journal Web site, www.anesthesiology.org.

Table 1. ELISA Determination of Serum Antibodies

	Microsomes		CYP	
	Control	Halothane	2E1	2A6
Patient	1.887*	1.940*	0.160	2.289*
Controls	0.500	0.537	0.151	0.313

Enzyme-linked immunosorbent assay (ELISA) screening of patient and control sera for antibodies that react with rat liver microsomal protein from halothane-exposed and control rats (100 μ g), purified native human CYP2E1 (1 μ g), and purified native human CYP2A6 (1 μ g). Sera were diluted 1/100. A reaction was considered positive when the absorbance at 405 nm was greater than 2 SDs above the mean value obtained from the sera of 10 control patients.

* Significantly different from control, $P < 0.01$, t test.

CYP = cytochrome P-450.

requested discontinuation of all support, and the patient died. Permission for an autopsy was denied by the family, and neither an *ante* nor a *post mortem* liver biopsy was performed.

Serum was collected on hospital day 8 and tested for reactions of serum antibodies to liver microsomes from halothane-exposed and control rats, purified human CYP2E1,² and human CYP2A6³ by previously described enzyme-linked immunosorbent assays.^{2,4} Control patients were normal subjects ($n = 10$) without a history of anesthetic exposure. The enzyme-linked immunosorbent assays revealed that the patient had higher concentrations of serum antibodies that reacted with both trifluoroacetic acid (TFA)-labeled and unmodified rat liver microsomal proteins and CYP2A6 than those of control patients (table 1). In contrast, very little immune reactivity was seen against CYP2E1.

Discussion

Soon after the introduction of halothane, several cases of hepatotoxicity were linked to this agent.⁵ The hepatic injury may be of two types; a relatively common, mild dysfunction or a rare, severe centrilobular necrosis, which can lead to fulminant hepatic failure. Oxidative metabolism of halothane in the liver, particularly by CYP2E1, produces trifluoroacetyl chloride. This reactive metabolite binds covalently with liver microsomal proteins to form several TFA-labeled neoantigens.^{2,6} It is believed that these neoantigens may be immunogenic in susceptible patients and induce the formation of specific pathogenic antibodies and T cells directed against native or acyl-modified epitopes of these proteins.^{2,7-9} Other volatile fluorinated agents are also metabolized to form acylated protein adducts, but at much slower rates than halothane (halothane $\gg\gg$ enflurane $>$ isoflurane $>$ desflurane).¹ The incidence of hepatic injury caused by these drugs follows the same trend.¹⁰⁻¹⁵

In a previous study, 67% of a group of 24 halothane hepatitis patients had specific serum reactivity against trifluoroacetylated liver microsomal proteins from halothane-treated rats.⁴ That number increased to 79% when specific TFA-labeled proteins purified from rat liver microsomes were used as test antigen in the enzyme-linked immunosorbent assay. Importantly, a significant number of halothane hepatitis patients did not react with the trifluoroacetylated protein neoantigens. This observation led us to discover that in many cases, halothane hepatitis was associated with serum antibodies directed against native as opposed to

trifluoroacetylated proteins. These proteins include protein disulfide isomerase,¹⁶ P 58,¹⁷ ERp72,¹⁸ and CYP2E1.²

The P450 isoenzymes are a superfamily of hemoproteins that catalyze the metabolism of a large number of endogenous and exogenous compounds.¹⁹ Autoantibodies against specific human CYPs have been found in the sera of patients with a variety of diseases, including those caused by drugs. In the cases of hepatitis caused by tienilic acid and dihydralazine, patients had serum antibodies directed against CYP2C9 and 1A2, respectively.^{20,21} In a subset of patients with idiopathic autoimmune chronic active hepatitis, antibodies to CYP2D6 were identified.²² Antibodies against CYP1A2 and 2A6 have been found in the sera of patients with autoimmune polyglandular syndrome type I.²³ Autoantibodies to CYP2E1 have been previously reported in 45-70% of halothane hepatitis patients' sera and are thought to be induced by the formation of immunogenic TFA-CYP2E1 adducts.^{2,24} Cytochrome 2A6 can also oxidatively metabolize halothane²⁵ to form trifluoroacetylated protein adducts, including TFA-CYP2A6.²⁶ In susceptible patients, it is possible that TFA-CYP2A6 may bypass the immunologic tolerance that normally exists against CYP2A6 and may induce the formation of CYP2A6 autoantibodies.²

Immunologic cross-sensitization has been associated with the use of fluorinated volatile anesthetics.²⁷ Therefore, exposure to one fluorinated volatile anesthetic may sensitize a patient to subsequent exposure by another fluorinated volatile anesthetic and lead to a severe immunologic reaction. Examples of possible cross-sensitization reactions between halothane and enflurane,²⁸ isoflurane,²⁹ or desflurane¹⁵ have been previously reported.

This patient's clinical presentation in many ways was typical of that of patients who have postoperative hepatic injury after exposure to fluorinated inhaled anesthetics. She was a middle-aged, obese woman who presented within a few days of surgery with nausea, vomiting, jaundice, and an unexplained hepatic injury after isoflurane anesthesia. Rash and eosinophilia were not seen. In addition, the search for alternative causes of fulminant hepatic failure ruled out other major precipitating causes. Although hepatitis is known to occur in biliary surgery and pancreatitis, based on this patient's history, laboratory data, and clinical presentation, we believe instead that she may have been sensitized to enflurane 22 yr previously and that the subsequent isoflurane anesthesia resulted in a cross-sensitization immunologic reaction leading to hepatic failure and death. In a previous report, a patient died after a period of 28 yr between halothane exposures.³⁰ These findings suggest that there may be no safe interval between exposures to fluorinated volatile anesthetics in sensitized patients. Although CYP2A6 antibodies have been identified in association with other immune syndromes, we believe this is the first report of autoantibodies to CYP2A6 in association with drug-induced hepatic injury. The diagnostic

and prognostic significance of the CYP2A6 autoantibodies remains to be determined.

The authors thank Allan Rettie, Ph.D., William F. Trager, Ph.D., and Sidney D. Nelson, Ph.D., of the Department of Medicinal Chemistry, School of Pharmacy, University of Washington, Seattle, Washington, for providing the human purified CYP2E1 and CYP2A6.

References

- Njoku D, Laster MJ, Gong DH, Eger EI, Reed GF, Martin JL: Biotransformation of halothane, enflurane, isoflurane, and desflurane to trifluoroacetylated liver proteins: Association between protein acylation and hepatic injury. *Anesth Analg* 1997; 84:173-8
- Bourdi M, Chen W, Peter RM, Martin JL, Buters JTM, Nelson SD, Pohl LR: Human cytochrome P450 2E1 is a major autoantigen associated with halothane hepatitis. *Chem Res Toxicol* 1996; 9:1159-66
- Chen W, Koenigs LL, Thompson SJ, Peter RM, Rettie AE, Trager WF, Nelson SD: Oxidation of acetaminophen to its toxic quinone imine and nontoxic catechol metabolites by baculovirus-expressed and purified human cytochromes P450 2E1 and 2A6. *Chem Res Toxicol* 1998; 11:295-301
- Martin JL, Kenna JG, Pohl LR: Antibody assays for the detection of patients sensitized to halothane. *Anesth Analg* 1990; 70:154-9
- National Halothane Study: Summary of the National Halothane Study: Possible associations between halothane anesthesia and postoperative hepatic necrosis. *JAMA* 1966; 197:157-8
- Amouzadeh HR, Bourdi M, Martin JL, Martin BM, Pohl LR: UDP-Glucose: Glycoprotein glucosyltransferase associates with endoplasmic reticulum chaperones and its activity is decreased *in vivo* by the inhalation anesthetic halothane. *Chem Res Toxicol* 1997; 10:59-63
- Kenna JG, Satoh H, Christ DD, Pohl LR: Metabolic basis for a drug hypersensitivity: Antibodies in sera from patients with halothane hepatitis recognize liver neoantigens that contain the trifluoroacetyl group derived from halothane. *J Pharmacol Exp Ther* 1988; 245:1103-9
- Pohl LR, Pumford NR, Martin JL: Mechanisms, chemical structures and drug metabolism. *Eur J Haematol* 1996; 60S:98-104
- Kenna JG, Jones RM: The organ toxicity of inhaled anesthetics. *Anesth Analg* 1995; 81(suppl 6):S51-66
- Lewis JH, Zimmerman HJ, Ishak KG, Mullick FG: Enflurane hepatotoxicity: A clinicopathologic study of 24 cases. *Ann Intern Med* 1983; 98:984-92
- Paull JD, Fortune DW: Hepatotoxicity and death following two enflurane anesthetics. *Anaesthesia* 1987; 42:1191-6
- Carrigan TW, Straughen WJ: A report of hepatic necrosis and death following isoflurane anesthesia. *ANESTHESIOLOGY* 1987; 67:581-3
- Brunt EM, White H, Marsh JW, Holtmann B, Peters MG: Fulminant hepatic failure after repeated exposure to isoflurane anesthesia: A case report. *Hepatology* 1991; 13:1017-21
- Sinha A, Clatch RJ, Stuck G, Blumenthal SA, Patel SA: Isoflurane hepatotoxicity: A case report and review of the literature. *Am J Gastroenterol* 1996; 91:2406-9
- Martin JL, Plevak DJ, Flannery KD, Charlton M, Poterucha JJ, Humphreys CE, Derfus G, Pohl LR: Hepatotoxicity after desflurane anesthesia. *ANESTHESIOLOGY* 1995; 83:1125-9
- Martin JL, Kenna JG, Martin BM, Thomassen D, Reed GF, Pohl LR: Halothane hepatitis patients have serum antibodies that react with protein disulfide isomerase. *Hepatology* 1990; 18:858-63
- Martin JL, Reed GF, Pohl LR: Association of anti-58 kDa endoplasmic reticulum antibodies with halothane hepatitis. *Biochem Pharmacol* 1993; 46:1247-50
- Pumford NR, Martin BM, Thomassen D, Burris JA, Kenna JG, Martin JL, Pohl LR: Serum antibodies from halothane hepatitis patients react with rat endoplasmic reticulum protein ERp72. *Chem Res Toxicol* 1993; 6:609-15
- Wrighton SA, Stevens JC: The human hepatic cytochromes P450 involved in drug metabolism. *Crit Rev Toxicol* 1992; 22:1-21
- Beaune P, Dansette PM, Mansuy D, Kiffel L, Finck M, Amar C, Leroux JP, Homberg JC: Human anti-endoplasmic reticulum autoantibodies appearing in a drug-induced hepatitis are directed against a human liver cytochrome P450 that hydroxylates the drug. *Proc Natl Acad Sci U S A* 1987; 84:551-5
- Bourdi M, Larrey D, Nataf J, Bernuau J, Pessayre D, Iwaski M, Guengerich FP, Beaune PH: Anti-liver endoplasmic reticulum autoantibodies are directed against a human cytochrome P450 1A2: A specific marker of dihydralazine-induced hepatitis. *J Clin Invest* 1990; 85:1967-73
- Zanger UM, Hauri HP, Loeper J, Homberg JC, Meyer UA: Antibodies against human cytochrome P450 db1 in autoimmune hepatitis type II. *Proc Natl Acad Sci U S A* 1988; 85:8256-60
- Clemente MG, Meloni A, Obermayer-Straub P, Frau F, Manns MP, De Virgillis S: Two cytochromes P 450 are major hepatocellular autoantigens in autoimmune polyglandular syndrome type 1. *Gastroenterology* 1998; 114:324-8
- Eliasson E, Kenna JG: Cytochrome P450 2E1 is a cell surface autoantigen in halothane hepatitis. *Mol Pharmacol* 1996; 50:573-82
- Spracklin DK, Hankins DC, Fisher JM, Thummel KE, Kharasch ED: Cytochrome P4502E1 is the principal catalyst of human oxidative halothane metabolism *in vitro*. *J Pharmacol Exp Ther* 1997; 281:400-11
- Bourdi M, Amouzadeh HR, Rushmore TH, Martin JL, Pohl LR: Halothane-induced liver injury in outbred guinea pigs: Role of trifluoroacetylated protein adducts in animal susceptibility. *Chem Res Toxicol* 2000; 14:362-70
- Christ DD, Kenna JG, Kammerer W, Satoh H, Pohl LR: Enflurane metabolism produces covalently bound liver adducts recognized by antibodies from patients with halothane hepatitis. *ANESTHESIOLOGY* 1988; 69:833-8
- Sigurdsson J, Hreidrasson AB, Thjodleifsson B: Enflurane hepatitis: A report of a case with a previous history of halothane hepatitis. *Acta Anaesthesiol Scand* 1985; 29:495-6
- Gunaratnam NT, Benson J, Gandolfi AJ, Chen M: Suspected isoflurane hepatitis in an obese patient with a history of halothane hepatitis. *ANESTHESIOLOGY* 1995; 83:1361-4
- Martin JL, Dubbink DA, Plevak DJ, Perrone A, Taswell HF, Hay EJ, Pumford NR, Pohl LR: Halothane hepatitis 28 years after primary exposure. *Anesth Analg* 1992; 74:605-8

Anesthesiology 2001; 95:553-5

© 2001 American Society of Anesthesiologists, Inc. Lippincott Williams & Wilkins, Inc.

Mask Induction with Sevoflurane in a Parturient with Severe Tracheal Stenosis

Emily F. Ratner, M.D.,* Sheila E. Cohen, M.B., Ch.B., F.R.C.A.,† Yasser El Sayed, M.D.,‡ Maurice Druzin, M.D.§

MASK induction of general anesthesia is not routinely performed in obstetric patients because of the risk of

pulmonary aspiration.¹ We report a case of a pregnant patient with severe tracheal stenosis who underwent laryngoscopy, bronchoscopy, and tracheal biopsy after mask induction with sevoflurane.

* Assistant Professor, † Professor of Anesthesia and Gynecology and Obstetrics, and Director of Obstetric Anesthesia, Department of Anesthesiology, ‡ Assistant Professor, § Charles B. and Ann L. Johnson Professor of Gynecology and Obstetrics, and Chief, Division of Maternal Fetal Medicine, Department of Gynecology and Obstetrics.

Received from the Departments of Anesthesiology and Gynecology and Obstetrics, Stanford University School of Medicine, Stanford, California. Submitted for publication December 19, 2000. Accepted for publication March 9, 2001. Nonclinical time of Drs. Ratner and Cohen was supported by the Department of Anesthesiology, Stanford University School of Medicine, Stanford, California.

Address reprint requests to Dr. Ratner: Department of Anesthesiology, Room H3580, Stanford University School of Medicine, 300 Pasteur Drive, Stanford, California 94305-5640. Address electronic mail to: eratner@leland.stanford.edu. Individual article reprints may be purchased through the Journal Web site, www.anesthesiology.org.

Case Report

A 33-yr-old gravida 2 para 0 woman at 32 weeks of gestation was scheduled for laryngoscopy, bronchoscopy, biopsy, and possible laser ablation of a tracheal obstruction. Her medical history included a respiratory arrest during the first trimester of her previous pregnancy, followed by a prolonged intensive care unit stay, residual right vocal cord damage, and pregnancy loss. In her second pregnancy, she noted increasing shortness of breath and dyspnea on exertion since her second month of gestation.

The patient was admitted to the hospital at 28 weeks of gestation for worsening dyspnea. She reported dyspnea while lying supine, which was relieved when she sat up 30°. She underwent bronchoscopy during local anesthesia with sedation; a subglottic tracheal obstruction was visualized, and a 4- to 6-mm airway opening was identified 4 cm below the vocal cords. Her respiratory symptoms improved markedly after antibiotic and bronchodilator therapy, and her pulmonologist, otolaryngologic surgeon, and obstetrician all agreed to delay biopsy, bronchoscopy, and possible ablation of the tracheal lesion until later in the third trimester to allow for further fetal maturation. The decision was made to observe the patient in the hospital setting in case worsening respiratory compromise should occur. Twenty milligrams intravenous methylprednisolone was administered to the patient twice daily to decrease airway swelling and promote fetal lung maturity.

Before elective surgery at 32 weeks of gestation, the patient was informed of the risk of intraoperative fetal distress and that emergency cesarean delivery might be necessary. She fasted for 8 h preoperatively and was premedicated with 10 mg intravenous metoclopramide, 50 mg ranitidine, and 0.2 mg glycopyrrolate. Intravenous midazolam was also administered in 0.25-mg increments up to 1.5 mg. In addition to standard monitors, an external fetal heart rate monitor and a 20-gauge radial intraarterial catheter were placed. Otolaryngologic surgeons, an obstetric team, and a neonatal team were ready in the operating room in case fetal distress occurred and the need for emergent cesarean delivery occurred. The patient breathed 100% oxygen *via* face mask for 7 min. The reservoir bag was then rapidly filled with 8% sevoflurane in 10 l/min oxygen. The patient was asked to take deep breaths, which resulted in her losing consciousness in approximately 40 s. A patent airway was maintained with the patient breathing spontaneously in the supine position with left uterine displacement. Mask ventilation was easy, and 100 mg intravenous succinylcholine was administered to the patient. After paralysis, mask ventilation continued without difficulty. Muscle relaxation was maintained with 40 mg intravenous rocuronium to ensure optimal operating conditions. Anesthesia was maintained with 2% sevoflurane in 100% oxygen and small doses of intravenous fentanyl. Laryngoscopy and bronchoscopy initially proceeded without difficulty, and manual ventilation was maintained through the adult bronchoscope. The initial blood gas showed a pH of 7.32, a partial pressure of carbon dioxide (P_{CO_2}) of 40 mmHg, and a partial pressure of oxygen (P_{O_2}) of 312 mmHg. However, because the degree of subglottic stenosis was so severe, a pediatric bronchoscope was necessary to proceed with surgery. High inspiratory pressures (up to 70 cm H_2O) were necessary to maintain adequate oxygenation. Oxygen saturation never decreased below 94%, and arterial blood gas measurements during this period were as follows: pH, 7.22; PCO_2 , 53 mmHg; and PO_2 , 155 mmHg. On inspection, a very fine tracheal web was visualized. When the web was biopsied with forceps, the airway diameter enlarged to 1.2 cm. Ventilation improved markedly after this, and the otolaryngologic surgeons decided that no further resection of the web was indicated. Ten milligrams intravenous dexamethasone was administered to the patient to minimize airway swelling, and muscle relaxation was reversed. Spontaneous respiration resumed, and the patient awakened before transfer to the postanesthesia care unit. No fetal heart rate deceleration or distress was noted intraoperatively. Although Wegener granulomatosis was suspected, laboratory and pathologic specimens did not confirm this diagnosis. The patient had an uneventful postoperative course and underwent elective cesarean delivery at 37 weeks of gestation for fetal breech presentation during spinal anesthesia without incident. She required no additional therapy for her tracheal stenosis because she was asymptomatic.

Discussion

Despite apparent contraindications to the use of mask inhalation anesthesia in pregnant patients, mask induc-

tion facilitated successful management of this patient. Four cases of tracheal stenosis in pregnant patients have been reported. Pare *et al.*² described a patient with tracheal stenosis in whom severe respiratory compromise developed. Salama *et al.*³ described tracheal balloon dilatation in a patient with a tracheal web, and Mallett *et al.*⁴ used a helium-oxygen gas mixture to facilitate respiratory function during labor and vaginal delivery in a patient with subglottic stenosis. In the fourth case report, Sutcliffe *et al.*⁵ described a patient with severe tracheal stenosis who underwent cesarean delivery during regional anesthesia but died a month later.

Because the current patient was able to maintain an adequate airway while awake, mask induction was chosen. If respiratory compromise had occurred, alterations in her position might have improved respiratory status. If complete airway obstruction had occurred, we would have discontinued administration of volatile anesthetic to allow the patient to regain consciousness and, hopefully, a patent airway. Gambling *et al.*⁶ reported about the safety of sevoflurane in parturients undergoing elective cesarean delivery. Another report described mask induction with sevoflurane for emergency cesarean delivery.⁷ This report sparked controversy because general anesthesia was induced without intravenous access,⁸ an issue not relevant to the current case. Mask induction with sevoflurane has been reported in pregnant patients with other conditions.^{9,10} Ours is the first report of a pregnant patient undergoing mask general anesthesia induction with sevoflurane for severe tracheal obstruction.

The risk of aspiration was of some concern in the current patient because of her pregnancy. Because the surgery was elective, she fasted for 8 h preoperatively, and ranitidine and metoclopramide were administered, this risk was reduced.

When to perform surgery primarily depended on maternal condition. Because the patient's respiratory status markedly improved after her respiratory infection resolved, her physicians believed that delaying surgery was appropriate. Had her respiratory status deteriorated, she would have undergone surgery immediately. Fetal maturity was a secondary consideration. Because the patient was stable and fetal outcome is significantly better at 32 weeks than at 28 weeks, 32 weeks of gestation was chosen as the optimal time to perform surgery. This decision was made to minimize maternal risk and optimize neonatal outcome. Alternatively, she could have undergone surgery later in the third trimester, but the increased maternal risk was believed to be unwarranted after 32 weeks of gestation.

In summary, this is the first report of a pregnant patient undergoing mask general anesthesia induction with sevoflurane for tracheal stenosis. This technique should

be considered in parturients with airway obstruction or when a difficult airway is encountered.

References

- Hawkins JL, Koonin LM, Palmer SK, Gibbs CP: Anesthesia-related deaths during obstetric delivery in the United States, 1979-1990. *ANESTHESIOLOGY* 1997; 86:277-84
- Pare PD, Donevan RE, Nelems JM: Clues to unrecognized upper airway obstruction. *Can Med Assoc J* 1982; 127:39-41
- Salama DJ, Body SC: Management of a term parturient with tracheal stenosis. *Br J Anaesth* 1994; 72:354-7
- Mallett VT, Bhatia RK, Kissner DG, Sokol R: Use of a HeO₂ mixture in the management of upper airway obstruction during labor and delivery. *J Reprod Med* 1989; 34:429-30
- Sutcliffe N, Remington SAM, Ramsay TM, Mason C: Severe tracheal stenosis and operative delivery. *Anaesthesia* 1995; 50:26-9
- Gambling DR, Sharma SK, White PF, Van Beveren T, Bala AS, Gouldson R: Use of sevoflurane during elective cesarean birth: A comparison with isoflurane and spinal anesthesia. *Anesth Analg* 1995; 81:90-95
- Schaut DJ, Khona R, Gross JB: Sevoflurane inhalation induction for emergency cesarean section in a parturient without intravenous access. *ANESTHESIOLOGY* 1997; 86:1392-4
- Klafia JM: The practice of using sevoflurane inhalation induction for emergency cesarean section and a parturient with no intravenous access. *ANESTHESIOLOGY* 1998; 88:275-8
- Que JC, Lusaya VO: Sevoflurane induction for emergency cesarean section in a parturient in status asthmaticus. *ANESTHESIOLOGY* 1999; 90:1475-6
- Sotome K, Fukuda H, Akazawa S, Hirabayashi Y, Kasuda H, Inoue S, Shimizu R: [Anesthetic management for emergency cesarean section in a patient with intracranial hemorrhage due to ruptured arteriovenous malformation.] *Maui* 1999; 48:76-8

Anesthesiology 2001; 95:555-7

© 2001 American Society of Anesthesiologists, Inc. Lippincott Williams & Wilkins, Inc.

Foreign Body Aspiration: A Presenting Sign of Juvenile Myasthenia Gravis

David J. Murray, M.D.,* John McAllister, M.D. †

FOREIGN body aspiration is one of the most common pediatric airway emergencies. Neurologic and neuromuscular diseases are known to be predisposing factors for aspiration pneumonia, but there are no reports of a foreign body aspiration as the presenting diagnostic sign of an underlying neuromuscular disorder. We report an 8-yr-old boy who aspirated popcorn during a myasthenic crisis. This foreign body aspiration led to the subsequent diagnosis and treatment for juvenile myasthenia gravis (JMG).

Case Report

The patient was an 8-yr-old boy who experienced a choking episode while eating popcorn. Paramedics found that the child was cyanotic and had stridor and limited air movement, and they performed a Heimlich maneuver. The child coughed and regurgitated a large amount of popcorn. His ventilation improved, but he continued to have coarse breath sounds, stridor, and a weak voice. At the time of arrival in the emergency room, clinical examination indicated stridor, tachypnea, and poor air entry by auscultation. His oxygen saturation was 100% with 5 l O₂ delivered *via* a nonrebreathing mask. His admitting vital signs were blood pressure of 120/90 mmHg, heart rate of 121 beats/min, and respiratory rate of 30 breaths/min. His estimated body weight was 25 kg. He was alert during the initial examination, but when not stimulated, he closed his eyes and was quiet on the emergency room stretcher.

Fifteen minutes after his arrival in the emergency department, a chest radiograph was obtained en route to the operating room. During

transport to the operating room, his breathing was noted to be less stridorous with very limited gas exchange, and his oxygen saturation decreased despite increasing the oxygen flow to his nonrebreathing mask to 10 l/min. He was transferred to the operating room table with an oxygen saturation of 70% and a heart rate of 60 beats/min. Positive-pressure ventilation with an anesthesia bag and mask provided effective ventilation, and his oxygen saturation increased to 100%. His pharynx was suctioned for a large amount of undigested popcorn. He was able to move his extremities and open his eyes without difficulty but continued to have very limited gas exchange with spontaneous ventilation. His ventilation was assisted, and an inhalation induction was initiated with halothane in 5 l O₂. Less than 2 min after halothane induction was started, he was unresponsive and apneic. His ventilation was controlled, and a 40-mg propofol bolus was administered before direct laryngoscopy and bronchoscopy. The bronchoscope was inserted, and a large amount of undigested popcorn and popcorn kernels were identified in the trachea. This was removed in the course of a 90-min endoscopy. Anesthesia was maintained with a propofol infusion of 100 µg · kg⁻¹ · min⁻¹ as well as 1.0-1.5% halothane administered *via* the side arm of the Storz® bronchoscope (Storz Endoscopy, Culver City, CA). No neuromuscular blocking agents were administered during endoscopy. His cardiorespiratory status was stable throughout the endoscopy with a mean blood pressure between 70 and 80 mmHg, a heart rate between 80 and 100 beats/min, and an oxygen saturation greater than 95%. This boy's ineffective spontaneous ventilation en route to the operating room, his rapid loss of consciousness, and apnea during a halothane induction, as well as the large volume of aspirated material found during endoscopy, suggested an underlying neurologic condition.

After endoscopy, he was admitted to the pediatric intensive care unit and underwent ventilation *via* an endotracheal tube. Approximately 2 h after his arrival in the pediatric intensive care unit, he was alert and responsive and maintained an oxygen saturation of 100% on a fraction of inspired oxygen (F_IO₂) of 0.21 with a respiratory rate of 25 breaths/min. He had an effective cough and sustained handgrip but was noted to have ptosis and difficulty maintaining a sustained head lift. The endotracheal tube was removed 3 h after his arrival to the pediatric intensive care unit. His parents arrived after his emergency bronchoscopy and provided a detailed history of his problems at school and at home during the preceding 6 months. At school, his performance had deteriorated because his speech was often unintelligible and his handwriting was illegible. In addition to his difficulties at school, he had

* Professor, † Associate Professor.

Received from the Department of Anesthesiology, Washington University School of Medicine, St. Louis, Missouri. Submitted for publication December 22, 2000. Accepted for publication March 9, 2001. Support was provided solely from the Department of Anesthesiology, Washington University School of Medicine, St. Louis, Missouri.

Address reprint requests to Dr. Murray: Division of Pediatric Anesthesia 6W4, One Children's Place, St. Louis, Missouri 63110-1077. Address electronic mail to: murrayd@notes.wustl.edu. Individual article reprints may be purchased through the Journal Web site, www.anesthesiology.org.

stopped participating in an indoor soccer league because of his inability to keep up with his teammates. A head computed tomography scan was normal. He had been referred to speech and occupational therapists who were treating his hypernasal speech and gait disturbance. His parents reported that he seemed alert, active, and able to eat in the morning, but by the evening, he had difficulty holding his utensils, his speech was unintelligible, and he had trouble swallowing.

Clinical examination after his extubation confirmed global muscular weakness and ptosis. The differential diagnosis included myasthenia gravis, a motor neuron disorder, tick paralysis, botulism, a brain stem tumor, or syring. An electromyographic study of the right orbicularis oculi muscle showed a 50% decrement in response to repeated stimuli. After 3 min of facial muscle exercise, an 80% decrement in response to a 2-Hz stimulus was observed in this muscle group. Muscle studies in the distribution of the median nerve of the right forearm as well as the trapezius muscle did not show a decremental response with repeated stimuli at 2 Hz. JMG was diagnosed. Computed tomography of the chest and mediastinum indicated no thymic enlargement.

Administration of 60 mg oral pyridostigmine four times daily was started, and the patient was scheduled for plasmapheresis. After a subclavian double lumen catheter was placed during ketamine sedation, plasmapheresis was conducted on hospital days 4, 6, 8, 10, and 12. Each plasmapheresis replaced approximately 1.5 times the estimated plasma volume of the patient (1.7–1.9 l) with normal saline and 5% albumin. By the final plasmapheresis, he had minimal evidence of muscle weakness. He was discharged to his home with a pyridostigmine dosage of 60 mg orally, four times daily. He returned for elective cervical thymectomy 4 days later. Anesthesia was induced with propofol and maintained with sevoflurane and nitrous oxide for the 2-h operative procedure. After an uneventful operation and anesthesia, he underwent extubation in the operating room and was discharged from hospital the following morning. Six months after his thymectomy, he continues to be in remission and takes no medications.

Discussion

This child's presentation in myasthenic crisis was attributed to a more common problem in children—an aspirated foreign body. This report shows the importance of considering an undiagnosed neurologic or neuromuscular disease as an underlying cause of foreign body aspiration, particularly if the clinical presentation is in an older child. JMG is considered similar to the adult form but accounts for less than 2 or 3% of all patients with myasthenia gravis.^{1–3} Two other forms of myasthenia gravis occur in children.^{4,5} Transient neonatal myasthenia caused by placental transfer of acetylcholine receptor antibodies may be observed in as many as one fourth of neonates born to mothers with myasthenia gravis. Congenital myasthenic syndromes present in infancy or childhood and are believed to be a genetic defect of the neuromuscular junction rather than an autoimmune disorder of myasthenia gravis.^{4,5}

Using the Osserman classification to define the severity of symptoms at diagnosis, children often present with more severe symptoms of myasthenia gravis.⁶ Fifty percent of prepubescent children present, like the current patient, with respiratory symptoms or myasthenic crisis

(Osserman 3) at the time of diagnosis, compared to less than 10% of adults.^{1–3} Despite the more severe symptoms with JMG, no case reports have identified a myasthenia crisis as an underlying cause of foreign body aspiration in children.

This child's deterioration en route to the operating room was initially believed to be the result of complete airway obstruction from movement of the foreign body, but his rapid response to bag and mask ventilation suggested that an underlying neurologic condition caused hypoventilation.^{7,8} Although positive pressure ventilation was used during the anesthesia, neuromuscular blocking drugs were not administered during this anesthesia. An undiagnosed neuromuscular disease as a predisposing cause of foreign body aspiration is another reason for caution in the use of neuromuscular blocking drugs in children with airway foreign bodies.^{7,8} The use of either succinylcholine or a nondepolarizing neuromuscular drug would have complicated this child's recovery and potentially might have led to a further delay in his diagnosis and treatment.

Juvenile myasthenia gravis, like adult forms of the disease, is a prototypical autoimmune disorder.^{1–5,9} The presence of acetylcholine receptor antibodies in most patients, passive transfer symptoms of the disease associated with antibodies, and the improvement in condition that occurs when antibody titers decrease are evidence of the autoimmune origin.^{3–5} Plasmapheresis is frequently used preoperatively to reduce antibody titers and ameliorate disease symptoms.^{9–11} Thymectomy can produce a long-lasting remission of symptoms in many patients with this illness.^{12,13} Thymectomy was initially reserved for patients with thymoma and thymic hyperplasia, but early thymectomy results in remission in almost 50% of patients with JMG, compared to 10–20% remission in children who receive medical therapy.^{1,12,13} The rapid recovery and lesser surgical morbidity associated with cervical thymectomy compared to sternal thymectomy are additional reasons that many pediatric neurologists favor early thymectomy in children with JMG.^{1,13}

In summary, this report highlights the need to consider a neurologic or neuromuscular disease in patients with foreign body aspiration. This child's clinical presentation and response to treatment indicate some of the differences in presenting symptoms and signs and response to thymectomy in JMG compared with adult-onset myasthenia gravis.

References

1. Evoli A, Batocchi AP, Bartocconi E, Lino MM, Minisci C, Tonali P: Juvenile myasthenia gravis with prepubertal onset. *Neuromusc Disord* 1998; 8:561–7

2. Afifi AK, Bell WE: Tests for juvenile myasthenia gravis: Comparative diagnostic yield and prediction of outcome. *J Child Neurol* 1993; 8:403-11
3. Lindner A, Schalke B, Toyka KV: Outcome in juvenile-onset myasthenia gravis: A retrospective study with long-term follow-up of 79 patients. *J Neurol* 1997; 244:515-20
4. Heitmiller RF: Myasthenia gravis: clinical features, pathogenesis, evaluation, and medical management. *Semin Thorac Cardiovasc Surg* 1999; 11: 41-6
5. Drachman DB: Myasthenia gravis. *N Engl J Med* 1994; 330:1797-810
6. Osserman KE, Genkins G: Studies on myasthenia gravis: Review of twenty year experience in over 1200 patients. *Mt Sinai J Med* 1971; 38:497-537
7. Litman RS, Ponnuri J, Trogan I: Anesthesia for tracheal or bronchial foreign body removal in children: An analysis of ninety-four cases. *Anesth Analg* 2000; 91:1389-91
8. Kain Z, O'Connor T, Berde C: Management of tracheobronchial and esophageal foreign bodies in children: A survey study. *J Clin Anesth* 1994; 6:28-32
9. Andrews PI, Massey JM, Sanders DB: Acetylcholine receptor antibodies in juvenile myasthenia gravis. *Neurology* 1993; 43:977-82
10. Consensus Conference: The utility of therapeutic plasmapheresis for neurologic disorders. *JAMA* 1986; 256:1333-7
11. Krucylak PE, Naunheim KS: Preoperative preparation and anesthetic management of patients with myasthenia gravis. *Semin Thorac Cardiovasc Surg* 1999; 11:47-53
12. Heitmiller RF, Heitmiller ES: Surgery for myasthenia gravis, *Advanced Therapy in Thoracic Surgery*. Edited by Franco KL, Putman J. Philadelphia, BC Decker, 1998, pp 423-31
13. Adams C, Theodorescu D, Murphy EG, Shandling B: Thymectomy in juvenile myasthenia gravis. *J Child Neurol* 1990; 5:215-8