

The Unexpected Difficult Airway and Lingual Tonsil Hyperplasia

A Case Series and a Review of the Literature

Andranik Ovassapian, M.D.,* Raymond Glassenberg, M.D.,† Gail I. Randel, M.D.,† Allan Klock, M.D.,‡ Paul S. Mesnick, M.D.,‡ Jerome M. Klapf, M.D.‡

Background: An unexpected difficult intubation occurs because physical examination of the airway is imperfect in predicting it. Lingual tonsil hyperplasia (LTH) is one risk factor for an unanticipated failed intubation that is not detectable during a routine oropharyngeal examination. The authors attempted to determine the incidence of LTH in unanticipated failed intubation in patients subjected to general anesthesia.

Methods: Thirty-three patients with unanticipated failed intubation via direct laryngoscopy were subjected to airway examinations and fiberoptic pharyngoscopy to determine the cause(s) of failure. Mouth opening, mandibular subluxation, head extension, thyromental distance, and Mallampati airway class were recorded. Fiberoptic pharyngoscopy was then performed to evaluate the base of the tongue and valleculae.

Results: Of these 33 patients, none had an airway examination that suggested a difficult intubation. The lungs of 12 patients were difficult to ventilate by mask. In 15 patients, airway measurements were within normal limits with Mallampati class of I or II. Ten patients had a Mallampati class III airway, 6 associated with obesity and 5 with mildly limited head extension. Among the 5 morbidly obese patients, most of the weight was distributed on the lower trunk and body. The 3 remaining patients had a thyromental distance of 6 cm or less but otherwise had a normal airway examination. The only finding common to all 33 patients was LTH observed on fiberoptic pharyngoscopy.

Conclusion: Lingual tonsil hyperplasia can interfere with rigid laryngoscopic intubation and face mask ventilation. Routine physical examination of the airway will not identify its presence. The prevalence of LTH in adults and the extent of its contribution to failed intubation is unknown.

UNANTICIPATED difficult intubation remains a serious problem for anesthesiologists. Clinical studies have failed to establish a strong positive predictive value for anatomical risk factors that may contribute to the difficulty of tracheal intubation.¹⁻⁴ A supraepiglottic mass was recognized as one risk factor for unanticipated failed tracheal intubation in several case reports.⁵⁻²² In many of those reports, the supraepiglottic mass was lingual tonsil hyperplasia (LTH).⁵⁻¹⁶ In one patient with LTH, a

combination of failed mask ventilation and intubation resulted in hypoxic brain damage and death.⁸ We tried to determine the incidence and possible role of LTH in unanticipated failed intubations in patients scheduled for various surgical procedures.

Material and Methods

Approval for analysis and publication of these data were obtained from the institutional review boards of Northwestern University and the University of Chicago. From July 1989 to December 2000, 27 patients with failed rigid laryngoscopic tracheal intubation and 6 patients with a history of unanticipated failed intubation were subsequently examined for the cause(s) of failure (fig. 1). Failed intubations were considered unanticipated when preoperative physical examination did not strongly suggest a possible difficulty and when intubation failed after two or more attempts by an experienced anesthesiologist. Failed intubation was defined as inability to pass an endotracheal tube into the trachea because of inadequate exposure of the glottis with a grade 4 rigid laryngoscopic view. The initial intubation attempt in 27 patients during general anesthesia with complete relaxation with nondepolarizing muscle relaxant was conducted by a resident. Subsequent intubation attempts (limited to four in most patients) included the use of both curved and straight blades with a stylette. At least two of the attempts were made by the attending anesthesiologist with a minimum of 10 yr experience. The decision to stop further rigid laryngoscopy attempts and switch to fiberoptic intubation was made by the attending anesthesiologist. Fiberoptic intubations were performed either by the attending anesthesiologist in charge or the first author, who acted as a consultant. Ventilation by face mask was considered difficult when, in addition to placement of an oral airway, jaw thrust was required by a second person for unobstructed air exchange. Ventilation was considered very difficult when oral or nasal airways and jaw thrust applied by a second person did not completely overcome the airway obstruction. Ventilation was considered impossible when air exchange could not be established with oral and nasal airways in place and a second person applying jaw thrust.

Upon recovery from anesthesia, verbal consent was obtained from the patient for examination of the airway and fiberoptic pharyngoscopy by the senior author. Before the status of the base of the tongue and valleculae was evalu-

* Professor, ‡ Assistant Professor, Department of Anesthesia and Critical Care, The University of Chicago. † Assistant Professor, Department of Anesthesiology, Northwestern University.

Received from the Department of Anesthesia and Critical Care, The University of Chicago, Chicago, Illinois, and the Department of Anesthesiology, Northwestern University, Chicago, Illinois. Submitted for publication October 8, 2001. Accepted for publication February 14, 2002. Support was provided solely by institutional and/or departmental sources. Presented at the annual meeting of the American Society of Anesthesiologists, New Orleans, Louisiana, October 17, 2001.

Address reprint requests to Dr. Ovassapian: Department of Anesthesia and Critical Care, University of Chicago Hospitals, MC 4028, 5841 South Maryland Avenue, Chicago, Illinois 60637. Address electronic mail to: aovassap@airway.uchicago.edu. Individual article reprints may be purchased through the Journal Web site, www.anesthesiology.org.

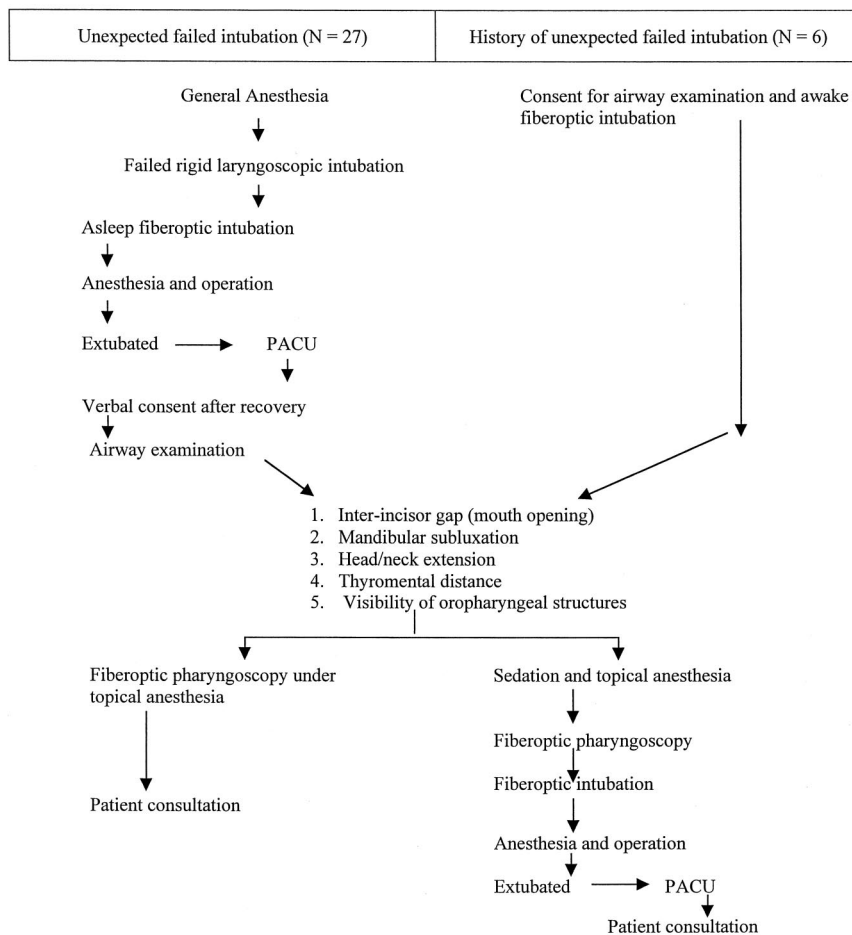


Fig. 1. Sequence of patients' evaluations in 33 failed intubations.

ated by fiberoptic pharyngoscopy, patients were examined, and measurements were recorded for five known anatomic risk factors¹⁻⁴: (1) the interincisor gap measurement with the mouth fully open; (2) mandibular subluxation measured by the distance between the incisors when the lower were protruded maximally beyond the upper; (3) head extension over the neck in the sitting position subjectively rated as not limited if the tip of the chin and ear lobe were in the same horizontal line, mildly limited with a two-thirds extension, moderately limited with a one-third extension, or unable to extend the head; (4) thyromental distance measured in a straight line from the thyroid notch to the anterior border of the mandibular mentum with the mouth closed and head in full extension; and (5) Mallampati class, determined by the visibility of the oropharyngeal structures in a seated patient, with the head in a neutral position, mouth fully opened, and tongue protruding maximally without phonation.² In class I, faucial pillars, soft palate, and uvula are in view. In class II, the uvula is masked by the base of the tongue and is not visible. In class III, faucial pillars and uvula are not visible, and only the soft palate is seen.

After the physical examination was completed and measurements were recorded, flexible fiberoptic pharyngoscopy was performed through the mouth in 31

patients and through the nose in 2 patients. In the oral approach, the base of the tongue and pharyngeal walls were anesthetized with 4% lidocaine spray. An intubating airway was placed to prevent accidental damage to the fiberscope. In the nasal approach, the mucosa was anesthetized with 4% cocaine in one patient and a combination of 3% lidocaine and 0.25% phenylephrine on a cotton tip applicator in the other. The fiberoptic bronchoscope was passed through the airway or the prepared nostril to visualize the epiglottis, base of the tongue, valleculae, and glottic opening without touching the laryngeal structures.

Six other patients who had a history of unexpected failed intubation scheduled for operation with general anesthesia were subjected to the same airway examination and measurements preoperatively. Fiberoptic pharyngoscopy was performed in the operating room during fiberoptic orotracheal intubation with topical anesthesia and sedation. A picture of the hypopharynx was taken in 21 patients.

After all data were compiled, in order to determine if physical examination would have predicted difficult laryngoscopy in these patients, we applied the composite airway risk score for grade III or IV laryngoscopic view, as described by El-Ganzouri *et al.*²³ This scoring system

Table 1. Demographic and Airway Assessment Data

Case No.	Age	Sex	PS	Weight (kg)	Height (cm)	BMI	MO (cm)	MS (mm)	TMD (cm)	Head Extension	Mall. Class	Dentition
Group 1: Patients with normal airway measurements (n = 15)												
1	57	M	1	88	170	30	4.6	3	8.0	Full	2	Full set
2	69	M	3	105	190	29	5.5	2	7.5	2/3*	1	Full set
3	44	F	1	59	155	24	4.4	8	6.3	Full	2	Full set
4	66	M	2	86	177	28	5	5	7.0	Full	2	Full set
5	44	M	2	114	185	33	5	3	7.5	2/3*	1	Full set
6	63	M	2	74	180	23	4.5	2	7.2	Full	2	Full set
7	47	F	1	58	162	22	4	2.5	8	Full	2	Full set
8	37	F	1	45	147	20	4	2	7.5	Full	1	Full set
9	27	F	1	97	167	35	4	1	6.4	Full	1	Full set
10	34	M	2-E	100	182	30	5.6	1	8.5	Full	2	Missing upper front tooth
11	37	M	2	73	170	25	5.0	11	7.5	Full	1	Full set
12	65	M	3	66	172	23	5.5	3	7	Full	1	Full set
13	33	F	1	70	167	25	4.3	4	7.4	Full	2	Full set
14	50	F	2	65	156	27	4.9	4	8.5	Full	2	Full set
15	49	F	2	107	162	40	3.9	1	10	Full	1	Full set
Group 2: Patients with Mallampati class III (n = 10)												
16	59	M	2	111	170	38	4.5	2	7.5	2/3*	3	Full set
17	45	M	1	102	175	33	4.1	2	7.0	Full	3	Full set
18	37	M	2	77	182	23	3.8	1	7.0	Full	3	Full set
19	46	M	2	90	150	40	4	3	5.5	Full	3	Missing upper middle two
20	52	M	2	100	177	32	4.4	3	7.0	2/3*	3	Full set
21	71	M	2	102	172	34	5.5	4	7.5	Full	3	Missing upper incisors
22	40	M	1	75	165	28	3.0	3	8.7	Full	3	Full set
23	78	M	3	103	185	30	6.0	3	7.5	1/3*	3	Edentulous
24	69	F	2	60	166	21	4	2	7.5	2/3	3	Full set
25	36	M	1	104	167	37	4	2	6.5	2/3	3	Full set
Group 3: Morbidly obese with normal airway findings (n = 5)												
26	66	F	2	110	162	42	4.8	3	7.5	2/3	3	Full set
27	46	F	3	107	157	43	5.0	3	7.5	Full	1	Full set
28	53	F	3	156	156	65	5	5	7.5	2/3	2	Full set
29	47	M	3	182	182	55	5.5	4	9.5	2/3	2	Full set
30	60	F	2	116	164	43	5	3	8.5	Full	2	Full set
Group 4: TMD of ≤ 6 cm (n = 3)												
31	62	M	4	74	167	26	4.7	0	6.0	2/3	2	Full set
32	42	M	2	73	165	27	3.7	1	5.8	Full	1	Full set
33	52	F	2	57	162	22	4.0	2	6	Full	1	Full set

PS = American Society of Anesthesiologists physical status classification; BMI = body mass index; MO = mouth opening; MS = mandibular subluxation; TMD = thyromental distance; Mall. = Mallampati class.

assigns weighted scores to 6 physical examination characteristics (mouth opening, thyromental distance, Mallampati class, neck movement, ability to prognath, and body weight) and history of difficult intubation to predict difficulty with laryngoscopy.²³ The score provided an objective rating system to rate anatomic findings and history of difficult intubation in predicting a difficult laryngoscopy.

During a postoperative visit, the findings of the airway examination were shared with the patient. The importance of the findings was explained, and some patients were registered with the Medic Alert system.

Results

No results from the 33 patients were excluded from analysis. The demographic characteristics of these pa-

tients and other data are presented in tables 1 and 2. The patients are presented in four groups. Group 1 consisted of 15 patients all of whom had airway measurements within normal values not expected to interfere with tracheal intubation. Three patients (Nos. 5, 9, 15) in this group were overweight or obese with a body mass index between 31 and 40.

In the 10 patients in group 2, the main finding was a Mallampati class III airway. Six of these patients were also obese (body mass index 31-40), 5 had mildly limited head extension, and 1 had short thyromental distance.

The 5 patients in group 3 were morbidly obese (body mass index > 40), but most of their weight was distributed on the lower trunk and body. Patient 26 in this group also had a Mallampati class III rating, and 3 had mildly limited head extension (Nos. 26, 28, 29).

Group 4 included 3 patients with a thyromental distance less than or equal to 6 cm; head extension was mildly limited in 1 patient in this group.

The composite airway risk index scores for each subject are shown in figure 2. The maximum possible score is 32. Sixty-four percent of our subjects had scores less than or equal to 11, which would correlate with approximately 95% chance of easy intubation. The score of six patients with a history of difficult intubation would be 9 points less if the score is based on physical examination only. Four of these 6 patients would have a total score of 7 or less.

Fiberoptic pharyngoscopy was tolerated well by all patients and showed LTH in every case. The lingual tonsils of 21 patients were photographed; 6 are presented in figure 3. The specifics of fiberoptic intubation²⁴ are presented in table 3.

Face mask ventilation was considered difficult or impossible in 12 (35.3%) patients (table 4). Face mask ventilation was very difficult in one patient and impossible in another, but both were successfully ventilated with a size 4 laryngeal mask airway (LMA). The LMA was then removed and fiberoptic intubation performed. One of the 6 patients in the awake-intubation group (case 26) had had a history of difficult mask ventilation and intubation in another hospital 10 yr previously. At that time, difficult ventilation became impossible after repeated attempts at intubation. The patient suffered cardiac arrest as a result of severe hypoxia. Resuscitation was successful after blind orotracheal intubation with a 6-mm endotracheal tube.

Discussion

After a clinician encounters an unanticipated difficult intubation, there is reason to reflect upon the case to determine if the difficult laryngoscopy could have been anticipated. Occasionally, a thorough airway examination may not have been performed (e.g., in an emergency procedure), or the assessment may not have been performed properly. Neither of these scenarios applied to the subjects in this study. All of the patients received a preoperative airway assessment by an experienced anesthesiologist and were thought to be suitable candidates for intravenous induction of general anesthesia and paralysis before direct laryngoscopy. In addition, a second experienced practitioner (A. O.) independently performed an airway evaluation, where low composite airway risk index scores were found for most of the patients, especially in group 1 (fig. 2), conferring a low probability of difficult laryngoscopy.

Every patient in our series had LTH. In 15 (Nos. 1-15), this was the only finding that could have contributed to failure of intubation. The lingual tonsils are composed of nodular irregular lymphoid tissues at the base of the

tongue, confined between the epiglottis posteriorly, valvate papillae anteriorly, and the tonsillar pillars bilaterally. The lingual tonsils are usually symmetrically distributed on either side of the glossoepiglottic fold, but they may be unilateral. Huge lingual tonsils can occupy the entire vallecula and in some patients override the tip and lateral borders of the epiglottis. Enlarged lingual tonsils can displace the epiglottis posteriorly, causing dysphagia and respiratory obstruction.

Lingual tonsil hyperplasia in adults is often asymptomatic, but a number of symptoms, such as sore throat, dysphagia, globus sensation, snoring, feeling of lump in the throat, and obstructive sleep apnea, should alert clinicians to its presence.²⁵ Two thirds of patients with LTH have a history of palatine tonsillectomy or adenoidectomy.²⁵ Tonsillectomy may contribute to compensatory LTH in individuals with repeated pharyngeal inflammatory episodes. LTH may cause airway obstruction,²⁶⁻²⁹ recurrent acute tonsillitis,³⁰ sleep apnea,³¹ and recurrent epiglottitis.³²

Benign LTH,⁵⁻¹⁶ acute lingual tonsillitis,^{29,30} lingual tonsillar abscess, lingual thyroid,²² and thyroglossal cysts¹⁷⁻²⁰ are recognized causes of respiratory obstruction contributing to difficult mask ventilation and tracheal intubation. External physical examination of the airway will not identify patients with a supraepiglottic mass. The lingual tonsils, located at the posterior section of the tongue, are not visible to simple inspection of the oropharynx. If ventilation *via* face mask or LMA is acceptable and oxygenation is maintained at a satisfactory level, fiberoptic intubation can be applied successfully, as was the case for the 27 anesthetized patients in this report. With a fiberscope, atraumatic intubation and evaluation of an airway are possible. When failed intubation is associated with difficult or impossible mask ventilation (cannot intubate-cannot ventilate), establishing ventilation, not tracheal intubation, becomes the primary concern. The LMA has been used in cannot-intubate-cannot-ventilate situations caused by LTH with success^{9,10,12,14,33} or with partial success.¹¹ In one patient, ventilation could not be established with an LMA.³³ Laryngeal mask placement requires less time than most intubation techniques and is less invasive than other ventilatory devices and tracheostomy. If an airway cannot be established with a laryngeal mask, a Combitube (Kendall Health Care), transtracheal jet ventilation, or cricothyrotomy are other options.

Several anatomic characteristics have been applied to identify patients who may be difficult to intubate, including the Mallampati test, thyromental distance, mouth opening, head extension, and subluxation of the mandible.¹⁻³ Their value as predictors of difficult laryngoscopy and intubation is limited because they are associated with a high incidence of false-positive and false-negative results.¹⁻³ In studies of the value of multiple risk factors for prediction of difficult intubation, results are conflicting, and the models vary widely.^{4,23,34,35} Variability is

Table 2. Ventilation and Intubation Information

	General Anesthesia		Fiberoptic Intubation				
	Mask Ventilation	Rigid Laryngoscopy	Scope Size (mm)	Tube Size	Ease of Intubation	Attempt	ET Tube Insertion (Smoothly)
Group 1: Patients with normal airway measurements (n = 15)							
1	Difficult	2 attempts	4	41F DLT	Mod. diff.	1	Yes
2	Easy	4 attempts	4	8	Easy	1	Yes
3	Easy	4 attempts	4	7	Mod. diff.	3	Yes
4	Easy	3 attempts	4	8.5	Mod. diff.	2	Yes
5	Easy	3 attempts	4	8	Mod. diff.	3	No
6	Easy	4 attempts	5	8	Difficult	2	Yes
7	Easy	4 attempts	6	7.5	Easy	1	Yes
8	Difficult	3 attempts	4	7	Mod. diff.	1	Yes
9	Easy	6 attempts	6	7	Difficult	2	Yes
10	Easy	4 attempts	5	8	Mod. diff.	1	Yes
11	Easy	4 attempts	5	8	Mod. diff.	1	Yes
12	Easy	4 attempts	4	8	Difficult	3	No
13	Easy	4 attempts	5	7.5	Difficult	1	No
14	Difficult	4 attempts	4	7.5	Easy	1	No
15	Hx of difficult	Hx of failed intubation	6	7.5	Awake	1	Yes
Group 2: Patients with Mallampati class III (n = 10)							
16	Difficult	3 attempts	5	8	Mod. diff.	1	No
17	Difficult	5 attempts	4	9	Mod. diff.	2	Yes
18	Easy	5 attempts	4	8	Mod. diff.	1	Yes
19	Easy	5 attempts	4	7	Easy	1	Yes
20	Easy	2 rigid and Upshire	4	8	Easy	1	No
21	Easy	4 attempts	4	8	Easy	1	No
22	Easy	3 attempts	6	8	Easy	1	Yes
23	Difficult	4 attempts	4	8	Easy	1	Yes
24	Hx of difficult	Hx of failed intubation	5	7	Awake	1	No
25	Very difficult LMA	3 attempts	5	8	Mod. diff.	2	No

(continues)

found in study design, patient population, and the definition of a difficult intubation. We chose to apply the El-Ganzouri composite risk index score because it has been validated in a large population, and our database

included all the variables necessary to calculate the score.

Tests to identify patients with a potentially difficult intubation have not included evaluation of the epiglottis

Table 2. (continued)

General Anesthesia			Fiberoptic Intubation			
Mask Ventilation	Rigid Laryngoscopy	Scope Size (mm)	Tube Size	Ease of Intubation	Attempt	ET Tube Insertion (Smoothly)
Group 3: Morbidly obese with normal airway findings (n = 5)						
26	Hx of impossible cardiac arrest	Hx of failed intubation	6	7.5	Awake Mod. diff.	1 No
27	Hx of impossible, LMA	Hx of failed intubation 1 hr 45 min try	6	7.5	Awake Easy	1 Yes
28	Hx of difficult	Hx of failed intubation; tip of epiglottis only	5	7.5	Awake Easy	1 Yes
29	Hx of difficult	Hx of failed intubation, GERD	5	7.5	Awake Mod. diff.	1 Yes
30	Easy	4 attempts tip of epiglottis only	4	7	Mod. diff.	1 Yes
Group 4: TM distance of ≤ 6 cm (n = 3)						
31	Easy	3 attempts tip of epiglottis only	4	8	Easy	1 No
32	Easy	3 attempts tip of epiglottis only	4	7.5	Easy	1 Yes
33	Easy	4 attempts tip of epiglottis only	4	7 RAE	Easy	1 Yes

and supraepiglottic area. Ignoring this area may have contributed to the poor positive predictive value of commonly accepted risk factors or may have given undeserved validity to some factors such as a Mallampati class III airway. In one study, only 6.6% of patients with Mallampati III or IV airways were difficult to intubate.³⁵ In our study, 10 patients had Mallampati class III airways;

whether LTH or Mallampati class III contributed more to the difficulty of intubation is not known at this time. There is general agreement that face mask ventilation is often difficult in morbidly obese patients.³⁶ There is less consensus about the difficulty of tracheal intubation in the morbidly obese.^{1,37,38} Obesity has been considered a weak predictor of difficult intubation¹ or excluded en-

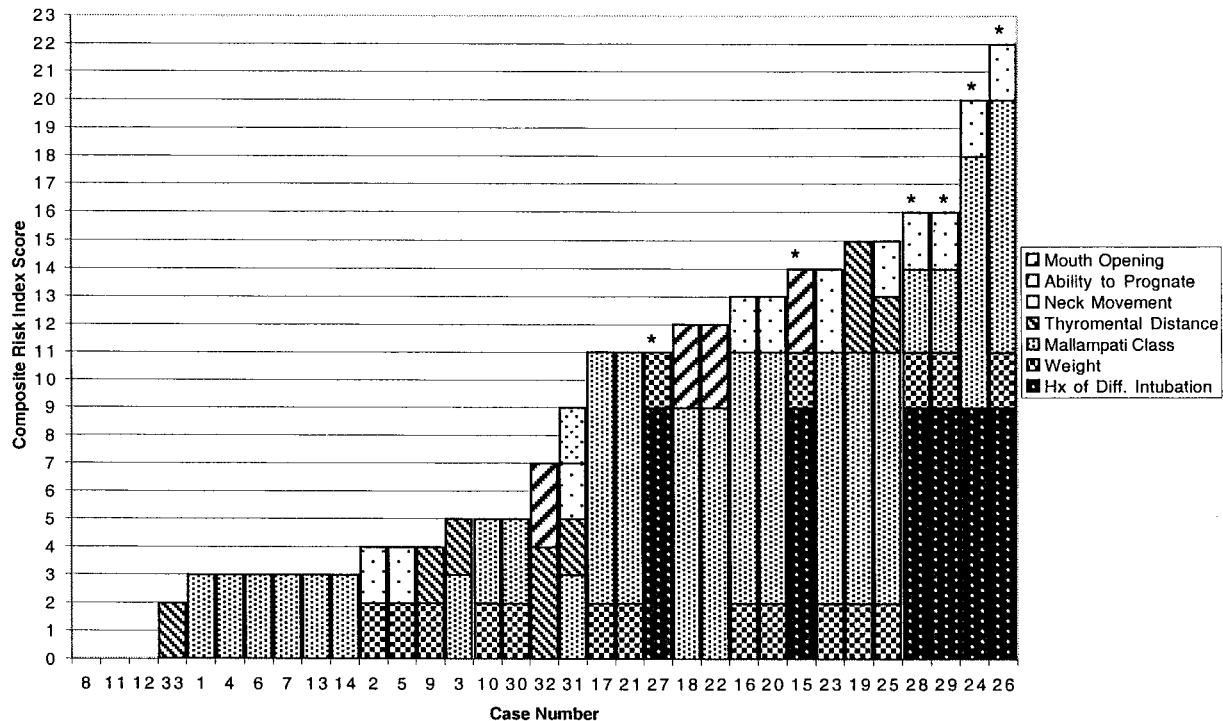


Fig. 2. Histogram of composite airway risk index score. Stacked bar graph of composite airway risk index scores are arranged from lowest to highest. The score is calculated using El-Ganzouri's multivariate model for grade III or IV laryngoscopic view. The median score is 7. Subjects identified with an asterisk had a history of difficult intubation.

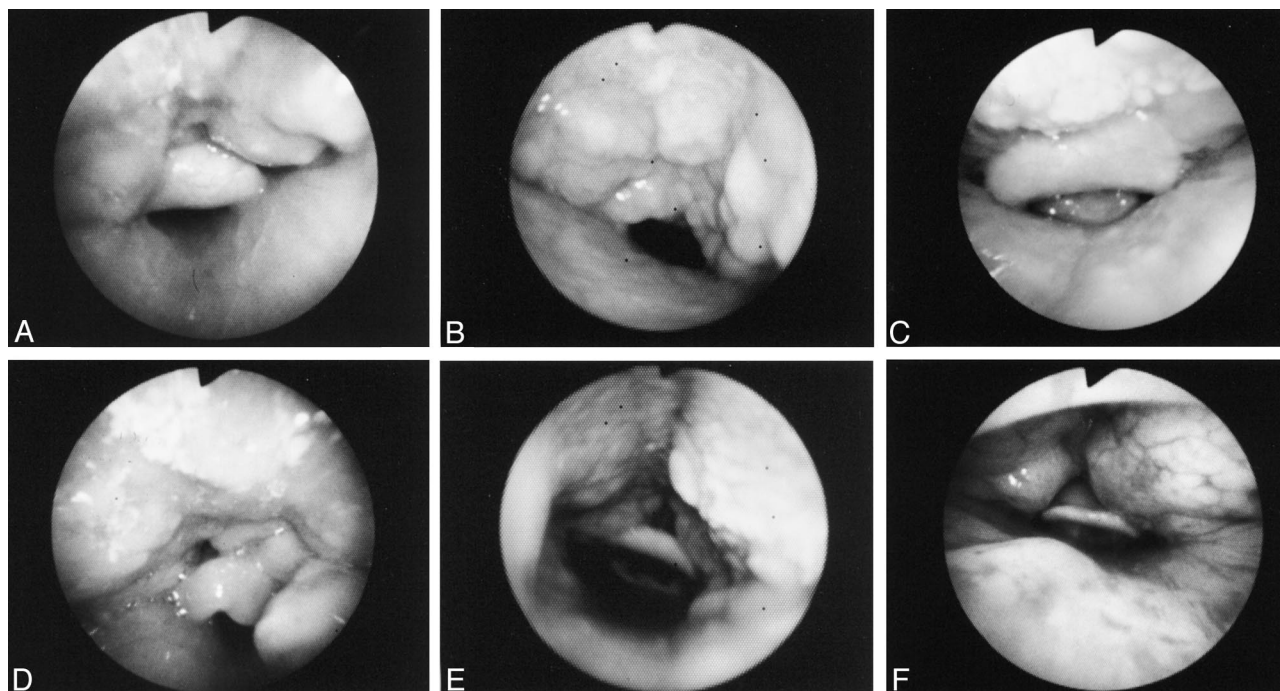


Fig. 3. Endoscopic view of the epiglottis and vallecula of six patients awake and breathing spontaneously. **Group 1:** (A) Patient 15: This patient had a history of failed intubation and difficult mask ventilation. Massive hypertrophy of lingual tonsil covers the tip and lateral borders of the epiglottis. **Group 2:** (B) Patient 24: Failed rigid intubation resulted in an unrecognized esophageal tear but was intubated with fiberoptic for loop ileostomy. The patient returned later that day for repair of the esophageal tear. Awake fiberoptic intubation showed massive enlargement of the lingual tonsils extended to the tip and lateral borders of the epiglottis. **Group 3:** (C) Patient 26: Ten years ago when the patient weighed 85 kg, she could not be intubated and suffered cardiac arrest. A 6-mm tube was placed blindly into the trachea followed by successful resuscitation. The massive enlargement of the lingual tonsils covers the lateral borders and the tip of the epiglottis. (D) Patient 27: Previous anesthesia 8 months ago for thoracotomy was cancelled after 90 min of failed intubation attempts. Face mask ventilation was also impossible from the beginning and a size 4 LMA was used to ventilate the lungs between intubation attempts. Awake fiberoptic orotracheal intubation was performed for an orthopedic procedure. Massive lingual tonsils with redundant pharyngeal tissues pushed the epiglottis down against the posterior pharyngeal wall. (E) Patient 29: Scheduled for gastric bypass revision. Mask ventilation was difficult with both oral and nasal airways in place. Large lingual tonsils occupy the entire vallecula extending down to the tip and lateral edges of the epiglottis. **Group 4:** (F) Patient 33: The lobulated mass represents lingual tonsil hyperplasia (LTH). ENT consultation confirmed LTH and ruled out hemangioma.

tirely as a risk factor.³⁵ Still, others have found no correlation between body mass index and difficult laryngoscopy.³⁷

Two studies using magnetic resonance imaging and three-dimensional helical scans could not identify sets of soft tissue measurements that would distinguish difficult from easy intubations in 20 and 24 patients with known difficult intubations, respectively.^{38,39} The distances between the epiglottis, uvula, vocal cords, and the posterior pharyngeal wall were measured. The absence or presence of hyperplastic lingual tonsils was not considered in these two studies.

In a study evaluating the larynx with indirect mirror laryngoscopy, difficult intubation correlated better with a grade 3 or 4 laryngeal view than with Mallampati classification or Wilson risk sum score.⁴⁰ In grade 3, the epiglottis is visible; in grade 4, no glottic structure is visible. The study did not identify the anatomic features contributing to a grade 3 or 4 laryngeal view.

When acoustic reflection measurements of upper airway open space were compared in two groups of patients (one with failed tracheal intubation, the other easy

to intubate),⁴¹ the open pharyngeal volume was smaller in the failed-intubation group. Acoustic reflectometry measurements discriminated between failed and successful intubation based on pharyngeal volume, not routinely measured on physical examination. As an adjunct to physical examination, acoustic reflection measurement of airway space may provide a simple technical method to improve detection of difficult-to-intubate patients.

The science of predicting difficult laryngoscopy is imperfect. The composite airway risk score would have indicated a very low rate of difficult laryngoscopy for the majority of our patients.²³ Eighteen of our 33 subjects had total scores of 9 or less, which should have conferred a risk of a difficult laryngoscopy less than 9%.

When LTH produces a cannot-intubate-cannot-ventilate situation, the option of surgical excision of the enlarged tonsils should be discussed with the patient and the otolaryngologist. Lingual tonsillectomy has not been performed or recommended as a prophylactic measure to avoid future cannot-intubate-cannot-ventilate, life-threatening emergency situations. It has been performed

Table 3. Specifics of Successful Fiberoptic Intubations

	Anesthetized n (%)	Awake n (%)
Degree of difficulty*		
Easy	11 (41)	2 (33)
Moderately difficult	12 (44)	4 (66)
Difficult	4 (15)	0 (0)
Intubation attempts		
1	18 (66.6)	6 (100)
2	6 (22.2)	—
3	3 (11.1)	—
Endotracheal tube size (mm-ID)		
7	6 (22.2)	0
7.5	4 (14.8)	1 (16.7)
8	14 (51.9)	5 (83.3)
8.5	2 (7.4)	0
41-French DLT	1 (3.7)	0
Fiberscope size (mm)		
4	18 (67)	0
5	6 (22)	3 (50)
6	3 (11)	3 (50)
Tube entered trachea		
Smoothly	18 (67)	4 (67)
Against resistance†	9 (33)	2 (33)

* The definitions below are modified from Ovassapian *et al.*²⁴

Easy: Fiberscope well aligned for visualization of the cords and little or no manipulation of the fiberscope tip is required to enter the trachea. Intubation is achieved on the first attempt.

Moderately difficult: Some manipulation of fiberscope in all directions is necessary to locate the glottis and enter the trachea. Intubation is achieved with one or two attempts.

Difficult: Extensive manipulation of the fiberscope in all directions is necessary to identify the vocal cords and enter the trachea. Intubation is achieved in two attempts or more.

† More than one try was required to advance the tube over the fiberscope into the trachea.

to overcome airway obstruction,²⁷⁻²⁹ prevent repeated attacks of acute epiglottitis,³² and treat obstructive sleep apnea.³¹ Surgical excision of lingual tonsils can cause major blood loss; however, cryosurgery and carbon dioxide lasers have made lingual tonsillectomy a safer and simple procedure.³¹

Our study has four limitations. The prevalence of LTH in adults and how often LTH alone or in combination with other risk factors contributes to failed intubation is unknown. A large-scale study of surgical patients is needed to shed light on prevalence of LTH and its contribution to a difficult airway. We did not

Table 4. Face Mask Ventilation in Patients with Failed Rigid Laryngoscopy Intubation

Patients	Easy	Difficult	Very Difficult	Impossible
Anesthetized (n = 27)	20	6	1*	0
Awake (n = 6), previous anesthetic	0	4	0	2*

In the second patient (No. 26), the impossible face mask ventilation happened 10 yr ago. The patient suffered cardiac arrest when a 6-mm endotracheal tube was passed blindly into the trachea and resuscitated successfully.

* Laryngeal mask airway (LMA, size 4) successfully placed for lung ventilation in one very difficult and one impossible face mask ventilation.

include all cases of unsuspected failed intubations during the 10-yr study period because the first author was not consulted in all cases. The examination of the airway was performed after failed intubation by one person aware of the failure, even though physical examination and measurements had been recorded before fiberoptic laryngoscopy. Finally, because several experienced anesthesiologists were involved in the anesthetic and airway management of these patients, it is likely that uniform patient positioning for intubation was not adhered to.

In summary, this report provides additional evidence that LTH may interfere with rigid laryngoscopic intubation and face mask ventilation. Routine physical examination of the airway will not identify its presence. All patients with unanticipated failed intubation should be subjected to fiberoptic examination to rule out the presence of LTH. Fiberoptic laryngoscopy is an excellent diagnostic modality, easily performed in the hospital or in an outpatient setting with good patient acceptance. The therapeutic role of surgical excision of enlarged lingual tonsils for the prevention of future cannot-ventilate-cannot-intubate situations needs to be explored.

References

- Wilson ME, Spiegelhalter D, Robertson JA, Lesser P: Predicting difficult intubation. *Br J Anaesth* 1988; 61:211-6
- Mallampati SR, Gatt SP, Gugino LD, Desai SP, Waraksa B, Freiburger D, Liu PL: A clinical sign to predict difficult tracheal intubation: A prospective study. *Can Anaesth Soc J* 1985; 32:429-34
- Calder I, Calder J, Crockard HA: Difficult direct laryngoscopy in patients with cervical spine disease. *Anaesthesia* 1995; 50:756-63
- Karkouti K, Rose DK, Wigglesworth D, Cohen MM: Predicting difficult intubation: A multivariable analysis. *Can J Anaesth* 2000; 47:730-9
- Ovassapian A: Case reports, Fiberoptic Airway Endoscopy in Anesthesia and Critical Care. Edited by Ovassapian A. New York, Raven Press, 1990, pp 149-62
- Guarisco JL, Littlewood SC, Butcher RB III: Severe upper airway obstruction in children secondary to lingual tonsil hypertrophy. *Ann Otol Rhinol Laryngol* 1990; 99:621-4
- Georgescu A, Miller JN, Lecklitner ML: The Sellick maneuver causing complete airway obstruction. *Anesth Analg* 1992; 74:457-9
- Jones DH, Kohle SD: Unanticipated difficult airway secondary to lingual tonsillar hyperplasia. *Anesth Analg* 1993; 77:1285-8
- Baraka A: Laryngeal mask airway in the cannot-intubate, cannot-ventilate situation (letter). *ANESTHESIOLOGY* 1993; 79:1151-2
- Biro P, Shahinian H: Management of difficult intubation caused by lingual tonsillar hyperplasia (letter). *Anesth Analg* 1994; 79:389
- Fundingsland BW, Benumof JL: Difficulty using a laryngeal mask airway in a patient with lingual tonsil hyperplasia (letter). *ANESTHESIOLOGY* 1996; 84:1265-6
- Conacher ID, McMahon CC, Meikle D: "Chicane-like" airway as a complication of lingual tonsils (letter). *Lancet* 1996; 348:475
- Omote K, Kawamata T, Imaizumi H, Namiki A: Case of Cowden's disease that caused airway obstruction during induction of anesthesia. *ANESTHESIOLOGY* 1999; 91:1537-40
- Dell RG: Upper airway obstruction secondary to a lingual tonsil (letter). *Anaesthesia* 2000; 55:393
- Andrews SR, Mabey MF: Tubular fiberoptic laryngoscope (WuScope) and lingual tonsil airway obstruction. *ANESTHESIOLOGY* 2000; 93:904-5
- Asai T, Hirose T, Shingu K: Failed tracheal intubation using a laryngoscope and intubating laryngeal mask. *Can J Anaesth* 2000; 47:325-8
- Mason DG, Wark KJ: Unexpected difficult intubation: Asymptomatic epiglottic cysts as a cause of upper airway obstruction during anaesthesia. *Anaesthesia* 1987; 42:407-10
- Rashid J, Wartler B: Awake fiberoptic intubation for a rare cause of upper airway obstruction: An infected laryngocoele. *Anaesthesia* 1989; 44:834-6
- Kamble VA, Lilly RB, Gross JB: Unanticipated difficult intubation as a result of an asymptomatic vallecular cyst. *ANESTHESIOLOGY* 1999; 91:872-3
- Henderson LT, Denneny JC III, Teichgraber J: Airway-obstructing epiglottic cyst. *Ann Otol Rhinol Laryngol* 1985; 94:473-6

21. Crozier WC: Upper airway obstruction in neurofibromatosis. *Anaesthesia* 1987; 42:1209-11
22. Buckland RW, Pedley J: Lingual thyroid: A threat to the airway. *Anaesthesia* 2000; 55:1103-5
23. El-Ganzouri AR, McCarthy RJ, Tuman KJ, Tanck EN, Ivankovich AD: Preoperative airway assessment: Predictive value of a multivariate risk index. *Anesth Analg* 1996; 82:1197-204
24. Ovassapian A, Yelich SJ, Dykes MHM, Brunner EE: Blood pressure and heart rate changes during awake fiberoptic nasotracheal intubation. *Anesth Analg* 1983; 62:951-4
25. Golding-Wood DG, Whittet HB: The lingual tonsil: A neglected symptomatic structure? *J Laryngol Otol* 1989; 103:922-5
26. Johnson CA, Mehdiabadi RJ, Ruff T: Infection and hypertrophy of the lingual tonsil as a cause of airway obstruction. *Tex Med* 1986; 82:29-31
27. Dindzans IJ, Irvine BWH, Hayden RE: An unusual case of airway obstruction. *J Otolaryngol* 1984; 13:252-4
28. Kashyap A, Farid A, Aldridge R, King AB: Lingual tonsil causing airway obstruction. *Ear Nose Throat J* 1994; 73:830-4
29. Bourne RA, Cameron PA, Dziukas L: Respiratory obstruction with lingual tonsillitis. *Anaesth Intensive Care* 1992; 20:367-9
30. Puar RK, Puar HS: Lingual tonsillitis. *South Med J* 1986; 79:1126-8
31. Olsen KD, Suh KW, Staats BA: Surgically correctable causes of sleep apnea syndrome. *Otolaryngol Head Neck Surg* 1981; 89:726-31
32. Wilson JF, Coutras S, Tami TA: Recurrent adult acute epiglottitis: The role of lingual tonsillectomy. *Ann Otol Rhinol Laryngol* 1989; 98:602-4
33. Parmet JL, Colonna-Romano P, Horrow JC, Miller F, Gonzales J, Rosenberg H: The laryngeal mask airway reliably provides rescue ventilation in cases of unanticipated difficult tracheal intubation along with difficult mask ventilation. *Anesth Analg* 1998; 87:661-5
34. Lewis M, Keramati S, Benumof JL, Berry CC: What is the best way to determine oropharyngeal classification and mandibular space length to predict difficult laryngoscopy? *ANESTHESIOLOGY* 1994; 81:69-75
35. Rocke DA, Murray WB, Rout CC, Gouws E: Relative risk analysis of factors associated with difficult intubation in obstetric anesthesia. *ANESTHESIOLOGY* 1992; 77:67-73
36. Langeron, Masso E, Huraux C, Guggiari M, Bianchi A, Coriat P, Riou B: Prediction of difficult mask ventilation. *ANESTHESIOLOGY* 2000; 92:1229-36
37. Bond A: Obesity and difficult intubation. *Anaesth Intensive Care* 1993; 21:828-30
38. Samra SK, Schork MA, Guinto FC: A study of radiologic imaging techniques and airway grading to predict a difficult endotracheal intubation. *J Clin Anesth* 1995; 7:373-9
39. Naguib M, Malabarey T, AlSatli RA, Al Damegh S, Samarkandi AH: Predictive models for difficult laryngoscopy and intubation: A clinical, radiologic and three-dimensional computer imaging study. *Can J Anaesth* 1999; 46:748-59
40. Yamamoto K, Tsubokawa T, Shibata K, Ohmura S, Nitta S, Kobayashi T: Predicting difficult intubation with indirect laryngoscopy. *ANESTHESIOLOGY* 1997; 86:316-21
41. Eckmann DM, Glassenberg R, Gavrieli N: Acoustic reflectometry and endotracheal intubation. *Anesth Analg* 1996; 83:1084-9