

Influence of Lung Aeration on Pulmonary Concentrations of Nebulized and Intravenous Amikacin in Ventilated Piglets with Severe Bronchopneumonia

Marilia Elman, M.D.,* Ivan Goldstein, M.D.,† Charles-Hugo Marquette, M.D., Ph.D.,‡ Frédéric Wallet, M.D.,§ Gilles Lenaour, Ph.D.,|| Jean-Jacques Rouby, M.D., Ph.D.,# the Experimental ICU Study Group**

Background: Pulmonary concentrations of aminoglycosides administered intravenously are usually low in the infected lung parenchyma. Nebulization represents an alternative to increase pulmonary concentrations, although the obstruction of bronchioles by purulent plugs may impair lung deposition by decreasing lung aeration.

Methods: An experimental bronchopneumonia was induced in anesthetized piglets by inoculating lower lobes with a suspension of 10^6 cfu/ml *Escherichia coli*. After 24 h of mechanical ventilation, 7 animals received two intravenous injections of 15 mg/kg amikacin, and 11 animals received two nebulizations of 40 mg/kg amikacin at 24-h intervals. One hour following the second administration, animals were killed, and multiple lung specimens were sampled for assessing amikacin pulmonary concentrations and quantifying lung aeration on histologic sections.

Results: Thirty-eight percent of the nebulized amikacin (15 mg/kg) reached the tracheobronchial tree. Amikacin pulmonary concentrations were always higher after nebulization than after intravenous administration, decreased with the extension of parenchymal infection, and were significantly influenced by lung aeration: 197 ± 165 versus 6 ± 5 $\mu\text{g/g}$ in lung segments with focal bronchopneumonia ($P = 0.03$), 40 ± 62 versus 5 ± 3 $\mu\text{g/g}$ in lung segments with confluent bronchopneumonia ($P = 0.001$), 18 ± 7 versus 7 ± 4 $\mu\text{g/g}$ in lung segments with lung aeration of 30% or less, and 65 ± 9 versus 2 ± 3 $\mu\text{g/g}$ in lung segments with lung aeration of 50% or more.

Conclusions: In a porcine model of severe bronchopneumonia, the nebulization of amikacin provided 3–30 times higher pulmonary concentrations than the intravenous administration of an equivalent dose. The greater the lung aeration, the higher were the amikacin pulmonary concentrations found in the infected lung segments.

VENTILATOR-ASSOCIATED pneumonia is the most frequent nosocomial infection in patients undergoing mechanical ventilation,¹ represents the first cause of death

from hospital-acquired infections among critically ill patients,² and can be prevented by the intratracheal administration of colistin.³ In addition, it frequently complicates the course of acute respiratory distress syndrome and prolongs the duration of mechanical ventilation.⁴ Microbiologic findings are variable, and the type of causative microorganism found is affected by the duration of mechanical ventilation.⁵ Gram-negative bacteria are responsible for 60% of ventilator-associated pneumonia,² and in patients with acute respiratory distress syndrome who are ventilated for 4 days or more, the most commonly found organisms are *Escherichia coli*, *Klebsiella* species, *Staphylococcus aureus*, *Pseudomonas aeruginosa* and *Acinetobacter* species.⁶

Intravenous aminoglycosides are frequently administered to critically ill patients to treat gram-negative bacteria lung infection complicating prolonged mechanical ventilation. It is well known that their lung deposition is limited,^{7,8} resulting in low tissue concentrations, reduced antibacterial activity, and high serum concentrations, carrying the risk of renal toxicity.⁹ The inhalation route is an alternative way of administration that may provide high pulmonary and low serum concentrations. In healthy, ventilated piglets receiving either intravenous or nebulized amikacin, pulmonary concentrations were found to be about 10 times higher in the nebulization group than in the intravenous group,¹⁰ whereas peak serum concentrations were 4 times lower. However, such high pulmonary concentrations may not be observed in animals with an experimental bronchopneumonia resulting from a direct intrabronchial inoculation. The obstruction of distal bronchioles by purulent plugs may impair lung deposition of inhaled amikacin and result in low pulmonary concentrations within the infected parenchyma. In other words, high pulmonary concentrations of amikacin found in normally aerated lung parenchyma may not be any more present in nonaerated infected lung regions. If lung deposition of nebulized aminoglycosides is correlated to the degree of lung aeration, then pulmonary concentrations should be higher in early stages of bronchopneumonia where pulmonary aeration is partially preserved than in late stages characterized by lung consolidation. Positive end-expiratory pressure by reopening some of the collapsed lung territories¹¹ should also potentiate the pulmonary deposition of nebulized antimicrobial agents.

The aim of this study was to assess the influence of lung aeration and histologic stage of lung infection on

* Research Fellow, Réanimation Chirurgicale Pierre Viars, La Pitié-Salpêtrière Hospital. Current: Department of Anesthesiology, Santa Casa de Misericórdia de São Paulo, Faculdade de Ciências Médicas da Santa Casa de São Paulo, São Paulo, Brazil. † Assistant Professor of Anesthesiology and Intensive Care, || Assistant of Pathology, # Professor of Anesthesiology and Critical Care and Director of the Surgical Intensive Care Unit, University of Paris 6. ‡ Professor of Pneumology, § Assistant Professor of Bacteriology, University of Lille. ** Members of the Experimental ICU Study Group who participated in this study are listed in the appendix.

Received from the Réanimation Chirurgicale Pierre Viars (Department of Anesthesiology) and the Department of Pathology, La Pitié-Salpêtrière Hospital, University of Paris 6, Paris, France, and Unité INSERM 416 of Institut Pasteur and Département Hospitalo-Universitaire de Recherche Expérimentale, University of Lille, Lille, France. Submitted for publication October 19, 2001. Accepted for publication February 26, 2002. Dr. Elman is the recipient of a scholarship (ref 2334471) from the Ministère Français des Affaires Étrangères, Paris, France.

Address reprint requests to Dr. Rouby: Réanimation Pierre Viars, Department of Anesthesiology, La Pitié-Salpêtrière Hospital, 47-83 boulevard de l'Hôpital, 75013 Paris, France. Address electronic mail to: jjrouby.pitie@invivo.edu. Individual article reprints may be purchased through the Journal Web site, www.anesthesiology.org.

pulmonary concentrations of amikacin administered either by nebulization or intravenously in ventilated piglets with bronchopneumonia.

Methods

The Experimental Intensive Care Unit

The study was performed in the Experimental Intensive Care Unit initiated in 1997 by the Research ICU group of La Pitié-Salpêtrière hospital (J.-J. R.) and was set up in Lille in the Département Hospitalo-Universitaire de Recherche Expérimentale (DHURE; C.-H. M.). The experimental setting was composed of two operating tables, two cardiovascular monitors and intensive care ventilators, several electrical infusers, and one recorder. A medical team composed of three physicians was on-call on a 24-h-period shift. Two technicians were present daily from 9 AM to 5 PM. Despite the cost and the difficulties of such a project, the existence of an experimental intensive care unit allowing the prolonged mechanical ventilation of large animals whose cardiorespiratory physiology is very similar to human was considered as mandatory for reproducing clinical conditions that are encountered in intensive care units.

Animal Preparation

Eighteen healthy bred domestic Largewhite-Landrace piglets, aged 3 to 4 months and weighing 20 ± 2 kg, were anesthetized using 3 mg/kg propofol and orotracheally intubated in the supine position with a 7.0 Hi-Lo Jet Mallinckrodt tube (Mallinckrodt Inc., Argyle, NY). Anesthesia was maintained with a continuous infusion of $0.3 \text{ mg} \cdot \text{kg}^{-1} \cdot \text{h}^{-1}$ midazolam, $0.3 \text{ mg} \cdot \text{kg}^{-1} \cdot \text{h}^{-1}$ pancuronium, and $5 \mu\text{g} \cdot \text{kg}^{-1} \cdot \text{h}^{-1}$ fentanyl. A catheter was inserted in the ear vein for continuous infusion of 10% dextrose ($1.5 \text{ ml} \cdot \text{kg}^{-1} \cdot \text{h}^{-1}$) and Ringer's lactate ($3 \text{ ml} \cdot \text{kg}^{-1} \cdot \text{h}^{-1}$) using an infusion pump, and the femoral artery was cannulated with a 3-French polyethylene catheter (Plastimed, St Leu la forêt, France) for pressure monitoring and blood sampling. An 8-French suprapubic urinary catheter (Vesicoset; Angiomed, Karlsruhe, Germany) was placed in the bladder transabdominally. All animals were treated according to the guidelines of the Department of Experimental Research of the Lille University and to the Guide for the Care and Use of Laboratory Animals (National Institutes of Health publication No. 93-23, revised 1985).

Respiratory Measurements

After anesthesia and technical preparation, the piglets were placed in the prone position. They were mechanically ventilated in a volume-controlled mode with a Cesar type 1 ventilator (Taema, Antony, France). The initial ventilatory parameters consisted of a tidal volume of 15 ml/kg, a respiratory rate of 15 breaths/min, an

inspiratory-to-expiratory ratio of 0.5, and zero end-expiratory pressure. Inspired gases were humidified using a conventional humidifier (MR290; Fisher & Paykel, New Zealand), and an initial fraction of inspired oxygen (FiO_2) of 0.21 was used. Airway pressure was measured at the distal tip of the Hi-Lo Jet endotracheal tube. Pressure-volume curves were performed on the Cesar ventilator after a 3-s end-expiratory pause according to a previously validated technique.¹² Blood gases were analyzed at 37°C with an ABL120 blood gas analyzer (Radiometer, Copenhagen, Denmark). All data were recorded on a strip-chart recorder (Gould ES1000; Gould Instruments, Cleveland, OH).

Bronchial Inoculation and Mechanical Ventilation

Measurements of baseline cardiorespiratory parameters at steady state were performed 1 h after anesthetic induction and orotracheal intubation. Following these measurements, a suspension of *E. coli* (biotype 54465) was selectively inoculated in lower lobes using bronchoscopy in the prone position. A volume of 40 ml containing 10^6 cfu/ml was instilled in the right and left lower lobes. The piglets were ventilated during a maximum of 3 days with a fixed tidal volume of 15 ml/kg and a variable respiratory rate adjusted initially to provide an arterial carbon dioxide tension (Paco_2) ranging between 35 and 45 mmHg before bacterial inoculation. Hemodynamic parameters, airway pressures, respiratory compliance, and blood gases were determined every hour. Throughout the protocol, zero end-expiratory pressure was maintained. FiO_2 was increased to maintain arterial oxygen tension (Pao_2) above 80 mmHg. Paco_2 was kept between 35 and 45 mmHg by increasing respiratory rate to the maximum level preceding the appearance of auto-positive end-expiratory pressure. Above this limit, hypercapnia was tolerated. Septic shock, defined as a 30% decrease in mean arterial pressure persisting despite a rapid 500-ml intravenous fluid loading, was treated by a continuous infusion of norepinephrine. In case of sudden rise in airway pressures or hemodynamic failure, pneumothorax was suspected and drained promptly.

Aerosol Generation

A commercially available Atomisor MegaHertz ultrasonic nebulizer (Diffusion Technique Française, Saint-Etienne, France), designed to produce small-size particles in standard operating conditions, was positioned in the inspiratory limb of the ventilator circuit, 40 cm proximal to the Y-piece. During nebulization, the conventional humidifier was disconnected, and the inspiratory time was set at 50%. Amikacin powder (40 mg/kg; Bristol-Myers-Squibb, La Défense, France) diluted in 12 ml saline was the daily dose administered during the study.

Aerosol granulometry was assessed using a laser particle sizer (APS 33; TSI Inc., Saint Paul, MN), which mea-

sures the aerodynamic size of single suspended particles in real time over the 0.5- to 15- μm range. The sampling rate was accelerated at 150 m/s to avoid coalescence of particles. The light scattered from the particles while crossing two laser beams was received by a photomultiplier. Aerodynamic diameter was directly related to the time between the two signals. The data were transferred to a computer for calculation of mass median aerodynamic diameter and geometric SD. Measurements were performed at three different locations within the ventilatory circuit used for the *in vivo* study: immediately proximal to the nebulizer, immediately before the Y-piece, and at the distal end of the endotracheal tube.

Nebulizer retention was defined as the mass of amikacin retained in the nebulizer, including the nebulizer chamber and the reservoir. The residual volume trapped in the reservoir was carefully measured. Circuit deposition was defined as the mass of amikacin deposited in the inspiratory limb and Y-piece and measured at the end of the experiment by washing the inspiratory circuit. Endotracheal tube deposition was measured by washing the endotracheal tube at the end of the experiment. It included particles deposited on the endotracheal tube both during inspiration and expiration. Exhalation mass was defined as the amount of drug extracted from the expiratory filter, which was opened at the end of the experiment and crushed in a fixed volume of water. This included particles expired by the animal and particles that had passed directly into the expiratory circuit. Pulmonary deposition of amikacin was then computed as the total amount of amikacin administered minus the extrapulmonary deposition.

Study Design

Twenty-four hours after the inoculation, the piglets received either a daily intravenous dose of 15 mg/kg amikacin dissolved in 50 ml saline solution and delivered in 30 min by an infusion pump ($n = 7$) or 40 mg/kg powder diluted in 12 ml saline through ultrasonic aerosolization ($n = 11$). Twenty-four hours after the first administration, a second dose of amikacin was given, and animals were sacrificed 1 h later in both groups.

Sacrifice, Lung Preparation, and Measurement of Pulmonary Concentrations of Amikacin

At the end of the experiment, the heart and lungs were exposed through a cervicothoracic incision, and exsanguination was performed through direct cardiac puncture. Five "subpleural" lung specimens, 3–4 cm^3 , were excised from the upper lobes (S2), the middle lobe (S4), the apical segment (S6), the anterior segment (S8), and the posterior segment (S10) of the lower lobes. Each specimen was cut in two parts for histologic analysis and measurement of pulmonary concentrations of amikacin and was stored at -20°C . Tissue samples were cryomixed in nitrogen, weighed (AT 200; Mettler, Columbus,

OH; precision ± 0.1 ml), and homogenized in buffer solution before assessing amikacin concentrations. Pulmonary concentrations were measured by an immunoenzymatic method with a sensitivity limit of 0.8 $\mu\text{g/g}$ (Tdx; Abbott, Abbott Park, IL).

Assessment of Lung Aeration

To quantify lung aeration, an image analyzer computerized system (Leica Q500IW; Cambridge, United Kingdom) was coupled to a high-resolution color camera (JVC KYF 3 CCD; Yokolama, Japan), and an optical microscope objective $\times 2.5$ (Leitz, Wetzlar, Germany). An interactive software program—QUIPS (Quantimet Image Processing Software, Leica Cambridge, United Kingdom)—using a computerized program specially created for this study served for detection of air space structures.

Each histologic section was analyzed on a screen of a PC connected to the optical microscope and the color camera. Each optical field was analyzed as an automatically delineated rectangular elementary unit with an area of 2.289 mm^2 . Within the elementary unit, aerated lung structures were automatically identified by a color encoding system. Air-like structures, such as pulmonary vessels and interlobular septa, were visually detected and manually deselected to include as lung aeration alveolar and bronchial air-filled structures only. Lung aeration of the elementary unit expressed as a percentage was computed as the area of alveolar and bronchial air-filled structures divided by the difference between 2.289 mm^2 and the area of air-like structures. An example of different lung aerations is shown in figure 1. For a given histologic section, representative of a lung segment in a given animal, lung aeration was computed as the mean lung aeration of all elementary units present in the histologic section. Overlapping between different elementary units when changing the optical field was visually avoided by referring to histologic hallmarks.

Histologic Classification

Lung samples were processed for routine histologic preparation and embedded in paraffin. Sections of 4- μm thickness were cut by block and stained with hematoxylin-eosin. Bronchopneumonic lesions were assessed on each secondary pulmonary lobule present in a given histologic section and classified into five different categories as previously described^{13,14}: (1) Bronchiolitis was defined as the proliferation of polymorphonuclear leukocytes within the bronchial lumen leading to the formation of purulent plugs associated with necrosis and disruption of bronchial mucosa. (2) Interstitial bronchopneumonia was defined as the presence of scattered neutrophilic infiltrates localized to alveolar septa and terminal bronchioles. (3) Focal bronchopneumonia was defined as an intense proliferation of polymorphonuclear leukocytes localized to terminal bronchioles and

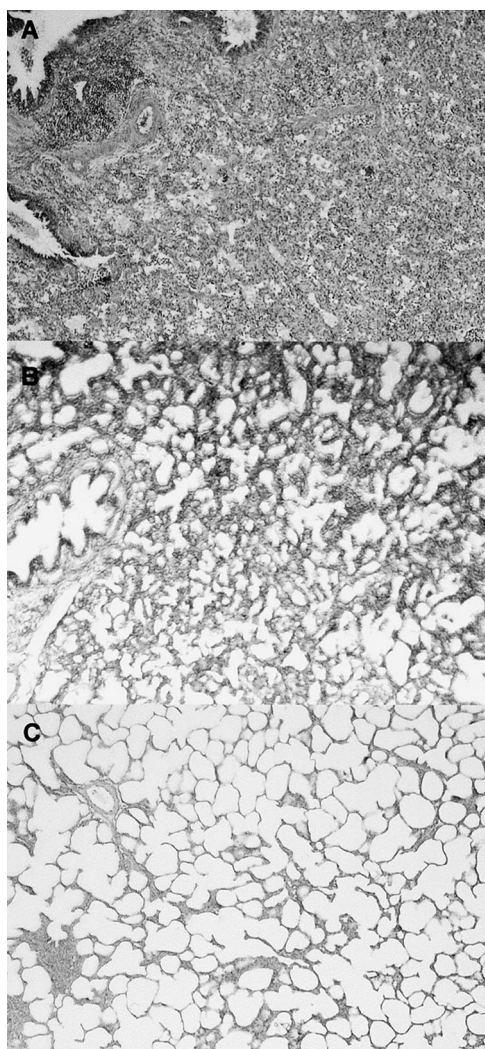


Fig. 1. Histologic sections representative of different lung aerations (magnification $\times 10$). (A) Histologic section with an aeration of 1.5%. (B) Histologic section with an aeration of 40%. (C) Histologic section with an aeration of 65%.

surrounding alveoli. (4) Confluent bronchopneumonia was defined as an extension of these elementary lesions to one or several adjacent pulmonary lobules. (5) Purulent bronchopneumonia was defined as confluent bronchopneumonia associated with tissue necrosis and disruption of normal lung architecture. Classification of a given pulmonary lobule was based on the worst category observed. Final classification of a lung segment was defined as the most frequently observed lesion in all secondary pulmonary lobules present in the histologic sections cut from the tissue block representative of the lung segment.

Statistical Analysis

All data are expressed as mean \pm SD. Amikacin pulmonary concentrations according to lung aeration were analyzed using a one-way analysis of variance followed by a protected least significant difference Fisher exact

test. Amikacin pulmonary concentrations according to lung aeration and mode of administration were analyzed using a two-way analysis of variance for two grouping factors (lung aeration and mode of administration). Amikacin pulmonary concentrations according to the histologic stage of bronchopneumonia were analyzed using a Mann-Whitney test. Pulmonary aeration characterizing the different lung segments of the nebulization group was compared with lung aeration characterizing the different lung segments of the intravenous group using a nonpaired bilateral Student *t* test after verification by a Kolmogorov-Smirnov test that the distribution of segmental aeration was normal. Statistical analysis was performed using Statview 5.2 (SAS Institute Inc., Cary, NC). The level of statistical significance was set at $P \geq 0.05$.

Results

Duration of mechanical ventilation for inoculated animals was 50 h in both groups: 1 h from anesthetic induction to bacterial inoculation, 24 h from bacterial inoculation to the first amikacin administration, and 25 h from the first amikacin administration to sacrifice.

Measurement of Aerosol Granulometry and Extrapulmonary Deposition

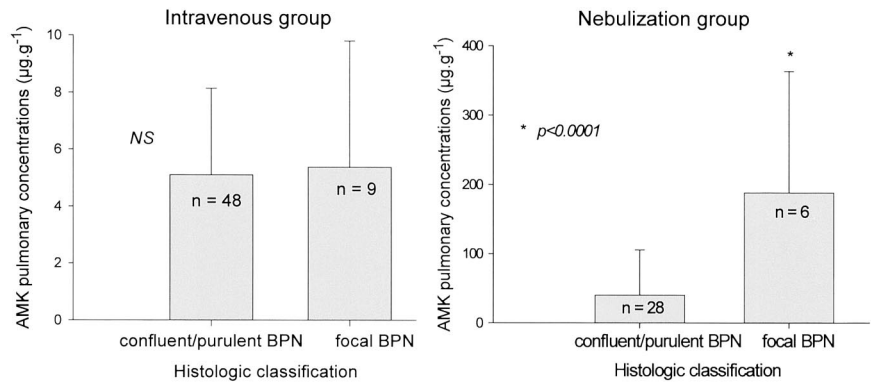
In vitro measurements of the particle sizes at the outlet of the nebulizer, close to the Y-piece, and at the distal end of the endotracheal tube were respectively 4.2 ± 0.2 , 3.8 ± 0.3 , and $3.4 \pm 0.2 \mu\text{m}$ (mean \pm SD). The fraction of particles between 0.5 and $5 \mu\text{m}$ ranged from 45 to 50% at the distal tip of the endotracheal tube. No coalescence between particles was observed.

Of the initial amount of amikacin placed in the nebulizer, $22 \pm 6\%$ was retained in the nebulizer chamber and reservoir, $18 \pm 8\%$ was fixed to the inspiratory limb of the respiratory circuits, $4 \pm 2\%$ was fixed to the endotracheal tube, and $18 \pm 7\%$ was retained in the expiratory filter. Nebulization was completed in 20 min. The concentration of amikacin was higher in the residual than in the initial solution (120 vs. 83 mg/ml).

Macroscopic and Histologic Findings

Fifty-seven lung segments were analyzed in the nebulization group, and 35 were analyzed in the intravenous group. Microscopically, lung infection was detected in all lung segments examined. In both groups, severe stages of bronchopneumonia (confluent and purulent bronchopneumonia) were largely predominant: 85% of the lung segments in the nebulization group versus 80% in the intravenous group (NS). Less severe forms of bronchopneumonia (bronchiolitis, interstitial bronchopneumonia, and foci of bronchopneumonia) were observed in 15% of the lung segments examined in the nebulization group and in 20% of the lung segments

Fig. 2. Amikacin (AMK) pulmonary concentrations according to histologic stage of bronchopneumonia in intravenous and nebulization groups. Data are mean \pm SD; n indicates the number of lung segments analyzed.



examined in the intravenous group (NS). Lung aeration was greater in the nebulization group, although the difference did not reach statistical significance: 42 versus 32% ($P = 0.08$).

Pulmonary Concentrations of Amikacin

For a given histologic stage and lung aeration, pulmonary concentrations of amikacin were always significantly higher in the nebulization group than in the intravenous group.

As shown in figure 2, pulmonary concentrations of amikacin in lung segments with focal bronchopneumonia were $197 \pm 165 \mu\text{g/g}$ in the inhalation group and $6 \pm 5 \mu\text{g/g}$ in the intravenous group ($P = 0.03$). Pulmonary concentrations of amikacin in the lung segments with more severe forms of bronchopneumonia (confluent and purulent bronchopneumonia) were $40 \pm 62 \mu\text{g/g}$ in the inhalation group and $5 \pm 3 \mu\text{g/g}$ in the intravenous group ($P < 0.001$). In the inhalation group, pulmonary concentrations of amikacin in lung segments with the most severe stages of bronchopneumonia were significantly lower than in lung segments with less severe forms of bronchopneumonia ($P < 0.01$). This difference was not observed in the intravenous group.

As shown in figure 3, in the inhalation group, pulmonary concentrations of amikacin significantly increased with lung aeration of pulmonary segments: $18 \pm 7 \mu\text{g/g}$ for lung segments with lung aeration of 30% or less, $40 \pm 7 \mu\text{g/g}$ for lung segments with aeration ranging between 30 and 50%, and $65 \pm 9 \mu\text{g/g}$ for lung segments with aeration of 50% or more ($P < 0.001$). In contrast,

pulmonary concentration of amikacin significantly decreased with lung aeration of pulmonary segments in the intravenous group: $7 \pm 4 \mu\text{g/g}$ for lung segments with lung aeration of 30% or less, $4 \pm 2 \mu\text{g/g}$ for lung segments with aeration ranging between 30 and 50%, and $2 \pm 3 \mu\text{g/g}$ for lung segments with aeration of 50% or more ($P < 0.01$).

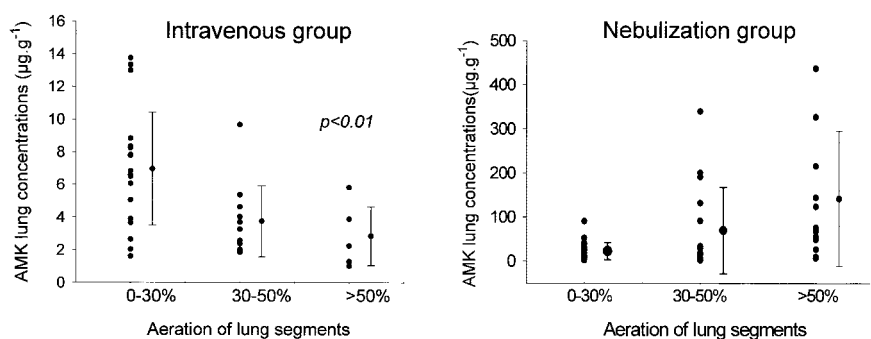
Discussion

In piglets mechanically ventilated for 48 h, because of a severe *E. coli* bronchopneumonia, the intratracheal nebulization of amikacin resulted in much higher pulmonary concentrations than the intravenous administration of an equivalent dose. Following intratracheal nebulization, amikacin pulmonary concentrations demonstrated marked regional variations ranging between 3 and 438 $\mu\text{g/g}$. In fact, amikacin pulmonary concentrations increased with lung aeration and decreased with severity of lung infection. Following intravenous injection, amikacin pulmonary concentrations were more uniform, ranging between 1 and 14 $\mu\text{g/g}$ and were influenced by lung aeration in the opposite direction: the greater the lung aeration, the lower the pulmonary concentrations.

Influence of the Mode of Administration on Amikacin Pulmonary Concentrations

In the present study, nebulized and intravenous doses were calculated to deliver comparable amounts of amikacin to the respiratory tract. Of the 40 mg/kg amikacin initially placed into the nebulizer chamber, 62% was

Fig. 3. Amikacin (AMK) pulmonary concentrations according to aeration of lung segments in intravenous and nebulization groups (each dot represents a single lung segment).



deposited in the ventilatory circuits, and 38%—the equivalent of 15 mg/kg—entered the tracheobronchial tree. To obtain such a high lung deposition, optimization of the nebulizing system was essential. During inhalation therapy, several factors, which were all present in our study, are of critical importance to augment lung deposition: (1) the use of an ultrasonic nebulizer providing particles with an internal diameter less than 5 μm ; (2) the use of a large-volume fill nebulizer with a nebulizer retention of less than 25%;¹⁵ (3) the use of an inspiratory time of 50% together with the interruption of the conventional humidifier;¹⁶ (4) the serial insertion of the nebulizer into the respiratory limb 40 cm before the Y-piece, allowing flushing into the airways of an aerosol bolus at each inspiratory phase.

Following intravenous injection, the total amount of amikacin corresponding to a dose of 15 mg/kg reached the lung *via* pulmonary circulation. However, the first passage into the lungs was likely too short to allow a substantial pulmonary absorption. Amikacin was then dispersed in the different regional circulations where tissue absorption occurred because of a much longer transit time. As previously demonstrated,¹⁰ during the following lung passages, plasma concentrations decreased according to a biexponential decay resulting from amikacin extrapulmonary absorption. Because of the resulting decrease in the blood-tissue gradient, pulmonary absorption was likely less and less effective. In other words, following the intravenous administration of amikacin, the compartments of distribution were essentially extrapulmonary. This markedly contrasts with what happened following amikacin nebulization. According to the 62% deposition in the respiratory circuits, the initial 40 mg/kg put into the nebulizer chamber corresponded to 15 mg/kg of amikacin actually delivered to the tracheobronchial tree. The amikacin penetrated more or less distally depending on the size of the particles composing the aerosol generated by the ultrasonic nebulizer. However, once delivered into the tracheobronchial tree, amikacin remained intrapulmonary for the most part, a small diffusion within the blood compartment occurring with time.¹⁰ In other words, following the nebulization of amikacin, the compartment of distribution was essentially pulmonary, likely allowing a substantial time-dependent diffusion into the infected lung parenchyma.

Pathophysiologic Parameters Influencing Amikacin Pulmonary Concentrations

A critical parameter that influences amikacin pulmonary concentrations is its diffusion through physiologic barriers, such as bronchial epithelium and vascular endothelium. Normally, these tissue barriers offer a high resistance to lung penetration of amikacin as attested to by the rather small systemic diffusion of nebulized amikacin and the weak lung deposition of

intravenous amikacin in piglets with normal lungs.¹⁰ However, antibiotics may be actively transported to the site of infection by inflammatory cells, like polymorphonuclear leukocytes.¹⁷ In addition, fever may increase the pulmonary concentrations by producing local vasodilatation secondary to the increase in regional temperature.¹⁸

Nebulized amikacin may directly penetrate the alveolar space *via* open distal bronchioles if aerosolized particles are small enough to reach the distal tracheobronchial tree. This direct access to the lung parenchyma likely explains why very high pulmonary concentrations were measured in healthy piglets in comparison to the intravenous administration.¹⁰ It also explains why pulmonary concentrations of amikacin tend to decrease proportionally to the lung aeration. Experimental bronchopneumonia produced by a direct bronchial inoculation and ventilator-associated pneumonia observed in mechanically ventilated patients are both characterized by multiple purulent plugs obstructing distal bronchioles.^{13,14,19} Lung aeration decreases with the extension and the severity of bronchopneumonia, and the direct access to the infected lung parenchyma is reduced proportionally to bronchiolar obstruction. It is therefore easy to understand why amikacin pulmonary concentrations found in the present study decreased with the lung aeration and the severity of lung infection.

The same mode of reasoning can be applied to understand lung deposition following the intravenous administration of amikacin. In patients or animals with normal lungs, the alveolar epithelium and the vascular endothelium prevent lung penetration of the drug, and, as previously shown in healthy piglets,¹⁰ lung deposition of intravenous amikacin is weak. Lung infection, as any type of lung injury, results in disruption of the alveolar-capillary membrane, which may promote amikacin lung deposition.²⁰ The degree of alveolar-capillary membrane alteration is linked to the loss of lung aeration: infected lung segments at an early stage remain partially aerated with minimum alterations of the alveolar-capillary membrane, whereas more severe forms of lung infection are characterized by a quasi-complete disappearance of the lung aeration. Very likely, the massive disruption of the alveolar-capillary membrane that results in lung consolidation allows an increased lung penetration of amikacin. Such a mechanism has been documented concerning the pulmonary penetration of vancomycin in human bronchopneumonia²⁰ and the diffusion of antibiotics into the cerebrospinal fluid of patients with meningitis. Although the penetration of most antibiotics across the normal blood-brain barrier is quite low,²¹ an inflammation of the hematoencephalic barrier potentiates the diffusion into the subarachnoid space. It should be pointed out that despite the increased permeability of the alveolar-capillary barrier that tends to

promote lung deposition, pulmonary amikacin concentrations remained hopelessly low after the intravenous injection. One explicative mechanism could be that lung perfusion is seriously compromised in acute respiratory distress syndrome. The presence of multiple and disseminated pulmonary thrombosis and the marked reduction of the pulmonary vascular bed are characteristic features of all forms of acute lung injury.²² Such pathologic vascular disorders certainly represent serious impediment for the pulmonary disposition of intravenous amikacin. In addition, the rapid formation of pseudocysts in nonaerated lung regions by compressing pulmonary vessels may also contribute to impair pulmonary blood flow and limit amikacin pulmonary deposition.²³

An Experimental and Clinical Research Program on Nebulized Antibiotics

The present study is a part of an extended experimental and clinical research program initiated 4 yr ago that is aimed at assessing the efficiency of nebulized antibiotics for treating human ventilator-associated bronchopneumonia. Before treating humans with nebulized antibiotics, we felt that it was necessary to perform experimental studies in piglets on long-term mechanical ventilation with healthy or bronchopneumonic lungs. The initial obligatory step was to set up an experimental intensive care unit allowing the long-term mechanical ventilation of large animals.²³

The first set of experiments was then performed in piglets with healthy lungs on prolonged mechanical ventilation. Amikacin lung tissue concentrations were found to be much higher after nebulization than after intravenous administration.¹⁰ In a second study that is not yet published, we assessed the interval of time between each nebulization required for providing high lung tissue concentrations without producing plasma accumulation over a 4-day period of mechanical ventilation. A second set of experiments was performed in mechanically ventilated piglets with experimental bronchopneumonia caused by the intrabronchial inoculation of *E. coli*. The present study, which is the first part of these experiments, shows that despite the massive loss of lung aeration resulting from lung infection, amikacin concentrations measured in the infected lung parenchyma remain significantly higher after nebulization than after intravenous administration. In a subsequent study performed in the same experimental model, we demonstrated that such high amikacin lung tissue concentrations are associated with a greater bactericidal efficiency: more than 60% of the lung specimens cultured were sterile after 24 h of nebulized amikacin *versus* 18% after 24 h of intravenous amikacin.²⁴ A third set of experiments is aimed at assessing lung tissue and plasma concentrations and the bactericidal efficiency of nebulized *versus* intravenous ceftazidime in an experimental bronchopneumo-

nia caused by the intrabronchial inoculation of *P. aeruginosa* resistant to ticarcillin.

When all these experiments are completed, including the assessment of plasma pharmacokinetics of nebulized *versus* intravenous amikacin and ceftazidime, and if the beneficial effects of nebulized antibiotics are confirmed, then a randomized controlled study will be set up in critically ill patients with ventilator-associated bronchopneumonia to assess the comparative therapeutic efficiency of nebulized and intravenous antibiotics.

References

1. Rouby JJ: Nosocomial infection in the critically ill: The lung as a target organ. *ANESTHESIOLOGY* 1996; 84:757-9
2. Vincent JL, Bihari DJ, Suter PM, Bruining HA, White J, Nicolas-Chanoine MH, Wolff M, Spencer RC, Hemmer M: The prevalence of nosocomial infection in intensive care units in Europe: Results of the European Prevalence of Infection in Intensive Care (EPIC) Study. EPIC International Advisory Committee. *JAMA* 1995; 274:639-44
3. Rouby JJ, Poëte P, Martin de Lassale E, Nicolas MH, Bodin L, Jarlier V, Korinek AM, Viars P: Prevention of Gram negative nosocomial bronchopneumonia by intratracheal colistin in critically ill patients: Histologic and bacteriologic study. *Intensive Care Med* 1994; 20:187-92
4. Marcowicz P, Wolff M, Djedaïni K, Cohen Y, Chastre J, Delclaux C, Merrer J, Herman B, Veber B, Fontaine A, Dreyfuss D: Multicenter prospective study of ventilator-associated pneumonia during acute respiratory distress syndrome. *Am J Respir Crit Care Med* 2000; 161:1942-8
5. Bauer TT, Torres A: Acute respiratory distress syndrome and nosocomial pneumonia. *Thorax* 1999; 54:1036-40
6. Kollef MH, Silver P, Murphy DM, Trovillion E: The effect of late-onset ventilator-associated pneumonia in determining patient mortality. *Chest* 1995; 108:1655-62
7. Mendelman PM, Smith AL, Levy J, Weber A, Ramsey B, Davis RL: Aminoglycoside penetration, inactivation, and efficacy in cystic fibrosis sputum. *Am Rev Respir Dis* 1985; 132:761-5
8. Pennington JE: Penetration of antibiotics into respiratory secretions. *Rev Infect Dis* 1981; 3:67-73
9. Mingeot-Leclercq MP, Tulkens PM: Aminoglycosides: Nephrotoxicity. *Antimicrob Agents Chemother* 1999; 43:1003-12
10. Goldstein I, Waller F, Robert J, Becquemin MH, Marquette CH, Rouby JJ, Experimental ICU Study Group: Lung tissue concentrations of nebulized amikacin during mechanical ventilation in piglets with healthy lungs. *Am J Respir Crit Care Med* 2002; 165:171-5
11. Malbouisson LM, Muller JC, Constantin JM, Lu Q, Puybasset L, Rouby JJ: Computed tomography assessment of positive end-expiratory pressure-induced alveolar recruitment in patients with acute respiratory distress syndrome. *Am J Respir Crit Care Med* 2001; 163:1444-50
12. Lu Q, Viera S, Richecoeur J, Puybasset L, Kalfon P, Coriat P, Rouby J: A simple automated method for measuring pressure-volume curves during mechanical ventilation. *Am J Respir Crit Care Med* 1999; 159:275-82
13. Rouby JJ, Martin De Lassale E, Poëte P, Nicolas MH, Bodin L, Jarlier V, Le Charpentier Y, Grosset J, Viars P: Nosocomial bronchopneumonia in the critically ill: Histologic and bacteriologic aspects. *Am Rev Respir Dis* 1992; 146:1059-66
14. Fabregas N, Torres A, El-Ebiary M, Ramirez J, Hernandez C, Gonzalez J, de la Bellacasa JP, de Anta J, Rodriguez-Roisin R: Histopathologic and microbiologic aspects of ventilator-associated pneumonia. *ANESTHESIOLOGY* 1996; 84:760-71
15. Thomas SH, O'Doherty MJ, Page CJ, Treacher DF, Numan TO: Delivery of ultrasonic nebulized aerosols to a lung model during mechanical ventilation. *Am Rev Respir Dis* 1993; 148:872-7
16. O'Riordan TG, Greco MJ, Perry RJ, Smaldone GC: Nebulizer function during mechanical ventilation. *Am Rev Respir Dis* 1992; 145:1117-22
17. Vallee E, Azoulay-Dupuis E, Pocard JJ, Bergogne-Berezin E: Activity and local delivery of azithromycin in a mouse model of *Haemophilus influenzae* lung infection. *Antimicrob Agents Chemother* 1992; 36:1412-7
18. Wiedemann GJ, Siemens HJ, Mentzel M, Biersack A, Wossmann W, Knocks D, Weiss C, Wagner T: Effects of temperature on the therapeutic efficacy and pharmacokinetics of ifosfamide. *Cancer Res* 1993; 53:4268-72
19. Rouby JJ, Rossignon MD, Nicolas MH, Martin de Lassale E, Cristin S, Grosset J, Viars P: A prospective study of protected bronchoalveolar lavage in the diagnosis of nosocomial pneumonia. *ANESTHESIOLOGY* 1989; 71:679-85
20. Lamer C, de Beco V, Soler P, Calvat S, Fagon JY, Dombret MC, Farinotti R, Chastre J, Gibert C: Analysis of vancomycin entry into pulmonary lining fluid by

bronchoalveolar lavage in critically ill patients. *Antimicrob Agents Chemother* 1993; 37:281-6

21. Lutsar I, Friedland IR: Pharmacokinetics and pharmacodynamics of cephalosporins in cerebrospinal fluid. *Clin Pharmacokinet* 2000; 39: 335-43

22. Tomaszewski JF Jr, Davies P, Boggis C, Greene R, Zapol WM, Reid LM: The pulmonary vascular lesions of the adult respiratory distress syndrome. *Am J Pathol* 1983; 112:112-26

23. Goldstein I, Bughalo MT, Marquette CH, Lenaour G, Lu Q, Rouby JJ: Mechanical ventilation-induced air-space enlargement during experimental pneumonia in piglets. *Am J Respir Crit Care Med* 2001; 163: 958-64

24. Goldstein I, Wallet F, Nicolas-Robin A, Elman M, Marquette CH, Rouby JJ: Diffusion pulmonaire et efficacité de l'Amikacine administrée par inhalation au cours d'une bronchopneumonie expérimentale chez le porc ventilé (abstract). *Ann Fr Anesth Reanim* 2001; 20(suppl 1):46

Appendix

The following members of the Experimental ICU Study Group participated in this study: Ania Nieszkowska, M.D. (Research Fellow, Réanimation Chirurgicale Pierre Viars, Paris, France); Armelle Nicolas Robin, M.D. (Assistant Professor of Anesthesiology and Critical Care, Réanimation Chirurgicale Pierre Viars); Qin Lu, M.D. (Research Attendant, Réanimation Chirurgicale Pierre Viars); Pierre Coriat, M.D. (Professor of Anesthesiology and Intensive Care, Chairman, Department of Anesthesiology, Pitié-Salpêtrière Hospital, Paris, France); and Jean-François Finet, M.D. (Assistant Professor of Pathology, Department of Pathology, Pitié-Salpêtrière Hospital).