

Skin Injury with the Use of a Water Warming Device

Bhargavi Gali, M.D.,*† James Y. Findlay, F.R.C.A.,‡§ David J. Plevak, M.D.¶§

HYPOTHERMIA is common during extensive and prolonged surgery such as a liver transplantation (OLT). Hypothermia can cause or exacerbate preexisting coagulation abnormalities and myocardial dysfunction.^{1,2} Efforts to prevent hypothermia during OLT and other major operations have largely employed active warming devices utilizing forced-air warming. A new device, the Allon System with the ThermoWrap garment (MTRE Advanced Technologies Ltd., Centerville, OH), circulates warmed water through a special garment to prevent hypothermia. We report the case of pressure/burn injury secondary to the use of this device.

Case Report

A 67-yr-old woman with end-stage liver disease secondary to primary biliary cirrhosis presented to the operating room for OLT. Preoperative dietary assessment had noted significant muscle wasting and a poor nutritional status. Laboratory analysis revealed a serum albumin level of 2.9 g/dl (normal range, 3.4-4.8 g/dl). The patient's skin was noted to be intact at her admission physical examination.

In the operating room, the patient was placed on a prewarmed ThermoWrap garment (MTRE Advanced Technologies Ltd.) per the manufacturer's directions and under the supervision of a MTRE representative. Before it was used, the ThermoWrap garment was checked by the institutional bioengineering department and was approved for operating room use. General anesthesia was induced, with fentanyl, midazolam, propofol, and succinylcholine. After induction, the usual percutaneous catheters were placed for the surgery. The warming blanket was then wrapped around the the patient's legs with the adjustable Velcro. The ThermoWrap garment is designed to cover the legs, torso, and arms with the use of Velcro attachments. Because of the nature of the surgical procedure, the arms and torso were not wrapped. The temperature sensor for the warming system was placed in the esophagus. Surgery then proceeded. The intraoperative course was unremarkable, with a time of 6.5 h in the operating room. There were approximately 15 min of hypotension during the procedure (defined as less than 70% baseline systolic pressure). There was no evidence of warmer malfunction. The patient's temperature was 36.3°C at the end of the case. The patient was then transferred to the cart without the warming garment and taken to the intensive care unit for postoperative care, where she was extubated 8 h later. The next day, the patient reported back pain in both the thoracic and sacral areas. Examination revealed a several-centimeter area over the mid-sacrum and a similarly sized area on the mid-upper thorax, which was

erythematous and blistered in the pattern of the warming blanket and consistent with second-degree burns in the opinion of the attending surgeon (figs. 1 and 2). These and the associated pain resolved over the next few days, and she was discharged on postoperative day 9. The patient visited the transplant clinic on postoperative days 12 and 20; examination during both visits revealed continued appropriate healing of the affected areas.

Discussion

The Food and Drug Administration-approved Allon System employs the ThermoWrap blanket, body temperature sensors, and a microprocessor that controls the heating unit. The ThermoWrap garment can be wrapped around the extremities and torso, thus allowing for a

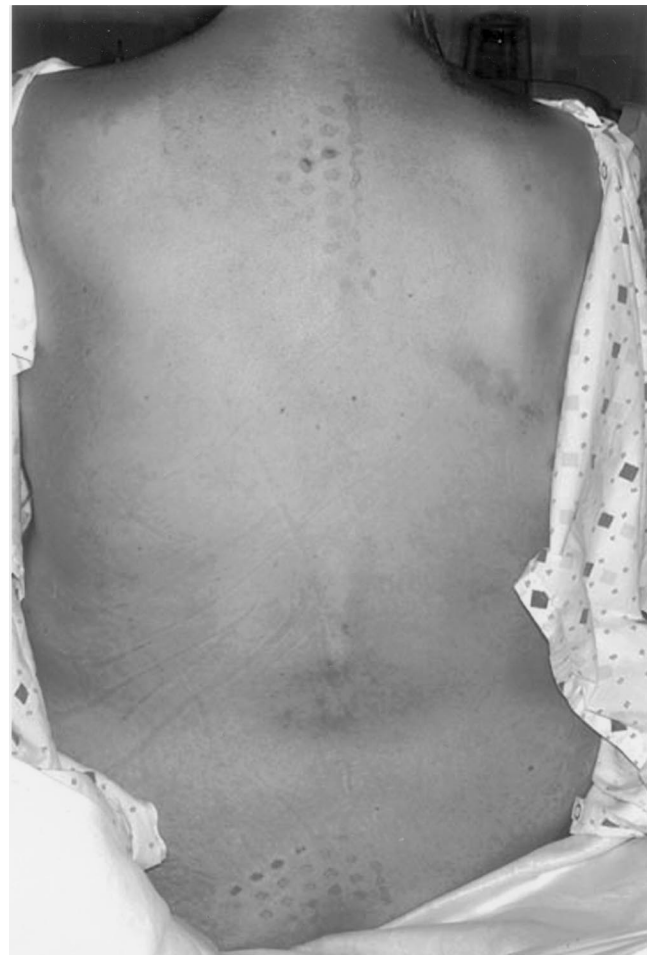


Fig. 1. Photograph showing skin injury at the mid-sacrum and mid-upper thorax.

greater surface area for heat transfer and more efficient

* Instructor of Anesthesiology, † Assistant Professor of Anesthesiology, ‡ Professor of Anesthesiology, Mayo Medical School; † Senior Associate Consultant, § Consultant, Department of Anesthesiology, Mayo Clinic, Rochester, Minnesota.

Received from the Department of Anesthesiology, Mayo Clinic, Rochester, Minnesota. Submitted for publication June 18, 2002. Accepted for publication September 25, 2002. Support was provided solely from institutional and/or departmental sources.

Address reprint requests to Dr. Gali: Department of Anesthesiology, Mayo Clinic, 200 First Street SW, Rochester, Minnesota 55905. Address electronic mail to: gali.bhargavi@mayo.edu. Individual article reprints may be purchased through the Journal Web site, www.anesthesiology.org.

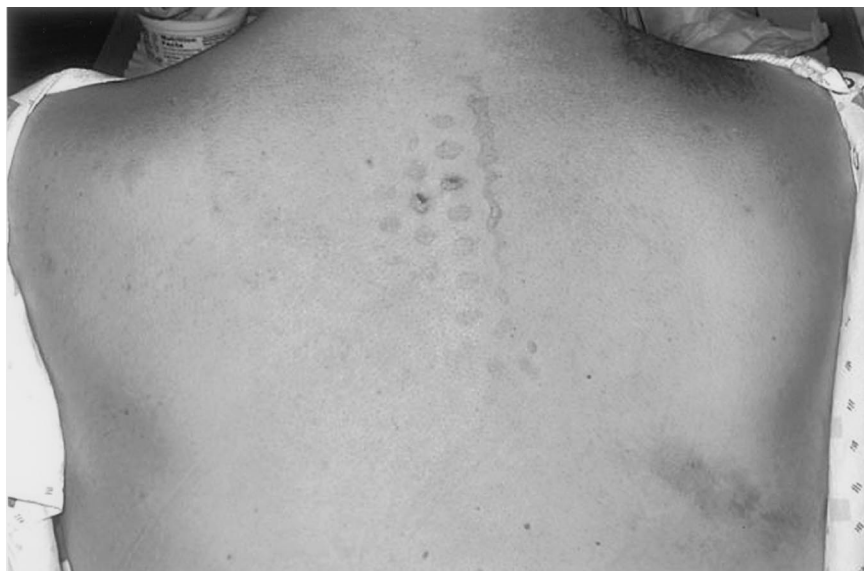

Fig. 2. Photograph showing mid-upper thorax skin injury.

temperature regulation. The ThermoWrap blanket is filled with water; temperature is regulated *via* a micro-processor that receives feedback from up to three temperature sensors. The sensors can be utilized to measure rectal, esophageal, and skin temperatures. Feedback from the sensors adjusts the temperature of the water circulating through the garment.

The warmed, circulating water has been used to maintain body temperature intraoperatively in both children and adults.^{3,4} A small study in patients undergoing OLT found this technology to be safe and effective in maintaining core temperature.⁵ To date there have been no previous reports of injury associated with the use of warmed circulating water technology. Our patient had several risk factors that may have predisposed her to skin injury, including age, poor nutritional status, low serum albumin level, and prolonged surgery^{6,7}; however, these characteristics are not infrequent in patients who undergo OLT or other major surgical procedures. Whether the injury was primarily due to pressure, heat, or a combination of these two factors is difficult to discern. Because the patient complained of burning pain on her back soon after she was able to effectively communicate with her caregivers, the primary injury was most likely a

burn. MTRE Advanced Technologies Ltd. was notified of this patient-related injury.

Despite the existence of some data affirming its effectiveness, clinicians planning to use the Allon System or any system that employs circulating warmed fluid for prolonged procedures should first consider this potential risk.

References

1. Rohrer MJ, Natale AM: Effect of hypothermia on the coagulation cascade. *Crit Care Med* 1992; 20:1402-5
2. Greene PS, Cameron DE, Mohlala ML, Dinatale JM, Gardner TJ: Systolic and diastolic left ventricular dysfunction due to mild hypothermia. *Circulation* 1989; 80(5 Pt 2):III44-8
3. Neshor N, Wolf T, Uretzky G, Oppenheim-Eden A, Yussim E, Kushnir I, Shoshany G, Rosenberg B, Berant M: A novel thermoregulatory system maintains perioperative normothermia in children undergoing elective surgery. *Paediatr Anaesth* 2001; 11:555-60
4. Janicki PK, Higgins MS, Janssen J, Johnson RF, Beattie C: Comparison of two different temperature maintenance strategies during open abdominal surgery: upper body forced-air warming versus whole body water garment. *ANESTHESIOLOGY* 2001; 95:868-74
5. Janicki PK, Higgins MS, Stoica C, Pai R, Walia A: Comparison of water warming garment and air warming system in prevention of hypothermia during liver transplantation. *ANESTHESIOLOGY* 2000; 93:A-385
6. Stewart TP, Magnano SJ: Burns or pressure ulcers in the surgical patient? *Decubitus* 1988; 1:36-40
7. Kemp MG, Keithley JK, Smith DW, Morreale B: Factors that contribute to pressure sores in surgical patients. *Res Nurs Health* 1990; 13:293-301

Probable Meperidine-Induced Serotonin Syndrome in a Patient with a History of Fluoxetine Use

Todd A. Tissot, M.D.*

SEROTONIN syndrome is a condition that can result when drugs capable of increasing central nervous system serotonin neurotransmission are administered. Although it rarely occurs with monotherapy, serotonin syndrome is far more likely to occur when multiple drugs that can increase serotonin levels are administered concomitantly. In particular, the combination of selective serotonin reuptake inhibitors and other agents capable of increasing serotonin activity (e.g., monoamine oxidase inhibitors) has been most commonly associated with the syndrome.

The potential for serotonin syndrome to develop in patients receiving monoamine oxidase inhibitors who are exposed to meperidine is well known to most anesthesiologists. This report describes a case of probable serotonin syndrome in a patient who had been taking a selective serotonin reuptake inhibitor and was subsequently given meperidine, an interaction that has not been widely recognized.

Case Report

A 43-yr-old man, American Society of Anesthesiologists physical status II (height 171 cm, weight 71 kg), presented for endoscopic retrograde cholangiopancreatography to evaluate chronic and recurrent episodes of pancreatitis. The patient had a history of type 2 diabetes mellitus and dyslipidemia. The only medications that he was taking at the time of the procedure were rosiglitazone and fenofibrate. He had undergone endoscopic retrograde cholangiopancreatography several months earlier and was given meperidine and midazolam without incident. The patient had no known drug allergies or intolerances.

At arrival in the endoscopy suite, the patient's systolic/diastolic blood pressure was 130/75 mmHg, his pulse rate was 80 beats/min, and oxygen saturation was 100% on 4 l/min nasal oxygen. Midazolam (2 mg) was administered intravenously with minimal sedation noted, and 50 mg meperidine was subsequently administered intravenously. The patient immediately became agitated and restless. Although he remained conscious, the patient was too confused to follow verbal commands. Systolic/diastolic blood pressure rose to 180/100 mmHg, heart rate rose to 130 beats/min, and oxygen saturation declined to 95%. No specific treatment was given for hypertension and tachycardia because the patient removed the iv catheter in his confused state. An

iv catheter was reinserted, at which time the patient was noted to be extremely diaphoretic, with widely dilated pupils.

After approximately 10 min, his systolic/diastolic blood pressure declined to 90/45 mmHg, heart rate slowed to 120 beats/min, and oxygen saturation remained at 95%. The patient stated that he needed to move his bowels and had an episode of diarrhea. After approximately another 10 min, his agitation subsided but he remained sleepy and confused. Systolic/diastolic blood pressure returned to approximately 120/70 mmHg, heart rate declined to 105 beats/min over a period of approximately 15 min, and oxygen saturation remained at 95%. The endoscopic procedure was canceled, and the patient was taken to the recovery room.

In the recovery room, the patient's temperature was noted to be 98.4°F orally, systolic/diastolic blood pressure was 108/84 mmHg, heart rate was 99 beats/min, and oxygen saturation was 96% on nasal oxygen. The sensorium appeared to clear after the subsequent 60- to 90-min period, and diaphoresis resolved. Reflex changes in the lower extremities were not sought. An electrocardiogram demonstrated a sinus rhythm with nonspecific repolarization changes. The patient had a single episode of nausea and vomiting approximately 2 h after the procedure; this was managed with iv ondansetron.

Initially, the patient denied taking any antidepressants. In the absence of a history of exposure to drugs other than meperidine that might precipitate serotonin syndrome, and because his confusion and autonomic lability had resolved, treatment with cyproheptadine was not initiated. The patient remained afebrile with stable vital signs over the next 24 h, and serial creatine kinase and creatine kinase MB measurements were unremarkable. Several episodes of abdominal pain reminiscent of the pain he had experienced with pancreatitis were treated with iv administration of hydromorphone without adverse reaction, and the patient was discharged home the next day.

The patient presented again several weeks later for endoscopy, at which time his medication history was again reviewed. He subsequently confirmed that he had been taking fluoxetine approximately every other day, but had not taken the medication for approximately 2 weeks before the procedure. The patient had not been taking fluoxetine several months earlier when he had an uneventful exposure to meperidine. He subsequently underwent an uneventful endoscopy utilizing fentanyl, midazolam, and propofol for sedation.

Discussion

Although well recognized in the emergency medicine, neurology, and psychiatry literature, relatively little information regarding serotonin syndrome has appeared in the anesthesiology literature. In its typical form, the syndrome is characterized by abnormal functioning in each of the following three areas: (1) autonomic instability (hypertension, hypotension, sweating, pupillary dilatation, fever, diarrhea), (2) behavioral changes (confusion, agitation, lethargy), and (3) neuromuscular changes (hyperreflexia, myoclonus, and rigidity). Neuromuscular changes are usually most marked in the lower extremities. In severe instances, coma, seizures, coagulopathy, and metabolic acidosis may develop. The severity of

* Attending Anesthesiologist, Department of Anesthesia, Beth Israel Medical Center (Singer Division), New York, New York.

Received from the Department of Anesthesia, Beth Israel Hospital (Singer Division), New York, New York. Submitted for publication September 4, 2002. Accepted for publication February 11, 2003. Support was provided solely from institutional and/or departmental sources.

Address reprint requests to Dr. Tissot: Department of Anesthesia, Beth Israel Medical Center (Singer Division), New York, New York 10128. Address electronic mail to: toddtissot@yahoo.com. Individual article reprints may be purchased through the Journal Web site, www.anesthesiology.org.

the syndrome may vary markedly, and symptoms from one or two categories often predominate. Many episodes, as in the case reported here, are relatively mild.^{1,2}

Some of the symptoms that developed in this patient, such as nausea and somnolence, are common with meperidine use. However, the sudden onset of autonomic instability, diarrhea, and confusion in the context of recent exposure to a selective serotonin reuptake inhibitor is very suggestive of serotonin syndrome. The diagnosis of serotonin syndrome is facilitated by criteria first proposed by Sternbach (Appendix). However, it should be noted that some common findings of serotonin syndrome, such as tachycardia, hypertension, and pupillary dilatation, are not among the diagnostic criteria, even though their presence may be suggestive in a patient with a history of exposure to drugs that might serve as a trigger. In this instance, the patient's uneventful behavior during previous exposures to meperidine when he was not taking fluoxetine further supports the likelihood of an interaction between the two drugs.

It is worth noting that the selective serotonin reuptake inhibitors have relatively long half-lives, and patients may be at risk for this interaction days or weeks after therapy is discontinued. Fluoxetine is unusual in that its active metabolite, norfluoxetine, has a 2-week half-life, which potentially creates a long period of risk for patients exposed to other drugs with serotonin activity.³ In addition, the use of selective serotonin reuptake inhibitors is becoming more widespread due to their favorable safety profile in overdose, making it likely that interactions of this nature will become more common over time.⁴

Treatment of serotonin syndrome is supportive. Serotonergic medications should be withdrawn until signs and symptoms resolve. Cyproheptadine may attenuate the severity and duration of the syndrome. Seizure precautions are indicated, and observation at least until

signs and symptoms resolve is indicated. Muscle rigidity should be treated with benzodiazepines, and nondepolarizing neuromuscular-blocking agents if benzodiazepines are ineffective. Severe cases may require intubation and mechanical ventilation.⁵

Appendix: The Sternbach Criteria

Criteria A, B, and C required for diagnosis.⁵

- A. Coincident with the addition of or increase in a known serotonergic agent to an established medication regimen, at least three of the following clinical features are present:
 1. Mental status changes (confusion, hypomania)
 2. Agitation
 3. Myclonus
 4. Muscle rigidity (usually lower extremities predominating)
 5. Hyperreflexia
 6. Diaphoresis
 7. Shivering
 8. Tremor
 9. Diarrhea
 10. Incoordination
 11. Fever
- B. Other causes (infectious, metabolic, substance abuse or withdrawal) have been excluded.
- C. A neuroleptic agent had not been started or increased in dosage before the onset of the signs and symptoms previously listed.

References

1. Mills KC: Serotonin syndrome: A clinical update. *Crit Care Clin* 1997; 13:764-83
2. Mason PJ, Morris VA, Balcezak TJ: Serotonin syndrome: Presentation of 2 cases and review of the literature. *Medicine* 2000; 79:201-9
3. Coplan JD, Gorman JM: Detectable levels of fluoxetine after discontinuation: An unexpected serotonin syndrome. *Am J Psychiatry* 1993; 150:837
4. Sarko J: Antidepressants old and new. *Emerg Clin North Am* 2000; 18:637-54
5. Arnold DH: The central serotonin syndrome: Paradigm for psychotherapeutic misadventure. *Pediatr Rev* 2002; 23:427-32

Treatment of Excessive Bleeding in Jehovah's Witness Patients after Cardiac Surgery with Recombinant Factor VIIa (NovoSeven®)

Kenichi A. Tanaka, M.D.,* Amr A. Waly, M.D.,† William A. Cooper, M.D.,‡ Jerrold H. Levy, M.D.§

CARDIAC surgery with cardiopulmonary bypass (CPB) poses serious hemostatic challenges in Jehovah's Witnesses, who refuse blood transfusions on religious grounds. Excessive bleeding (> 2 l) after cardiac surgery is encountered in 5-7% of Jehovah's Witness patients,¹ and necessitates reexploration in 3.6% of cases.² Recombinant factor VIIa (rFVIIa, NovoSeven®; Novo Nordisk, Princeton, NJ), produced in baby hamster kidney cell lines and free of human protein, could be an alternative hemostatic agent and is generally acceptable to these patients. It has been used in hemophiliac and nonhemophiliac patients to treat bleeding diatheses in medical and surgical settings. We describe two cases of severe microvascular bleeding during and after mitral valve replacement in Jehovah's Witness patients who were successfully treated with a single dose of rFVIIa.

Case Reports

Case 1

A 74-yr-old, 104-kg woman was scheduled for mitral valve replacement. The patient was a Jehovah's Witness, and her medical history included congestive heart failure due to mitral regurgitation, hypertension, and diabetes mellitus. Baseline hematocrit was 32.6%, and activated clotting time was 137 s. Anesthesia was fentanyl based with isoflurane and vecuronium supplementation. Aprotinin (2 million units) was administered as a loading dose, followed by a 2 million-unit pump prime and 500,000 U/h. The mitral valve was replaced after 126 min of CPB, during which hematocrit was 15-18% and blood salvage (cell saver) and ultrafiltration were performed. The patient was initially separated from CPB, and heparin was reversed with protamine. Subsequently, CPB was urgently reinstated to repair a tear in the left atriotomy site after administration of 400 U/kg heparin. The patient was weaned from CPB after repair, and protamine was administered. Activated clotting time returned to 134 s, but there was persistent microvascular bleeding from the field. Laboratory studies disclosed the following values: hematocrit, 22%; platelet count, $131 \times 10^9/l$; prothrombin time (PT), 30.8 s; and fibrinogen, 116 mg/dl. Thromboelastogram analysis showed a reaction time of 32.5 min and a maximum amplitude of 49 mm. Because bleeding continued, the patient received

45 $\mu\text{g}/\text{kg}$ rFVIIa prior to chest closure. Results of the repeat laboratory analysis were as follows: activated clotting time, 122 s; PT, 19 sec; platelet count, $63 \times 10^9/l$; and fibrinogen, 117 mg/dl. Thromboelastogram results also improved the reaction time to 19 min and maximum amplitude to 66 mm. Over the course of 4 h, the chest tube drainage totaled 200 ml and hematocrit was 24%. The following day, hematocrit was 19%, 24-h chest drainage was 740 ml, and recombinant erythropoietin was started. On the third day, the hematocrit value decreased to 16% but steadily climbed to 22% by the eighteenth day. On the twentieth postoperative day, the patient was discharged from the intensive care unit after being weaned from prolonged ventilatory support.

Case 2

A human immunodeficiency virus-positive 49-yr-old, 76-kg man was scheduled for mitral valve replacement. He was a Jehovah's Witness, and his medical history included congestive heart failure due to mitral regurgitation, diabetes mellitus, and end-stage renal failure requiring hemodialysis. Baseline laboratory data were as follows: hematocrit, 39.7%; platelet count, $155 \times 10^9/l$; PT/aPTT, 17.7/52.9 s; and creatinine level, 9.7 mg/dl. Anesthesia was fentanyl based with isoflurane, pancuronium supplementation. Aprotinin was administered as described in case 1. Immediately after CPB was initiated, a profuse left nasal bleed occurred spontaneously. The epistaxis was not controlled with repeated intranasal doses of 0.25% phenylephrine and 0.1% epinephrine, and a right nasal bleed was noted. Nasal passages were packed with epinephrine-soaked gauzes. The mitral valve was replaced after 199 min of CPB, and the patient was separated from CPB with milrinone, norepinephrine, and vasopressin infusions. Activated clotting time returned to baseline values (146 s) after administration of protamine, and desmopressin acetate (32 μg) was given intravenously. Laboratory results were as follows: hematocrit, 26.5%; platelet count, $82 \times 10^9/l$; fibrinogen level, 205 mg/dl; and thromboelastogram maximum amplitude, 59 mm. PT/aPTT (27.1/55.3 s) and thromboelastogram reaction time (14.2 min) were prolonged to approximately twice the normal value. Epistaxis and microvascular bleeding from the surgical wound continued, and rFVIIa (60 $\mu\text{g}/\text{kg}$) was given intravenously prior to the chest closure. After 3 min of rFVIIa therapy, clot formation was noticed at the surgical sites, and epistaxis began to slow. Findings of repeat laboratory analysis were as follows: reaction time, 8 min; PT/aPTT, 16.4/56.9 s; and fibrinogen, 176 mg/dl. Abciximab-modified thromboelastogram also showed improvements after rFVIIa therapy; reaction time shortened from 14.5 min to 8 min, and maximum amplitude increased from 14 mm to 21 mm. Chest tube drainage was 270 ml upon arrival in the intensive care unit, and then decreased to an average of 55 ml/h. By the next day, hematocrit was 28.6% and 24-h chest drainage was 1090 ml. The patient was discharged from the intensive care unit on the fourth postoperative day.

* Assistant Professor of Anesthesiology, † Cardiothoracic Anesthesia Fellow, ‡ Assistant Professor of Surgery (Cardiothoracic), § Professor of Anesthesiology, Departments of Anesthesiology and Surgery (Cardiothoracic), Emory University School of Medicine and Division of Cardiothoracic Anesthesiology and Critical Care, Emory Healthcare, Atlanta, Georgia.

Received from the Departments of Anesthesiology and Surgery (Cardiothoracic), Emory University School of Medicine and Division of Cardiothoracic Anesthesiology and Critical Care, Emory Healthcare, Atlanta, Georgia. Submitted for publication October 11, 2002. Accepted for publication February 12, 2003. Support was provided solely from institutional and/or departmental sources.

Address reprint requests to Dr. Levy: Department of Anesthesiology, Emory University Hospital, 1364 Clifton Rd., N.E., Atlanta, Georgia 30322. Address electronic mail to: jerrold_levy@emoryhealthcare.org. Individual article reprints may be purchased through the Journal Web site, www.anesthesiology.org.

Discussion

We have described two cases where a single dose of rFVIIa (NovoSeven®) was used to improve hemostasis in cardiac surgical patients who refused blood products on religious grounds. There are no human protein or deriv-

atives present during the manufacturing or purification processes of recombinant factor VIIa in baby hamster kidney cells; therefore rFVIIa is an acceptable treatment option for these patients.³

These two Jehovah's Witness patients provided us with a unique opportunity to examine the effect of rFVIIa in the treatment of CPB-induced coagulopathy without transfusion. We used aprotinin prophylactically in both cases, and desmopressin acetate was administered to improve platelet adhesiveness in a patient with preexisting renal insufficiency (case 2). However, profuse microvascular bleeding continued, secondary to prolonged CPB. When there were no therapeutic options remaining for these patients, rFVIIa was administered and hemostasis improved. High doses of rFVIIa are used to control bleeding episodes in hemophilia A and B patients who have inhibitory antibodies against FVIII or FIX, respectively.⁴ In addition, off-label use of rFVIIa has been reported for the treatment of uncontrollable bleeding in trauma,⁵ cardiac surgery,^{6,7} orthotopic liver transplantation,⁸ and prostatectomy.⁹ While the optimal effective dose remains to be determined, 90 $\mu\text{g}/\text{kg}$ rFVIIa has been accepted as a standard dose.⁴ We administered a smaller dose (45–60 $\mu\text{g}/\text{kg}$) of rFVIIa than that suggested for hemophilia because lower doses have been reported to be effective in nonhemophilic surgical patients.

Reduced thrombin generation at the site of injury is not uncommon after CPB. This is because coagulation factors are diluted, and platelets are often defective and deficient. FVIIa plays a critical role in initiating thrombin generation by binding to tissue factor at injury sites.¹⁰ rFVIIa is believed to increase thrombin generation, activate platelets, and stabilize fibrin polymerization (fig. 1).^{11,12} Thromboelastogram tracings depicted characteristics of rFVIIa action. Before and after rFVIIa therapy, reaction time was reduced in both native and abciximab-modified thromboelastogram. Suppression of glycoprotein IIb/IIIa abrogates the contribution of platelets to clot formation; therefore, improved thromboelastogram parameters in the presence of abciximab suggest that rFVIIa-mediated clot potentiation is, at least in part, platelet independent. This finding underlies its efficacy in various platelet disorders.^{13,14}

Dietrich¹⁵ suggests that the mode of action of rFVIIa in cardiac surgical patients is still somewhat controversial. However, clinical experiences with rFVIIa in a large number of patients with hemophilia support its relative safety,⁴ though there are a few reported cases of thrombotic episodes.^{14,16} Furthermore, bleeding alone is a potentially life-threatening problem where additional therapeutic options are needed.

In summary, we report a refractory surgical wound bleeding and epistaxis in Jehovah's Witness patients following CPB that was successfully managed with a single dose of rFVIIa (45–60 $\mu\text{g}/\text{kg}$). We believe that rFVIIa

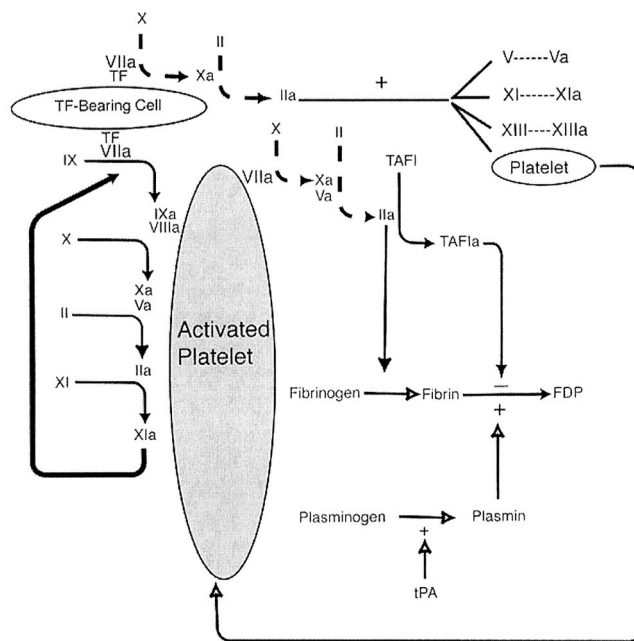


Fig. 1. Recombinant factor VIIa therapy (dashed arrows) may circumvent the deficiency of factor VIII or IX (i.e., hemophilia) by directly activating factor X and IX in the presence of tissue factor (TF). Activated factor X (Xa) complexes with factor Va on TF-bearing cells to convert prothrombin (II) to thrombin (IIa). Thrombin formation leads to fibrin formation, platelet activation, activation of fibrin-stabilizing factor (XIII), and thrombin-activatable fibrinolysis inhibitor (TAFI).

offers an important therapeutic option in this patient population, although additional studies are needed to prove its safety and efficacy in cardiac surgical patients.

References

1. Testa LD, Tobias JD: Techniques of blood conservation. Part II: Autologous transfusion, intraoperative blood salvage, pharmacologic agents, and cost issues. *Am J Anesth* 1996; 23:63–72
2. Mann MC, Votto J, Kambe J, McNamee MJ: Management of the severely anemic patient who refuses transfusion: Lessons learned during the care of a Jehovah's Witness. *Ann Int Med* 1992; 117:1042–8
3. Majumdar G, Savidge GF: Recombinant factor VIIa for intracranial haemorrhage in a Jehovah's Witness with severe haemophilia A and factor VIII inhibitors. *Blood Coag Fibrinol* 1993; 4:1031–3
4. Poon MC: Use of recombinant factor VIIa in hereditary bleeding disorders. *Curr Opin Hematol* 2001; 8:312–8
5. Martinowitz U, Kenet G, Segal E, Luboshitz J, Lubetsky A, Ingerslev J, Lynn M: Recombinant activated factor VII for adjunctive hemorrhage control in trauma. *J Trauma Infection Crit Care* 2001; 51:431–9
6. Al Douri M, Shafi T, Al Khudairi D, Al Bokhari E, Black L, Akinwale N, Musa MO, Al Homaidhi A, Al Fagih M, Andreasen RB: Effect of the administration of recombinant activated factor VII (rFVIIa; NovoSeven(TM)) in the management of severe uncontrolled bleeding in patients undergoing heart valve replacement surgery. *Blood Coag Fibrinol* 2000; 11:S121–7
7. Hendriks HGD, Van der Maaten J, De Wolf J, Waterbolk TW, Slooff MJH, Van der Meer J: An effective treatment of severe intractable bleeding after valve repair by one single dose of activated recombinant factor VII. *Anesth Analg* 2001; 93:287–9
8. Hendriks HGD, Meijer K, De Wolf J, Klompmaaker IJ, Porte RJ, De Kam PJ, Hagenaaers AJM, Melsen T, Slooff MJH, Van Der Meer J: Reduced transfusion requirements by recombinant factor VIIa in orthotopic liver transplantation. *Transplantation* 2001; 71:402–5
9. Friederich PW, Geerdink MGF, Spataro M, Messelink EJ, Henny Ch P, Buller HR, Levi M: The effect of the administration of recombinant activated factor VII (NovoSeven(TM)) on perioperative blood loss in patients undergoing transabdominal retropubic prostatectomy: The PROSE study. *Blood Coag Fibrinol* 2000; 11:S129–32

10. Ten Cate H, Bauer KA, Levi M, Edgington TS, Sublett RD, Barzegar S, Kass BL, Rosenberg RD: The activation of Factor X and prothrombin by recombinant factor VIIa in vivo is mediated by tissue factor. *J Clin Invest* 1993; 92:1207-12
11. Hedner U: NovoSeven(TM) as a universal hemostatic agent. *Blood Coag Fibrinol* 2000; 11:S107-11
12. Monroe DM, Hoffman M, Oliver JA, Roberts HR: Platelet activity of high-dose factor VIIa is independent of tissue factor. *Br J Haematol* 1997; 99:542-547
13. Poon MC, D'Oiron R: Recombinant activated factor VII (NovoSeven(TM)) treatment of platelet-related bleeding disorders. *Blood Coag Fibrinol* 2000; 11: S55-68
14. D'Oiron R, Menart C, Trzeciak MC, Nurden P, Fressinaud E, Dreyfus M, Laurian Y, Negrier C: Use of recombinant factor VIIa in 3 patients with inherited type I Glanzmann's thrombasthenia undergoing invasive procedures. *Thromb Haemost* 2000; 83:644-7
15. Dietrich W, Spannagl M, Hendriks HGD, Van der Maaten J, De Wolf J, Der Meer J: Caveat against the use of activated recombinant factor VII for intractable bleeding in cardiac surgery (multiple letters). *Anesth Analg* 2002; 94:1369-71
16. Peerlinck K, Vermylen J: Acute myocardial infarction following administration of recombinant activated factor VII (Novo Seven) in a patient with haemophilia A and inhibitor. *Thromb Haemost* 1999; 82:1775-6