

# Safety of Chronic Intrathecal Morphine Infusion in a Sheep Model

Tamara Lee Gradert, B.S.,\* Wallace B. Baze, D.V.M., Ph.D.,† William C. Satterfield, D.V.M.,‡  
Keith R. Hildebrand, D.V.M., Ph.D.,§ Mary J. Johansen, Pharm.D.,|| Samuel J. Hassenbusch, M.D., Ph.D.#

**Background:** The safety of chronically administered intrathecal morphine has been questioned. Therefore, the authors examined the behavioral and neurologic effects and neurotoxicity of continuous intrathecal morphine administration in sheep.

**Methods:** Groups of three sheep were implanted with intrathecal infusion systems for the continuous administration of morphine (3, 6, 9, 12, or 18 mg/day) or saline at a fixed infusion rate of 1.92 ml/day beginning approximately 7 days after implantation. Sheep were examined daily for any changes in behavior or neurologic function. After 28–30 days, the animals were humanely killed. Cerebrospinal fluid samples were collected and analyzed for protein, erythrocytes and leukocytes, and morphine content. The spinal cord and meninges with the catheter *in situ* was removed *en bloc* and fixed in formalin for histologic analysis.

**Results:** Unilateral hind-leg gait deficits were observed in two of three animals in each of the 12- and 18-mg/day dose groups. Gross and microscopic evaluation of spinal cord tissue from these animals revealed intradural-extramedullary inflammatory masses that compressed the spinal cord at the catheter-tip and mid-catheter areas. This inflammation was ipsilateral to extremities that exhibited gait deficits and had acute and chronic cellular components.

**Conclusions:** The toxicity of intrathecal morphine seems to be dependent on the amount of morphine infused, although the effects of dose *versus* concentration cannot be clearly distinguished in this study. Intrathecal morphine doses of 12–18 mg/day produced inflammatory masses extending from the catheter tip down the length of the catheter within the subarachnoid space. Doses of 6–9 mg/day produced mild-to-moderate inflammation 5 cm cranial to the catheter tip. A dose of 3 mg/day produced no neurotoxicity and spinal histopathologic changes that were equivalent to those observed in the saline-treated animals.

This article is accompanied by an Editorial View. Please see:  
Follett KA: Intrathecal analgesia and catheter-tip inflammatory masses. ANESTHESIOLOGY 2003; 99:5–6.

\* Senior Research Assistant, † Associate Professor, Associate Veterinary Pathologist, and Section Chief, Veterinary Pathology, ‡ Associate Professor of Comparative Medicine and Section Chief, Large Animal and Land Management, Department of Veterinary Sciences, || Assistant Professor Cancer Medicine, Department of Experimental Therapeutics, # Professor, Department of Neurosurgery, The University of Texas M. D. Anderson Cancer Center. § Staff Scientist, Drug Delivery Ventures, Medtronic, Inc., Minneapolis, Minnesota.

Received from the Departments of Neurosurgery and Veterinary Sciences, The University of Texas M. D. Anderson Cancer Center, Houston, Texas. Submitted for publication September 4, 2002. Accepted for publication January 8, 2003. Supported by Medtronic, Inc. Minneapolis, Minnesota. Presented in part at the 21st annual meeting of the American Pain Society, Baltimore, Maryland, March 16, 2002.

Address reprint requests to Dr. Hassenbusch: Department of Neurosurgery, The University of Texas M. D. Anderson Cancer Center, 1515 Holcombe Boulevard, Unit 442, Houston, Texas 77030-4009. Address electronic mail to: samuel@neosoft.com. Individual article reprints may be purchased through the Journal Web site, [www.anesthesiology.org](http://www.anesthesiology.org).

INTRATHECAL morphine has a long history of clinical use. The first known spinal administration of morphine occurred in 1901 when a Japanese physician used intrathecal morphine for the treatment of vertebral inflammation.<sup>1</sup> Intrathecal morphine was introduced clinically for obstetric analgesia in 1979.<sup>2</sup> In 1981, Onofrio *et al.*<sup>3</sup> reported the first use of an implanted pump and catheter system for the delivery of continuous low-dose (0.62–1.8 mg/day) intrathecal morphine for the treatment of chronic cancer pain. Additional clinical trials further established the efficacy and safety of intraspinal morphine for the treatment of intractable cancer pain.<sup>4–9</sup> Preservative-free morphine sulfate was first approved by the United States Food and Drug Administration for epidural and intrathecal administration as Duramorph® (1 mg/ml; Elkins-Sinn, Cherry Hill, NJ) in September 1984 and then as Infumorph® 100 (10 mg/ml) and 500 (25 mg/ml; Elkins-Sinn) in July 1991. At present, preservative-free morphine sulfate is the only opioid approved by the Food and Drug Administration for continuous long-term intrathecal administration to treat chronic intractable pain.

Although preliminary studies of spinally administered morphine *via* bolus dosing for the treatment of nonmalignant pain were not promising,<sup>10</sup> more recent studies have shown the benefit of continuous intrathecal morphine infusion for the treatment of a wide range of conditions including postoperative pain, failed-back syndrome, ankylosing spondylitis, pelvic pain, postthoracotomy pain, low back and leg pain, chronic arachnoiditis, visceral pain, postherpetic neuralgia, phantom limb pain, spinal cord injury, peripheral neuropathy, and reflex sympathetic dystrophy.<sup>11–15</sup> Moreover, implantable technology for intrathecal drug infusion has made a route of administration that once was viewed as exotic clinically acceptable.<sup>16</sup> However, with this technology have come new challenges.<sup>17</sup> Recently, there have been increasing reports of breakthrough pain in patients using implanted morphine pumps on dosing regimens that had previously controlled their symptoms.<sup>17–19</sup> In addition, there have been increasing reports of intradural-extramedullary masses at the tips of the intraspinal catheters, resulting in spinal cord compression and potentially serious neurologic deficits.<sup>20,21</sup> In response to these reports, a double-blinded study was conducted in sheep to determine the safety of preservative-free morphine sulfate continuously infused into the subarachnoid space.

## Materials and Methods

### *Study Protocol and Animal Care*

The study protocol was approved by The University of Texas M. D. Anderson Cancer Center's Institutional Animal Care and Use Committee (Houston, Texas). Eighteen Rambouillet-cross sheep of either sex (weight, 36.8–58.6 kg) were used in a double-blinded study that was conducted in compliance to Good Laboratory Practice. The study was performed in strict compliance with US Public Health Service Guidelines for the Care and Use of Research Animals. All sheep were quarantined for 3 weeks in a pasture with shelter while being conditioned for the study. All were provided with coastal Bermuda grass and water *ad libitum* and fed a mixture of commercially available livestock rations.

### *Surgical Procedure*

All sheep were fasted 48 h before surgery to minimize the risk of aspiration pneumonia. Anesthesia was induced with 6 mg/kg ketamine and 0.2 mg/kg diazepam administered intravenously. Endotracheal anesthesia was maintained using 2.2–3.9% halothane in oxygen. To obtain baseline data, venous blood was drawn for hematology (leukocyte count, erythrocyte count, hematocrit, platelet count, *etc.*) and chemistry tests (globulin [calculated], aspartate aminotransferase, chloride,  $\gamma$ -glutamyl transferase, triglycerides, calcium, phosphorous, creatine phosphokinase, lactate dehydrogenase, uric acid, sodium, potassium, cholesterol, albumin, globulin, alanine aminotransferase, creatinine, total protein, total bilirubin, alkaline phosphatase, glucose, albumin, and blood urea nitrogen) prior to intrathecal pump implantation. A midline incision was made over L6–S2 to expose the lumbodorsal fascia. A 16-gauge Tuohy needle was inserted into the intravertebral space at L7/S1. The needle was slowly advanced until the dura was punctured and cerebrospinal fluid (CSF) was flowing freely from the hub of the needle. A sample of CSF was collected for baseline analyses including routine culture (aerobic and anaerobic organisms), cytology, and total protein analysis. A silicone intraspinal catheter (model 8703; Medtronic, Inc., Minneapolis, MN) was threaded into the Tuohy needle and advanced 10 cm cephalad into the subarachnoid space to the approximate level of L4/L5. The catheter was checked for CSF flow and was secured to the muscle fascia with a 90° silastic anchor and silk suture. A subcutaneous pocket was fashioned in the left paralumbar fossa for the pump, and connecting tubing was tunneled subcutaneously and attached to the spinal catheter. The tubing was attached to the pump, and the pump (Medtronic model 8627-18, 8627 L-18, or 8616-18 L) was anchored to the muscle in three locations with silk sutures. The pump was filled with 10 ml sterile saline. The subcutaneous pump pocket was flushed with a saline-gentamicin solution and closed in layers.

Analgesics (5 mg butorphanol) were administered when the sheep emerged from anesthesia, the evening of surgery, the following morning, and as needed thereafter. The postoperative antibiotic regimen consisted of 1 g cefazolin intramuscularly twice daily for 3 days and then 5 ml Benz Pen (penicillin G benzathine and penicillin G procaine) subcutaneously once daily for an additional 3 days. Sheep fully recovered from anesthesia within a few hours and were given hay and water.

### *Test Drug and Solutions*

Morphine sulfate (Infumorph<sup>®</sup> 500, lot No. 100077) was purchased from Wyeth-Ayerst Laboratories (Philadelphia, PA). The drug is dispensed in a 20-ml glass ampule at a concentration of 25 mg/ml. The drug was diluted aseptically with preservative-free sterile saline (0.9%, US Pharmacopoeia, Rockville, MD) and filtered through a sterile 0.22- $\mu$ m filter (Millipore, Bedford, MA). During pump refills, the dilutions were filtered again through a sterile 0.22- $\mu$ m filter (Medtronic 8551 Refill Kit).

### *Treatment Groups and Clinical Observations*

Sheep were allowed to recover from implant surgery for 7 days ( $\pm 2$  days) before being started on a randomly assigned dose of morphine (3, 6, 9, 12, or 18 mg/day at concentrations of 1.56, 3.13, 4.69, 6.25, and 9.38 mg/ml, respectively) or saline (control) at a continuous infusion of 1.92 ml/day. Each group consisted of three sheep. Each sheep was weighed on the day before pump implantation, on days coinciding with pump refills (every 7 days, +1 day,  $n =$  five refills), and again before death. The residual volume was measured at the time of refill, and the daily flow rates were retrospectively calculated for each refill period. The average calculated flow rate was 2.10 ml/day. Sheep were observed at approximately the same time of day, twice daily (for 15 min each), for any changes in behavior and for potential neurologic deficits. These observations were made by one individual in the morning and another individual in the afternoon. Both observers had more than 8 yr of experience in observing normal sheep behavior and behavior indicative of toxicity. The twice-daily written narrative of observations included appetite, posture, ambulation, herding activity, and reactions to the environment. Rectal body temperatures were also recorded daily.

### *Gross Anatomic and Histopathologic Examination*

On day 28 ( $n = 14$ ), 29 ( $n = 5$ ), or 30 ( $n = 2$ ) of morphine infusion, the sheep were humanely killed by anesthetic overdose. Blood samples for hematology and serum chemistries were taken prior to death. At necropsy, CSF samples were collected for analysis of drug concentrations, cytology, and total protein. Cisternal CSF samples were obtained by dural puncture with an 18-gauge needle. A dorsal laminectomy was performed from S1 to C1. The spinal cord and meninges were

removed *en bloc* with the intrathecal catheter *in situ*. The appearance of the tissue near the catheter was recorded, as were the position and path the catheter traveled and the length of catheter in the subarachnoid space. The spinal cord was fixed in 10% formalin for a minimum of 1 week. After fixation, representative cord sections were taken from the region of the catheter tip, from an area 5 cm cranial to the catheter tip, and from the mid-catheter area. Tissues were then processed routinely, paraffin-embedded, sectioned at 4–6  $\mu\text{m}$ , and stained with hematoxylin and eosin. As needed, cord sections were also stained with Gram stain and Grocott modification of Gomori methenamine silver stain. Sections were evaluated for the presence or absence of (1) inflammation or other reactions (*e.g.*, fibroplasia/fibrosis) around the catheter; (2) inflammation in the meninges and spinal cord parenchyma; and (3) compression or other damage to the cord parenchyma. Inflammation was classified as acute (presence of eosinophils, degenerate and/or necrotic cells, vacuolated histiocytes, neutrophils, cellular debris), chronic (presence of lymphocytes, plasma cells, and fibroplasia), or both. The degree of inflammation or spinal cord compression was graded as mild, moderate, or severe. All spinal cord sections were examined by a board-certified veterinary pathologist blinded to the drug dose used.

#### *Measurement of Morphine and Morphine Metabolites*

Cerebrospinal fluid samples were analyzed by AAI International (Shawnee, Kansas), a Good Laboratory Practices compliant laboratory, using liquid chromatography–mass spectrometry–mass spectrometry to determine the concentrations of morphine, morphine-3-glucuronide, and morphine-6-glucuronide. Samples were adjusted to pH 9.3 with sodium carbonate, combined with deuterated internal standards and extracted using solid-phase extraction. The resulting extracts were injected onto a C18 loading column, transferred to an analytical C18 column through valve switching, and chromatographed using a binary gradient system with a flow rate of 200  $\mu\text{l}/\text{min}$ . The mobile phases consisted of 10 mm ammonium formate, pH 3.0, with solvent “A” containing 5% methanol and 5% acetonitrile, and solvent “B” containing 90% methanol. The analytes were detected using a PE Sciex API 3000 mass spectrometer (Concord, Ontario, Canada) in MRM mode for the following precursor/products (*m/z*): morphine (286\*165), morphine-D3 (289\*165), morphine-3- and morphine-6-b-D-glucuronides (462\*286), morphine-3- and morphine-6-b-D-glucuronide-D3 (465\*289) with retention times approximating 1.8 min (morphine-3-b-D-glucuronide), 2.2 min (morphine-6-b-D-glucuronide), and 2.6 min (morphine). The method was linear over a concentration range of 2.5–400 ng/ml CSF (0.1-ml sample volume).

#### *Statistical Analysis*

For data analysis, morphine concentrations in cisternal CSF were expressed as mean and SEM at each dose level (fig. 1, A). The correlation coefficient between lumbar intrathecal dose of morphine and cisternal CSF concentration was determined by linear regression (fig. 1, B).

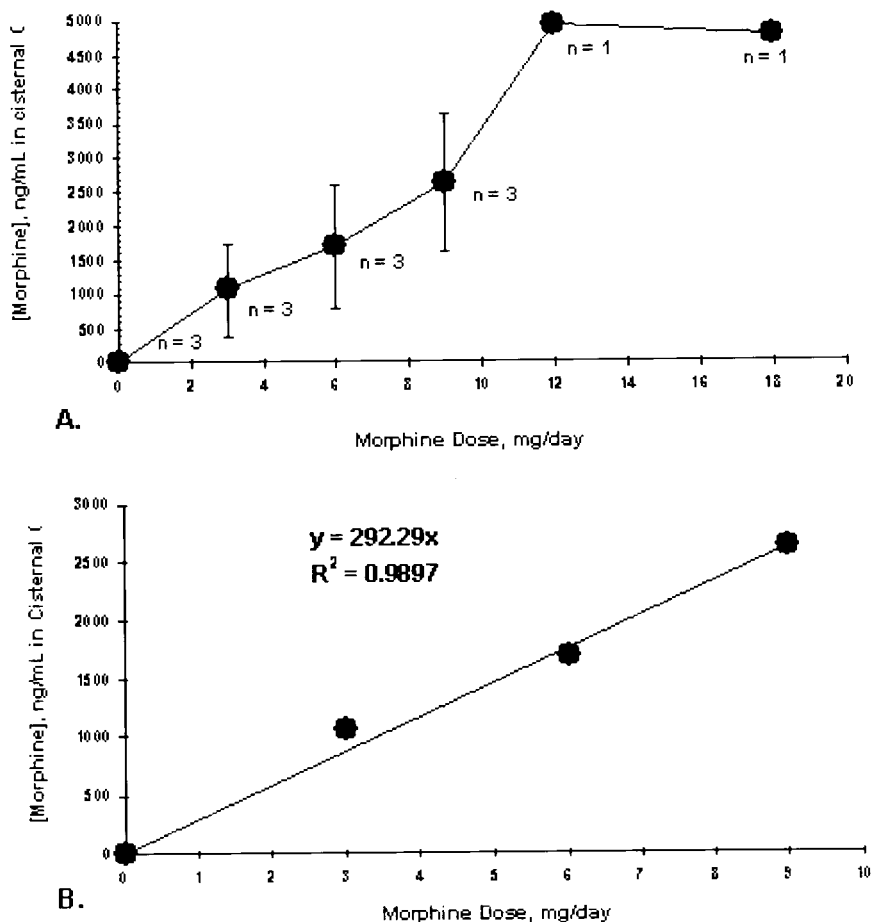
## Results

#### *Clinical Observations*

The toxicity of continuous intrathecal infusion of morphine sulfate was found to depend on the amount of drug infused. Because the concentration of morphine in the infusate increased with dose (to maintain a constant infusion volume between dose groups), it is not possible to clearly delineate the effects of dose *versus* concentration in these experiments (table 1, columns 2 and 3). At the two highest dose levels (12 and 18 mg/day), all sheep exhibited frank pain behavior within the first several days of initiating the morphine infusion. This behavior included biting and pulling wool over the caudal lumbar area. Other abnormal behaviors observed in sheep treated with doses of 12 mg/day or greater, typically within the first few days of treatment, included lying in the lateral recumbent position (sternal recumbency is normal in sheep), walking in circles, difficulty rising, abnormally high placement of the front legs while walking (“marching”), and reluctance to move unless prompted.

Unilateral hind-leg gait deficits were observed in two of three sheep in each of the two highest dose levels. This behavior was initially characterized by shortened hind-leg stride (hind-limb stiffness) or slight limping in one of the rear legs during the first 2 weeks of treatment (initially observed between days 7 and 12). This behavior progressed during the drug infusion period to unilateral non-weight-bearing lameness. Although observed at both of the two highest dose levels, these clinical signs were most severe in animals treated with 18 mg/day, as evidenced by more severe hind-leg dysfunction. One animal in each of the two highest dose groups did not exhibit gait deficits during the study (Nos. 946 and 954) but did exhibit frank pain behavior. The animal (No. 954) treated with 18 mg/day that did not develop lameness exhibited seizure-like episodes on days 16 and 22 of the study. With the exception of two animals, none of the animals in the 0-, 3-, 6-, and 9-mg/day dose groups exhibited any clinical signs during the study period. One animal (No. 949, 9 mg/day) exhibited frank pain behavior (biting and wool pulling over the caudal lumbar area) but only on the last day of morphine infusion. One saline-treated sheep displayed biting and wool pulling over the right flank area during four observation periods. At necropsy, the catheter in this particular animal was observed to pass through nerve roots on the right lateral side of the spinal canal. No clinically significant changes

**Fig. 1.** Concentrations of morphine in cisternal cerebrospinal fluid as a function of morphine sulfate dose (mg/day) administered *via* chronic lumbar intrathecal infusion. All samples were collected *via* percutaneous puncture of the atlanto-occipital interspace after 28–30 days of infusion at a fixed rate of 80  $\mu$ L/h and quantified using liquid chromatography–mass spectrometry–mass spectrometry. (A) Mean  $\pm$  SEM of morphine concentrations determined at each dose with the exception of 12 and 18 mg/day, in which morphine was only detected in one animal per dose group (*i.e.*, the animals that did not exhibit inflammatory masses). (B) Linear regression demonstrating the high positive correlation ( $R^2 = 0.9897$ ) between lumbar intrathecal dose and cisternal cerebrospinal fluid concentration in animals not affected with catheter-tip inflammatory masses.



in body weight or temperature were detected during the course of the study.

#### Gross and Microscopic Pathologic Studies

At necropsy, the four sheep treated with doses of 12 mg/day or greater that displayed hind-limb dysfunction had severe inflammatory masses associated with the subarachnoid catheter body and catheter tip (fig. 2). In each sheep, the inflammatory process was ipsilateral to the observed gait deficit. In three sheep, the inflammation was greatest in diameter at the catheter tip and varied in thickness as it extended caudally along the body of the catheter. The inflammatory mass in one sheep was approximately the same thickness at the tip and along the body of the catheter (No. 820, 12 mg/day). The diameters of the inflammatory masses at the catheter-tip regions ranged from 5 to 9 mm. The masses extended caudally along the catheter body a distance of 8–11 cm within the subarachnoid space and had a variable diameter ranging from 3 to 6 mm. There was no difference in the gross appearance and size of the inflammatory masses observed in sheep treated with 12 *versus* 18 mg/day morphine. Two sheep in the high-dosing groups did not develop inflammatory masses (fig. 3). Sheep treated with doses of 9 mg/day or less had no

discernible gross changes in spinal cord tissue in the vicinity of the catheter.

On microscopic examination, spinal tissue from the four sheep that exhibited clinical lameness and gross inflammation surrounding the catheter revealed severe spinal cord compression and severe acute and chronic inflammation at the level of the catheter tip (table 2). The inflammation, which primarily arose from the meninges, compressed the spinal cord architecture by 30–40% (fig. 4). The degree of compression correlated positively with the degree of inflammation. The cellular changes in all four animals with inflammatory masses were characterized as having both acute (eosinophils, degenerate neutrophils and/or necrotic cells, vacuolated histiocytes, neutrophils, cellular debris) and chronic (lymphocytes, plasma cells, and fibroplasia) inflammatory components (fig. 5). In addition, the leptomeninges and cord parenchyma contained occasional aggregates of lymphocytes characteristic of chronic inflammation.

In contrast to the lame animals, sheep treated with morphine at doses of 9 mg/day or less and the two animals treated with doses of 12 mg/day or greater that did not develop lameness displayed microscopic spinal cord changes in the vicinity of the catheter that were comparable to those observed in saline-treated animals

**Table 1. Morphine and Morphine Metabolite Concentrations in Cisternal CSF of Sheep Chronically Infused with Lumbar Intrathecal Morphine**

Sheep No.	Morphine Dose (mg/day)	Infusate Concentration (mg/ml)*	Morphine Concentration (ng/ml)‡	Morphine-3-glucuronide (ng/ml)‡	Inflammatory Mass Present§
960	0.0	Saline	<2.50	<2.50	No
943	0.0	Saline	<2.50	<2.50	No
950	0.0	Saline	<2.50	<2.50	No
941	3.0	1.56	106.94	<2.50	No
962	3.0	1.56	2,348.75	<2.50	No
953	3.0	1.56	716.84	<2.50	No
956	6.0	3.13	909.51	<2.50	No
966	6.0	3.13	3,502.14	<2.50	No
818	6.0	3.13	641.26	<2.50	No
963	9.0	4.69	4,524.26	10.06	No
949	9.0	4.69	2,214.79	<2.50	No
952	9.0	4.69	1,110.50	<2.50	No
820	12.0	6.25	4.59	<2.50	Yes
959	12.0	6.25	<2.50	<2.50	Yes
946	12.0	6.25	4,943.80	<2.50	No
954	18.0	9.38	4,785.26	<2.50	No
965	18.0	9.38	18.14	19.84	Yes
957	18.0	9.38	26.41	5.76	Yes

\* All infusates were administered at a constant rate of 80  $\mu$ l/day (1.92 ml/day) and prepared from Infumorph® 500 diluted with 0.9% saline (U.S. Pharmacopoeia) to give the appropriate concentration as indicated in column 3. † All samples were collected at the end of the 28- to 30-day infusion period via percutaneous puncture of the atlantooccipital interspace. ‡ The amount of morphine-6-glucuronide present in all samples analyzed was below the limit of quantification. § The presence of "granuloma" was assessed by gross and microscopic postmortem examination after approximately 28 days of morphine administration. || The limit of quantification for the analytical method was 2.50 ng/ml for morphine, morphine-3-glucuronide, and morphine-6-glucuronide. CSF = cerebrospinal fluid.

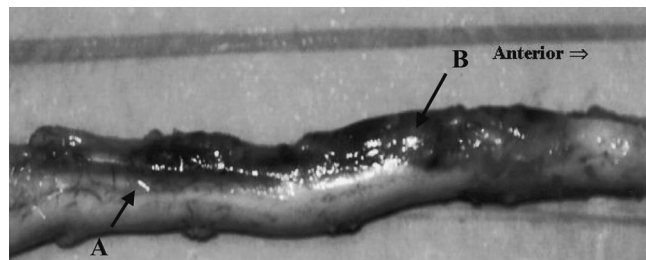
(fig. 6). These changes consisted of mild chronic inflammation and mild spinal cord compression consistent with the mechanical presence of the intrathecal catheter.

In addition to microscopic assessment of spinal cord tissue adjacent to the catheter, tissue 5 cm cranial to the tip of the catheter was also evaluated (table 2). In saline-treated animals, no changes were observed in this area, whereas spinal cord tissue from five morphine-treated sheep displayed chronic inflammation, which involved lymphocytes and plasma cells. Two animals (Nos. 959 and 965) treated with morphine doses of 12 mg/day or greater displayed mild chronic inflammation in this region. Both animals also had catheter-related inflammatory masses. Two animals treated with 9 mg/day morphine displayed mild (No. 949) and moderate (No. 952) chronic inflammation, and one animal (No. 956) treated

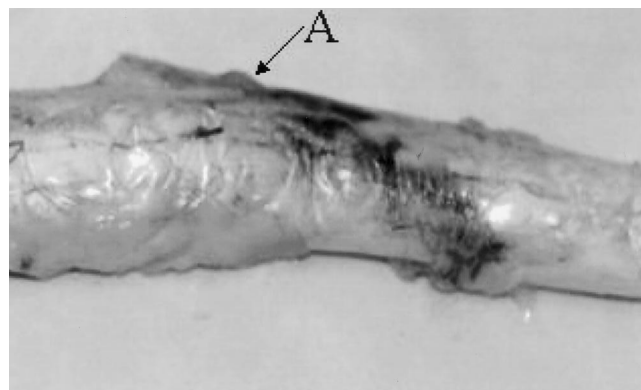
with 6 mg/day displayed mild chronic inflammation 5 cm cranial to the catheter tip. Similar to saline-treated control animals, sheep treated with 3 mg/day morphine exhibited no microscopic changes 5 cm cranial to the tip of the catheter.

#### Clinical Pathologic Study

Analysis of CSF demonstrated a positive correlation between the degree of local spinal cord inflammation and the number of leukocytes and total protein present in the CSF.



**Fig. 2.** Spinal cord from sheep (No. 965) treated with 18 mg/day morphine sulfate, demonstrating an intradural-extramedullary inflammatory mass (A) extending along the length of the intrathecal catheter body (B). The catheter tip is obscured by the inflammatory mass. The dark shade is due to the injection of methylene blue dye.



**Fig. 3.** Representative gross pathologic findings: caudal spinal cord with meninges and distal intrathecal catheter *in situ*. Spinal cord from sheep (No. 954) treated with 18 mg/day morphine sulfate but demonstrating normal spinal cord appearance. After death, methylene blue (dark area) was injected to identify the catheter tip. The catheter tip (A) is visible beneath the meninges with dye freely flowing from the end hole of the catheter.

**Table 2. Summary of Pathologic Findings**

SHEEP No. and Dose	Gross Observations*	Microscopic Observations of Inflammation		
		5 cm Cranial to Catheter Tip	Catheter Tip	Mid Catheter
Control				
960	—	—	Chronic+	Chronic+
943	—	—	Chronic+, compression+	Chronic+, compression+
950	—	—	—	Chronic+, compression+
3 mg/day				
941	±	—	Chronic+, compression+	Chronic+
962	—	—	Chronic+, compression+	Chronic+
953	—	—	—	—
6 mg/day				
956	—	Chronic+	Chronic+	Chronic+, compression+
966	—	—	—	Chronic+, compression+
818	—	—	Chronic+, compression+	Chronic+, compression+
9 mg/day				
963	—	—	Chronic+, compression+	Chronic+, compression+
949	—	Chronic+	Chronic+, compression+	Chronic+, compression+
952	—	Chronic++	Chronic+, compression+	Chronic+, compression+
12 mg/day				
820	Present	—	Acute+++, chronic+++, compression+++	Acute+, chronic++, compression+
959	Present	Chronic+	Acute+++, chronic+++, compression+++	Acute+, chronic++, compression+
946	—	—	Chronic+	Chronic+, compression+
18 mg/day				
954	—	—	Chronic+	Chronic+
957	Present	—	Acute+++, chronic+++, compression+++	Acute+, chronic++, compression+
965	Present	Chronic+	Acute+++, chronic+++, compression+++	Acute+, chronic++, compression++

\* Catheter area inflammation (inflammatory mass).

+ = Present or mild; — = absent; ++ = moderate; +++ = severe; +/- = equivocal; acute and chronic refer to the type of inflammatory process that was present.

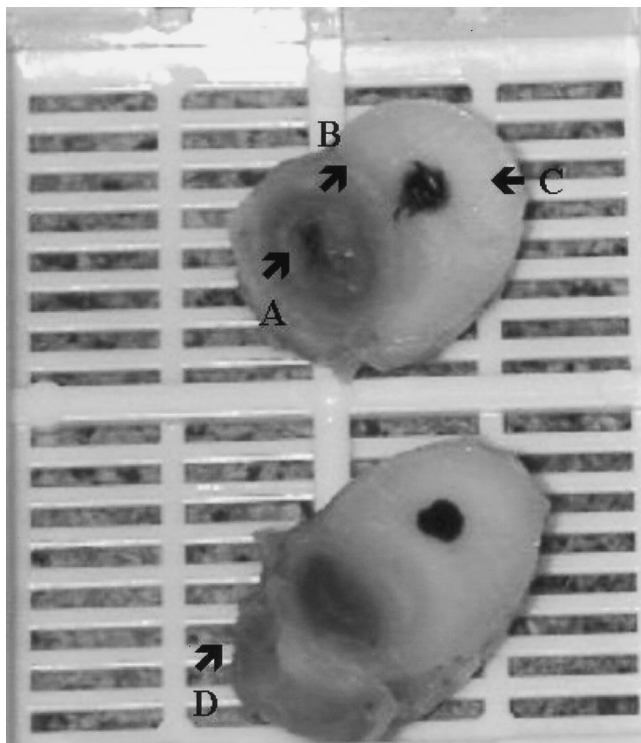
All four sheep that exhibited inflammatory masses had elevated leukocyte counts (18 mg/day, baseline leukocyte counts  $1.33 \pm 0.58$  vs.  $602.67 \pm 882.76$  cells/ $\mu$ l at necropsy, and 12 mg/day, baseline leukocyte counts  $0.67 \pm 0.58$  vs.  $126.33 \pm 190.24$  cells/ $\mu$ l at necropsy, compared to saline control, baseline leukocyte counts  $1.00 \pm 1.00$  vs.  $10.67 \pm 7.23$  cells/ $\mu$ l at necropsy), and three had an increased total protein (18 mg/day, baseline total protein counts  $36.33 \pm 17.93$  vs.  $262.67 \pm 324.72$  cells/ $\mu$ l at necropsy, and 12 mg/day, baseline total protein counts  $39.67 \pm 18.45$  vs.  $99.00 \pm 116.91$  cells/ $\mu$ l at necropsy, compared to saline control, baseline total protein counts  $30.67 \pm 10.79$  vs.  $36 \pm 13$  cells/ $\mu$ l at necropsy). Special stains (Gram, periodic acid-Schiff, and Grocott modification of Gomori methenamine silver stains) revealed no bacteria or fungi in selected spinal cord sections from sheep with inflammatory masses.

#### Toxicokinetics

In animals that did not develop catheter-tip inflammatory masses, the amount of morphine measured in cis-

ternal CSF correlated positively ( $R^2 = 0.9897$ ) with the daily dose of morphine sulfate that was infused into the lumbar subarachnoid space (fig. 1, B). Morphine concentrations measured in cisternal CSF were much less in animals with inflammatory masses compared to unaffected animals in the same dose groups. The two animals exhibiting inflammatory masses in each of the 12- and 18-mg/day dose groups had cisternal morphine concentrations less than 30 ng/ml, whereas the unaffected animal in each group had cisternal morphine concentrations greater than 4,000 ng/ml (table 1). Sheep with inflammatory masses also had lumbar CSF collected *via* dural puncture (caudal to the catheter tip). Sheep Nos. 820, 959 (12 mg/day), and 957 (18 mg/day) had lumbar CSF morphine concentrations of 609, 439, and 380 ng/ml, respectively. The lumbar CSF sample was consumed before the morphine concentration could be determined for the fourth sheep.


Similar to animals treated with morphine doses of 12 mg/day or greater, sheep receiving 9 mg/day had cisternal CSF morphine concentrations, which corre-



**Fig. 4.** Representative gross pathologic findings: transected spinal cord segments taken from the catheter tip (*upper section*) and mid-catheter regions of sheep (No. 965) treated with 18 mg/day morphine sulfate. (A) Near the tip of the catheter, the inflammatory mass is slightly smaller in diameter than the spinal cord and has a necrotic central lumen. (B) The arrow indicates the degree of spinal cord compression by the mass (30–40%). (C) The black dots indicated by the right arrow within the spinal cord parenchyma are orientation markers. (D) The mid-catheter inflammatory mass is smaller than near the tip (A) and lacks a prominent necrotic center.

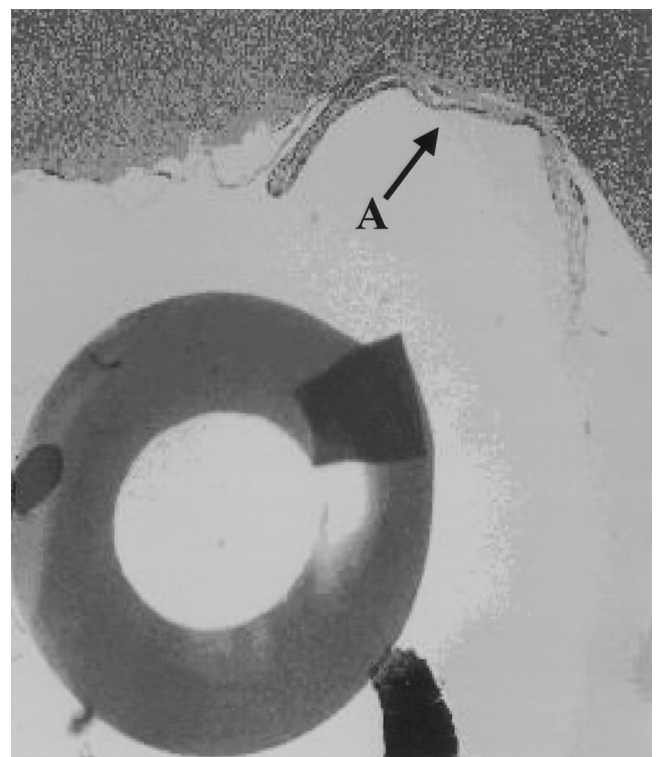
lated with the degree of spinal cord pathologic observations. The sheep (No. 963) with no histologic changes 5 cm cranial to the catheter tip had the highest cisternal morphine concentration (4,524.3 ng/ml), whereas the animal that exhibited the greatest histologic changes (No. 952, moderate chronic inflammation) had the lowest cisternal morphine concentration (1,110.5 ng/ml). The sheep (No. 949) with mild chronic inflammation 5 cm cranial to the catheter tip had an intermediate cisternal morphine concentration (2,214.8 ng/ml).

Morphine-6-glucuronide, a metabolite formed primarily by hepatic enzymes, was not detected (limit of quantification = 2.50 ng/ml) in any CSF sample including those collected *via* lumbar puncture from the animals with inflammatory masses. Morphine-3-glucuronide was detected in only three cisternal CSF samples (table 1). Two sheep treated with 18 mg/day morphine, both of which exhibited inflammatory masses (Nos. 965 and 957), had cisternal morphine-3-glucuronide concentrations of 19.8 and 5.8 ng/ml. On the contrary, neither animal that exhibited inflammatory mass in the 12-mg/day dose group (Nos. 820 and 959) had measurable metabolites in cisternal CSF. Measurable concentrations of morphine-3-glucuro-



**Fig. 5.** Representative photomicrograph ( $\times 100$ ) of pericatheter spinal cord tissue from sheep (No. 965) treated with 18 mg/day morphine sulfate. (A) The section collected from the mid-catheter region demonstrates prominent inflammatory mass wall. (B) Encircling the catheter and compressing the adjacent spinal cord tissue. The adjacent meninges are inflamed and increased in thickness. (C) Catheter material.

nide (10.06 ng/ml) were only detected in cisternal CSF from one animal (No. 963) that did not have an inflammatory mass. Lumbar CSF samples collected from animals with inflammatory masses also revealed relatively high morphine-3-glucuronide concentrations. In the 18-mg/day dose group, two sheep, Nos. 957 and 965, had concentrations of



**Fig. 6.** Representative photomicrograph ( $\times 100$ ) of pericatheter spinal cord (*top*) tissue from sheep (No. 950) treated with normal saline (control). (A) Mild spinal cord compression.

8.75 and 28.17 ng/ml, respectively. In the 12-mg/day dose group, two sheep, Nos. 959 and 820, had concentrations of 18.07 and 17.69 ng/ml, respectively.

## Discussion

### *Human Studies*

Morphine has long been considered the gold standard of spinally administered opioids because of its duration of action and relative ease of use.<sup>11</sup> Moreover, it is the only opioid the Food and Drug Administration has approved for chronic intraspinal administration. In a study comparing intrathecal morphine with oral opioids, long-term continuous infusion improved relief of nonmalignant pain by up to 74.2% over nearly 6 yr of follow-up.<sup>22</sup> In another study of 40 patients with various forms of benign pain, chronic intrathecal opioid treatment provided successful long-term pain relief in 41–50% of patients.<sup>23</sup> In a study of 26 patients with chronic low back or leg pain, intrathecal morphine infusion provided pain relief for up to 27 months (length of study) in 59% of the patients.<sup>24</sup> Although these studies used intrathecal morphine doses ranging from 0.3 to 25 mg/day, the majority of patients received between 2.7 and 5.4 mg/day.

As the use of chronic intrathecal morphine infusion has increased, however, so have reports of complications including the development of inflammatory masses at the catheter tips of patients receiving high doses of intrathecal morphine.<sup>20,21</sup> In response, this study was conducted to determine the safety of intrathecal morphine administration in a sheep model. The sheep model provides several advantages for investigating intraspinal drug toxicity. Because of the size of the animal, the entire clinically relevant delivery system can be implanted, including the silicone catheter. In addition, the spinal subarachnoid space and CSF volume of sheep more closely approximate those of humans as compared to smaller animal models, such as rats and dogs, making toxicokinetics more clinically relevant.

### *Sheep Studies*

The sheep in this study responded to intrathecal morphine in a dose-dependent manner. All the sheep in the high-dose groups (12 and 18 mg/day) exhibited frank pain behavior as evidenced by biting and pulling wool over the caudal lumbar area. This pain phenomenon observed on initiation of high-dose, intrathecal morphine treatment has been previously described in rats given high doses (150  $\mu$ g, 50 mg/ml) of intrathecal morphine and involved intermittent bouts of biting and scratching in the area proximal to the catheter tip.<sup>25</sup> A similar but less intense behavior of scratching and/or biting has been reported in dogs (non-dose dependent) and cats (at high doses only).<sup>26,27</sup> Although the authors of the canine study postulated that this behavior parallels

the clinically known side effect of pruritus, the mechanism of this reaction induced by high-dose morphine is not well understood. Intrathecal morphine infusion at doses of 12 and 18 mg/day for 1 month produced inflammatory masses in the sheep model. These masses extended from the catheter tip down the length of the catheter body present within the subarachnoid space and caused spinal cord compression in two of the three animals in each dose group. Unilateral hind-leg lameness was present on the side corresponding to the location of the mass. These intrathecal morphine doses (12 and 18 mg/day) in sheep are equivalent to 36 and 54 mg/day, respectively, in humans. This dose conversion from sheep to humans is based on the following: The steady state concentration of a drug in a biologic fluid compartment is equal to the dosing rate divided by the efflux clearance. The hydrophilic molecule, morphine, is cleared from the subarachnoid compartment by bulk CSF clearance. Therefore, approximate interspecies dose-scaling factors are derived by comparing bulk CSF clearance (or formation) rates. The sheep CSF clearance rate is approximately 7.2 ml/h, and the human value is approximately 21 ml/h. Therefore, the scaling factor between sheep and humans is approximately 3, *i.e.*, the 12-mg/day sheep dose would be equivalent to a 36-mg/day human exposure.

There was a positive correlation between the degree of local spinal cord inflammation and the number of leukocytes and total protein in the CSF after clinical analysis. This correlation may have clinical implications in the future to detect inflammatory mass formation in patients by aspirating CSF from the side port of the pump and analyzing these samples for increases in leukocytes and total protein concentrations periodically. However, this correlation needs to be further tested in animals and then evaluated clinically to validate the procedure.

In addition to affecting neurologic function *via* spinal cord compression, it is also clear that the inflammatory mass affects the distribution of morphine within the neuraxis. This may explain in part why the development of inflammatory mass in humans is often associated with patient reports of loss of analgesia or rapid or large increases in analgesic doses needed for pain control.<sup>21</sup> The animals with inflammatory masses had marked reductions in cisternal morphine concentrations as compared to unaffected animals in the same dose group. On the contrary, the one animal in the highest dose group unaffected with inflammatory mass experienced seizure-like behavior on two occasions, most likely related to the high supraspinal morphine concentrations (4,785.3 ng/ml in cisternal CSF). Seizures in response to high-dose morphine have been described in humans.<sup>28–30</sup> The lumbar CSF morphine concentrations from animals with inflammatory mass were much lower (<7 times) than the cisternal concentrations measured in unaffected animals in the same dose groups. This suggests that inflammatory mass is reduc-



ing CSF distribution of morphine even within the lumbar region of the cord.

Cerebrospinal fluid was analyzed for the presence of the metabolites, morphine-6-glucuronide and morphine-3-glucuronide, to determine whether these metabolites may contribute the formation of inflammatory masses. Morphine-6-glucuronide was not detected in any CSF sample (limit of quantification was 2.5 ng/ml). A trend was seen in the concentration of morphine-3-glucuronide in cisternal and lumbar CSF samples in both of the sheep receiving 18 mg/day that exhibited inflammatory masses at necropsy. Sheep 965 had lumbar concentrations of morphine-3-glucuronide of 28.1 ng/ml and a cisternal concentration of 19.8 ng/ml. Sheep 957 had lumbar concentrations of morphine-3-glucuronide of 8.8 ng/ml and cisternal concentration of 5.8 ng/ml (table 1). The significance of these findings is unclear because the animals receiving 12 mg/day, which exhibited inflammatory masses at necropsy, did not have measurable metabolites in cisternal CSF. To further complicate the significance of the concentration of morphine-3-glucuronide in CSF, sheep 963 (9 mg/day), which did not have an inflammatory mass, had a morphine-3-glucuronide concentration of 10.06 ng/ml. The histologic changes at the catheter tip and mid-catheter areas for this animal were identical to the other sheep in this group receiving 9 mg/day. To determine the significance of morphine-3-glucuronide and its relationship to the formation of inflammatory masses, further investigation is needed.

Histologic evaluation of the sheep receiving doses of 12 mg/day or more that exhibited inflammatory masses at necropsy revealed both acute and chronic inflammation. These animals exhibited severe acute and chronic inflammation at the catheter tip and mild acute and moderate chronic inflammation in the mid-catheter areas. The sheep receiving morphine doses of 9 mg/day or less did not reveal any acute inflammation; only chronic inflammation was seen in these animals (table 2).

### *Etiology*

Although inflammatory masses observed in sheep exposed to high doses and/or concentrations of intrathecal morphine infusion may represent a pathologic finding similar to that observed clinically in pain patients, the masses observed in animals differ from their clinical counterparts in at least two important aspects: morphology and rate of growth. Inflammatory masses reported in humans have been described by North *et al.* and others<sup>31-33</sup> as being present at the catheter tip only and extending some distance cephalad in the subarachnoid space. On the contrary, masses observed in sheep involved the catheter tip predominantly but also the entire length of the catheter body present within the subarachnoid space. It is likely that in the sheep model, once the catheter tip was occluded, the infusate preferentially flowed back along the length of the catheter, producing

further inflammatory mass formation. This may be a more common morphology in animals in part because of a smaller intrathecal space and greater likelihood of restricted cranial CSF flow as a result of the increasing mass. However, in a case report, Langsam<sup>34</sup> describes the surgical dissection of an inflammatory mass from the catheter tip caudally along the catheter length to its subcutaneous lumbar spine insertion site. This description is identical to what was seen in the sheep, although the clinical significance of this finding is unclear. Similar to the inflammatory masses at the catheter tip reported in humans, local inflammation may also occur in areas cephalad to the catheter tip as evidenced in the five sheep that exhibited mild-to-moderate inflammation 5 cm cranial to the catheter tip.

Another important distinction between the inflammatory masses observed in sheep and those reported rarely in humans is the apparent rate of growth of these lesions as evidenced by the onset of clinical signs after the initiation of the infusion. In our studies, some sheep began showing clinical signs of spinal cord compression, *i.e.*, lameness, as early as 1 week after initiating the morphine infusion. All four affected animals showed obvious signs of lameness by 2 weeks. On the contrary, the diagnosis of inflammatory mass in humans has only rarely been made less than 6 months after initiating therapy.<sup>21</sup> As previously mentioned, this may reflect in part the smaller size of the ovine subarachnoid space. Although the high incidence and rapid onset of inflammatory masses in sheep may not allow for a direct calculation of the safety of spinal morphine in humans, the model allows for a worst-case approximation of what might be expected clinically. Another important distinction is the way in which the opioid is administered. The opioid-naïve sheep in this study that developed inflammatory masses were immediately started on a high dose of morphine. In humans, the intrathecal dose of morphine is typically initiated as low as possible (approximately 1-2 mg/day) and titrated over time as need to maintain analgesia. Moreover, the intrathecal route is used clinically only after less invasive routes of opioid administration have proven ineffective (*i.e.*, in general, pain patients initiated on intrathecal infusion are not opioid naïve).

The association of the inflammatory mass with the catheter tip (and catheter body in the sheep model) has led to speculation that this inflammatory process may represent a reaction to the catheter material rather than the infusate. The current findings suggest that this is unlikely. None of the saline-treated animals developed an inflammatory mass. Morphine-treated animals developed an inflammatory response, which was dependent on the amount of morphine infused. The widest area of the inflammatory mass for three of the four affected animals was at the catheter tip, the location of the single hole through which the infusate enters the subarachnoid

space. Five animals treated with morphine (6–18 mg/day) had evidence of mild-to-moderate chronic inflammation 5 cm cranial to the tip of the catheter, which was not observed in sheep treated with saline or low-dose morphine (3 mg/day).

Differences in the reaction to spinal administration of morphine within the dosing groups may be due to inter-individual variation in CSF volume, amount of CSF flow in the area of the catheter tip, size of the intrathecal space, reactivity toward morphine, or subtleties in catheter-tip position such as the distance between the catheter tip and specific spinal anatomical structures (e.g., cord, meninges, nerve roots). No correlation was found between the presence of inflammation and the circumferential location of the catheter tip in relation to the spinal cord. In the four sheep affected with inflammatory masses, two catheters resided on the ventral side of the cord, one left of the ventral midline and the other right of the ventral midline, whereas the remaining two resided laterally on the right side of the spinal cord. In the two animals treated with morphine doses of 12 mg/day or greater that did not develop inflammatory masses, one catheter tip was positioned left of the dorsal midline and the other on the left lateral side.

The mechanisms by which morphine induces the formation of inflammatory masses are not clear. Inflammatory masses of similar composition (i.e., “granulomas”) have been described in sheep infused for 1 month with epidural morphine and hydromorphone.<sup>35,36</sup> It has been demonstrated *in vitro* using cultured human lymphocytes that morphine stimulates lymphocyte proliferation and mitogen-activated protein kinases by activating  $\mu$ -opioid receptors.<sup>37,38</sup> *In vivo* studies in opioid-naive, nonhuman primates also suggest that morphine may activate quiescent lymphocytes for proliferation.<sup>39</sup> It is interesting to note that the opioid-induced epidural “granulomas” in sheep reported by Coombs *et al.* were described as having “lymphoid proliferation to the point of germinal center formation.”<sup>36</sup> Although both morphine and hydromorphone,  $\mu$ -opioid receptor agonists, induced “granulomas” when infused into the epidural space of sheep, it is not known whether other opioids besides morphine sulfate lead to inflammatory mass within the intrathecal space in sheep. In humans, chronically placed epidural catheters regardless of the infusate are often associated with pericatheter fibrosis, which is seldom seen with catheters placed intrathecally. Although inflammatory masses have been reported in humans receiving continuous hydromorphone infusions, many of these patients were receiving morphine before being switched over to the more potent  $\mu$  agonist.<sup>21</sup>

Although intrathecal morphine at 6 and 9 mg/day may be safe in the sheep model, mild-to-moderate inflammation cranial to the catheter tip was observed in some animals treated at these doses. These histologic changes were not associated with clinical signs and were not

observed in saline or 3 mg/day morphine-treated sheep. These changes were observed after approximately 1 month of morphine infusion. The clinical outcome of longer-term infusions in this model is not certain.

Because of the design of the current study (i.e., infusion rate held constant with concentration adjusted to give the appropriate daily dose), it is not possible to draw conclusions about whether the observed toxicologic effects were related to the daily morphine dose, to the concentration of morphine infused, or to a combination of both variables. Because inflammatory mass represents a local toxicity in a biologic fluid compartment, which is not well mixed, it is reasonable to suggest that the concentration of the infusate may be an important factor in this toxicologic process. Sheep treated with 12–18 mg/day were exposed to morphine concentrations of only 6.25 and 9.38 mg/ml, respectively. In clinical practice, physicians often use concentrations between 25 and 50 mg/ml to increase the interval between pump refills.

In summary, these data demonstrate that morphine sulfate properly formulated for intrathecal administration may induce the formation of intradural-extramedullary inflammatory masses of sufficient size to produce spinal cord compression in the sheep model. The formation of inflammatory mass is dependent on the amount of morphine infused. Doses of 12 mg/day or greater delivered in a volume of approximately 2 ml/day resulted in morphine-related inflammatory masses in some but not all sheep after approximately 1 month of infusion. Morphine at doses of 3 mg/day produced no clinical signs and spinal histologic changes that were equivalent to those observed in saline-treated animals. Intermediate morphine doses (6–9 mg/day) produced no clinical signs but did produce mild-to-moderate chronic inflammation cephalad to the tip of the catheter in some animals.

The authors thank Russell Schmidt, B.S., M.T. (A.S.C.P.) (Senior Research Technologist), Kyle Voelker, B.S. (Large Animal Section Supervisor), Troy King, A.L.A.T. (Animal Technician D), Gerald Costello, B.S., H.T. (A.S.C.P.) (Senior Research Histology Technician), and Don Hudson, B.S. (Animal Technologist, The University of Texas M. D. Anderson Cancer Center, Department of Veterinary Sciences, Bastrop, Texas), for expert technical assistance in performing the study. They also thank Medtronic Neurological, Inc. (Minneapolis, Minnesota) for support and technical assistance.

## References

1. Matsuki A: Nothing new under the sun: A Japanese pioneer in the clinical use of intrathecal morphine. *ANESTHESIOLOGY* 1983; 58:289–90
2. Alper MH: Intrathecal morphine: A new method of obstetric analgesia. *ANESTHESIOLOGY* 1979; 51:378–9
3. Onofrio BM, Yaksh TL, Arnold PG: Continuous low-dose intrathecal morphine administration in the treatment of chronic pain of malignant origin. *Mayo Clin Proc* 1981; 56:516–20
4. Onofrio BM, Yaksh TL: Long term pain relief produced by intrathecal morphine infusion in 53 patients. *J Neurosurg* 1990; 72:200–9
5. Spaziant R, Cappabianca P, Ferone A, Craus W, de'Santi MS, de Divitiis E: The treatment of chronic cancer pain by means of continuous intrathecal low dose morphine administration with a totally implantable subcutaneous pump: Case report. *J Neurol Sci* 1985; 29:143–51

6. Shetter AG, Hadley MN, Wilkinson E: Administration of intraspinal morphine for the treatment of intractable cancer pain. *Neurosurgery* 1986; 18:740-7
7. Penn RD, Paice JA, Gottschalk W: Cancer pain relief using chronic morphine infusion: Early experience with a programmable implanted drug pump. *J Neurosurg* 1984; 61:302-6
8. Krames ES, Gershow J, Glassberg A, Kenefick T, Lyons A, Taylor P, Wilkie D: Continuous infusion of spinally administered narcotics for the relief of pain due to malignant disorders. *Cancer* 1985; 56:696-702
9. Hassenbusch SJ, Pillay PK, Magdinec M, Currie K, Bay JW, Covington EC, Tomaszewski MZ: Constant infusion of morphine for intractable cancer pain using an implanted pump. *J Neurosurg* 1990; 73:405-9
10. Coombs DW, Saunders RL, Gaylor MS, Block AR, Colton T, Harbaugh R, Pageu MG, Mroz W: Relief of continuous chronic pain by intrathecal narcotics infusion via an implanted reservoir. *JAMA* 1983; 250:2336-9
11. Krames ES: Intraspinal opioid therapy for chronic nonmalignant pain: Current practice and clinical guidelines (review). *J Pain Symptom Manage* 1996; 11:333-52
12. de Lissoyov G, Brown RE, Halpern M, Hassenbusch SJ, Ross E: Cost-effectiveness of long-term intrathecal morphine therapy for pain associated with failed back surgery syndrome. *Clin Ther* 1997; 19:96-112
13. Hassenbusch SJ: Epidural and subarachnoid administration of opioids for nonmalignant pain: Technical issues, current approaches and novel treatments (review). *J Pain Symptom Manage* 1996; 11:357-62
14. Hassenbusch SJ, Stanton-Hicks M, Covington EC: Spinal cord stimulation versus spinal infusion for low back and leg pain. *Acta Neurochir Suppl* 1995; 64:109-15
15. Krames ES, Lanning RM: Intrathecal infusional analgesia for nonmalignant pain: Analgesic efficacy of intrathecal opioid with or without bupivacaine. *J Pain Symptom Manage* 1993; 8:539-48
16. Kroin JS: Intrathecal drug administration. *Clin Pharmacokinet* 1992; 22:319-26
17. Bijjani GK, Karim NO, Tzortzidis F: Intrathecal granuloma after implantation of a morphine pump: Case report and review of the literature. *Surg Neurol* 1997; 48:288-91
18. Anderson SR, Orbegozo, M, Racz G, Raj PP: Intrathecal granuloma in patients receiving high-dose intrathecal morphine therapy: A report of two cases. *Pain Practice* 2001; 1:61-7
19. Langsam A: Spinal cord compression by catheter granulomas in high-dose intrathecal morphine therapy: Case report. *Neurosurgery* 1999; 44:689-91
20. Schuchard M, Lanning R, North R, Reig E, Krames E: Neurologic sequelae of intraspinal drug delivery systems: Results of a survey of American implanters of implantable drug delivery systems. *Neuromodulation* 1998; 1:137-48
21. Coffey R, Burchiel K: Inflammatory mass lesions associated with intrathecal drug infusion catheters: Report and observations on 41 cases. *Neurosurgery* 2002; 50:78-87
22. Winkelmueller M, Winkelmueller W: Long-term effects of continuous intrathecal opioid treatment in chronic pain of nonmalignant etiology. *J Neurosurg* 1996; 85:458-67
23. Anderson V, Burchiel K: A prospective study of long-term intrathecal morphine in the management of chronic nonmalignant pain. *Neurosurgery* 1999; 44:289-300
24. Tutak U, Doleys D: Intrathecal infusion systems for treatment of chronic low back and leg pain of noncancer origin. *Southern Med J* 1996; 89:295-300
25. Yaksh T, Harty G, Onofrio B: High doses of spinal morphine produce a nonopioid receptor mediated hyperesthesia: Clinical and theoretic implications. *ANESTHESIOLOGY* 1986; 64:590-7
26. Sabbe M, Grafe M, Mjanger E, Tiseo P, Hill H, Yaksh T: Spinal delivery of sufentanil, alfentanil, and morphine in dogs. *ANESTHESIOLOGY* 1994; 81:899-20
27. Yaksh T, Noueihed R, Durant P: Studies of the pharmacology and pathology of intrathecally administered 4-anilinopiperidine analogues and morphine in the rat and cat. *ANESTHESIOLOGY* 1986; 64:54-66
28. Landow L: An apparent seizure following inadvertent intrathecal morphine. *ANESTHESIOLOGY* 1985; 62:545-6
29. Groudine S, Cresanti-Daknis C, Lumb P: Successful treatment of a massive intrathecal morphine overdose. *ANESTHESIOLOGY* 1995; 82:292-5
30. Kronenberg M, Laimer I, Rifici C, Saltrari L, Bramanti P, Moriggi U, Norer B, Kofler A: Epileptic seizure associated with intracerebroventricular and intrathecal morphine bolus. *Pain* 1998; 75:383-7
31. Cabbell K, Taren J, Sagher O: Spinal cord compression by catheter granulomas in high-dose intrathecal morphine therapy: Case report. *Neurosurgery* 1998; 42:1176-80
32. Blount J, Remley K, Yue S, Erickson D: Intrathecal granuloma complicating chronic spinal infusion of morphine: Report of three cases. *J Neurosurg* 1996; 84:272-6
33. North R, Cutchis P, Epstein J, Long D: Spinal cord compression complicating subarachnoid infusion of morphine: Case report and laboratory experience. *Neurosurgery* 1991; 29:778-84
34. Langsam A: A case of spinal cord compression syndrome by a fibrotic mass presenting in a patient with an intrathecal pain management pump system. *Pain* 1999; 83:97-9
35. Rawal N, Nuutinen L, Raj P, Lovering S, Gobuty A, Hargardine J, Lehmkuhl L, Herva R, Abouleish E: Behavioral and histopathologic effects following intrathecal administration of butorphanol, sufentanil, and nalbuphine in sheep. *ANESTHESIOLOGY* 1991; 75:1025-34
36. Coombs D, Colburn R, DeLeo J, Hoopes P, Twitchell B: Comparative spinal neuropathology of hydromorphone and morphine after 9- and 30-day epidural administration in sheep. *Anesth Analg* 1994; 78:674-81
37. Bidlack J, Hemmick L: Morphine enhancement of mitogen-induced T-cell proliferation. *Prog Clin Biol Res* 1990; 328:405-8
38. Chuang L, Killam K, Chuang R: Induction and activation of mitogen-activated protein kinases of human lymphocytes as one of the signaling pathways of the immunomodulatory effects of morphine sulfate. *J Biol Chem* 1997; 272:26815-17
39. Chuang L, Killam K, Chuang R: Opioid dependency and T-helper cell functions in rhesus monkey. *In Vivo* 1993; 7:159-66