

Brachial Plexus Examination and Localization Using Ultrasound and Electrical Stimulation

A Volunteer Study

Anahi Perlas, M.D.,* Vincent W. S. Chan, M.D.,† Martin Simons, M.D.‡

Background: Current techniques of brachial plexus block are “blind,” and nerve localization can be frustrating and time consuming. Previous studies on ultrasound-assisted brachial plexus blocks are mostly performed with scanning probes of 10 MHz or less. The authors tested the usefulness of a state-of-the-art, high-resolution ultrasound probe (up to 12 MHz) in identifying the brachial plexus in five locations of the upper extremity and in guiding needle advancement to target before nerve stimulation.

Methods: In this prospective observational study, 15 volunteers underwent brachial plexus examination using an L12-L5 MHz probe and a Philips-ATL 5000 ultrasound unit in the interscalene, supraclavicular, infraclavicular, axillary, and midhumeral regions. Thereafter, an insulated block needle was advanced under direct ultrasound guidance to target nerves before confirmation by electrical nerve stimulation in five volunteers in each of the interscalene, supraclavicular, and axillary regions. The quality of brachial plexus images, anatomic variations, and the technique of needle advancement for nerve localization were recorded.

Results: The brachial plexus components were successfully identified in the transverse view as round to oval hypochoic structures with small internal punctuate echos in all regions examined except the infraclavicular area (visualized in 27% of the cases). The authors’ technique of advancing the needle in-line with the ultrasound beam allowed moment-by-moment observation of the needle shaft and tip movement at the time of nerve localization. Hypochoic structures were stimulated electrically and confirmed to be nerves.

Conclusions: These preliminary data show that the high-resolution L12-L5 probe provides good quality brachial plexus ultrasound images in the superficial locations *i.e.*, the interscalene, supraclavicular, axillary, and midhumeral regions. The needle technique described here for ultrasound-assisted nerve localization provides real-time guidance and is potentially valuable for brachial plexus blocks.

BRACHIAL plexus block is indicated for upper extremity surgery, and many techniques are available. The key to success depends on the accuracy of needle placement, nerve localization, and local anesthetic injection. Current techniques of nerve localization rely on surface anatomic landmarks for estimating brachial plexus location. However, at the time of needle insertion, the search for target nerves remains “blind”; thus, nerve localization can be frustrating and time consuming. Most often, block failures result from imprecise needle placement, and even in experienced hands, the failure rate can be as high as 10–15%.¹

Blind techniques can also cause complications, patient discomfort, and long procedure times. Although infrequent, direct or indirect needle injury may cause serious complications such as nerve damage,² spinal cord injury (with interscalene block³), pneumothorax (with the supraclavicular approach⁴), vascular puncture,⁵ and systemic local anesthetic toxic reactions.⁶ Complications aside, the trial-and-error approach to nerve localization often requires multiple needle attempts, leading to patient anxiety and operating room delay.

In recent years, there has been growing interest in the development of image-guided brachial plexus blocks. Both magnetic resonance imaging⁷ and computed tomographic scanning⁸ provide excellent anatomic images of the brachial plexus, but they are expensive and inaccessible to the operating room. Fluoroscopy is another option,^{9,10} but its usefulness is limited to visualization of bony landmarks and contrast dye spread near to the neurovascular bundle within the plexus sheath. Ultrasound, on the other hand, is noninvasive, portable, and moderately priced.

This real-time imaging technology can aid in brachial plexus blocks in the interscalene,¹¹ supraclavicular,¹² and infraclavicular regions.¹³⁻¹⁵ Most previous ultrasound studies examining brachial plexus anatomy used scanning probes with frequency in the range of 5–10 MHz. Advanced ultrasound technology today offers high-resolution probe (12–15 MHz) and compound imaging. Such new image-enhancing capability allows clear visualization of nerves and can potentially improve the technique of ultrasound-assisted brachial plexus block.

The purposes of the current study are to evaluate the usefulness of a state-of-the-art, high-resolution ultrasound probe in identifying the brachial plexus and evaluate the

This article is accompanied by an Editorial View. Please see: Greher M, Kapral S: Is Regional Anesthesia Simply an Exercise in Applied Sonoanatomy? Aiming at Higher Frequencies of Ultrasonographic Imaging ANESTHESIOLOGY 2003; 99:250-1.

* Resident, † Associate Professor, Department of Anesthesia, ‡ Assistant Professor, Department of Medical Imaging.

Received from the Departments of Anesthesia and Medical Imaging, Toronto Western Hospital, University Health Network, University of Toronto, Toronto, Ontario, Canada. Submitted for publication October 10, 2002. Accepted for publication February 7, 2003. Study equipment support was provided from institutional sources and Philips Medical Systems ATL Ultrasound, Bothell, Washington. Study funding was provided solely from departmental sources.

Address reprint requests to Dr. Chan: Department of Anesthesia, Toronto Western Hospital, University Health Network, 399 Bathurst Street, Toronto, Ontario, Canada M5T 2S8. Address electronic mail to: vincent.chan@uhn.on.ca. Individual article reprints may be purchased through the Journal Web site, www.anesthesiology.org.

feasibility of using real-time ultrasound imaging to guide needle advancement and nerve stimulation.

Materials and Methods

After Institutional Review Board approval (Toronto Western Hospital, University Health Network, University of Toronto, Toronto, Ontario, Canada) and written informed consent, 15 healthy volunteers (American Society of Anesthesiologists physical status I or II; aged 31–52 yr; height, 152–185 cm; weight, 56–105 kg; body mass index, 19–36 kg/m²) underwent ultrasound examination of the brachial plexus using a Philips ATL HDI 5000 unit (ATL Ultrasound, Bothell, WA). This unit is equipped with a high-frequency linear 5-cm probe in the 5- to 12-MHz range (L12–L5), which can generate high-resolution images in the near field (*i.e.*, 3–4 cm). Additional features of the ATL HDI 5000 unit include color flow Doppler that differentiates vascular from neural structures and compound imaging that gathers target echos at several angles in real-time and filters echo artifacts during signal processing. Image recording was accomplished with a Sony video printer (Sony, Tokyo, Japan).

When positioned supine, each subject was scanned at five clinically relevant anatomic locations: interscalene, supraclavicular, infraclavicular, axillary, and midhumeral levels. For each location, the subject was positioned per standard textbook description for the block technique.¹⁶ For interscalene and supraclavicular scanning, the head was rotated slightly to the contralateral side and the arm by the side of the body. For infraclavicular scanning, the head was in neutral position and the arm by the side of the body per the coracoid approach.¹⁷ For axillary and midhumeral¹⁸ scanning, the head was in neutral position, and the arm and elbow were abducted and flexed at 90°.

The ultrasound scanhead was positioned and oriented at each location to obtain the best possible transverse view of the brachial plexus (*i.e.*, the ultrasound beam in a plane approximately 90° to the brachial plexus) as shown in figure 1. Thus, the probe was in the axial oblique plane for the interscalene location, coronal-oblique for the supraclavicular location, parasagittal for the infraclavicular location, and transverse to the arm for the axillary and midhumeral locations. The following assessments were made at each anatomic location: the quality of ultrasound brachial plexus images (good image = image of the brachial plexus and its branches that can be clearly and independently identified by two investigators; poor image = one that cannot be identified by one or both investigators); the number of nerves or nerve groups identified; the skin-to-nerve distance (reported as mean ± SD); and identification of neighboring vascular, muscular, and bony structures.

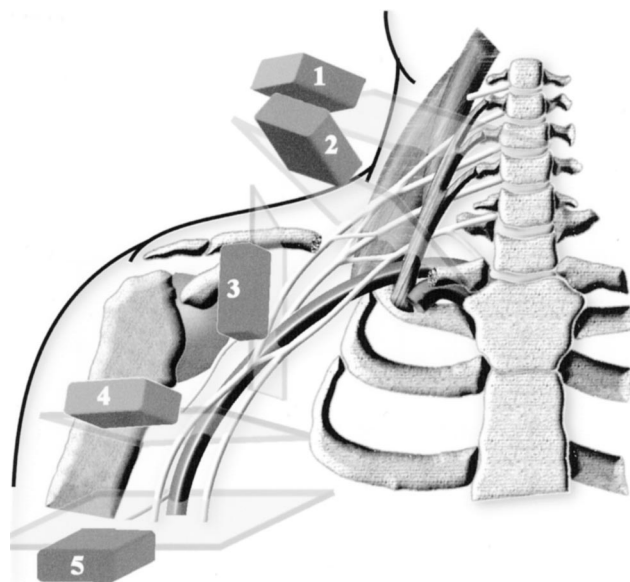


Fig. 1. Ultrasound probe position at five anatomical locations. It is directed in the axial oblique plane for the interscalene location (1), coronal oblique for the supraclavicular location (2), parasagittal for the infraclavicular location (3), transverse for the axillary location (4), and transverse for the midhumeral location (5).

After initial ultrasound scanning, needle insertion for nerve localization and stimulation was performed in five subjects for each of three locations: interscalene, supraclavicular, and axillary. The purpose of electrical stimulation was to interrogate the nature of the presumed neural structures seen on ultrasound and to confirm definitively that they were indeed nerves. The skin was prepared with Betadine solution and 1 ml lidocaine, 1%, was injected at the puncture site. After application of a sterile probe cover and gel and under direct real-time ultrasound imaging guidance, a 2-inch, 22-gauge insulated block needle (Stimuplex; Braun Medical, Bethlehem, PA) was inserted and advanced until it was seen in contact with the target nerve(s). To optimize visualization of the needle shaft, the needle was inserted at the skin on the outer end of the ultrasound probe so that the path of needle advancement would be in-line with and in the same plane as the ultrasound beam. Once the needle was judged in satisfactory position, a nerve stimulator (Stimuplex) was turned on to elicit muscle contraction to a maximum of 1.5 mA. The site of muscle contraction was noted, and the minimum stimulating current was reported as mean ± SD. No local anesthetic was injected.

Results

All subjects successfully completed the study. Ultrasound images of the brachial plexus and its components showed round- to oval-shaped nodular hypoechoic structures (dark images on the monitor) often punctuated

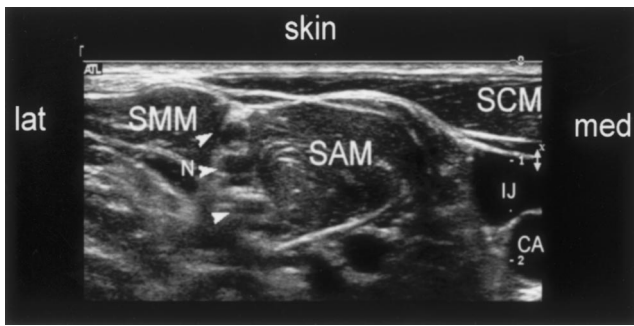


Fig. 2. Transverse sonogram in the interscalene region showing brachial plexus as hypoechoic nodules (N with arrows) interposed between scalenus anterior (SAM) and medius (SMM) muscles, beneath the posterior margin of the sternocleidomastoid muscle (SCM). CA = carotid artery; IJ = internal jugular vein.

with small internal hyperechoic (bright) shadows. When in cluster, the nerves appear as grape-like structures in the transverse view. With the L12-L5 probe, high-quality images of the brachial plexus and its components were obtained in 100% of the subjects at each location with the exception of the infraclavicular location, in which brachial plexus images were obtained in only 27% of cases (4 of 15).

The Interscalene Location

When scanned in the axial oblique plane at this level, the most superficial structure consistently encountered was the sternocleidomastoid muscle. It shaped like a triangle with the apex pointing laterally (fig. 2). Deep to the sternocleidomastoid muscle were the scalenus anterior and medius muscles (scalenus anterior medially and scalenus medius laterally). At the level of the cricoid cartilage (C6), the brachial plexus was consistently found between the scalenus anterior and medius muscles in the interscalene groove as expected. Depending on the angle of the probe, it is most common to identify one to three hypoechoic structures (presumably nerve roots or trunks) at this level. They varied in size and appearance but were consistently superficial; the mean skin-to-nerve distance was 0.9 ± 0.2 cm (mean \pm SD).

When scanned above the cricoid cartilage in the axial plane, the original nerve root(s) could be seen exiting next to the transverse process of the cervical vertebra (fig. 3). The root within the neural foramina could not be seen because of shadowing from bone. When scanned caudad, the original nerve root(s) now moved to a more superficial location. Other structures identified were the carotid artery and internal jugular vein situated anteriorly and medially to the brachial plexus (fig. 2) and occasionally the vertebral artery.

The Supraclavicular Location

When scanned in the coronal oblique plane at this location, the ultrasound images we obtained consistently showed the first rib with the subclavian artery lying

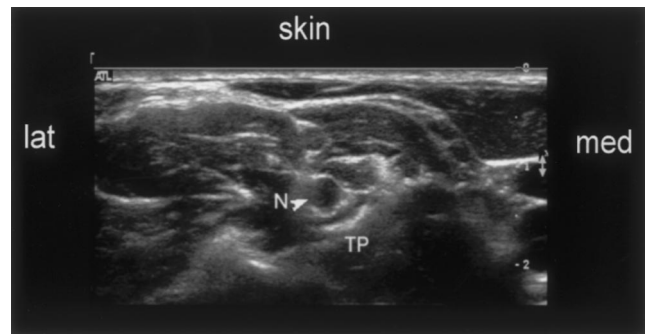


Fig. 3. Transverse sonogram above the C6 level showing brachial plexus hypoechoic nodules (N with arrow) emerging from the cervical transverse process (TP), which blocks the ultrasound beam, casting a dark hypoechoic shadow.

immediately above (fig. 4). In this plane with the ultrasound beam at approximately 90°, the subclavian artery appeared as a round pulsatile hypoechoic structure, and the first rib appeared as a curved linear hyperechoic shadow as depicted in figure 4. The brachial plexus was found consistently in clusters lateral, posterior, and often cephalad to the subclavian artery. Distinct round- to oval-shaped hypoechoic nerve structures (presumably trunks or divisions) were seen varying in number, size, and appearance. The mean skin-to-nerve distance was 0.9 ± 0.3 cm at this level. Scanning more medially showed the subclavian vein and the anterior scalene muscle (fig. 4). Pleura was also hyperechoic and often seen on either side of the first rib. Pleural and lung movement could be observed during respiration.

The Infraclavicular Level

The L12-L5 scanhead was positioned 2 cm medial to the coracoid process for this assessment. In contrast to the other locations, we were able to identify the brachial plexus in the parasagittal plane in only 27% of the cases (4 of 15), and the mean skin-to-nerve distance was 2.0 ± 0.7 cm in these subjects. The brachial plexus (presum-

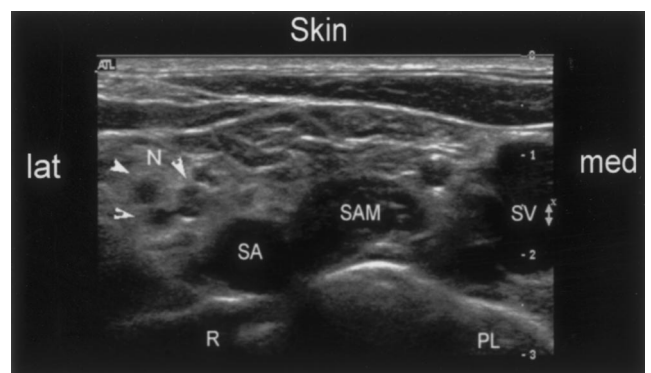


Fig. 4. Transverse sonogram in the supraclavicular region shows brachial plexus as a group of hypoechoic nodules (N with arrows) lateral to subclavian artery (SA) and cephalad to the first rib (R). PL = pleura; SAM = scalenus anterior muscle; SV = subclavian vein.

Downloaded from http://asa2.silverchair.com/anesthesiology/article-pdf/99/2/429/408800/0000542-200308000-00025.pdf by guest on 31 January 2023

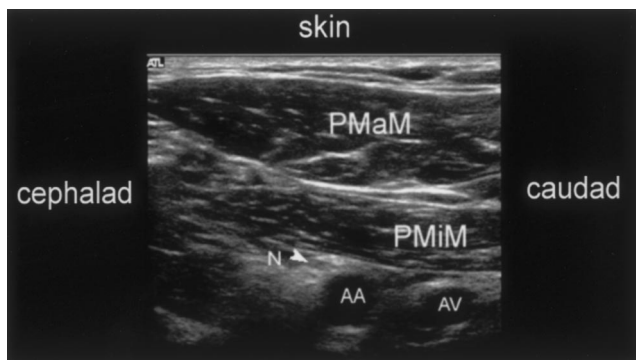


Fig. 5. Transverse sonogram in the infraclavicular region showing brachial plexus as hypoechoic nodules (*N* with arrow). AA = axillary artery; AV = axillary vein; PMaM = pectoralis major muscle; PMiM = pectoralis minor muscle.

ably the cords) in this location was deep to the pectoralis major and minor muscles, in close proximity to the axillary artery and vein (fig. 5). In the remaining 11 subjects, the axillary vessels were not clearly visualized at a depth of 4 cm or more, indicating that the penetration limit of the probe had been reached.

The Axillary Level

When scanned at the axillary fold in an outstretched arm, branches of the brachial plexus were easily identified in close relationship to the axillary artery (often one) and veins (often one to two). Veins were differentiated from artery by their ease of compressibility by the ultrasound probe (fig. 6) and by color flow Doppler. The axillary vein(s) were typically found medial and posterior to the artery and could be anterior to the nerves. Ultrasound images showed three distinct terminal branches of the brachial plexus (median, ulnar, and radial nerves) in 10 of the 15 subjects (67%) but only two in the remaining 5 subjects. The mean skin-to-nerve distance was 0.6 ± 0.3 cm. The location of these nerves was highly variable—most often lateral or medial to the axillary artery (lateral = away from the axilla, medial = toward the axilla) and less often directly anteroposterior to the artery. Other structures identified were the biceps, coracobrachialis, and triceps muscles (fig. 6, A).

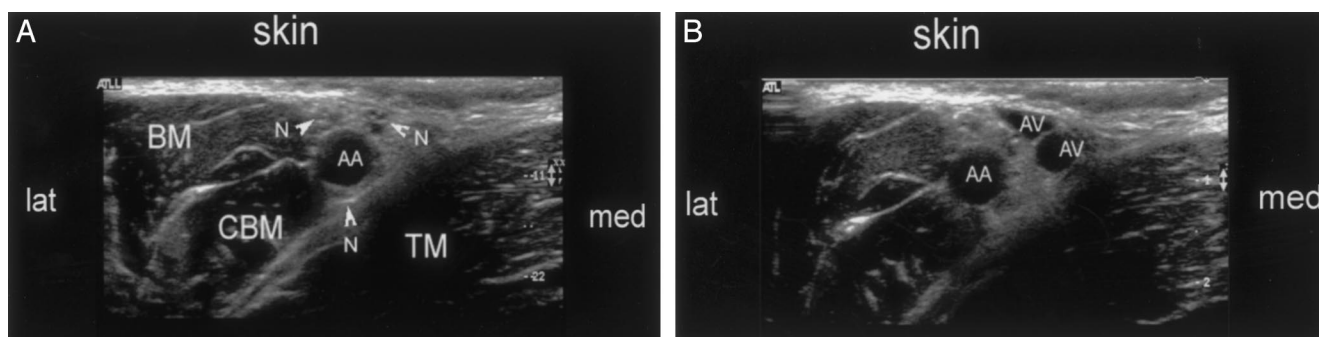


Fig. 6. (A) Transverse sonogram in the axillary region showing three terminal branches of the brachial plexus as hypoechoic nodules (*N* with arrows). AA = axillary artery; BM = biceps muscle; CBM = coracobrachialis muscle; TM = triceps muscle. (B) Transverse sonogram in the axillary region showing axillary veins (AV) without compression.

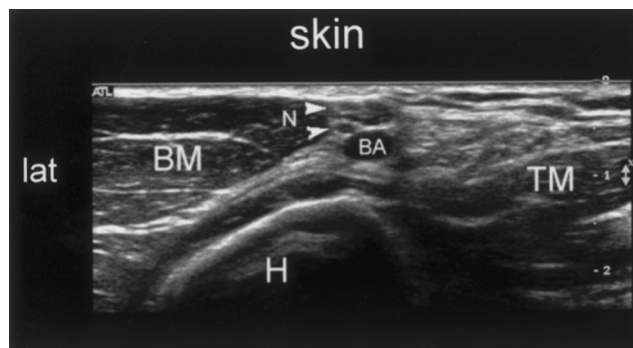

Fig. 7. Transverse sonogram in the midhumeral region showing two terminal branches of the brachial plexus as hypoechoic nodules (*N* with arrows). BA = brachial artery; BM = biceps muscle; H = humerus; TM = triceps muscle.

The Midhumeral Location

The probe was positioned at the junction of the upper and middle third of the outstretched arm. At this level, the ultrasound images consistently identified two nerves, next to the artery (fig. 7). These are presumably the ulnar and median nerves. The mean skin-to-nerve distance was 0.7 ± 0.3 cm. The musculocutaneous and radial nerves were not seen. Other structures identified were the biceps and triceps muscles and the humerus (fig. 7).

Nerve Localization and Stimulation

Under real-time ultrasound guidance, five subjects underwent nerve localization and stimulation successfully for each of the three locations: interscalene, supraclavicular, and axillary (fig. 8, A-C). When the block needle was passed in-line with the ultrasound beam, its shaft was seen as a white linear shadow on the monitor as it approached the target nerve(s) (fig. 8, D-F). When in contact with the hypoechoic nodular structures, electrical stimulation through the needle evoked muscle contraction in all cases, confirming that these structures were indeed nerves. The minimum effective stimulating current was 0.36 ± 0.11 mA. Deltoid and biceps muscle contraction was most often observed when stimulated at the interscalene and supraclavicular locations, whereas

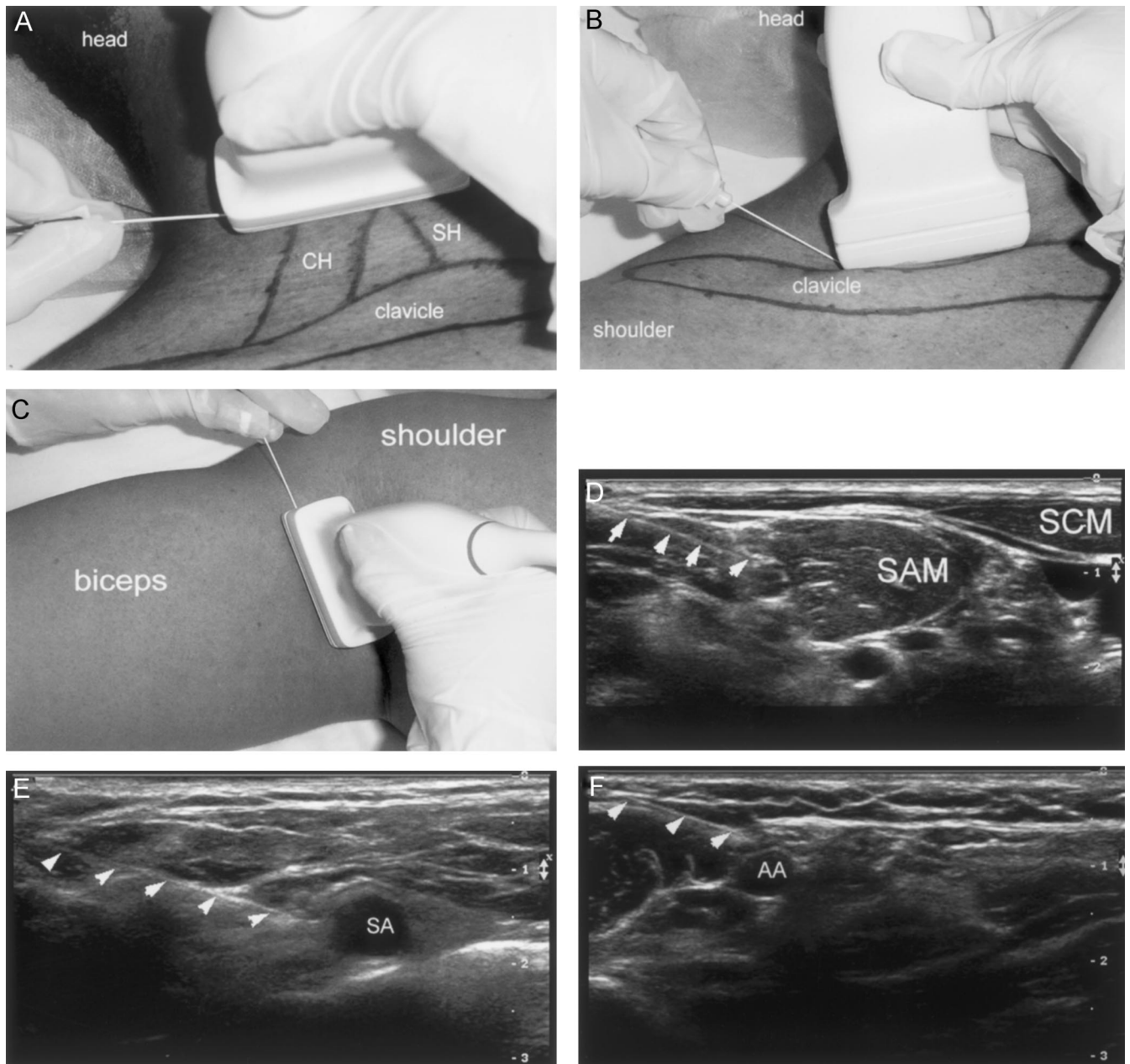


Fig. 8. (A–F) The ultrasound-guided needle advancement technique, showing one hand holding the probe and one hand holding the insulated needle in the interscalene location (A) (CH = clavicular head of sternocleidomastoid muscle; SH = sternal head), the supraclavicular location (B), and the axillary location (C). In all cases, the needle is positioned at one end of the ultrasound probe and passed in-line with the ultrasound beam *i.e.*, in the same plane. Sonogram of the needle (arrows) in contact with the brachial plexus in the interscalene (D), supraclavicular (E), and axillary (F) locations. AA = axillary artery; SA = subclavian artery; SAM = scalenus anterior muscle; SCM = sternocleidomastoid muscle.

hand muscle contraction was noted for the axillary location. No subject reported paresthesia.

We observed that nerves at these three locations were highly mobile. They moved away or to the side when approached by the block needle. Also, when the block needle was judged to be in contact with the target nerve on ultrasound, nerve-stimulated muscle contraction might not happen immediately even with current up to 1.5 mA. To elicit muscle contraction, it was necessary to make a minor adjustment by moving the needle longitudinally along the

course of the nerve in 14% of the cases. It was not necessary to advance the needle further or deeper.

Discussion

Our study has demonstrated that high-frequency ultrasound probing up to 12 MHz can generate clear images of the brachial plexus, visually guide the needle to reach target nerves with precision, and show nerve movement

when the needle makes contact with the nerve. Our preliminary data suggest that it is technically feasible to localize accurately and consistently the brachial plexus at the interscalene, supraclavicular, axillary, and midhumeral locations using high-resolution ultrasound imaging. The ability to visualize depends on the depth of penetration of the ultrasound beam. With the linear L12-L5 MHz probe, we obtain excellent images of the brachial plexus as it is situated superficially (within 1-2 cm from the skin surface) at these four locations. However, its ability to provide superior image resolution in the near field (3-4 cm) is offset by the limited penetration capacity of this probe precluding its usefulness at the infraclavicular coracoid location. To scan deep-seated structures, probes of lower frequency (e.g., in the 4- to 7-MHz range) will be necessary. When it comes to probe selection for brachial plexus scanning, one must find the optimal balance between image quality and depth of penetration.

The use of ultrasound technology for peripheral nerve block has been reported in earlier studies,^{19,20} but many of them are limited to probes of 10 MHz or less. Older technology (< 7 MHz) identifies vascular and bony structures but not nerves. Thus, earlier attempts of ultrasound-assisted brachial plexus block rely on identification of the subclavian or axillary artery, the principal landmark for needle placement. For example, Ootaki *et al.*¹³ performed infraclavicular brachial plexus block guided by a 7-MHz probe. Needle and local anesthetic were placed adjacent to the subclavian artery without visualization of the brachial plexus. Local anesthetic injection generates a ring-shaped shadow around the artery and results in consistent success. With advanced ultrasound technology today, it is now possible to visualize the brachial plexus using high-frequency probes. Our study shows that nerve images are particularly distinct in the interscalene and supraclavicular locations but not the infraclavicular location. Sheppard *et al.*²¹ recommends linear transducers of 7.5 MHz or higher for scanning at the supraclavicular and infraclavicular locations.

Data on ultrasound studies of brachial plexus anatomy are preliminary and limited.^{22,23} When scanned in the transverse section, nerves appear consistently as oval to round hypoechoic shadows in clusters often punctuated with small internal hyperechoic bands (fig. 4). In a study by Silvestri *et al.*²⁴ comparing the histologic structure with ultrasound echotexture of peripheral nerves, the hypoechoic components correspond to neuronal fascicles, and the hyperechoic areas correlate with the connective tissue layers forming the epineurium. Such internal echogenic fascicular pattern is appreciated most often in the trunks and proximal cords and is less apparent at the root level. Compared to nerves, vessels, tendons, and muscles are also hypoechoic, whereas fat and bones are hyperechoic. In the transverse view, small

vessels, lymph nodes, and muscle fascicles can be mistaken for nerves because they have similar size and echogenicity. For this reason, we have decided to use color Doppler and electrical stimulation to interrogate the identity of the hypoechoic shadows, presumably nerves, in the current study.

Our attempts in nerve localization and stimulation were successful in all cases. The technique we chose for needle insertion is unique, unlike any of the techniques taught conventionally. With the ultrasound technique, identification of surface landmarks is not as important. A preliminary scan prior to needle insertion shows distinct anatomic details of the nerves and their neighboring structures. The site we selected for needle puncture was the site with the shortest skin-to-nerve distance. In all cases, we purposely placed the nerve-seeking needle on the outer end of the ultrasound probe and advanced it in a lateral-to-medial direction. The most unique feature of this technique is the alignment of the path of needle advancement with that of the ultrasound beam (fig. 8, A-C). In this case, we are able to see the needle shaft and its tip as a hyperechoic linear shadow on screen and can follow needle movement toward the target nerves (fig. 8, D-F). Guided by the ultrasound images, needle movement is controlled and target specific. Instantaneous feedback provided by real-time imaging guides the angle, depth, and direction of needle penetration so that any improper move is recognized and corrected quickly. It is important to note that there are other ultrasound-guided nerve localization techniques¹⁹ advocating the passage of needle perpendicular to the ultrasound beam. In this case, only indistinct needle movement in the subcutaneous tissue can be observed and not the actual needle shaft.

Dynamic examination of nerves shows that they are mobile structures and they typically move away or to the side when approached by the insulated needle. Conceivably, nerve movement may protect itself from direct needle injury to some extent. However, although relatively blunt-tipped and less likely to impale a nerve, insulated needles have been associated with clinical reports of neurologic damage.²⁵

Under normal brachial plexus block circumstances, firm manual pressure applied on the skin will pin down the nerve (in particular, at the interscalene and axillary locations) and fix it in position before needle insertion. This may decrease nerve mobility and increase the chance of direct needle contact or trauma in some situations. With the ultrasound-guided technique, skin pressure exerted by the probe is probably less than manual palpation allowing a greater degree of nerve mobility. Whether ultrasound-guided brachial plexus block can decrease the risk of nerve injury associated with needle trauma or intraneural injection is not known at this time.

Another interesting finding of the current study is the inconsistency of nerve-stimulated muscle contraction

when the needle is in contact with a nerve in some cases. Despite clear ultrasound evidence of nerve contact in the transverse view, the stimulating needle may not evoke muscle contraction with current up to 1.5 mA. This is surprising. In this situation, it is not necessary to further advance the needle because the needle tip will past the nerve. Rather, fine adjustment by moving the needle tip longitudinally along the course of the nerve (*i.e.*, moving to either side of the transverse plane; refer to fig. 1 for orientation) will eventually evoke muscle contraction. Interestingly, the ultrasound scan shows similar needle-to-nerve contact images in the transverse view before or after muscle contraction. Results of the current study lend support to studies by Choyce *et al.*²⁶ and Urmey and Stanton²⁷ showing the response disparity between paresthesia and nerve-stimulated muscle contraction. A sensory response following needle contact with a nerve may not always be accompanied by a motor response, and this indicates some degree of insensitivity with the nerve stimulation technique for nerve localization. If ultrasound guidance were not provided in the current study, we would have advanced the block needle further in search of muscle contraction not realizing that it has already reached the target.

In summary, state-of-the-art ultrasound technology can provide high-quality images of the brachial plexus and aid nerve localization by guiding needle penetration moment-by-moment to the target nerves. Future studies are required to determine the clinical utility of ultrasound-assisted brachial plexus blocks using high-resolution probes for superficial locations.

References

1. Sia S, Bartoli M, Lepri A, Marchini O: Multiple injection axillary brachial plexus block: A comparison of two methods of nerve localization: nerve stimulation versus paresthesia. *Anesth Analg* 2000; 91:647-51
2. Borgeat A, Ekatothramis G, Kalberer F, Benz C: Acute and nonacute complications associated with interscalene block and shoulder surgery: A prospective study. *ANESTHESIOLOGY* 2001; 95:875-80
3. White JL: Catastrophic complications of interscalene nerve block. *ANESTHESIOLOGY* 2001; 95:1301
4. Brown DL, Cahill DR, Bridenbaugh LD: Supraclavicular nerve block: Anatomic analysis of a method to prevent pneumothorax. *Anesth Analg* 1993; 76:530-4
5. Stan TC, Krantz MA, Solomon DL, Poulos JG, Chaouki K: The incidence of neurovascular complications following axillary brachial plexus block using a transarterial approach: A prospective study of 1,000 consecutive patients. *Reg Anesth* 1995; 20:486-92
6. Dominguez E, Garbaccio MC: Reverse arterial blood flow mediated local anesthetic central nervous system toxicity during axillary brachial plexus block. *ANESTHESIOLOGY* 1999; 91:901-2
7. Wong GY, Brown DL, Miller GM, Cahill DR: Defining the cross-sectional anatomy important to interscalene brachial plexus block with magnetic resonance imaging. *Reg Anesth Pain Med* 1998; 23:77-80
8. Mukherji S, Wagle A, Armao D: Brachial plexus nerve block with CT guidance for regional pain management. *Radiology* 2000; 216:886-90
9. Nishiyama M, Naganuma K, Amaki Y: A new approach for brachial plexus block under fluoroscopic guidance. *Anesth Analg* 1999; 88:91-7
10. Moorthy SS: Fluoroscopic imaging during supraclavicular lateral paravascular brachial plexus block. *Reg Anesth Pain Med* 2000; 25:327-8
11. Yang WT, Chui PT, Metreweli C: Anatomy of the normal brachial plexus revealed by sonography and the role of sonographic guidance in anesthesia of the brachial plexus. *AJR Am J Roentgenol* 1998; 171:1631-6
12. Kapral S, Krafft P, Eibenberger K: Ultrasound-guided supraclavicular approach for regional anesthesia of the brachial plexus. *Anesth Analg* 1994; 78:507-13
13. Ootaki C, Hayashi H, Amano M: Ultrasound-guided infraclavicular brachial plexus block: An alternative technique to anatomical landmark-guided approaches. *Reg Anesth Pain Med* 2000; 25:600-4
14. Sandhu NS, Capan LM: Ultrasound-guided infraclavicular brachial plexus block. *Br J Anaesth* 2002; 89:254-9
15. Sandhu NS, Bahniwal CS, Capan LM: Ultrasound guidance reduces local anesthetic requirement for infraclavicular brachial plexus block (abstract). *ANESTHESIOLOGY* 2001; 95:A851
16. Cousins MJ, Bridenbaugh PO: *Neural blockade, Clinical Anesthesia and Management of Pain*, 3rd edition. Philadelphia, Lippincott-Raven, 1998
17. Wilson JL, Brown DL, Wong GY, Ehman RL, Cahill DR: Infraclavicular brachial plexus block: Parasagittal anatomy important to the coracoid technique. *Anesth Analg* 1998; 87:870-3
18. Bouaziz H, Narchi P, Mercier FJ, Labaille T, Zerrouk N, Girod J, Benhamou D: Comparison between conventional axillary block and a new approach at the midhumeral level. *Anesth Analg* 1997; 84:1058-62
19. De Andres J, Sala-Blanch X: Ultrasound in the practice of brachial plexus anesthesia. *Reg Anesth Pain Med* 2002; 27:77-89
20. Peterson MK, Millar FA, Sheppard DG: Ultrasound-guided nerve blocks. *Br J Anaesth* 2002; 88:621-4
21. Sheppard D, Iyer R, Fernstermacher M: Brachial plexus: Demonstration at ultrasound. *Radiology* 1998; 208:402-6
22. Retzl G, Kapral S, Greher M, Mauritz W: Ultrasonographic findings of the axillary part of the brachial plexus. *Anesth Analg* 2001; 92:1271-5
23. Greher M, Retzl G, Niel P, Kamolz L, Marhofer P, Kapral S: Ultrasonographic assessment of topographic anatomy in volunteers suggests a modification of the infraclavicular vertical brachial plexus block. *Br J Anaesth* 2002; 88:632-6
24. Silvestri E, Martinoli C, Derchi LE, Bertolotto M, Chiaramondia M, Rosenberg I: Echotexture of peripheral nerves: Correlation between US and histologic findings and criteria to differentiate tendons. *Radiology* 1995; 197:291-6
25. Fanelli G, Casati A, Garancini P, Torri G: Nerve stimulator and multiple injection technique for upper and lower limb blockade: Failure rate, patient acceptance, and neurologic complications. Study Group on Regional Anesthesia. *Anesth Analg* 1999; 88:847-52
26. Choyce A, Chan VW, Middleton WJ, Knight PR, Peng P, McCartney CJ: What is the relationship between paresthesia and nerve stimulation for axillary brachial plexus block? *Reg Anesth Pain Med* 2001; 26:100-4
27. Urmey WF, Stanton J: Inability to consistently elicit a motor response following sensory paresthesia during interscalene block administration. *ANESTHESIOLOGY* 2002; 96:552-4