

Sacral Osteomyelitis after Single-shot Epidural Anesthesia *via* the Caudal Approach in a Child

Sabine Wittum, M.D.,* Christoph K. Hofer, M.D., D.E.A.A.,* Urs Rölli, M.D.,* Markus Suhner, M.D.,† Jacques Gubler, M.D.,‡ Andreas Zollinger, M.D.§

THE caudal block, a frequently applied anesthetic technique in children, has a low incidence of complications.¹ Severe infections of the epidural space and associated structures rarely occur and have only been described when using continuous epidural catheterization.^{2,3} We report a case of sacral osteomyelitis after single-shot epidural anesthesia *via* the caudal approach.

Case Report

A 6-yr-old, 130-cm, 20-kg healthy boy (American Society of Anesthesiologists classification D), without preexisting systemic or regional infection, had general anesthesia and a caudal block for circumcision on an outpatient basis. After application of the standard monitoring (pulse oximetry, 5-lead ECG, and noninvasive blood pressure measurement), general anesthesia was induced by inhalational technique (sevoflurane 3 minimum alveolar concentration in 40% N₂O with oxygen) and an intravenous access was established. After skin disinfection of the puncture area using a solution of octenidine hydrochloride, the caudal block was performed by single-shot technique with no difficulties. A 22-gauge needle was introduced under aseptic conditions (*i.e.*, sterile gloves, facemask, and operation cap) at a 45-degree angle without lancing the skin. Bony structures were not grazed. Next, 20 ml of 0.125% Bupivacaine with epinephrine 1:200,000 was injected, providing effective intra- and postoperative analgesia. The anesthetic and surgical procedures were uncomplicated, and the early postoperative period was uneventful.

However, on the third postoperative day, the child presented with immobilizing back pain. He was in good clinical condition and was afebrile. A tender spot in the area of the caudal puncture without signs of local inflammation was detected. Sensibility and motor function of the legs were preserved. Leukocyte count and C-reactive protein level were normal. Blood cultures or local tissue-samples were not taken. Magnetic resonance imaging (MRI) revealed a phlegmonous, subcutaneous inflammation of the sacral region. There was no abscess, but edema at the anteroposterior periosteum of the lower sacrum indicated a beginning osteomyelitis (fig. 1).

Amoxicillin-clavulanic acid 120 mg·kg⁻¹ daily initially intravenously for 3 days, then 120 mg·kg⁻¹ daily orally for 46 days, was used as empiric therapy based on the clinical estimation of highest probability for Gram-positive organisms by the infectious disease consultant. The MRI was repeated after 17 days of antibiotic therapy, at which time the acute osteomyelitis of the sacrum with signs of a soft-tissue infection

was diagnosed (fig. 2). Antibiotic therapy was continued for another 30 days, and the patient showed complete recovery: The back pain disappeared 7 days after the second MRI, and a follow-up MRI showed no signs of infection in the sacral area.

Discussion

Local inflammation of the skin and the subcutaneous tissue after an epidural puncture or catheter insertion is a frequent event with spontaneous resolution. An incidence of up to 11% has been reported.⁴ In contrast, serious infections are exceptional. The development of an osteomyelitis, especially after single-shot caudal block, has not been reported previously. Spinal epidural abscess, the most frequent form of serious infection after epidural puncture, has a reported incidence of 0.2 to 1.2 per 10,000 in hospitalized children.⁵ The occurrence of this complication is equally frequent after short-term catheterization and single epidural injection.² Moreover, a similar incidence of spontaneous epidural abscess has been reported.^{6,7}

Epidermal contamination of the subcutis may be the most probable origin of the serious infection in the current case. However, the hematologic spread of bacteria is the common etiologic factor in a spontaneous epidural infection,⁶ but the child presented with no history or sign of local or systemic infection. Epidural injection and catheterization inherently carry a risk for bacterial colonization. Recent studies found a 20–35% colonization of all epidural catheters in children by various strains of bacteria after a period of 3 days. Gram-positive colonization was similar for caudal and lumbar catheters, whereas Gram-negative strains were found with a higher incidence on caudal catheters.^{4,8} Furthermore, the epidural space may be contaminated by skin flora, even after correct disinfection.⁹ Neither a solution of 0.5% Chlorhexidine nor povidone iodine may be able to completely eradicate bacterial skin flora. Octenidine hydrochloride is registered for skin disinfection but may also lack efficacy in bacterial eradication. In addition, bacteria may accumulate in the hair follicles of the skin¹⁰ and then be transported to the deeper tissue by a needle track, which could be prevented by lancing the skin.¹¹

Early diagnosis of infections of the sacral region after epidural puncture is difficult. The patient may be asymptomatic or may present with minor symptoms: One case with hip pain as the main symptom was reported.¹² In the current case, exclusive back pain led to the diagnosis

* Consultant, † Senior Consultant, and § Head, Institute of Anesthesiology, and ‡ Senior Consultant, Head of Infectiology, Department of Internal Medicine, Triemli City Hospital Zurich.

Received from the Institute of Anesthesiology, Triemli City Hospital Zurich, Zurich, Switzerland. Submitted for publication December 20, 2002. Accepted for publication March 25, 2003. S. Wittum is a regular consultant at the Institute of Anesthesiology, Triemli City Hospital. Support was provided solely from institutional and/or departmental sources.

Address reprint requests to Dr. Zollinger: Institute of Anesthesiology, Triemli City Hospital Zurich Birmensdorfstr. 497, 8063 Zurich, Switzerland. Address electronic mail to: andreas.zollinger@triemli.stzh.ch. Individual article reprints may be purchased through the Journal Web site, www.anesthesiology.org.

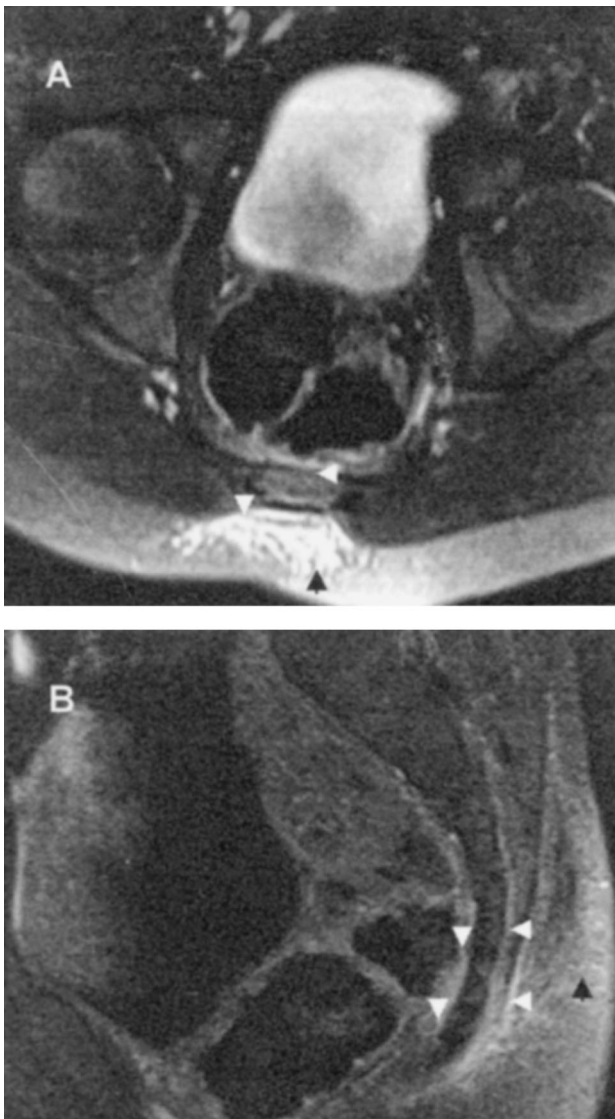


Fig. 1. The initial horizontal T2-weighted magnetic resonance image (A) and the sagittal T1-weighted image with gadolinium (B) demonstrated a phlegmonous inflammation of the subcutis (black arrowheads) and an edema at the anteroposterior periosteum of the lower sacrum (S5) and the coccygeal bone as indirect sign of a beginning osteomyelitis (white arrowheads).

sis. Unfortunately, however, the infection is frequently not detected until the development of significant neurologic complications.⁵ Gadolinium-enhanced MRI is considered to be the definitive standard in the diagnosis of spinal epidural abscess.^{12,13} However, in our case an early MRI showed relatively minor soft-tissue infection and indirect signs of a beginning osteomyelitis, whereas the diagnosis of osteomyelitis could only be confirmed later.

To avoid subsequent surgical intervention,¹² an early empiric antibiotic therapy was begun after clinical indications of an infection. The choice of antibiotics must be directed primarily against Gram-positive organisms, especially *Staphylococcus aureus*, streptococci, and enterococci, the leading pathogens for tissue infection af-

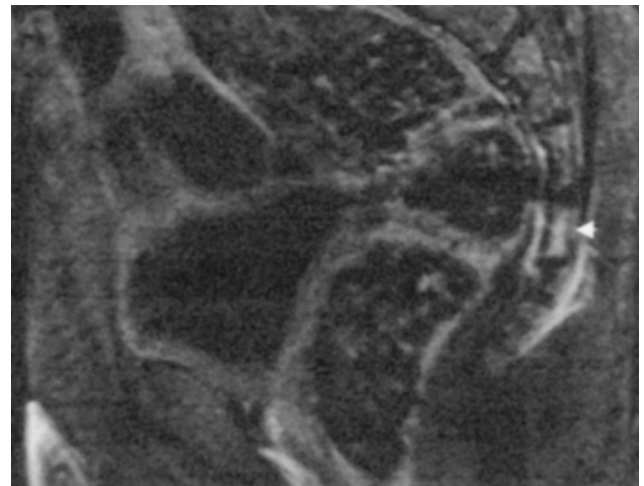


Fig. 2. A follow-up T1-weighted magnetic resonance image with gadolinium confirmed the diagnosis of osteomyelitis of the lower sacral segment S5 (white arrowhead).

ter epidural puncture.¹⁴ Furthermore, antibiotics must provide low toxicity to enable treatment over several weeks, and they should easily penetrate bone tissue.¹⁵ Amoxicillin-clavulanic acid met the demands in the current case, particularly because susceptibility of the Gram-positive bacteria strains to this drug is still very high in our hospital. If clinical symptoms fail to resolve with therapy, the presence of methicillin-resistant organisms must be considered^{16,17} and the responsible bacteria should be identified by culture and Gram stain. In the present case, rapid clinical improvement of the patient's complaints warranted continuation of empiric treatment, hence avoiding further intervention in the sacral region for bacterial analysis with general anesthesia in this child.

In summary, we report a case of sacral osteomyelitis after single-shot epidural anesthesia *via* the caudal approach under aseptic conditions in a child. Back pain was the predominant clinical sign of infection, whereas the initial MRI did not show the early osteomyelitis. Empiric antibiotic therapy resulted in complete recovery.

References

1. Veyckemans F, Van Obbergh IJ, Gouverneur JM: Lessons from 1100 pediatric caudal blocks in a teaching hospital. *Reg Anesth* 1992; 17:119-25
2. Strafford MA, Wilder RT, Berde CB: The risk of infection from epidural analgesia in children: A review of 1620 cases. *Anesth Analg* 1995; 80:234-8
3. Schroter J, Wa DD, Hoffmann V, Bach A, Motsch J: Epidural abscess after combined spinal-epidural block. *Can J Anaesth* 1997; 44:300-4
4. Kost-Byerly S, Tobin JR, Greenberg RS, Billett C, Zahurak M, Yaster M: Bacterial colonization and infection rate of continuous epidural catheters in children. *Anesth Analg* 1998; 86:712-6
5. Rubin G, Michowiz SD, Ashkenasi A, Tadmor R, Rappaport ZH: Spinal epidural abscess in the pediatric age group: Case report and review of literature. *Pediatr Infect Dis J* 1993; 12:1007-11
6. Baker AS, Ojemann RG, Swartz MN, Richardson EP Jr: Spinal epidural abscess. *N Engl J Med* 1975; 293:463-8
7. Jacobsen FS, Sullivan B: Spinal epidural abscesses in children. *Orthopedics* 1994; 17:1131-8
8. McNeely JK, Trentadue NC, Rusy LM, Farber NE: Culture of bacteria from lumbar and caudal epidural catheters used for postoperative analgesia in children. *Reg Anesth* 1997; 22:428-31

9. Sato S, Sakuragi T, Dan K: Human skin flora as a potential source of epidural abscess. *ANESTHESIOLOGY* 1996; 85:1276-82

10. Selwyn S, Ellis H: Skin bacteria and skin disinfection reconsidered. *Br Med J* 1972; 1:136-40

11. Du Pen SL, Peterson DG, Williams A, Bogosian AJ: Infection during chronic epidural catheterization: Diagnosis and treatment. *ANESTHESIOLOGY* 1990; 73:905-9

12. Bair-Merritt MH, Chung C, Collier A: Spinal epidural abscess in a young child. *Pediatrics* 2000; 106:E39

13. Wang JS, Fellows DG, Vakharia S, Rosenbaum AE, Thomas PS: Epidural abscess: Early magnetic resonance imaging detection and conservative therapy. *Anesth Analg* 1996; 82:1069-71

14. Reihnsaus E, Waldbaur H, Seeling W: Spinal epidural abscess: A meta-analysis of 915 patients. *Neurosurg Rev* 2000; 23:175-204

15. Leys D, Lesoin F, Viaud C, Pasquier F, Rousseaux M, Jomin M, Petit H: Decreased morbidity from acute bacterial spinal epidural abscesses using computed tomography and nonsurgical treatment in selected patients. *Ann Neurol* 1985; 17:350-5

16. Auletta JJ, John CC: Spinal epidural abscesses in children: A 15-year experience and review of the literature. *Clin Infect Dis* 2001; 32:9-16

17. Herold BC, Immergluck LC, Maranan MC, Lauderdale DS, Gaskin RE, Boyle-Vavra S, Leitch CD, Daum RS: Community-acquired methicillin-resistant *Staphylococcus aureus* in children with no identified predisposing risk. *JAMA* 1998; 279:593-8

Anesthesiology 2003; 99:505-6

© 2003 American Society of Anesthesiologists, Inc. Lippincott Williams & Wilkins, Inc.

Albuterol-induced Lactic Acidosis

Edwin B. Liem, M.D.,* Stephen C. Mnookin, M.D.,† Michael E. Mahla, M.D.‡

LACTIC acidosis occurring in association with β -2 agonist treatments such as salbutamol,^{1,2} ritodrine,³ metaproterenol,⁴ and albuterol⁵ has been reported, and its mechanism remains poorly understood. Lactic acidosis in the setting of severe asthma has been attributed to the production of lactate by overworked respiratory muscles.⁶ However, the increased work of breathing seems an unlikely factor in patients who are anesthetized, paralyzed, and mechanically ventilated, and this phenomenon has not been previously reported in anesthetized patients. We report a case of severe lactic acidosis in a patient undergoing thoracoscopic sympathectomy under general anesthesia who received repeated albuterol nebulizer treatments for bronchospasm.

Case Report

A 39-yr-old white woman was scheduled for thoracoscopic sympathectomy at the University of Florida, Shands Hospital, to alleviate reflex sympathetic dystrophy. The patient had a history of mild asthma for which she was never intubated or hospitalized in the past. Her home medications included loratadine (Claritin-D®; Schering-Plough, Kenilworth, NJ), fluticasone (Flonase®; Glaxo Smith Kline, Philadelphia, PA), amitriptyline (Elavil®; AstraZeneca, Wilmington, DE), and albuterol-metered-dose inhalers that she used one to two times per week. The patient was allergic to sulfa drugs, mexiletine, and benzoin. Previous operations, all without complications, included cholecystectomy, appendectomy, carpal tunnel release, and removal of a ganglion cyst on right wrist. Physical examination revealed a 97-kg woman in no apparent distress with clear breath sounds on auscultation; her hematocrit was 0.37.

* Assistant Professor, Outcomes Research™ Institute and Department of Anesthesiology, University of Louisville. † Anesthesia Consultant, Anesthesiology Associates of Tallahassee, P.A. ‡ Professor of Anesthesiology and Neurosurgery, Associate Professor for Education, Department of Anesthesiology, University of Florida.

Received from the Outcomes Research™ Institute and Department of Anesthesiology, University of Louisville, Louisville, Kentucky; and the Department of Anesthesiology and Neurosurgery, University of Florida, Gainesville, Florida. Submitted for publication January 17, 2003. Accepted for publication March 25, 2003. Support was provided solely from institutional and/or department sources.

Address reprint requests to Dr. Liem: Department of Anesthesiology, University of Louisville Hospital, 530 S. Jackson, Louisville, Kentucky 40202. Address electronic mail to: edliem@bellsouth.net. Individual article reprints may be purchased through the Journal Web site, www.anesthesiology.org.

Preoperative medications included an albuterol nebulizer treatment (2.5 mg) and intravenous midazolam (2 mg). The patient was then taken to the operating room; initial vital signs were heart rate of 100 beats per minute, blood pressure 145/75 mmHg, and arterial oxygen saturation of 100% on room air. The patient was then preoxygenated for 2 min, and general anesthesia was induced with 350 mg sodium thiopental, 10 mg pancuronium, and 50 μ g sufentanil. Anesthesia was maintained with a sufentanil infusion and isoflurane. The patient was easily mask-ventilated. Tracheal intubation was attempted with a 39, and then a 37, French double-lumen endotracheal tube, but this was unsuccessful because of the patient's small mouth opening. Thus, we placed a 7.0-mm single-lumen endotracheal tube with a bronchial blocker (Univent, Fuji Systems Corporation, Tokyo, Japan).

The patient then developed severe bronchospasm, which was confirmed with auscultation and by observation of slow-rising expiratory phases on the capnography waveform. Initial tidal volumes were approximately 800 ml, mechanical ventilation rate was 12 breaths per minute, and peak inspiratory pressure readings were approximately 55 cm H₂O. Repeated albuterol nebulizer treatments were given for 45 min. Subsequently, the peak inspiratory pressure decreased to 30 cm H₂O, and the bronchospasm resolved. During this first episode of bronchospasm, the patient's mean arterial blood pressure remained at 70 mmHg or higher; furthermore, her arterial oxygen saturation remained 95% or higher except for a few brief periods of desaturation. The lowest recorded arterial oxygen saturation of 90% occurred during the initial onset of the bronchospasm. An arterial catheter was placed in the left radial artery, and the patient was placed in the left lateral position. On positioning, correct placement of the endotracheal tube was verified *via* fiberoptic bronchoscopy. Albuterol treatments were continued for 30 min, and then the right lung was deflated for surgical access.

Fifteen minutes after one lung ventilation was initiated, with the patient receiving 100% fraction of inspired oxygen, arterial blood gases were pH 7.24, Pco₂ 45 mmHg, Po₂ 102 mmHg, HCO₃⁻ 18.3 mm, base excess -8.5 mm, and lactate 5.1 mm. Fifteen minutes later, arterial blood gases were pH 7.22, Pco₂ 46 mmHg, Po₂ 105 mmHg, HCO₃⁻ 18.2 mm, base excess -8.9 mm, and lactate 5.9 mm. The patient's heart rate was 100-110 beats per minute, and her mean arterial blood pressure was stable and remained near 70 mmHg throughout the rest of the procedure. Her core body temperature was maintained between 35.5° and 36.0°C. During the procedure, there were no signs of ischemia on the electrocardiogram. Furthermore, the patient had good peripheral pulses and was hemodynamically stable, with a total blood loss of 200 ml and a urine output of 500 ml. Total intravenous fluids given during surgery were 4,000 ml normal saline.

At the conclusion of surgery, just before emergence, the patient had bronchospasm again and repeated albuterol treatments were given. She was eventually extubated and was sent to the postanesthesia recovery unit in no apparent distress.

With the patient receiving a 2-l nasal canula, her initial vital signs in the postanesthesia recovery unit were heart rate 117 beats per minute, arterial pressure 123/70 mmHg, respiration rate 13 breaths per minute, and arterial oxygen saturation 97%. The patient was given another albuterol nebulizer treatment in the postanesthesia recovery unit, and 1 h later her arterial blood gases were pH 7.14, PCO_2 42 mmHg, PO_2 86 mmHg, HCO_3^- 13.8 mm, base excess -14.1 mm, lactate 7.5 mm, Na^+ 139 mm, K^+ 3.4 mm, Cl^- 109 mm, blood urea nitrogen 3.2 mm, creatinine 53 μM , glucose 11.4 mm, and hematocrit 0.30. Her anion gap was 19.6 mm. The patient was in no distress, and her respiratory rate was 15 breaths per minute. She was taken to the surgical intensive care unit, where her lactate levels were followed, but no more albuterol treatments were administered. Her lactate level peaked at 7.8 mm. Sodium bicarbonate was administered, and 12 h later her lactate level was 1.8 mm. The patient was discharged in good health on postoperative day 2.

Discussion

Lactic acidosis can occur in two different clinically distinguishable categories. The first (type A) occurs when oxygen delivery to the tissues is compromised. The second (type B) occurs when either lactate production is increased or lactate removal is decreased without obvious oxygen delivery problems.^{7,8}

In a study by Phillips *et al.*,⁹ healthy volunteers without respiratory distress who were given intravenous infusions of either salbutamol or rimiterol had dose-related increases in lactic acid levels. In the absence of any clinical signs of circulatory shock or severe hypoxia in the current patient, we hypothesize that she had type B lactic acidosis.

β -2 Receptor activation produces excess glycogenolysis and lipolysis.¹⁰ Increased glycogenolysis eventually leads to increased concentrations of pyruvate. Pyruvate is converted to acetyl CoA, which enters the citric acid cycle. If pyruvate does not enter this aerobic pathway, it is converted to lactate instead, thereby potentially caus-

ing lactic acidosis. In addition, an increased lipolysis also increases acetyl CoA concentration through a different pathway. An increased acetyl CoA concentration potentially further inhibits pyruvate oxidation to acetyl CoA and leads to excess pyruvate. Finally, β -2 receptor stimulation will also inhibit the pyruvate dehydrogenase complex, and this might even further limit the rate that pyruvate is oxidized to acetyl CoA.¹⁰

We believe that the lactic acidosis in the current patient was caused by the repeated use of albuterol. We hypothesize that the cause was excess β -2 stimulation through the mechanisms described above, and that one should be aware of the possibility that severe lactic acidosis might develop, even in patients who are anesthetized and mechanically ventilated, with repeated and prolonged use of β -2 agonist drugs.

References

1. Stratakos G, Kalomenidis J, Routsis C, Papiris S, Roussos C: Transient lactic acidosis as a side effect of inhaled salbutamol. *Chest* 2002; 122:385-6
2. Prakash S, Mehta S: Lactic acidosis in asthma: Report of two cases and review of the literature. *Can Respir J* 2002; 9:203-8
3. Richards SR, Chang FE, Stempel LE: Hyperlactacidemia associated with acute ritodrine infusion. *Am J Obstet Gynecol* 1983; 146:1-5
4. Braden GL, Johnston SS, Germain MJ, Fitzgibbons JP, Dawson JA: Lactic acidosis associated with the therapy of acute bronchospasm. *N Engl J Med* 1985; 313:890-1
5. Assadi FK: Therapy of acute bronchospasm: Complicated by lactic acidosis and hypokalemia. *Clin Pediatr (Phila)* 1989; 28:258-60
6. Appel D, Rubenstein R, Schragger K, Williams MH Jr: Lactic acidosis in severe asthma. *Am J Med* 1983; 75:580-4
7. Cohen RD, Iles RA: Lactic acidosis: Some physiological and clinical considerations. *Clin Sci Mol Med* 1977; 53:405-10
8. Cohen RD, Iles RA: Lactic acidosis: Diagnosis and treatment. *Clin Endocrinol Metab* 1980; 9:513-41
9. Phillips PJ, Vedig AE, Jones PL, Chapman MG, Collins M, Edwards JB, Smeaton TC, Duncan BM: Metabolic and cardiovascular side effects of the beta 2-adrenoceptor agonists salbutamol and rimiterol. *Br J Clin Pharmacol* 1980; 9:483-91
10. Haffner CA, Kendall MJ: Metabolic effects of beta 2-agonists. *J Clin Pharm Ther* 1992; 17:155-64

Is More Information Better? Intraoperative Recall with a Bispectral Index® Monitor in Place

Brian K. Bevacqua, M.D.,* David Kazdan, M.D, Ph.D.†

RECALL during general anesthesia is a relatively rare but disturbing event that has generated increasing interest in both medical and popular literature. Part of this interest is attributable to the introduction of monitors that may assist in determining the level of consciousness during anesthesia.¹⁻³ Although not marketed as an “awareness monitor,” there has been speculation that using the Bispectral Index® monitor (BIS®, Aspect Medical Systems, Natick, MA) might reduce the possibility of recall.^{2,3} This reliance on bispectral index (BIS) data can be supported by reports indicating that if the BIS® is used correctly and scores are kept below 60, recall should be rare.⁴ We report the case of a patient whose anesthetic plan was in part based on BIS data, who had intraoperative BIS scores only occasionally above 60, and who had recall of intraoperative events.

Case Report

The patient was a 70-yr-old man who had been diagnosed with renal cell cancer and was scheduled for a nephrectomy. His past medical history was significant for non-insulin-dependent diabetes mellitus, peripheral vascular disease, atherosclerotic coronary artery disease, myocardial infarction and congestive heart failure (ejection fraction estimated at 20%), hypertension, obstructive lung disease, chronic renal insufficiency, atrial fibrillation, colon cancer, and hyperlipidemia. Past surgical history included coronary artery bypass grafting, multiple infra-inguinal vascular bypass grafting procedures, and sigmoid colectomy. Review of systems, physical examination, and diagnostic workup were consistent with the disease states noted above. Medical and cardiology consultants thought that the patient had been optimally prepared for surgery. Anesthetic options were discussed with the patient and his family, who agreed to the patient's receiving general anesthesia with arterial and pulmonary artery catheter placement and BIS monitoring.

The patient was brought to the operating room, where, in addition to standard monitoring, a radial artery arterial catheter was placed. A pulmonary artery catheter was also placed. Vital signs and anesthetic gas concentrations were recorded using the “Arkive” anesthesia recording system (BIS scores were entered manually). The patient had

intravenous induction of anesthesia with midazolam (1.5 mg), fentanyl (50 µg), propofol (90 mg), and succinylcholine (80 mg). Anesthesia was maintained with isoflurane (inspiratory concentration between 0.1-0.4%), remifentanyl infusion (0.01 to 0.15 µg · kg⁻¹ · min⁻¹), and vecuronium (a bolus of 4 mg after intubation followed by an infusion totaling 3.5 mg over 3 h). After induction, a BIS® monitor (model A 2000) was placed and showed good signal quality throughout. BIS scores were between 40 to 60 throughout the operation, except for three instances. On the first occasion, the BIS score was 70 and the systolic blood pressure was in the 70- to 80-mmHg range. The patient was treated with a single phenylephrine bolus, with return of blood pressure and BIS score to desired levels within 5 min. On the second occasion, the BIS score increased to 70 and the patient was given morphine (10 mg) with return to levels below 60 within 10 min. There was a third period of 15 min when the BIS score was noted to be 65 (systolic blood pressure in the 100-85 range) and the patient moved. He was treated with midazolam (0.5 mg) and an increase in isoflurane concentration, with return of the BIS score to 40 and no further movement. At the end of surgery, when the BIS score was in the 80-90+ range, the endotracheal tube was removed and he was transferred to the intensive care unit.

Several hours after surgery, the patient informed his nurse that he had recall of intraoperative events. We interviewed the patient the day of and the day after surgery, and he stated that he had “felt everything but was not able to move...heard conversation.” He had no clear memory of specific events but stated that he remembered the entire procedure. He noted that it was a “bad experience.” Careful and repeated questioning revealed no similar problems after general or regional anesthetics in the past. We told the patient that we believed him and apologized for these events. The patient was offered a mental health consult to deal with the stress associated with recall, which he refused. The remainder of the patient's postoperative course was uneventful. He has not been bothered by signs and symptoms of an acute stress reaction or posttraumatic stress disorder.

Discussion

In an update of cases reported to Aspect Medical, the incidence of recall when using a BIS® monitor was less than 1 per 40,000.⁴ When awareness occurred with BIS monitoring in place, it was usually associated with BIS values above 60, more frequently during cardiac surgery, and in younger (< 60 yr old), predominantly female (60%) patients.⁴ Although this may be the overall pattern, there are reports of recall (BIS 47),⁵ failure to lose consciousness (BIS 43),⁶ and awareness reactions during induction (BIS 50-60),⁷ with BIS values clinically appropriate for general anesthesia.

When evaluating this patient before surgery, we had estimated that he was at low risk for recall because of the scheduled surgery and his previous anesthetic history. These previous anesthetics had been largely inhalation agents (and/or regional anesthetics), as opposed to the more balanced technique used in this instance. The

* Associate Professor of Anesthesiology, University of Wisconsin School of Medicine. † Assistant Professor of Anesthesiology, Case Western Reserve School of Medicine.

Received from the University of Wisconsin School of Medicine, Madison, Wisconsin; and Case Western Reserve School of Medicine, Cleveland, Ohio. Submitted for publication October 18, 2002. Accepted for publication April 2, 2003. The Department of Veterans Affairs, Case Western Reserve University and the University of Wisconsin provided salary support for the authors. Otherwise no financial support was received and no financial relationships exist between the authors and any private companies.

Address reprint requests to Dr. Bevacqua: Chief, Anesthesiology Service (112A), 2500 Overlook Terrace, Madison, Wisconsin 53705. Address electronic mail to: brian.bevacqua2@med.va.gov. Individual article reprints may be purchased through the Journal Web site, www.anesthesiology.org.

change in the planned anesthetic in this case was attributable to what we believed to be a worsening of the patient's cardiac status. Also, BIS was not available for any of these patient's previous operations, and we were more comfortable altering the previously successful anesthetic plan with the knowledge that we would have additional information concerning the patient's level of consciousness to assist in drug dosing. Our goal was to limit this patient's medication exposure during surgery while achieving BIS values in the acceptable range of 40–60. Specifically, we were aiming for the higher end of this range, hoping to maintain hemodynamic stability and account for this patient's individual anesthetic needs while limiting the possibility of recall of intraoperative events.

This patient may have been placed at increased risk of recall due to a lack of amnesic premedication and the intraoperative use of opioids and muscle relaxants.⁸ However, he did receive midazolam during induction of anesthesia and had a consistent but low inspiratory concentration of isoflurane throughout the surgery. These smaller amounts of medications were based on hemodynamic data and BIS: when the highest blood pressure reading of 130/60 was noted, the BIS score was 40–50. Also, dopamine and phenylephrine infusions were needed intermittently, despite what might be thought to be light anesthesia. Muscle relaxant use may have masked an awake patient, but at least toward the end of surgery (despite a vecuronium infusion) the patient was able to move. This movement was treated not with more muscle relaxants but rather with a dose of midazolam and (increased) isoflurane, and movement ceased. If we had placed the BIS® before induction of anesthesia, we might have seen a lower BIS baseline because of senile dementia.⁹ However, we observed a return to (near) normal BIS (90+) before extubation, making an altered baseline an unlikely starting point. Finally, it can be argued that our patient did not have recall because of his lack of detailed memories of intraoperative conversations and details. The patient claimed, on several occasions to multiple interviewers, that he was never asleep and remembered the entire operation, specifically denying occasional or intermittent memories of the surgery. We chose to accept his version and not to challenge his claims, as we believe these actions are an important part of postoperative therapy for patients with recall.¹⁰ We believe this represents recall of intraoperative events, as the patient's memory fits well within the parameters established in published reports.¹¹ Also, we have not found errors in labeling or vigilance on our part that

could account for recall in this case.⁸ Finally, we did not use a convection air-warming blanket, which might have falsely elevated the BIS.¹²

After a case of intraoperative recall similar to ours,⁵ the question was posed, "How might one alter one's practice to avoid similar occurrences?"¹³ From this experience and our review of the literature, we suggest that when a BIS® monitor is used that there be strict adherence to the recommended range of values and rapid treatment to return scores to the appropriate range. This may be especially true when constitutional factors (such as cardiac disease with limited reserve) dictates the administration of light anesthesia, reducing the margin of error when dealing with variable surgical stimulation. In addition, the judicious use of muscle relaxants to allow patient movement in response to stimulation is also indicated, using amnesic agents and supplementation with adequate concentrations (0.6–1.3 minimal alveolar concentration) of volatile agents.¹⁰ The operative team must maintain decorum at all times so that if the patient's memory (implicit or explicit) is a problem, negative personal information will not be included.¹⁰ Planning must allow enough flexibility for reaction to the variability in surgical stimulation so that anesthetic delivery and requirement can be balanced.¹⁴

References

1. Drummond JC: Monitoring depth of anesthesia: With emphasis on the application of the bispectral index and the middle latency auditory evoked response to the prevention of recall. *ANESTHESIOLOGY* 2000; 93:876–82
2. Todd MM: EEGs, EEG processing, and the bispectral index (editorial). *ANESTHESIOLOGY* 1998; 89:815–7
3. Rosow C, Manberg PJ: Bispectral index monitoring. *Anesth Clin North Am* 2001; 19:947–66
4. Manberg PJ, Zraket D, Kovitch L, Christman L: Awareness during BIS monitoring: 2001 update (abstract). *ANESTHESIOLOGY* 2001; 95:564
5. Mychaskiw G, Horowitz M, Sachdev V, Heath BJ: Explicit intraoperative recall at a bispectral index of 47. *Anesth Analg* 2001; 92:808–9
6. Barr G, Anderson RE, Owall A, Jakobsson JG: Effects on the bispectral index during medium-high dose fentanyl induction with or without propofol supplement. *Acta Anaesthesiol Scand* 2000; 44:807–11
7. Schneider G, Wagner K, Reeker W, Hanel F, Werner C, Kochs E: Bispectral index (BIS) may not predict awareness reaction to intubation in surgical patients. *J Neurosurg Anesthesiol* 2002; 12:7–11
8. Domino KB, Posner KL, Caplan RA, Cheney FW: Awareness during anesthesia. *ANESTHESIOLOGY* 1999; 90:1053–6
9. Renna M, Venturi R: Bispectral index and anaesthesia in the elderly. *Minerva Anesthesiol* 2000; 66:398–402
10. Ghoneim MM: Awareness during anesthesia. *ANESTHESIOLOGY* 2000; 92:597–602
11. Seppo O-V, Ranta L, Saario J, Ali-Melkkila T, Hynynen M: Awareness with recall during general anesthesia: Incidence and risk factors. *Anesth Analg* 1998; 86:1084–9
12. Hemmerling TM, Fortier JD: Falsely increased bispectral value index in a series of patients undergoing cardiac surgery using forced-air-warming therapy of the head. *Anesth Analg* 2002; 95:322–3
13. Rampil I: False negative bis? Maybe, maybe not! (letter). *Anesth Analg* 2001; 93:798
14. Leslie K, Myles PS: Awareness during general anesthesia: Is it worth worrying about (editorial)? *Med J Aust* 2001; 174:212–3

Cortical Blindness and Neurologic Injury Complicating Cervical Transforaminal Injection for Cervical Radiculopathy

Marion R. McMillan, M.D.,* Cynthia Crumpton, R.N.†

SINCE the initial description by Morvan in 1988, cervical transforaminal injection of analgesic solutions and corticosteroids has been a useful diagnostic and therapeutic option for the nonoperative management of cervical radicular pain symptoms.^{1,2} Transforaminal cervical epidural injection is technically demanding, and the proximity to vascular and central nervous system structures may increase the risk of complications. Patients with previous cervical spine surgery may be at greater risk for procedural complications because of postsurgical anatomic variations or more advanced pathologic conditions, resulting in the failure of conservative management. Potential complications include nerve root trauma, unintentional dural puncture, unintended spinal anesthesia with respiratory and hemodynamic compromise, vertebral artery injury, and systemic allergic reactions to radiocontrast agents. Transient cortical blindness and brain injury have been infrequently associated with the use of ionic and nonionic radiocontrast agents introduced into the intracranial circulation during angiographic procedures,³⁻⁵ and they may also be embolic in origin.⁶ These complications have not been previously reported in association with cervical transforaminal injections for the management of pain. We present a case of acute cortical blindness and prolonged neurologic compromise complicating cervical transforaminal injection with acute disruption of the blood-brain barrier demonstrated by magnetic resonance imaging. Implications for patient management and prevention of complications are discussed.

Case Report

A 54-yr-old man was referred for pain management consultation because of a 14-yr history of neck pain, left cervical radiculopathy, and neuritic left arm pain. He had a 25-pack-year history of cigarette smoking with no known history of vascular disease. Physical examination was remarkable for sensory impairment to cold and light touch without allodynia or hyperalgesia in the left C₅ and C₆ dermatomes. Reflex examination documented reduced left biceps and triceps reflexes at 1+, respectively, with the remainder of the reflex and motor

examination of the upper extremity demonstrating normal findings. There was distal left cervical spine tenderness, which reproduced neuritic left elbow pain, and the patient complained of left-sided neck pain made worse by right rotation and extension. He had undergone three previous cervical spine operations for circumferential cervical spine stenosis from C₃₋₄ to C₆₋₇ by magnetic resonance imaging, including decompression from C₃ to C₇, with hardware fusion at C₆₋₇ 4 months before presentation. Postoperative computed tomography with cervical myelography demonstrated mild focal blunting at the left C₆ nerve root sleeve deemed to be surgically insignificant. He had responded poorly to opioid analgesics, and spinal injections had not been performed. Because of intractable radicular left arm pain, transforaminal cervical epidural steroid injection at the C₅₋₆ level was planned.

The left neuroforamen at C₅₋₆ was easily visualized in multiple oblique projections, and after local infiltration analgesia, a 22-gauge, 6-cm needle was advanced under fluoroscopy from an anterior/oblique approach to contact the superior dorsal quadrant of the foramen. On the first pass, bright red blood was aspirated near the opening of the foramen, suggesting left vertebral artery puncture. The needle was retracted, cleared of blood, and repositioned, with negative aspiration test results for blood or cerebrospinal fluid. Loss of resistance to 1 ml of injected air was followed by injection of 2 ml of myelogram-compatible iopamidol nonionic radiocontrast to confirm needle entry into the left lateral recess of the epidural space. The epidurogram was judged to be technically unsatisfactory, and within seconds after injection, the patient developed lateral nystagmus. He remained conscious and verbally responsive, and a final attempt to cannulate the C₄₋₅ foramen was aborted because of increasing patient restlessness and agitation. Approximately 45 min after the initial injection of air and radiocontrast and without injection of additional medications, the patient complained of total bilateral blindness, with bedside confirmation of no light perception. Brief bedside neurologic examination demonstrated no focal neurologic abnormalities. Arterial air embolism was suspected, and after consultation with a neurologist, the patient was treated empirically with corticosteroids and intravenous doxycycline. Emergent baseline and gadolinium-enhanced magnetic resonance imaging of the brain was requested. Images acquired 2 h after the initial foraminal injection demonstrated bilateral parenchymal gadolinium enhancement in the occipital lobes and throughout the posterior intracranial circulation, indicating true breakdown of the blood-brain barrier (fig. 1). Unexpectedly, simultaneous diffusion weighted images were normal. The patient remained responsive and alert and was transferred to a tertiary care facility, where he received empiric hyperbaric oxygen treatment within 4 h after the event. During the first 2 h of hyperbaric therapy, he suffered two grand mal seizures, resulting in discontinuation of hyperbaric therapy and transfer to the neurologic acute care unit. Over the next 24 h, he manifested obtundation, confusion, aphasia, swallowing dysfunction, and continued bilateral blindness. A second magnetic resonance scan of the brain on day 4 showed vasogenic and cytotoxic cerebral edema preferentially in the left occipital cortex on T2-weighted images with superimposed abnormalities on diffusion weighted images. Postgadolinium images demonstrated no parenchymal enhancement, and simultaneous magnetic resonance angiography showed patent intracranial arteries. He became more responsive over the next several days, and an ophthalmology consultant documented intact pupillary reflexes, normal fundoscopic examination, and globally impaired vision consistent with

* Medical Director and † Clinical Nurse Specialist, Foothills Regional Pain Center.

Received from the Foothills Regional Pain Center, Seneca, South Carolina. Submitted for publication January 9, 2003. Accepted for publication April 9, 2003. Support was provided solely from institutional and/or departmental sources.

Address reprint requests to Dr. McMillan: Medical Director, Foothills Regional Pain Center, 457 Sandifer Boulevard, Seneca, South Carolina 29678. Address electronic mail to: marionmc@att.net. Individual article reprints may be purchased through the Journal Web site, www.anesthesiology.org.

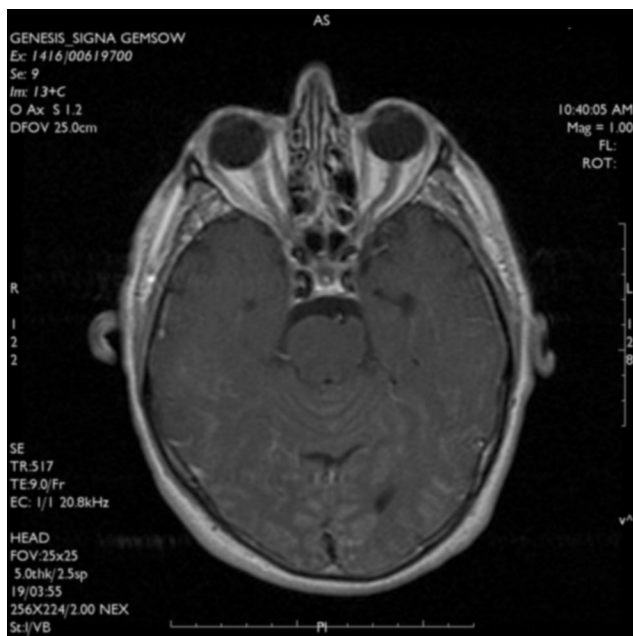

Fig. 1. Day 1, T1-weighted contrast enhanced magnetic resonance image at 2 h after cervical transforaminal injection demonstrating intense parenchymal uptake in bilateral occipital and temporal lobes compatible with acute disruption of the blood-brain barrier.

cortical blindness. He was able to partially track images in a mirror by the seventh hospital day. The patient made continued gradual improvement over the next 3 weeks, noting normalization of cognitive impairment, aphasia, dysphagia, and full return of the left visual field. By day 30, he manifested a mild short-term memory deficit and a persistent partial right homonymous hemianopia, and he was discharged from the hospital.

Discussion

Cortical blindness is a rare but recognized complication of the administration of radiocontrast agents into the intracranial vasculature. It has been seen most often in procedures involving the posterior intracranial circulation and is reported to occur during 0.3–1% of vertebral angiograms.^{3–5,7} Clinically, visual deficits following administration of radiocontrast agents have been associated with acute cognitive impairment, cranial nerve deficits, oculomotor disturbances, seizures, nausea, and vomiting, and are usually transient with restoration of normal neurologic function after days to weeks,^{3–5,8} but they may be permanent.⁹ Lantos suggested that the pathognomonic radiographic appearance of direct radiocontrast toxicity is the immediate contrast enhancement of brain parenchyma on computed tomography or magnetic resonance images reflecting true breakdown of the blood-brain barrier.³

The primary differential diagnosis in this case includes radiocontrast-induced cerebral injury *versus* vertebral artery embolism associated with vertebral artery injury or the use of air for epidural localization. The low sen-

sitivity of negative aspiration tests to detect intravascular injection during caudal¹⁰ and lumbar¹¹ transforaminal epidural injections has been previously reported. Case reports and published reviews of arterial air embolism indicate that clinical symptoms, time course of recovery, potential long-term sequelae are similar to those reported in association with radiocontrast toxicity.^{12–14} In arterial air embolism, hyperbaric oxygen therapy is the treatment of choice,¹² and animal studies also support the use of intravenous lidocaine¹⁵ and doxycycline¹⁶ for the reduction of cerebral injury in experimental cerebral air embolism. Our patient demonstrated acute parenchymal contrast enhancement and normal diffusion weighted images by magnetic resonance on day 1, and no contrast enhancement on day-4 images, when it would usually be expected with cerebral infarction.¹⁷ It is possible that arterial gas embolism may have caused ischemic disruption of the blood-brain barrier and predisposed the patient to subsequent radiocontrast toxicity. Observed neurologic deficits at 4 weeks may have been related to the persistent effects of air or other cerebral embolism, direct cytotoxic effects of the radiocontrast agent itself, or both.

Greater emphasis should be placed on the potential for cortical blindness and brain injury associated with cervical transforaminal injections, the indications for and clinical outcomes of these procedures in patients with persistent cervical radiculopathy after cervical spine surgery, and the risk of vertebral artery injury associated with the classic anterior/oblique approach. Our experience also leads us to suggest that the use of air to identify the cervical periradicular epidural space should be abandoned because of the risk of cerebral air embolism. We believe that the use of radiocontrast agents may be justified after individual assessment of potential benefits and risk of radiocontrast toxicity. Recently, Vallee *et al.* reported their results with a lateral periradicular approach for cervical transforaminal injections in 32 patients with cervical radiculopathy without the use of radiocontrast or loss of resistance maneuvers.¹⁸ We believe that additional research comparing the efficacy, safety, and indications for various cervical transforaminal techniques in defined patient populations is warranted.

References

1. Morvan G, Mompoint D, Bard M, Levi-Valensin G: Direct intra-foraminal injection of corticosteroids in the treatment of cervico-brachial pain, *Interventional radiology in bone and joint*. Edited by Bard M, Laredo JD. New York, Springer Verlag, 1988, pp 253–7
2. Bush K, Hillier S: Outcome of cervical radiculopathy treated with periradicular/epidural corticosteroid injections: A prospective study with independent clinical review. *Eur Spine J* 1996; 5:319–25
3. Lantos G: Cortical blindness due to osmotic disruption of the blood-brain barrier by angiographic contrast material: CT and MRI studies. *Neurology* 1989; 39:567–71
4. Kermod AG, Chakera T, Mastaglia FL: Low osmolar and non-ionic x-ray contrast media and cortical blindness. *Clin Exp Neurol* 1992; 29:272–6
5. Lim K, Radford D: Transient cortical blindness related to coronary angiography and graft study. *Med J Aust* 2002; 177:43–4

6. Sabovic M, Bonac B: An unusual case of cortical blindness associated with aortography: A case report. *Angiology* 2000; 51:151-4
7. Mani RL, Eisenberg RL: Complications of catheter cerebral arteriography: Analysis of 5000 procedures. III. Assessment of arteries injected, contrast medium used, duration of procedure, and age of patient. *Am J Radiol* 1978; 131: 871-4
8. Package insert, Isovue M-200 (Iopamidol injection, 41%) and M-300 (Iopamidol injection, 61%), Braco Diagnostics, Princeton, New Jersey 08543
9. Package insert, Optiray 160, 240, 300, 320, 350, (Ioversol injection, 34, 51, 64, 68, and 74%), Mallinckrodt, Inc., St. Louis, Missouri 63042
10. Renfrew DL, Moore T, Kathol M, El-Khoury G, Lemke JH, Walker CW: Correct placement of epidural steroid injections: Fluoroscopic guidance and contrast administration. *AJNR Am J Neuroradiol* 1991; 12:1003-7
11. Furman M, O'Brien E, Zgleszewski T: Incidence of intravascular penetration in transforaminal lumbosacral epidural steroid injections. *Spine* 2000; 25: 2628-32
12. Muth CM, Shank ES: Gas embolism. *N Engl J Med* 2000; 342:476-82
13. Hinkle D, Raizen D, McGarvey M, Liu G: Cerebral air embolism complicating cardiac ablation procedures. *Neurology* 2001; 56:792-4
14. Akhtar N, Jafri W, Mozaffar T: Cerebral artery air embolism following an esophagogastrosocopy: A case report. *Neurology* 2001; 56:136-7
15. Dutka AJ, Mink R, McDermott JJ, Clark JB, Hallenbeck JM: Effect of lidocaine on somatosensory evoked response and cerebral blood flow after canine cerebral air embolism. *Stroke* 1992; 23:1515-20
16. Reasoner DK, Hindman BJ, Dexter F, Subieta A, Cutkomp J, Smith T: Doxycycline reduces early neurologic impairment after cerebral artery air embolism in the rabbit. *ANESTHESIOLOGY* 1997; 87:569-76
17. Osborn AG, ed: *Stroke, Diagnostic neuroradiology*. St. Louis, Mosby-Year Book, 1994, pp 347-98
18. Vallee J-N, Feydy A, Carlier RY, Mutschler C, Mompont D, Vallee CA: Chronic cervical radiculopathy: Lateral approach periradicular corticosteroid injection. *Radiology* 2001; 218:886-92