

Mechanism of Pupillary Reflex Dilation in Awake Volunteers and in Organ Donors

Laura L. Yang, M.D.,* Claus U. Niemann, M.D.,† Merlin D. Larson, M.D.‡

Background: The mechanism of reflex pupillary dilation was investigated in eight patients who were declared brain dead after rupture of intracranial vascular malformations and in eight awake volunteers. The authors hypothesized that the reflex was primarily a spinal sympathetic reflex that would be blocked by topical application of the α_1 -adrenergic blocking agent dapiprazole and that it would be present in organ donors with intact spinal reflexes and no history of hypoxia.

Methods: In volunteers, pupil size was measured with an infrared pupillometer while brief painful electric stimuli were delivered to the finger. Pain was assessed with a visual analog scale and adjusted with each volunteer to equal 3 on a visual analog scale of 0-10. Subjects were studied before and after topical application of the α_1 -adrenergic antagonist dapiprazole. In organ donors, the authors measured pupil size after high-intensity tetanic electric stimulation and in dapiprazole-blocked and -unblocked pupils after surgically induced nociception.

Results: In volunteers, the pupil dilated 0.43 ± 0.23 mm after nociceptive stimuli. Dapiprazole eyedrops blocked this dilation, confirming that the reflex in awake humans is primarily a sympathetic reflex. Baseline diameters were 5.7 ± 0.5 mm before dapiprazole and 4.1 ± 0.9 mm after dapiprazole. In organ donors, a tetanic electric current failed to dilate the pupil, whereas the skin incision dilated the pupil 0.4 ± 0.4 mm, but this dilation was not blocked by dapiprazole.

Conclusion: The authors conclude that pupillary reflex dilation, as it is clinically performed in awake subjects by stimulating somatic nociceptors, is a sympathetic reflex. Because it is not present in organ donors, the neural pathway must require a supraspinal component for completion.

PUPILLARY reflex dilation (PRD) was originally described by Budge in 1852 as a sympathetic spinal reflex that dilated the pupil after noxious stimulation.¹ He proposed that painful stimuli excited the sympathetic efferents arising in the upper thoracic spinal cord segments *via* a spinal reflex. However, an extensive animal study by Loewenfeld showed that the reflex is not completed in the spinal cord but traverses a pathway through the midbrain before the combined effect of inhibition of the pupilloconstrictor nucleus and activation of the preganglionic sympathetic neurons initiates pupillary dilation.²

In awake human subjects, some investigators have concluded that PRD is essentially a spinal sympathetic reflex, thus confirming Budge's original theory.^{3,4} Other investigators have concluded that the reflex is not sympathetically mediated in humans and occurs primarily through inhibition of the pupilloconstrictor nucleus.⁵ In support of this, it has been shown that in anesthetized humans, there is no sympathetic component to PRD caused by noxious stimulation.⁶

Recently, it has been suggested that evaluation of this reflex might be valuable in certain clinical and research settings. It has been used to define the extent of sensory block during combined epidural-general anesthesia.⁷ Jorgensen has hypothesized that the return of PRD may help to predict neurologic outcome after cardiopulmonary resuscitation.⁸ Others have proposed that the reflex might provide insight into central processing of nociceptive stimuli.^{9,10} A purely spinal sympathetic reflex would not provide significant useful experimental information relating to central nociceptive processing. Furthermore, it would not be likely that return of a spinal reflex would predict meaningful neurologic recovery after cardiac arrest.

Therefore, we conducted the following study to investigate the mechanism of PRD in humans. Our hypothesis was that if the reflex were a sympathetic reflex, it would be blocked by the topical application of the α_1 -adrenergic antagonist dapiprazole.^{6,11} Furthermore, if it was a strictly spinal reflex, it would be present in organ donors with intact spinal sympathetic reflexes.

Although PRD has many names in the medical literature, such as the ciliospinal reflex,¹ reflex pupillary dilation,² phasic pupil dilation,¹⁰ and pupil dilation response,¹⁰ we will use the term *pupillary reflex dilation* (PRD) to indicate dilation of the pupil caused by nociceptive stimuli.

Methods

With approval of the Committee on Human Research (University of California, San Francisco, California), we studied eight consenting volunteers and eight organ donors.

Volunteers

Volunteers were healthy, were taking no medications, and had no history of eye disease. Subjects lay supine in a dimly lit room with ambient light set at approximately 150 lux. Surface silver-gel electrodes were placed on the middle finger approximately 2 cm apart, and a constant

* Research Associate, Department of Anesthesia and Perioperative Care, University of California, San Francisco. Current position: Anesthesia Resident, University of Colorado, Denver, Colorado. † Assistant Professor of Anesthesia, ‡ Professor of Anesthesia, Department of Anesthesia and Perioperative Care, University of California, San Francisco.

Received from the Department of Anesthesia and Perioperative Care, University of California, San Francisco, California. Submitted for publication March 5, 2003. Accepted for publication June 27, 2003. Support was provided solely from institutional and/or departmental sources.

Address reprint requests to Dr. Larson: Department of Anesthesia and Perioperative Care, University of California, San Francisco, 521 Parnassus Avenue, Room C450, Box 0648, San Francisco, California 94143-0648. Address electronic mail to: larsonm@anesthesia.ucsf.edu. Individual article reprints may be purchased through the Journal Web site, www.anesthesiology.org.

current of 100 Hz was applied for 0.1 s. The current was applied starting at 0 mA and increased in intensity until the subject experienced pain. The current was then set at a current sufficient to rate a score of 3 on a visual analog scale ranging from 0 (no pain) to 10 (worst pain).

After a period of rest, scans were taken with or without stimulation in a random sequence. After five scans with stimulation and five scans without stimulation, two drops of 0.5% dapiprazole were applied to the right eye. Dapiprazole eyedrops were repeated in the same dose 5 min later. Volunteers returned 1 h later to record the extent of PRD in the dapiprazole-blocked right eye. At this time, another two drops of 0.5% dapiprazole were instilled into the right eye. Previous studies have reported that this dose completely blocks mydriasis resulting from a topical challenge of α_1 -adrenergic agonists.¹¹

During this second session, attention was paid to elicit the same degree of pain by adjusting the delivered current to elicit a visual analog scale score of 3 after the nociceptive stimulus. The currents used were similar in both sessions. After the random recording of five scans with stimulus and five scans without stimulus, two drops of 2.5% phenylephrine were instilled into the right eye, and the diameter was measured 30–45 min later. Lack of pupillary dilation to this phenylephrine challenge was considered evidence of blockade of the adrenergic receptor on the dilator muscle.

Pupillary measurements were taken using an infrared pupillometer (Fairville Medical Optics, Buckinghamshire, United Kingdom).¹² The instrument was programmed to scan the pupil at a rate of 20 Hz for 2 s. To avoid recording possible dilations of the pupil brought by the measurement itself and/or anticipation of the stimulus, we subtracted the averaged scans taken from the volunteer subjects without stimulus from the averaged scans with stimulus. The area below the curve from this scan was used to quantitate the amount of pupillary dilation caused by the stimulus.¹³ Blink artifacts were detected by brief periods of extensive rapid changes in pupil diameter (constriction and redilation velocities greater than 15 mm/s) and were removed by averaging the diameters before and after each blink.

Organ Donors

Pupillary reflex dilation was measured in six subjects with ruptured intracranial aneurysms and two subjects with a ruptured arteriovenous malformation. No evidence of spinal cord injury was present in any subject, and none of the subjects had been hypoxic or had a previous cardiac arrest. Brain death was determined by absence of brain stem reflexes, absent respiratory drive at increased $Paco_2$ (apnea test), and transcranial Doppler ultrasonography. All subjects were studied in the operating room during collection of kidney and/or liver donor organs. Two drops of 0.5% dapiprazole were administered topically onto the corneal surface of the left eye

1 h before the anticipated time of operation and repeated 5 min later. Two drops of 0.5% dapiprazole were instilled again into the left eye at the time of arrival in the operating room. Previous studies have shown that this dose of dapiprazole completely blocks the sympathetic dilation of the pupil caused by arrest of the circulation in organ donors.¹⁴

Management in all cases consisted of paralysis with nondepolarizing muscle relaxants, continuous mechanical ventilation, and infusions of phenylephrine (rate, 0–150 $\mu\text{g}/\text{min}$) and/or dopamine (3–10 $\mu\text{g} \cdot \text{kg}^{-1} \cdot \text{min}^{-1}$). Anesthetic agents and opioids were not administered. Routine monitoring included invasive blood pressure, central venous pressure, electrocardiography, pulse oximetry, and esophageal body temperature.

We searched for possible pupillary dilations resulting from stimulation of nociceptive afferents. The first nociceptive stimulus was delivered before the skin incision and consisted of tetanic electrical stimuli delivered to the C5 dermatome. Stimuli were administered for the duration of a 2-s pupillary scan *via* stainless steel electrodes with 70 mA of 100-Hz electric current. Because there is less pupillary noise in organ donors compared to awake subjects, only two scans from each subject were taken without stimulation, and two were taken with stimulation. Electrodes were placed 2 cm apart over the C5 dermatome. Stimuli began from the start of the scan. We have previously demonstrated a nearly threefold increase in pupillary diameter with this method in anesthetized volunteers and have used it to quantify opioid effect during general anesthesia.^{13,15} We measured the diameter of the right pupil during noxious stimulation while it was covered with a rubber eye cup; the left eye was covered with an opaque dressing.

The second stimulus was the skin incision, which extended from the suprasternal notch to the pubis. Two pupil diameter measurements were made from both eyes at 1 min before the skin incision. Diameters were again measured from both eyes 8 min after the skin incision. Infusion rates of vasopressors were kept constant during the time required for recording pupillary responses to these nociceptive stimuli. Systolic blood pressure and heart rate were recorded at the time of pupillary measurements. With four cases, intermittent bilateral pupillary measurements were taken throughout the case, extending through the cross clamp period.

Statistical Analysis

Volunteers. The pupillary dilations resulting from stimulations before and after dapiprazole were compared using paired two-tailed *t* tests. We compared maximum dilation and area below the curve before and after dapiprazole. To assess whether the pupil dilated after dapiprazole treatment, we used unpaired *t* tests to compare the maximum dilations and area below the curve of

Table 1. Demographics of Volunteers and Organ Donors

	Volunteers (n = 8)	Brain-dead Subjects (n = 8)
Age, yr	32.0 ± 11.8	57.1 ± 16.6
M/F, No.	4/4	5/3
Weight, kg	75.5 ± 16.2	71.2 ± 12

the adjusted postdapiprazole scans with the scans taken from organ donors without stimulation.

Organ Donors. Pupillary dilations resulting from tetanic electric noxious stimulation were compared using two-tailed paired *t* tests of those scans taken without stimulation. Pupil sizes, heart rate, and systolic blood pressure before and after skin incision were compared using two-tailed paired *t* tests. All data are reported as mean ± SD; *P* < 0.05 was considered statistically significant. A power analysis revealed that eight subjects would be required to detect a 0.5-mm difference (10 times the resolution of the instrument) in the dilation of the left and right pupils with a power of 0.9 and an α of less than 0.05.

Results

Demographic data from volunteers and organ donors are shown in table 1. Noxious stimulation resulted in pupillary dilation in all eight volunteers, with a mean dilation of 0.43 ± 0.23 mm and peak dilation at 1.2 ± 0.4 s. Blockade of the α_1 -adrenergic receptor with dapiprazole eliminated statistically significant pupillary dilation after the same degree of noxious stimulation (table 2). The area below the curve was not different for the postdapiprazole trials compared to scans of the same duration taken without stimulation in organ donors (*P* = 0.9; tables 2 and 3). The average size of the pupil before phenylephrine challenge was 4.1 ± 0.9 mm, and the average size after phenylephrine was 4.0 ± 0.95 mm (not significant).

Organ donors were studied 26.4 ± 10.8 h after the diagnosis of brain death was established. During this interval, organ perfusion was maintained with small doses of vasopressors and careful attention to fluid balance. At the time of arrival in the operating room, the average phenylephrine infusion rate was 52 ± 58 μ g/

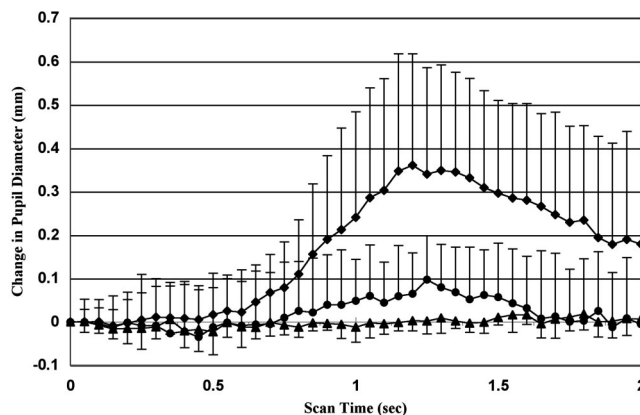


Fig. 1. Changes in pupil diameter for 2 s after 0.1-s tetanic stimulation before (*diamonds*) and after (*circles*) dapiprazole eyedrops in eight volunteers. *Triangles* indicate the average pupil size for 2 s taken from organ donors. In all plots, stimulation begins at the start of the scan (time 0). Data are presented as mean and SD.

min, and the average dopamine infusion rate was 3.4 ± 2.3 μ g · kg⁻¹ · min⁻¹. One subject was also receiving 1 μ g/min epinephrine in addition to the two other vasopressors.

Before stimulation, the diameter of the left blocked pupil was smaller than the right unblocked pupil in three cases, larger in three cases, and equal (within 0.1 mm) in two cases. Noxious stimulation of somatic afferents by tetanic stimulation failed to dilate the pupil in any of the organ donors (fig. 1; table 3). However, after the skin incision, there was a significant dilation of both pupils in each subject, with a range of 0.1 to 0.6 mm (table 4). In these subjects, the unblocked eye dilated 0.4 ± 0.4 mm, whereas the left (blocked) eye dilated 0.3 ± 0.2 mm compared to the average preincision diameter. The difference (0.13 mm) in dilations between the right (unblocked) and left eyes (blocked) (0.13 mm) was not significant (95% confidence interval, 0.12 to 0.38; *P* = 0.26). One of the four cases illustrating continued pupillometry throughout the cross clamp period is shown in figure 2.

Discussion

This study demonstrates that PRD in awake subjects is sympathetically mediated. In contrast, organ donors ex-

Table 2. Pupillary Changes after Noxious Stimulation before and after Dapiprazole in Awake Volunteers

	Before Dapiprazole*	After Dapiprazole*	Effect Size (95% CI)	<i>P</i> Value
Initial pupil size (before stimulation), mm	5.7 ± 0.5	4.1 ± 0.9	-1.6 ± 0.7 (-1.1 to -2.1)	0.0001
Maximum pupillary dilation, mm	0.43 ± 0.23	0.13 ± 0.1	-0.3 ± 0.3 (-0.1 to -0.5)	0.01
Time to maximum pupillary dilation, s	1.2 ± 0.4	1.4 ± 0.5	0.2 ± 0.7 (NS)	0.6
Area below the curve, mm-s	7.8 ± 5.4	0.8 ± 3.7	-7.0 ± 6.3 (-2.1 to -11.9)	0.01
Current, mA	0.96 ± 0.8	1.04 ± 0.8	0.08 ± 0.11 (NS)	0.05

* Scans shown in figure 1.

CI = confidence interval; NS = not significant.

Table 3. Effect of Noxious Electrical Stimulation of Cervical Dermatomes in Organ Donors

	Initial Pupil Size	Maximum Pupillary Dilation	Area Below Dilation Curve, mm-s
No stimulation—brain-dead subjects	5.9 ± 1.0	0.07 ± 0.08	0.9 ± 1.8
Electric stimulation—brain-dead subjects	5.9 ± 1.0	0.05 ± 0.03 (NS)	-0.1 ± 0.8* (NS)

* Scan shown in figure 1.

NS = not significant.

hibited no pupillary dilation after activation of somatic nociceptors by electrical stimulation, but small dilations, not sympathetically mediated, were observed after skin incision. We conclude that the neural pathways involved in PRD involve supraspinal pathways.

There is evidence from animals that the center for this reflex is not in the spinal cord. Studies with cats have shown that a midcollicular decerebration completely eliminates PRD. For example, Bremer was unable to produce dilation of the pupil after painful (electric) somatic stimuli after midcollicular decerebration caudal to the pupilloconstrictor nucleus.¹⁶ Loewenfeld noted that even higher transections, such as supracollicular decerebrations, eliminated the sympathetic component of pupillary dilation after painful stimuli.² Loewenfeld placed the reflex center for the sympathetic contribution to PRD within the thalamus and considered that anesthetics produced a blockade in the pathway from the thalamus to the hypothalamus (fig. 3).

The evidence that PRD is solely a spinal sympathetic reflex, without traversing more cephalad pathways, arises from studies on patients with partial or complete spinal cord injuries. Arief and Pyzik studied 19 patients with cervical cord lesions.³ They noted pupillary dilation when the upper thoracic dermatomes were stimulated but no change in pupil diameter when the face was stimulated. These authors concluded that a spinal sympathetic reflex was the sole mechanism involved in PRD in humans. However, there is recent evidence that new synaptic connections can be made on the preganglionic sympathetic neurons after spinal cord injury,^{17,18} and these new pathways may contribute to the exaggerated autonomic reflexes observed in quadriplegic patients. Therefore, the sympathetic reflex that dilates the pupil might become a pronounced segmental spinal reflex in the spinal cord injured patient even though it was a supraspinal reflex in the intact subject.

In contrast to our results, Reeves and Posner reported that PRD was present in six of seven patients with

rostrocaudal transtentorial herniation.⁴ Another group of patients in the same study with “central sympathetic denervation” also had brisk PRD responses. It is unclear whether other brain stem reflexes were present in their patients, but from the clinical descriptions, it seems that the majority of the patients retained some midbrain reflexes. Although the authors proposed that there was a complete interruption of the central sympathetic pathways, they did not perform the confirmatory topical cocaine test.^{19,20} Furthermore, there were no tests undertaken to confirm that these pupillary dilations resulted from activation of the spinal sympathetic fibers. Ablation of the pupillary dilations after topical α_1 -adrenergic blockade or after cervical sympathetic blockade would have confirmed that these reflexes were sympathetic in origin and not secondary to inhibition of the pupilloconstrictor nucleus.

Our results suggest that organ donors have an autonomically denervated iris that does not respond to nociceptive stimuli *via* a sympathetic response. Therefore, our failure to observe the typical Horner pupil (anisocoria) in brain-dead subjects after dapiprazole treatment is consistent with a lack of tonic innervation of the dilator muscle. Apparently, the doses of vasopressors that we administered and the adrenergic response to incision were insufficient to sympathetically dilate the pupil in our study, but this hormonal/intravenous effect would depend on the adrenergic levels attained in each individual case. Asphyxia does usually provide an increase of α_1 -adrenergic activity that results in pupillary dilation (fig. 3).⁶

The tetanic stimulus that we delivered is a profound stimulus,²¹ and this did not dilate the pupil. However, we did observe a small dilation of the pupil after the skin incision in both the blocked and the unblocked pupils. For this reason, we believe that this nonsympathetic dilation is due to factors other than activation of nociceptors. Therefore, this dilation might occur secondary to the re-

Table 4. Autonomic Changes Brought about Skin Incision in Organ Donors

	1 min before Incision	8 min after Incision	Effect Size (95% CI)	P Value
Pupil size—right, unblocked, mm	6.0 ± 1.3	6.4 ± 1.6	0.4 ± .4 (0.13–0.72)	0.01
Pupil size—left, blocked, mm	6.1 ± 1.3	6.4 ± 1.4	0.3 ± 0.2 (0.1–0.47)	0.008
Systolic blood pressure, mmHg	125.2 ± 22.6	163.8 ± 32.4	38.5 ± 27 (16–61)	0.005
Heart rate, beats/min	97.4 ± 19.3	110.8 ± 13.7	14 ± 13.5 (2–25)	0.03

CI = confidence interval.

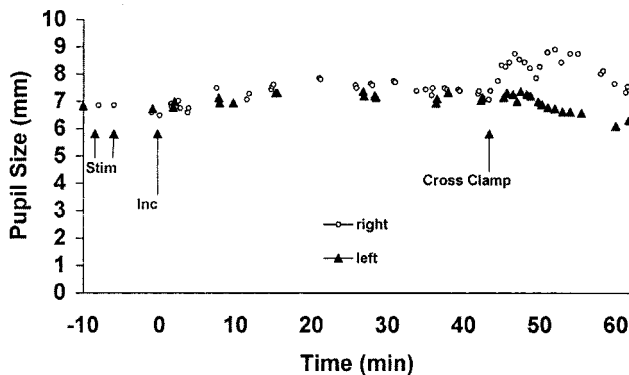


Fig. 2. Pupil changes during organ procurement. A 27-yr-old woman experienced intracranial hemorrhage from a ruptured basilar tip aneurysm. Brain death was declared 18 h before surgery. The left pupil (*triangles*) was treated with topical dapiprazole. Vasoactive drugs included $3 \mu\text{g} \cdot \text{kg}^{-1} \cdot \text{min}^{-1}$ dopamine and $1.5 \mu\text{g} \cdot \text{kg}^{-1} \cdot \text{min}^{-1}$ phenylephrine. Note that tetanic stimulation did not dilate the pupil, but the skin incision resulted in small bilateral dilations. Cross-clamping of the aorta dilated the unblocked pupil (*circles*), but the dapiprazole-treated pupil showed only a progressive constriction.

lease of chemical mediators, possibly histamine or related compounds, mobilized during tissue dissection.²²

Depression of the preganglionic sympathetic neurons

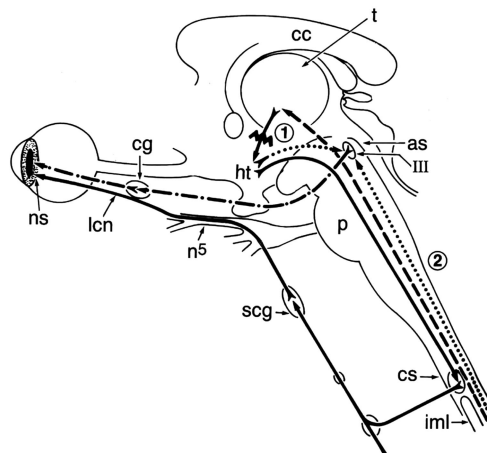


Fig. 3. Schematic representation of neural pathways that control pupil size in humans. The efferent sympathetic pathway begins in the thalamus and is shown by the *solid line*. General anesthesia is thought to produce blockade at the site between the thalamus and the hypothalamus (*t*). Note that the afferent sympathetic pathway bypasses the ciliospinal center (*cs*) and continues cephalad to the thalamus. The efferent parasympathetic pathway begins in the nucleus of the third cranial nerve and is shown by the *dotted-dashed line*. Inhibitory pathway (*dotted pathways*) into the parasympathetic nucleus arises within either the hypothalamus or *via* the spinotectal pathway. Local anesthetics block the afferent pathways from the spinal cord (2). as = aqueduct of Sylvius; cc = corpus callosum; cg = ciliary ganglion; cs = ciliospinal center of Budge, mostly T1 and T2 segments of the intermediolateral cell column; ht = hypothalamus; iml = intermediolateral cell column; lcn = long ciliary nerves; ns = neuromuscular synapse of postganglionic sympathetic nerves; n5 = ophthalmic division of the fifth nerve; p = pons; pc = posterior commissure; scg = superior cervical ganglion; t = thalamus; III = oculomotor nucleus. Adapted with permission from Loewenfeld.²

by spinal shock is an unlikely explanation for the lack of sympathetically induced pupillary dilation in the organ donors. Crenna *et al.*²³ have studied the return of spinal reflexes in brain-dead subjects and observed depressed nociceptive reflexes for up to 12 h after the declaration of brain death. Our studies were performed outside this time period and therefore should not be confounded by the presence of spinal shock. Furthermore, the marked blood pressure and heart rate changes that we observed after incision indicate intact spinal sympathetic reflexes innervating vascular beds. Several previous studies have demonstrated intact spinal sympathetic reflexes²⁴ and robust increases in epinephrine and norepinephrine after skin incision in organ donors.²⁵⁻²⁸

The small residual reflex that we observed in our dapiprazole-blocked volunteers is apparent on the averaged scan shown in figure 1, but the difference between this averaged postdapiprazole scan and the averaged scan taken without stimulation in organ donors was not statistically significant. We suggest that there may be a small dilation not due to sympathetic mechanisms in awake humans, but our stimulus and recording methods were not robust enough to demonstrate it with this number of volunteers. In animals, the small residual PRD after sympathectomy is thought to be due to inhibition of the pupilloconstrictor nucleus.² This reflex, which is not mediated by the sympathetic nervous system, is prominent in anesthetized human subjects.¹²

Our current findings, together with our previous data on this reflex in anesthetized subjects,⁶ are most consistent with information obtained from animals during electrical stimulation of peripheral nerves. These studies reported that in awake animals, nociceptive stimulation produced primarily sympathetic pupillary dilation, but during general anesthesia, the sympathetic dilations were completely abolished and were replaced by dilations resulting entirely through inhibition of the pupilloconstrictor nucleus (fig. 2).²⁹ Therefore, it seems that in animals² and also in humans, either awake or anesthetized, the neural reflex pathway for pupillary dilation after nociceptive stimulation must reach as far cephalad as the mesencephalon.

Our findings support the view of Jorgenson that PRD requires a partially intact midbrain. His studies have reported that PRD returns after successful cardiopulmonary resuscitation, but only after the return of the pupillary light reflex.⁸ Jorgenson has suggested that central reflexes usually return in a caudal to rostral manner, and this would imply that the center for PRD is located at a more cephalad location than the pupillary light reflex.

Several investigators have proposed that PRD might be used as a tool to investigate central processing of nociceptive information.^{9,10,30} Chapman *et al.*¹⁰ have noted that the extent of PRD is correlated with the intensity of noxious stimulation. In their studies, PRD magnitude was predicted by an evoked potential (N150) thought to

reflect preconscious cognitive activity. Ellermeier and Westfal evoked pain by applying finger pressure and observed that the resulting pupillary dilation correlated with the subjective assessment of pain.⁹ In addition, it has been shown that pupillary dilation after noxious stimulation in the anesthetized cat arises primarily from activation of the A δ and C fibers that subservise the sensation of pain.³¹ The observation that epidural analgesia effectively blocks PRD during general anesthesia supports the view that nociception contributes significantly to the reflex during general anesthesia.⁷

In summary, we have confirmed our hypothesis that PRD in awake humans is almost exclusively a sympathetic reflex but were unable to detect sympathetically mediated dilation in subjects with brain death secondary to intracranial hemorrhage. The neural mechanisms that dilate the pupil in humans after noxious stimulation must traverse a supraspinal pathway. Therefore, this reflex might provide prognostic information after cardiopulmonary resuscitation and also be a useful tool during studies relating to central processing of nociceptive stimuli.

The authors thank Chuck E. McCulloch, Ph.D. (Professor of Biostatistics, Department of Biostatistics, University of California, San Francisco, California), for statistical advice.

References

- Budge J: *Über den Einfluss des nerven systems auf die Bewegung des Iris*. Arch Philol Heilk 1852; 2:773-9
- Loewenfeld IE: Mechanism of reflex dilation of the pupil: Historical review and experimental analysis. Doc Ophthalmol 1958; 12:185-448
- Arief A, Pyzik S: The ciliospinal reflex in injuries of the spinal cord in man. Arch Neurol Psychiat 1953; 70:621-5
- Reeves A, Posner J: The ciliospinal response in man. Neurology 1969; 19:1145-52
- McNealy D, Plum F: Brainstem dysfunction with supratentorial mass lesions. Arch Neurol 1962; 7:10-32
- Larson MD, Tayefeh F, Sessler DI, Daniel M, Noorani M: Sympathetic nervous system does not mediate reflex pupillary dilation during desflurane anesthesia. ANESTHESIOLOGY 1996; 85:748-54
- Larson MD, Sessler DI, Ozaki M, McGuire J, Schroeder M: Pupillary assessment of sensory block level during combined epidural-general anesthesia. ANESTHESIOLOGY 1993; 79:42-48
- Jorgensen E: Course of neurological recovery and cerebral prognostic signs during cardio-pulmonary resuscitation. Resuscitation 1997; 35:9-16
- Ellermeier W, Westfal W: Gender differences in pain ratings and pupil reactions to painful pressure stimuli. Pain 1995; 61:435-9
- Chapman C, Oka S, Bradshaw D, Jacobson R, Donaldson G: Phasic pupil dilation response to noxious stimulation in normal volunteers: Relationship to brain evoked potentials and pain report. Psychophysiology 1999; 36:44-52
- Schmidbauer J, Hoh H, Franke G, Petsch E, Siegmund W: Clinical use of mydriasis with 10% phenylephrine and its antagonism by 0.5% dapiprazole. Ophthalmologie 1999; 96:182-6
- Larson M, Sessler D, Washington D, Merrifield B, Hynson J, McGuire J: Pupillary response to noxious stimulation during isoflurane and propofol anesthesia. Anesth Analg 1993; 76:1072-8
- Larson MD, Berry PD: Supraspinal pupillary effects of intravenous and epidural fentanyl during isoflurane anesthesia. Reg Anesth Pain Med 2000; 25:60-6
- Larson M, May J: Effect of asphyxia on the pupils of brain dead subjects. Resuscitation 2002; 55:31-6
- Larson M, Kurz A, Sessler DI, Dechert M, Bjorksten AR, Tayefeh F: Alfentanil blocks reflex pupillary dilation in response to noxious stimulation but does not diminish the light reflex. ANESTHESIOLOGY 1997; 87:849-55
- Bremer F: *Cerveau isole' et physiologie du sommeil*. Compte Rendu Soc Biol 1935; 118:1235-41
- Weaver L, Cassam A, Krassioukov A, Llewellyn-Smith I: Changes in immunoreactivity for growth associated protein-43 suggest reorganization of synapses on spinal sympathetic neurons after cord transection. Neuroscience 1997; 81:535-51
- Krenz N, Weaver L: Changes in the morphology of sympathetic preganglionic neurons parallel the development of autonomic dysreflexia after spinal cord injury in rats. Neurosci Lett 1998; 243:61-4
- Thompson HS: Diagnosing Horner's syndrome. Trans Am Acad Ophthalmol Otolaryngol 1977; 83:840-2
- Racz J: Topical diagnosis of Horner's syndrome on the basis of the Foerter-Gage test. Albrecht Von Graefes Arch Klin Exp Ophthalmol 1967; 172:69-73
- Laster MJ, Liu J, Eger EI II, Taheri S: Electrical stimulation as a substitute for the tail clamp in the determination of minimum alveolar concentration. Anesth Analg 1993; 76:1310-2
- Kamei C: Effects of histamine and related compounds on the bovine iris dilator. Methods Find Exp Clin Pharmacol 1996; 18:273-8
- Crenna P, Conci F, Boselli L: Changes in spinal reflex excitability in brain-dead humans. Electroenceph Clin Neurophysiol 1989; 73:206-14
- Kuwagata Y, Sugimoto H, Yoshioka T, Sugimoto T: Hemodynamic response with passive neck flexion in brain death. Neurosurgery 1991; 29:239-41
- Pennefather S, Dark J, Bullock R: Haemodynamic responses to surgery in brain-dead donors. Anaesthesia 1993; 48:1034-8
- Fitzgerald R, Dechtyar I, Templ E, Fridrich P, Lackner F: Cardiovascular and catecholamine response to surgery in brain-dead organ donors. Anaesthesia 1995; 50:388-92
- Gramm H, Zimmerman J, Meinhold H, Dennhardt R, Voigt K: Hemodynamic responses to noxious stimuli in brain-dead organ donors. Intensive Care Med 1992; 18:493-5
- Wetzel R, Setzer N, Stiff J, Rogers M: Hemodynamic responses in brain dead organ donor patients. Anesth Analg 1985; 64:125-8
- Bonvellet M, Zbronzna A: Les commandes reticulaires du systeme autonome et en particulier de l'innervation sympathetique et parasymphetique de la pupille. Arch Ital Biol 1963; 101:174-207
- Havelius U, Henck M, Milos P, Hindfelt B: Ciliospinal reflex response in cluster headache. Headache 1996; 36:568-73
- Evans M: The spinal pathways of the myelinated and the non-myelinated afferent nerve fibers that mediate reflex dilation of the pupils. J Physiology 1961; 158:560-72