

Ropivacaine-induced Cardiac Arrest after Peripheral Nerve Block: Successful Resuscitation

Pascal Chazalon, M.D.,* Jean P. Tourtier, M.D.,* Thierry Villevielle, M.D.,* Didier Giraud, M.D.,* Jean M. Saïssy, M.D.,† Georges Mion, M.D.,‡ Dan Benhamou, M.D.§

ROPIVACAINE is an amide local anesthetic with a long duration of action that was developed because of the high risk of cardiac complications induced by bupivacaine.¹ Preclinical studies have confirmed its reduced systemic and cardiac toxicity as compared with bupivacaine,^{2,3} and clinical studies have also been very reassuring regarding the risk of ropivacaine-induced systemic toxicity.^{4,5} There have, however, been several case reports in which significant cardiac side effects have occurred, but in none of them did the cardiac abnormalities progress to cardiac arrest or death.⁶ We report a clinical case in which cardiac arrest occurred, after neurologic complications, during lower limb regional anesthesia using ropivacaine, but resuscitation was successful.

Case Report

A 66-yr-old woman (height, 150 cm; weight, 45 kg; American Society of Anesthesiologists physical status II) was scheduled for right hallux valgus surgery with the patient receiving regional anesthesia. The patient had a single kidney, but her medical history disclosed no renal dysfunction. She presented with no cardiac, neurologic, or pulmonary alterations. Her unique treatment was hormone replacement therapy. She had already undergone left hallux valgus surgical treatment 3 months ago in the same institution. Although regional anesthesia had failed for the first procedure and general anesthesia had to be used, the patient agreed that regional anesthesia be tried again. Hydroxyzine (50 mg) was given as premedication 2 h before the procedure. The regional block was performed in the preanesthetic room while the patient was monitored using three-lead electrocardiography, noninvasive blood pressure determination, and pulse oximetry. Her initial blood pressure and heart rate were 155/70 mmHg and 92 beats/min,

respectively. An 18-gauge venous catheter was placed in her left forearm and infused with lactated Ringer's solution. Midazolam (2 mg) was given before the event because of anxiety. Once administration of oxygen (3 l/min via a facemask) was started, arterial oxygen saturation increased from 98% to 100%. After skin disinfection and local anesthesia with 2 ml lidocaine (1%), the patient was placed in the ventral decubitus, and the sciatic nerve was located in the popliteal fossa using nerve stimulation (STIMUPLEX-DIG; B. Braun Melsugen AG, Germany). A tibial nerve response was obtained at 0.4 mA (lowest intensity), and 25 ml ropivacaine (0.75%) was slowly injected (time 0) after a negative aspiration test, disappearance of the motor response after injection of 1 ml, and absence of pain and/or paresthesia. A popliteal catheter was placed for postoperative analgesia. Thirty minutes later, the saphenous nerve was subcutaneously infiltrated with 5 ml ropivacaine (0.75%),⁷ and two additional injections were given at the ankle because of inadequate efficacy of the block: 4 ml ropivacaine (0.75%) was injected in the tibial nerve using nerve stimulation (0.4 mA), and 6 ml ropivacaine (0.75%) was infiltrated subcutaneously in the superficial and deep peroneal nerves. The total dose of ropivacaine was 300 mg.

Sixty minutes later, the patient became agitated and confused, which was followed by loss of consciousness and oculogyric movements. Intravenous midazolam (2 mg) was injected, and mask ventilation was started. Bradycardia (heart rate, <50 beats/min) with hypotension (blood pressure, 90/60 mmHg) progressively appeared. Although the patient received 6 mg ephedrine and 1 mg atropine, bradycardia worsened (heart rate, 30 beats/min), whereas the QRS complex became larger and progressed to asystolic cardiac arrest. Cardiac massage was started, and 6 mg ephedrine was injected. Thirty seconds later, effective cardiac and respiratory activities reappeared, and sinus tachycardia rhythm was recorded. The patient responded to stimulation, and oxygen administration was continued. At 70 min, glucose, electrolyte, and troponin plasma concentrations were normal, whereas the ropivacaine plasma concentration measured using gas chromatography was 1.88 mg/l. The surgical procedure was performed under regional anesthesia after the patient had awakened. The patient had no awareness of the incident, had no sequelae, and was informed.

Discussion

Ropivacaine is an amino amide local anesthetic that differs from bupivacaine by the substitution of a propyl group for a butyl group on the nitrogen of the piperidine group. This substitution, which is associated with a lower lipid solubility and commercial release as a pure *S*-enantiomer, confers to ropivacaine a neurologic and cardiac toxicity inferior to that of an equal dose of bupivacaine.^{8,9} Greater safety is expected with use of large doses. In different studies, extremely high ropivacaine plasma concentrations after regional anesthesia (from 2 to 5.6 mg/l) were obtained without neurologic and cardiac toxicity.^{4,5} Several accidents after ropivacaine use have, however, been reported. Table 1 summarizes previously reported cases in which total ropivacaine venous plasma concentrations were ob-

This article is accompanied by an Editorial View. Please see: Polley LS, Santos AC: Cardiac Arrest following Regional Anesthesia with Ropivacaine: Here We Go Again! ANESTHESIOLOGY 2003; 99:1253-4.

* Physician Anesthesiologist, † Professor, Chief of Staff, Federation of Anesthesia and Intensive Care, Hôpital d' Instruction des Armées Bégin. ‡ Professor, Chief of Staff, Department of Anesthesiology, Hôpital d' Instruction des Armées du Val-de-Grâce, Paris, France. § Professor, Chief of Staff, Department of Anesthesiology, Centre Hospitalier Universitaire de Bicêtre, Le Kremlin-Bicêtre, France.

Received from the Federation of Anesthesia and Intensive Care, Hôpital d' Instruction des Armées Bégin, Saint-Mande, France. Submitted for publication March 31, 2003. Accepted for publication July 30, 2003. Support was provided solely from institutional and/or departmental sources.

Address reprint requests to Dr. Chazalon: 7, Avenue Watteau, 94130 Nogent sur Marne, France. Address electronic mail to: pchzn@club-internet.fr. Individual article reprints may be purchased through the Journal Web site, www.anesthesiology.org.

Table 1. Previously Reported Cases of Severe Neurologic or Cardiac Adverse Effects Induced by Ropivacaine after Regional Anesthesia

Regional Anesthetic Technique, Reference No.	Dose of Ropivacaine Injected (mg)	Side Effect(s)	Plasma Concentration (mg/l)*	Time (min)	Proposed Mechanism
Epidural anesthesia ¹⁰	20	Convulsions, sinus tachycardia, intraventricular conduction defect	1.4	40	Intravascular injection
Epidural anesthesia ¹¹	279 mg/5 h (150 mg in 3 bolus last 30 min)	Convulsions	3.5	60	Overdose
Interscalene brachial plexus block ¹²	400	Convulsions	2.09	40	Overdose, 6.15 mg/kg
Interscalene brachial plexus block ¹³	300	Mental confusion, convulsions, sinus tachycardia, arterial hypertension	6.0, 5.4, 4.6, 4.0	40, 60, 80, 98	Overdose, 6 mg/kg
Brachial plexus block ¹⁴	300	Mental confusion convulsions	2.70	2	Intravascular injection
Brachial plexus block ¹⁵	100	Convulsions	3.3, 1.6, 1.2, 1.0	15, 45, 75, 155	Intravascular injection
Midhumeral brachial plexus block ¹⁶	300	Convulsions	2.27	120	Overdose, 4.28 mg/kg
Midhumeral brachial plexus block ¹⁷	262.5	Mental confusion, convulsions, sinus tachycardia	5.22, 3.79	0, 15	Overdose, 5.36 mg/kg
Sciatic nerve block ⁶	225	Convulsions, severe bradycardia, QRS enlargement complex	3.6, 1.6	7, 12	Intravascular injection
Sciatic nerve block + 3-in-1 nerve block ¹⁸	225	Convulsions, sinus tachycardia	3.58	15	Intravascular injection

* Total Ropivacaine plasma concentrations (venous samples).

tained.^{6,10-18} These accidents were the consequence of direct intravascular injections (short onset) or secondary plasma absorption of an overdose (delayed clinical event). In the current case, cardiac arrest occurred. The absence of a neurologic or cardiac history, the time profile, and the symptoms observed suggest a ropivacaine-induced toxic accident. The total dose administered (*i.e.*, 6.7 mg/kg) was definitely excessive. Although it is difficult to recommend a safe maximal dose because of interindividual variability, it is reasonable to accept a maximum ropivacaine dose of 3 mg/kg for an upper limb block and 4 mg/kg for a lower limb block.¹⁹ The total ropivacaine plasma concentration measured 10 min after the toxic event was 1.88 mg/l and appeared to be low compared with those in the available literature (Table 1). This may suggest a particular sensitivity of the patient to local anesthetic toxicity, as has already been observed in ropivacaine toxicity studies.^{2,3} Several healthy volunteers tolerated only low doses, and initial neurologic signs occurred at plasma concentrations (venous samples) between 0.5 and 1 mg/l; one patient tolerated a plasma concentration of 3.2 mg/l.³ Alternatively, the apparently low plasma concentration of ropivacaine might be related to the long interval between injection and cardiac arrest, allowing time for redistribution from blood to tissue and binding to plasma proteins.²⁰

The incidence of ropivacaine-induced cardiovascular events has been described as 6.1 cases per 1,000,000 patients, compared with 8 cases of ropivacaine-induced neurologic convulsions per 1,000,000 patients.²¹ In previously reported cases, cardiac complications during ropivacaine toxic accidents always followed severe neurologic signs (confusion and convulsions). In our case,

however, only oculogyric movements were observed, possibly because the patient had received midazolam before the regional block.

In healthy volunteers, ropivacaine can impair conduction and myocardial contraction, but these events occur at plasma concentrations much higher than with bupivacaine, suggesting better tolerance and thus confirming findings of animal experiments.^{2,3} Moreover, these effects are more rapidly reversible. During the only serious cardiac accident reported so far, ropivacaine was responsible for severe intraventricular and atrioventricular conduction defects, which led to severe bradycardia⁶; the total ropivacaine plasma concentration was 3.6 mg/l (free concentration, 0.69 mg/l) 7 min after the accident, and the authors estimated the plasma concentration to be around 7.5 mg/l during the accident. A similar sequence of event mechanisms occurred in our patient and was associated with depression of myocardial contractility and cardiac arrest. As in the case reported by Ruetsch *et al.*,⁶ resuscitation was immediate and successful. No ventricular arrhythmias were observed. Although cardiopulmonary resuscitation was certainly facilitated by early treatment, the intrinsic lower cardiotoxicity (as compared with bupivacaine) certainly explains the outcome.²² Moreover, the treatment was not only successful but also very simple, contrasting the rash of bupivacaine-associated cardiac arrest that is often very difficult to treat because it may require cardiopulmonary bypass.^{23,24}

We report a case of cardiac arrest induced by ropivacaine overdose. Cardiorespiratory resuscitation was successful and easy to perform, substantiating previous data

showing that ropivacaine is less cardiotoxic than bupivacaine.

References

- Albright GA: Cardiac arrest following regional anesthesia with etidocaine and bupivacaine. *ANESTHESIOLOGY* 1979; 51:285-7
- Scott DB, Lee A, Fagan D, Bowler GMR, Bloomfield P, Lundh R: Acute toxicity of ropivacaine compared with that of bupivacaine. *Anesth Analg* 1989; 69:563-9
- Knudsen K, Beckman Suurküla M, Blomberg S, Sjövall J, Edvarsson N: Central nervous and cardiovascular effects of i.v. infusions of ropivacaine, bupivacaine and placebo in volunteers. *Br J Anaesth* 1997; 78:507-14
- Salonen MHA, Haasio J, Bachmann M, Xu M, Rosenberg PH: Evaluation of efficacy and plasma concentrations of ropivacaine in continuous axillary brachial plexus block: High dose for surgical anesthesia and low dose for post operative analgesia. *Reg Anesth Pain Med* 2000; 25:47-51
- Behnke H, Worthmann F, Cornelissen J, Kahl M, Wulf H: Plasma concentration of ropivacaine after intercostal blocks for video-assisted thoracic surgery. *Br J Anaesth* 2002; 89:251-3
- Ruetsch YA, Fattinger KE, Borgeat A: Ropivacaine-induced convulsions and severe cardiac dysrhythmia after sciatic block. *ANESTHESIOLOGY* 1999; 90:1784-6
- van der Wal M, Lang SA, Yip RW: Transarterial approach for saphenous nerve block. *Can J Anaesth* 1993; 40:542-6
- Sztark F, Malgat M, Dabadie P, Mazat JP: Comparison of the effects of bupivacaine and ropivacaine on heart cell mitochondrial bioenergetics. *ANESTHESIOLOGY* 1998; 88:1340-9
- Graf BM, Abraham I, Eberbach N, Kunst G, Stowe DF, Martin E: Differences in cardiotoxicity of bupivacaine and ropivacaine are the results of physicochemical and stereoselective properties. *ANESTHESIOLOGY* 2002; 96:1427-34
- Plowman AN, Bolsin S, Mather LE: Central nervous system toxicity attributable to epidural ropivacaine hydrochloride. *Anaesth Intensive Care* 1998; 26:204-6

Anesthesiology 2003; 99:1451-3

- Bischoff DY, Alardo JP, Razzgallah B, Just BY, Germain MLY, Millart HG, Trenque TC: Seizure induced by ropivacaine. *Ann Pharmacother* 2001; 35:311-3
- Mardirossoff C, Dumont L: Convulsions after the administration of high dose ropivacaine following an interscalenic block. *Can J Anaesth* 2000; 47:1263
- Ala-Kokko TI, Löppönen A, Alahuhta S: Two instances of central nervous system toxicity in the same patient following repeated ropivacaine-induced brachial plexus block. *Acta Anaesthesiol Scand* 2000; 44:623-6
- Raeder JC, Drosdahl S, Klaastad O, Kvalsvik O, Isaksen B, Stromskag KE, Mowinckel P, Bergheim R, Selander D: Axillary brachial plexus block with ropivacaine 7.5 mg/ml: A comparative study with bupivacaine 5 mg/ml. *Acta Anaesthesiol Scand* 1999; 43:794-8
- Müller M, Litz RJ, Hübler M, Albrecht DM: Grand mal convulsion and plasma concentrations after intravascular injection of ropivacaine for axillary brachial plexus blockade. *Br J Anaesth* 2001; 87:784-7
- Ould-Ahmed M, Drouillard I, Fourel D, Roussaly P, Almanza L, Segalen F: Convulsions induites par la ropivacaine lors d'un bloc au canal huméral. *Ann Fr Anesth Reanim* 2002; 21:681-4
- Eledjam JJ, Gros T, Viel E, Mazoit JX, Bassoul B: Ropivacaine overdose and systemic toxicity. *Anaesth Intensive Care* 2000; 28:705-7
- Petitjeans F, Mion G, Puidupin M, Tourtier JP, Hutson C, Saissy JM: Tachycardia and convulsions induced by accidental intravascular injection of ropivacaine during sciatic block. *Acta Anaesthesiol Scand* 2002; 46:616-7
- Mazoit JX: Toxicité des anesthésiques locaux, Conférences d'actualisation 2002, 44^e Congrès national d'anesthésie réanimation. Edited by Sfar, Paris, Editions scientifiques et médicales Elsevier SAS, et Sfar, 2002, pp 287-301
- Scott DB: Evaluation of the toxicity of local anesthetic agents in man. *Br J Anaesth* 1975; 47:56-61
- Periodic Safety Update Report: Naropin, AstraZeneca, May 17, 2000
- Feldman HS, Arthur GR, Pitkanen M, Hurley R, Doucette AM, Covino BG: Treatment of acute systemic toxicity after the rapid venous injection of ropivacaine and bupivacaine in the conscious dog. *Anesth Analg* 1991; 73:373-84
- Long WB, Rosenblum S, Grady IP: Successful resuscitation of bupivacaine induced cardiac arrest using cardiopulmonary bypass. *Anesth Analg* 1989; 69:403-6
- Tsai MH, Tseng CK, Wong KC: Successful resuscitation of a bupivacaine-induced cardiac arrest using cardiopulmonary bypass and mitral valve replacement. *J Cardiothorac Anesth* 1987; 1:454-6

© 2003 American Society of Anesthesiologists, Inc. Lippincott Williams & Wilkins, Inc.

Cardiac Arrest after Injection of Ropivacaine for Posterior Lumbar Plexus Blockade

Olivier Huet, M.D.,* Luc J. Eyrolle, M.D.,† Jean X. Mazoit, Ph.D., M.D.,‡ Yves M. Ozier, M.D.§

LUMBAR plexus blockade is used for intraoperative and postoperative analgesia. Its performance is sometimes difficult, and the procedure carries the risk of vascular, dural, or epidural puncture.^{1,2} These concerns, particularly the risk of intravascular injection, has recently led

many to use ropivacaine. This choice is based both on its long duration of action and because it is believed to be less cardiotoxic than bupivacaine.³ To date, there have been very few reports of severe cardiac or central neurologic complications after the administration of ropivacaine.⁴⁻⁶

However, we now report a case of cardiac arrest that occurred after accidental intravenous injection of ropivacaine for posterior lumbar plexus blockade.

Case Report

A 66-yr-old man (American Society of Anesthesiologists physical status II, 100 kg, 171 cm) was scheduled for elective hip arthroplasty. Significant medical history included coronary disease with two previous myocardial infarctions (in 1988 and 1999) with coronary angioplasty in 1999. Medication included aspirin (stopped 8 days before and replaced by flurbiprofen), metoprolol, perindopril, and simvastatin. Hematologic studies prior to surgery were all normal. His electrocardiogram showed a normal sinus rhythm with a heart rate of 70 beats/min.

The patient received hydroxyzine 50 mg orally 1 h before surgery. After placement of standard monitors (electrocardiogram, pulse oximetry, and automatic cuffed arterial blood pressure), peripheral venous

This article is accompanied by an Editorial View. Please see: Polley LS, Santos AC: Cardiac arrest following regional anesthesia with ropivacaine: Here we go again! *ANESTHESIOLOGY* 2003; 99:1253-4.

* Resident in Anesthesia, † Staff Anesthesiologist, § Professor of Anesthesia, Head, Anesthesia Intensive Care Department, COCHIN University Hospital. ‡ Staff Anesthesiologist, Anesthesia Intensive Care Department, KREMLIN-BICETRE University Hospital, Anesthesia Laboratory, KREMLIN-BICETRE College of Medicine, Paris-Sud University, Paris, France.

Received from the Anesthesia Intensive Care Department, COCHIN University Hospital, Paris, France. Submitted for publication March 24, 2003. Accepted for publication July 30, 2003. Support was provided solely from institutional and/or departmental sources.

Address reprint requests to Dr. Eyrolle: Anesthesia Intensive Care Department, COCHIN University Hospital, 27 Rue du Faubourg St. Jacques, 75679 PARIS CEDEX 14, France. Address electronic mail to: luc.eyrolle@cch.ap-hop-paris.fr. Individual article reprints may be purchased through the Journal Web site, www.anesthesiology.org.

access was established and 5 μg of sufentanil was administered. Using the Winnie technique,² the patient was placed in the right lateral decubitus Labat position and cutaneous marks were made. After sterile preparation, the skin was infiltrated with 2% lidocaine (8 mg). A short (100-mm long, 21-gauge) bevel needle (Stimuplex A; B. Braun Melsungen AG, Melsungen, Germany) with an injection line and connection to a neurostimulator was inserted perpendicularly to the skin. A quadriiceps response was elicited at 0.68 mA (0.1-ms pulse width) with a peripheral nerve stimulator. The depth of the needle was 100 mm. There was no spontaneous blood return and no blood could be aspirated. After aspiration, 25 ml of ropivacaine 0.75% (187.5 mg) was injected over 2 min in 5-ml increments, with intermittent attempts at withdrawal. Verbal contact was maintained during the injection, and no early sign of systemic toxicity occurred. However, 2 min after completion of the injection, the patient suddenly became unresponsive and showed tonic-clonic generalized seizures. He received 10 l/min oxygen *via* facemask, and 30 mg diazepam was injected. Because of the seizures, it was impossible to note any initial change on the electrocardiogram. One minute after the beginning of the seizures, movement stopped and asystole was apparent on the monitor. Tracheal intubation was performed and cardiopulmonary resuscitation was started. A bolus of 1 mg epinephrine was injected intravenously and was repeated once after 3 min. Cardiac activity was restored within 5 min with subsequent hemodynamic stability. The electrocardiogram showed a bradycardia with heart rate at 42 beats/min and widening of the electrocardiographic wave complex. The electrocardiogram was restored progressively in 10 min to normality, and the patient was transferred to the recovery room. At 1 h after ropivacaine injection, an arterial blood sample revealed metabolic acidosis with pH at 7.10. Lactate concentration in plasma was 11.7 U/ml, but PaO_2 and Paco_2 were normal. Troponin I was less than 0.2 U, and both liver and muscle enzymes were normal. There was no evidence of a lumbar plexus block. The patient was extubated 2 h after injection of the local anesthetic and had no evident sequelae. The electrocardiogram performed at that time showed no changes compared with preoperatively.

Blood samples were also taken 55, 125, and 420 min after intravascular injection, and ropivacaine concentration was measured in plasma using gas chromatography. The assay has an intraday and interday coefficient of variation of 8% in the range of concentrations measured. The respective concentrations were 5.61 mg/L, 2.69 mg/L, and 1.16 mg/L.

To gain some insight into the possible ropivacaine concentration associated with the cardiac arrest, the few measured concentrations obtained from the blood sampling were used to build a compartmental model that enabled us to predict the peak concentrations that occurred shortly after the injection using the following assumptions:

1. A linear two-compartment model was considered adequate to model ropivacaine kinetics.
2. No gross change in clearance and volumes had occurred during the measurement period.

Our estimate of the concentration at the time of cardiac arrest was 17.44 $\mu\text{g}/\text{ml}$ (95% CI, 14.66–19.24 $\mu\text{g}/\text{ml}$).

Discussion

Lumbar plexus blockade is widely used for analgesia in elective hip arthroplasty. However, patient morphology can make this technique more difficult.¹ Our patient's excess weight (body mass index, 34.1 kg/m^2) made blockade difficult. Surface landmarks were difficult to determine, and the 100-mm-long needle might have been inadequate. Finally, the bone contact with costiform apophysis, which is part of the technique, was not

achieved. Nevertheless, nerve stimulation suggested adequate needle location, and lack of spontaneous blood reflux and the negative aspiration test led us to proceed with the injection. In retrospect, we should have used the same precautions as during epidural anesthesia (test dose, slow and divided dose injection).⁷

The severe adverse reaction observed, and the measured ropivacaine plasma concentrations, suggest that at least a large part of 187.5-mg ropivacaine dose was accidentally intravascularly injected. However, the very high “time-zero” concentration of ropivacaine (17.44 $\mu\text{g}/\text{ml}$) extrapolated from our pharmacologic model must be cautiously interpreted. The model is only an estimate and is based on three blood samples, and we do not suggest that all other pharmacologic parameters were completely defined during the few minutes after cardiac arrest and during cardiopulmonary resuscitation (*e.g.*, volume distribution, clearance). However, the first *measured* plasma concentration performed 5 min after completion of the injection (5.61 mg/l) is clearly over the range of the experimental human threshold for central nervous system and cardiac toxicity. When given as an intravenous infusion in volunteers, Scott *et al.*⁸ showed a threshold for the appearance of convulsions at a ropivacaine plasma concentration of 1–2 mg/l. In a similar study, Knudsen *et al.*⁹ noted a threshold at 2.2 mg/l (0.5–3.2 mg/l).

Ropivacaine is an amino amide local anesthetic that has shown less neurologic and cardiac toxicity compared with bupivacaine. Knudsen *et al.*⁹ compared the incidence of central nervous system symptoms and changes in echography and electrophysiology during intravenous infusion of ropivacaine or bupivacaine in healthy volunteers. They showed that the maximum tolerated dose was higher for ropivacaine than for bupivacaine. Similarly, Reiz *et al.*¹⁰ showed in pigs that the electrophysiologic toxicity ratio was lower for ropivacaine than for bupivacaine. Although the mechanism of cardiotoxicity is more complex than originally presumed, more recent studies agree with a significant advantage of ropivacaine.^{11–13}

However, we stress that most of the clinical studies comparing nervous and cardiac toxicity of ropivacaine and bupivacaine have not been performed with equipotent doses. Actually, the doses used in clinical practice to ensure effective regional anesthesia are higher for ropivacaine than for bupivacaine. Nevertheless, in the current case, although massive plasma concentration was accidentally injected, cardiopulmonary resuscitation was quite easy and was rapidly successful without after-effects, because efficient cardiac activity was obtained after 5 min of cardiac compressions and 2 mg of epinephrine.

Cardiac resuscitation is always difficult to evaluate as a clinical model, but experimental literature reveals a lower incidence of unsuccessful cardiopulmonary resus-

citation after ropivacaine than bupivacaine. In a rat model, Ohmura *et al.*¹⁴ emphasized that ropivacaine-induced cardiac arrest seems to be more susceptible to treatment than that induced by bupivacaine or levobupivacaine. Groban *et al.*¹⁵ reported less epinephrine-induced ventricular fibrillation in ropivacaine-intoxicated dogs than in dogs given bupivacaine. Moreover, the plasma concentrations at collapse were larger for ropivacaine 19.8 $\mu\text{g/ml}$ (10–39 $\mu\text{g/ml}$) compared with bupivacaine 5.7 $\mu\text{g/ml}$ (5–18 $\mu\text{g/ml}$).

Only a few clinical cases of severe dysrhythmias occurring after ropivacaine injection have been previously reported.⁶ Because of its apparently low incidence of cardiac toxicity, ropivacaine is considered to be relatively safe and is widely used. However, ropivacaine is not totally nontoxic, and care should be taken when injecting any local anesthetic agent, whatever the site of administration (epidural or peripheral nerve).⁷

References

1. Farny J, Drolet P, Girard M: Anatomy of the posterior approach to the lumbar plexus block. *Can J Anaesth* 1994; 480–5
2. Winnie AP, Ramamurthy S, Durani Z, Radonjic R: Plexus block for the lower extremity surgery: New answer to old problems. *Anesthesiol Rev* 1974; 1:11–6

3. Whiteside JB, Wildsmith JA: Developments in local anaesthetic drugs. *Br J Anaesth* 2001; 87:27–35
4. Muller M, Litz RJ, Huler M, Albrecht DM: Grand mal convulsion and plasma concentrations after intravascular injection of ropivacaine for axillary brachial plexus blockade. *Br J Anaesth* 2001; 87:784–7
5. Petitjeans F, Mion G, Puidupin M, Tourtier JP, Hutson C, Saissy JM: Tachycardia and convulsions induced by accidental intravascular ropivacaine injection during sciatic block. *Acta Anaesthesiol Scand* 2002; 46:616–7
6. Ruetsch YA, Fattinger KE, Borgeat A: Ropivacaine-induced convulsions and severe cardiac dysrhythmia after sciatic block. *ANESTHESIOLOGY* 1999; 90:1784–6
7. Auroy Y, Benhamou D, Barges L, Ecoffey C, Falissard B, Mercier FJ, Bouaziz H, Samii K, Mercier F: Major complications of regional anesthesia in France: The SOS Regional Anesthesia Hotline Service. *ANESTHESIOLOGY* 2002; 97:1274–80
8. Scott DB, Lee A, Fagan D, Bowler GM, Bloomfield P, Lundh R: Acute toxicity of ropivacaine compared with that of bupivacaine. *Anesth Analg* 1989; 69:563–9
9. Knudsen K, Beckman Suurkula M, Blomberg S, Sjovall J, Edvardsson N: Central nervous and cardiovascular effects of i.v. infusions of ropivacaine, bupivacaine and placebo in volunteers. *Br J Anaesth* 1997; 78:507–14
10. Reiz S, Haggmark S, Johansson G, Nath S: Cardiotoxicity of ropivacaine: A new amide local anaesthetic agent. *Acta Anaesthesiol Scand* 1989; 33:93–8
11. Ladd LA, Chang DH, Wilson KA, Copeland SE, Plummer JL, Mather LE: Effects of CNS site-directed carotid arterial infusions of bupivacaine, levobupivacaine, and ropivacaine in sheep. *ANESTHESIOLOGY* 2002; 97:418–28
12. Graf BM, Abraham I, Eberbach N, Kunst G, Stowe DF, Martin E: Differences in cardiotoxicity of bupivacaine and ropivacaine are the result of physicochemical and stereoselective properties. *ANESTHESIOLOGY* 2002; 96:1427–34
13. Mazoit JX, Decaux A, Bouaziz H, Edouard A: Comparative ventricular electrophysiologic effect of racemic bupivacaine, levobupivacaine, and ropivacaine on the isolated rabbit heart. *ANESTHESIOLOGY* 2000; 93:784–92
14. Ohmura S, Kawada M, Ohta T, Yamamoto K, Kobayashi T: Systemic toxicity and resuscitation in bupivacaine-, levobupivacaine-, or ropivacaine-infused rats. *Anesth Analg* 2001; 93:743–8
15. Groban L, Deal DD, Vernon JC, James RL, Butterworth J: Cardiac resuscitation after incremental overdosage with lidocaine, bupivacaine, levobupivacaine, and ropivacaine in anesthetized dogs. *Anesth Analg* 2001; 92:37–43

Anesthesiology 2003; 99:1453–5

© 2003 American Society of Anesthesiologists, Inc. Lippincott Williams & Wilkins, Inc.

Bispectral Index Scale Is Higher for Halothane than Sevoflurane during Intraoperative Anesthesia

Johnathan J. Edwards M.D.,* Roy G. Soto M.D.,† David M. Thrush M.D.,‡ Robert F. Bedford M.D.‡

THE Bispectral Index (BIS) is a derived parameter from the scalp electroencephalogram used for monitoring the level of consciousness during administration of anesthetics and hypnotics.¹ BIS has been shown to correlate well with anesthetic depth for a number of agents, but it has not been studied with halothane.^{1–4} Typically, BIS values of 65–80 are indicative of loss of conscious information processing and recall, and when appropriately used, BIS can be useful for reducing the risk of intraoperative awareness.⁵

During halothane anesthesia, however, we observed BIS values to be higher (55–70 U) than those observed with equi-potent concentrations of isoflurane or sevoflu-

rane (35–50 U) and desflurane (~ 45–50 U). These observations suggest that BIS values obtained during halothane might lead an unwary clinician to underestimate the depth of anesthesia. The present study was undertaken to investigate whether BIS remains elevated throughout the range of clinical halothane anesthetic concentrations.

Case Report

With the approval of the Institutional Review Board at the University of South Florida, Tampa, Florida, we studied 19 consenting patients of American Society of Anesthesiologists physical status I or II who were scheduled for breast surgery. The choice of anesthetic was randomized, and exclusion criteria included subjects receiving β -adrenergic antagonists, those who received preoperative sedatives or any medication that might affect the electroencephalogram, and pregnancy. No patient received premedication or other sedatives/hypnotics. In the operating room, standard American Society of Anesthesiologists monitors and an adult sensor strip (Aspect A-2000, Bispectral Index® XP version 4.0; Aspect Medical Systems, Newton, MA) were applied. All measured impedances were under 5.0 k Ω . Baseline BIS values were recorded for 3 min before induction of anesthesia. A mask induction with halothane or sevoflurane with 100% oxygen was performed, and patients breathed spontaneously *via* a laryngeal mask airway. End-tidal concentrations of anesthetic, oxygen, and carbon dioxide were mon-

* Resident, † Assistant Professor, ‡ Professor, Department of Anesthesiology. ‡ Department of Interdisciplinary Oncology.

Received from the Departments of Anesthesiology and Interdisciplinary Oncology, University of South Florida College of Medicine, Tampa, Florida. Submitted for publication March 11, 2003. Accepted for publication May 28, 2003. The monitor and sensors were provided by Aspect Medical Systems, Newton, Massachusetts. Otherwise, support was provided from institutional and/or departmental sources. Presented in part at the Annual Meeting of the American Society of Anesthesiologists, Orlando, Florida, October 18, 2002.

Address reprint requests to Dr. Soto: Department of Anesthesiology, MDC 59, 12901 Bruce B Downs Boulevard, Tampa, Florida 33612. Address electronic mail to: rsoto@hsc.usf.edu. Individual article reprints may be purchased through the Journal Web site, www.anesthesiology.org.

Table 1. Observed BIS Values at Data Collection Points

Time Point	Halothane	Sevoflurane
Baseline	96 ± 1.2	97 ± 1.7
MAC _{1.3}	57 ± 4.7	32 ± 5.9*
Eye opening	87 ± 6.2	84 ± 6.3

Values are mean ± SD.

* $P < 0.001$ comparing halothane and sevoflurane BIS at MAC_{1.3}. Baseline BIS is prior to induction of anesthesia; MAC_{1.3} is during a 10-min period of minimal surgical stimulation.

BIS = bispectral index; MAC = minimum alveolar concentration; SD = standard deviation.

itored continuously (Datex Capnomatic, Helsinki, Finland). Volatile anesthetic concentration was titrated to maintain hemodynamic stability during surgical stimulation with a goal of reaching an end-tidal anesthetic concentration equal to 1.3 minimum alveolar concentration (MAC_{1.3}) adjusted for patient age.⁶ BIS was recorded every 2.5 min throughout the operation. Values recorded at MAC_{1.3} were obtained during a 10-min period of minimal surgical stimulation (e.g., while awaiting for frozen section results). To ensure end-tidal equilibration of the anesthetic to the brain, BIS values were recorded after maintaining end-tidal concentrations constant for at least 15 min.

Categorical data are presented as raw values, and intergroup statistical contrasts were made using the Pearson chi-square test. Demographic data are summarized as mean ± 1 SD, and intergroup comparisons were made with the Student *t* test for independent observations. Outcome data are summarized as mean ± 1 SD, and intergroup statistical comparisons were made with a repeated measures analysis of variance. When the *F* ratio was significant at the 0.05 level, the Tukey honestly significant difference *post hoc* test was used to distinguish intergroup differences. Statistical analyses were performed using Statistica software (version 6.0, StatSoft, Tulsa, OK).

All patients completed the protocol, although one did not complete the awakening portion of the study because of propofol administration at the end of surgery. The two study groups were comparable with respect to demographic data and hemodynamic parameters. The overall mean ages (± SD) for halothane and sevoflurane were 58 ± 15 and 54 ± 14, respectively; similarly, the overall weights were 73 ± 18 and 75 ± 27, respectively. Mean heart rates at MAC_{1.3} were 72 ± 7 and 71 ± 11 for halothane and sevoflurane, respectively; similarly, blood pressure readings at MAC_{1.3} were 76 ± 11 and 74 ± 11, respectively. The mean BIS value at MAC_{1.3} for halothane was significantly higher than that of sevoflurane at equi-potent end-tidal anesthetic concentrations (table 1). Given the differences in BIS at MAC_{1.3}, an unexpected finding was that during emergence, the mean BIS-value at eye opening was the same for both halothane and sevoflurane.

Figure 1 shows the observed mean BIS values at various end-tidal halothane and sevoflurane concentrations during surgical anesthesia. There was a nearly dose-independent relationship for both agents. Most BIS values for sevoflurane were clustered between 25 and 60; no BIS value was below 38 for halothane and some values were above 70 at MAC > 1.0.

At MAC_{1.3}, anesthesia was maintained with a mean end-tidal concentration of 0.9% ± 0.1 (± SD) halothane and 2.5% ± 0.2 sevoflurane. No recall of events occurred in any of the patients studied in either group, as assessed by questioning each subject at the time of discharge from the hospital.

Discussion

Halothane is a commonly used anesthetic agent in American pediatric anesthesia practice, and it is still used in over 30 countries worldwide. Because BIS values

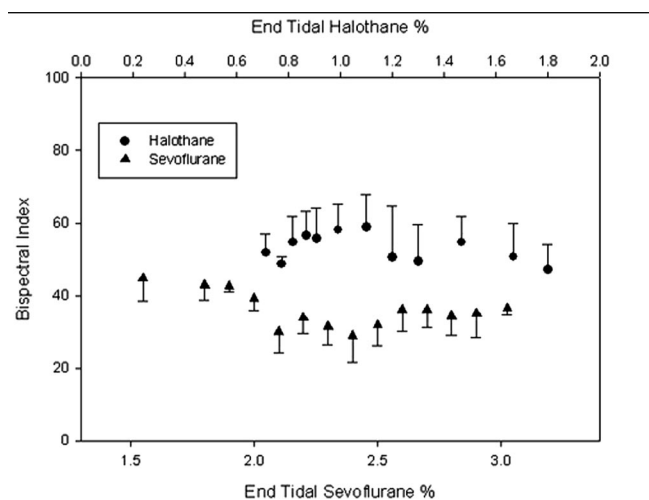


Fig. 1. Mean Bispectral Index (BIS) values recorded at various end-tidal sevoflurane and halothane concentrations during steady-state conditions with minimal surgical stimulation. The triangles represent halothane and the circles represent sevoflurane. Note the separation between the halothane and sevoflurane values as well as the dose-independent relationship between BIS values and end-tidal anesthetic concentrations.

during surgical halothane anesthesia are significantly higher than those seen with other volatile anesthetics, intraoperative BIS values do not accurately reflect the depth of halothane anesthesia and may lead to inadvertent overdosage if vital signs are not closely monitored.

We believe our findings are the result of the differences in electroencephalogram signature of halothane compared to that of sevoflurane.⁷ Constant *et al.* found that clinical concentrations of halothane produce relatively fast electroencephalogram rhythms, whereas sevoflurane produces progressively slower electroencephalogram activity with relatively few fast rhythms.⁷

Because the algorithm for deriving BIS remains proprietary, the impact of halothane anesthesia on BIS values could not have been predicted without clinically derived data. Indeed, the BIS value at MAC_{1.3} for the halothane group is comparable to values observed during light anesthesia with sevoflurane.⁸ We chose 1.3 MAC as a clinical endpoint to compare halothane and sevoflurane to achieve adequate depth of anesthesia during airway manipulations and surgical stimulation. By contrast, the fact that BIS values at eye opening during emergence were identical for both halothane and sevoflurane supports the use of BIS for monitoring hypnosis during halothane.

Because halothane is widely used in pediatric anesthesia practice, these data may also have significant implications for patient safety in children. BIS monitoring seems to be a promising method for gauging depth of anesthesia in children,⁹ and the BIS-sevoflurane dose response appears to be similar to that seen in adults.¹⁰ Our data, however, suggest that BIS values during halothane anesthesia are likely to be higher than those seen

with sevoflurane and may lead an unsuspecting clinician to administer excessive halothane in an attempt to achieve an "adequate" BIS value. Because halothane overdosage is an ongoing source of concern in pediatric anesthesia, understanding how halothane affects the BIS in this population seems warranted.

In summary, we have found that BIS values during surgical levels of halothane anesthesia are significantly higher than those found at equi-potent concentrations of sevoflurane. Caution is warranted when BIS monitoring is used during halothane anesthesia, because unexpectedly high BIS values might give the impression of inadequate anesthetic depth and result in inadvertent overdosage.

References

1. Katoh T, Suzuki A, Ikeda K: Electroencephalographic derivatives as a tool for predicting the depth of sedation and anesthesia induced by sevoflurane. *ANESTHESIOLOGY* 1998; 88:642-50
2. Blake DW, Hogg MN, Hackman CH, Pang J, Bjorksten AR: Induction of

anesthesia with sevoflurane, preprogrammed propofol infusion or combined sevoflurane/propofol for laryngeal mask insertion: Cardiovascular, movement and EEG bispectral index responses. *Anaesth Intensive Care* 1998; 26:360-5

3. Gan TJ, Glass PS, Windsor A, Payne F, Rosow C, Sebel P, Manberg P: Bispectral index monitoring allows faster emergence and improved recovery from propofol, alfentanil, and nitrous oxide anesthesia. *ANESTHESIOLOGY* 1997; 87:808-15
4. Glass PS, Bloom MJ, Kearse L, Rosow C, Sebel PS: Bispectral analysis measures sedation and memory effects of propofol, midazolam, isoflurane, and alfentanil in healthy volunteers. *ANESTHESIOLOGY* 1997; 86:836-47
5. Johansen JW, Sebel PS: Development and clinical application of electroencephalographic bispectrum monitoring. *ANESTHESIOLOGY* 2000; 93:1336-44
6. Eger EI: Age, minimum alveolar anesthetic concentration, and minimum alveolar anesthetic concentration-awake. *Anesth Analg* 2001; 93:947-53
7. Constant I, Dubois MC, Piat V, Moutard ML, McCue M, Murat I: Changes in electroencephalogram and autonomic cardiovascular activity during induction of anesthesia with sevoflurane compared with halothane in children. *ANESTHESIOLOGY* 1999; 91:1604-15
8. Song D, Girish JP, White PF: Titration of volatile anesthetics using bispectral index facilitates recovery after ambulatory anesthesia. *ANESTHESIOLOGY* 1997; 87:842-8
9. Bannister CF, Brosius KK, Sigl JC, Meyer BJ, Sebel PS: The effect of bispectral index monitoring on anesthetic use and recovery in children anesthetized with sevoflurane in nitrous oxide. *Anesth Analg* 2001; 92:877-81
10. Denman WT, Swanson EL, Rosow D, Ezbicki K, Connors PD, Rosow CE: Pediatric evaluation of the bispectral index (BIS) monitor and correlation of BIS with end-tidal sevoflurane in infants and children. *Anesth Analg* 2000; 90:872-7

Anesthesiology 2003; 99:1455-6

© 2003 American Society of Anesthesiologists, Inc. Lippincott Williams & Wilkins, Inc.

Severe Airway Obstruction during Arthroscopic Shoulder Surgery

Stephan Blumenthal, M.D.,* Marco Nadig, M.D.,* Christian Gerber, M.D.,† Alain Borgeat, M.D.‡

THE use of arthroscopic techniques has provided a major advance in the diagnosis and treatment of shoulder injuries.¹ However, shoulder arthroscopy is not a technique void of complications.² We describe a patient who presented with severe airway obstruction caused by tracheal compression due to extraarticular arthroscopy fluid accumulation during arthroscopic shoulder surgery. An interscalene block provided anesthesia.

Case Report

A 55-yr old man with a history of a painful rotator cuff rupture and American Society of Anesthesiology physical status II was scheduled for left shoulder arthroscopy. Except for obesity (body mass index, 31), preoperative physical examination and laboratory findings were normal. After premedication with 7.5 mg midazolam, an interscalene catheter (Polymedic® 22 gauge; Te Me Na, Bondi, France) was placed according to the modified lateral approach.³ The procedure was uneventful, and 50 ml ropivacaine, 0.5% (250 mg), was administered

through the catheter, with a surgical block achieved within 20 min. After 25 min, the patient was placed in the right lateral decubitus with the left shoulder up. Monitoring included pulse oximetry, electrocardiography, and noninvasive blood pressure determination. Supplemental analgesia (for pain in the right hip) was achieved with a remifentanyl-controlled infusion (target concentration, 2.0 ng/ml). The patient remained awake with a respiratory rate of 14 breaths/min. After insertion of the arthroscope, the subacromial space was inflated by infusion with lactated Ringer's solution, and his blood pressure was maintained between 80 and 100 mmHg.

The surgical procedure was uneventful during the first 110 min. Suddenly, the patient started to complain about breathing difficulties and a feeling of pressure on the throat. Within minutes, the patient became restless and developed severe dyspnea; the drapes were quickly removed, and the patient was placed in a supine position. Massive swelling of the left side of the chest and of the anterior portion of the neck extending to the face was noted. Oxygen saturation decreased quickly below 50%, and the patient became bradycardiac (heart rate, 38 beats/min). Emergency intubation was unsuccessful because the laryngeal structures could not be identified. Prednisone (200 mg) was given intravenously, and an incision was made by the surgeon at the level of the cricothyroid membrane to perform a tracheotomy. Immediately after the skin incision, manual ventilation became possible, and oxygen saturation steadily increased to 80% by relief of pressure on the trachea through mere distention of the tissue. The heart rate returned to normal. The tracheotomy procedure was stopped, and a second attempt at orotracheal intubation was now successful despite massive swelling of the tissue surrounding the airways. The patient's blood pressure remained stable. The incisions at the neck and shoulder were closed, and the patient was transferred to the intensive care unit, where he remained intubated for another 24 h. The patient was extubated the next day with no problems, and no sequelae were observed.

* Consultant, Department of Anesthesiology, † Professor and Chairman, Department of Orthopedic Surgery, ‡ Professor and Chief of Staff, Department of Anesthesiology.

Received from the Orthopedic University Clinic Balgrist, Zurich, Switzerland. Submitted for publication May 19, 2003. Accepted for publication June 30, 2003. Support was provided solely from institutional and/or departmental sources.

Address reprint requests to Dr. Borgeat: Department of Anesthesia, Orthopedic University Clinic Balgrist, Forchstrasse 340, CH-8008 Zurich, Switzerland. Address electronic mail to: aborgeat@balgrist.unizh.ch. Individual article reprints may be purchased through the Journal Web site, www.anesthesiology.org.

Discussion

We report another case of a severe airway problem during arthroscopic shoulder surgery performed during interscalene brachial plexus blockade and sedation. To our knowledge, only two cases have been reported before with extraarticular spread of arthroscopic irrigation fluid compromising the airway.^{4,5} The extraarticular leakage of fluid is a well-recognized complication of shoulder arthroscopy⁶; extravasation into the deltoid muscle and the chest frequently occurs, but usually it is without clinically significant symptoms and most often is reabsorbed within 12 h.^{7,8} Risk factors for an extended loss of irrigation fluid into soft tissue are increased pump pressure,⁴ obesity, duration of arthroscopic procedure, and arthroscopy within the subacromial space, because this space is not enclosed within a capsule.²

The worldwide use of regional anesthetic techniques is increasing; in parallel, an increasing number of patients are sedated during placement of the block and during surgery. Brown *et al.*⁹ demonstrated that the interscalene block compared with general anesthesia for shoulder arthroscopy was associated postoperatively with fewer side effects, shorter hospital stay, and higher patient satisfaction. In this context, sedation is likely to be increasingly used. This case emphasizes the need for

sedation that must be predictable, rapidly reversible, and easily monitored. As shown here, the patient's ability to communicate with the anesthetist and to complain about discomfort and airway problems during shoulder arthroscopy are crucial to a well-managed sedation. Direct communication with the patient permits early recognition of complications, such as any difficulty in swallowing or throat sensation, which are ominous signs of airway swelling.

References

1. Rodeo SA, Forster RA, Weiland AJ: Current concepts review: Neurological complications due to arthroscopy. *J Bone Joint Surg* 1993; 75:917-26
2. Matthews LS, Fadale PD: Subacromial anatomy for the arthroscopist. *Arthroscopy* 1989; 5:36-40
3. Borgeat A, Ekatothramis G: Anaesthesia for shoulder surgery, *Clinical Anesthesiology Best Practice & Research*. Edited by Van Aken H. New York, Baillière Tindall and Elsevier Science Company, 2002, pp 211-25
4. Borgeat A, Bird P, Ekatothramis G, Dumont C: Tracheal compression caused by periarticular fluid accumulation: A rare complication of shoulder surgery. *J Shoulder Elbow Surg* 2000; 9:443-5
5. Hynson JM, Tung A, Guevara JE, Katz JA, Glick JM, Shapiro WA: Complete airway obstruction during arthroscopic shoulder surgery. *Anesth Analg* 1993; 76:875-8
6. Berjano P, Gonzalez BG, Olmedo JF, Perez-Espana LA, Munilla MG: Complications in arthroscopic shoulder surgery. *Arthroscopy* 1998; 14:785-8
7. Ogilvie-Harris DJ, Boynton E: Arthroscopic acromioplasty: Extravasation of fluid into the deltoid muscle. *Arthroscopy* 1990; 6:52-4
8. Lilleby H: Shoulder arthroscopy. *Acta Orthop Scand* 1984; 55:561-6
9. Brown AR, Weiss R, Greenberg C, Flatow EL, Bigliani LU: Interscalene block for shoulder arthroscopy: Comparison with general anesthesia. *Arthroscopy* 1993; 9:295-300

Anesthesiology 2003; 99:1456-8

© 2003 American Society of Anesthesiologists, Inc. Lippincott Williams & Wilkins, Inc.

Life-threatening Airway Edema Resulting from Prolonged Shoulder Arthroscopy

Steven L. Orebaugh, M.D.*

ARTHROSCOPIC shoulder surgery is an accepted technique for managing rotator cuff tears, recurrent joint instability, and subacromial pathology.¹ Shoulder arthroscopy has several important advantages over open techniques, including less postoperative pain and more rapid rehabilitation.² Regional anesthesia for arthroscopic shoulder surgery is increasingly used. Advantages include less overall anesthetic drugs received by the patient, reduced postoperative analgesic requirements, lower rates of postoperative nausea, and reduced admission rates.³

Rarely, arthroscopic shoulder surgery under regional anesthesia produces complications that compromise the

patient's airway.⁴⁻⁷ This report describes a case of life-threatening airway edema due to extracapsular irrigation fluid collection during a prolonged shoulder arthroscopic repair.

Case Report

A 49-yr-old, healthy man presented for right shoulder arthroscopic surgery, subacromial decompression, and rotator cuff repair. He was receiving no medications and had no drug allergies. On physical examination, the patient was 70 inches tall, weighed 82 kg, and had clear lungs and regular heart sounds. His oral examination revealed a Mallampati class 2 airway, with a normal cervical range of motion.

In the preoperative holding area, the patient received 2 mg intravenous midazolam and 100 µg of fentanyl for sedation. The right side of his neck was prepared in sterile fashion. With the aid of a nerve stimulator (Stimuplex, B. Braun, Bethlehem, PA), a 25-mm, 24-gauge, insulated needle was used to elicit stimulation of the deltoid muscle, with a current of 0.4 mA. Then, 40 ml of levobupivacaine, 0.56% with epinephrine 1:300,000, was injected, and brachial plexus block was evident within 10 min.

The patient was placed in the "beach-chair" position in the operating room, monitors were attached, and sedation was initiated with a

* Assistant Professor of Anesthesiology.

Received from the University of Pittsburgh Medical Center-Southside, Pittsburgh, Pennsylvania. Submitted for publication April 3, 2003. Accepted for publication July 23, 2003. Support was provided solely from institutional and/or departmental sources.

Address reprints requests to Dr. Orebaugh: University of Pittsburgh Medical Center-Southside, 2000 Mary Street, Pittsburgh, Pennsylvania 15203. Address electronic mail to: orebaughsl@anes.upmc.edu. Individual article reprints may be purchased through the Journal Web site, www.anesthesiology.org.

propofol infusion of $100 \mu\text{g} \cdot \text{kg}^{-1} \cdot \text{min}^{-1}$. The patient was unconscious but was able to be aroused and continued to breathe supplemental oxygen spontaneously; end-tidal carbon dioxide was monitored *via* a catheter placed inside the oxygen mask.

Arthroscopy proceeded uneventfully for several hours. Joint irrigation was accomplished with lactated Ringer's solution with diluted epinephrine, using an infusion pump with pressures varying between 50 cm H₂O and 150 cm H₂O. The patient's arterial oxygen saturation (Sao₂) remained in the 97–98% range. However, approximately 3 h after the procedure was begun, the Sao₂ began to decrease, and audible stridor occurred. End-tidal carbon dioxide tension levels decreased from 15–20 mmHg to unobtainable levels. The surgeon was notified that severe neck and chest edema had caused respiratory arrest and that intubation would be necessary. Drapes were removed, revealing extensive swelling across the entire chest and neck as well as facial edema. The right side of the chest was woody in texture because of the extreme edema, and the overlying skin appeared mottled. Neck mobility was compromised, and laryngeal landmarks were not recognizable visibly or by palpation.

The Sao₂ rapidly decreased to 67%, cyanosis supervened, and there was no evidence of effective spontaneous ventilation. Positive pressure ventilation by facemask was impossible. The patient resisted attempts to open the mouth, and general anesthesia was induced with a bolus of 120 mg of propofol and 120 mg of succinylcholine. Direct laryngoscopy revealed marked airway edema, with bulging pharyngeal tissues that made recognition of the glottis impossible.

On failure of direct laryngoscopy, a Laryngeal Mask Airway™ (LMA Unique™, LMA of North America, Los Angeles, CA) was inserted into the pharynx and ventilation was initiated. The patient's chest was noted to rise with manual ventilation, and the Sao₂ rapidly climbed to 95%, with detectable levels of end-tidal carbon dioxide. However, the Sao₂ began to deteriorate once again, necessitating a more secure airway. A fiberoptic scope was passed into the LMA Unique™, and the aperture of the airway was recognized but was much reduced in size by the surrounding edema. The tip of the scope was passed through the laryngeal inlet, and a 6.0-mm endotracheal tube (ETT) was passed successfully.

Preparations were made to change the tube to one with greater length than the 6.0-mm ETT, which is restricted to a very short segment in the trachea by the LMA Unique™. A tube-exchange device (Cook Critical Care, Bloomington, IN) was inserted through the existing ETT. The LMA Unique™ and 6.0-mm ETT were removed, and a 7.0-mm tube was passed over the catheter against a degree of resistance. The exchange device was removed with difficulty, but ventilation through the new ETT was not effective. There was an audible air leak in the pharynx during ventilation, and no chest rise or end-tidal carbon dioxide was evident. Direct laryngoscopy was again attempted, and the ETT was curled in the posterior pharynx. It was removed, and the glottic opening was now recognizable from the fiberoptic intubation. A gum elastic bougie was placed through the small opening, and a 7.0-mm ETT was passed over this stylet.

The patient was transferred to the recovery room, and then to the intensive care unit, while sedation and mechanical ventilation were continued. Chest radiography revealed near-complete opacification of the right hemithorax. Computed tomography of the chest showed a large right pleural effusion with atelectasis of the lower and middle lobes, and marked edema of the right side of the neck with laryngeal displacement to the left. Hemodynamic stability was maintained, and diuresis was begun.

After 24 h, the patient's facial appearance had returned to nearly normal, although significant chest and neck swelling remained. An inspired fraction of oxygen of 80% was still necessary for adequate oxygenation. On the second postoperative day, the clinical situation had greatly improved and the patient was extubated that evening. Despite the repeated glottic intubations and manipulation, there were no complications. He was discharged home on postoperative day 5.

Discussion

This report describes an episode of severe airway edema occurring as a complication of shoulder arthroscopic surgery. Complications related to shoulder arthroscopy are not infrequent. Small⁸ describes an incidence of complications of 5.3%. Bigliani *et al.*⁹ characterized the frequency of complications as 1–3.2%, depending on the nature of the procedure. Complications described include extravasation of fluid, traction neuropraxias, intraoperative hemorrhage, infections, cartilage injury, and reflex sympathetic dystrophy.

However, respiratory compromise related to shoulder arthroscopy procedures is rare. Causes include air embolism,¹ pneumothorax,⁶ mediastinal air,⁷ tracheal compression,⁵ and complete airway obstruction from edema.⁴ Borgeat *et al.*⁵ reported a case of airway compromise in a patient who underwent interscalene block for an arthroscopic procedure on the left shoulder. Infusion of normal saline into the shoulder was initiated at a pressure of 80 mmHg, and then increased after 2 hr, at which time the surgeon noted a leak of fluid from the joint. The patient then complained of neck pressure, shortness of breath, and chest tightness. Wheezing and marked left-sided chest and neck edema were evident on examination. The patient, who was in the lateral decubitus position, was placed supine with her head elevated. She did not develop hypoxemia, and she recovered with no further intervention.

Complete airway obstruction during arthroscopic shoulder surgery occurred in a case described by Hynson *et al.*⁴ After interscalene block, the patient was placed in the left lateral decubitus position and was lightly sedated. An arthroscopy pump was used to irrigate the joint with lactated Ringer's solution. After 1 h and 45 min, the patient became dyspneic and was unable to phonate. Severe edema of the operative side of the chest and neck were observed. Attempted ventilation by facemask failed, and the patient was intubated. Because of massive pharyngeal edema, a 7.0-mm ETT could not be passed, and a 6.0-mm tube was inserted instead. By the next day, the edema had significantly improved, and the patient's trachea was extubated.

In both of the cases described, a degree of alertness allowed the patient to complain of neck pressure or dyspnea.^{4,5} Deeper degrees of sedation, such as in the present case, do not allow for such early verbal warnings that might avert the necessity of emergent ventilation or intubation.

Berjano *et al.*¹⁰ reported a series of complications in arthroscopic shoulder surgery in which he noted four cases of severe edema involving the cervical region, out of a total of 141 cases performed. Surgery in these cases was performed in the lateral decubitus position. Of these four, one required reintubation after surgery and admission to the intensive care unit.

Factors that may underlie the accumulation of extra-articular edema include the use of an irrigation pump for infusion of fluid into the joint, especially at high pressures,^{5,9,11} and the duration of surgery.⁴ The overall volume of irrigation fluid used is likely to contribute as well. Fluid escape is most common during arthroscopic acromioplasty, because the subacromial space is not encapsulated.¹² In addition, fluid may escape through the insertion portals of the surgical instruments.¹¹ Hynson *et al.*⁴ noted that patients' neck circumferences increased up to 5 cm after even routine shoulder arthroscopies.

In sum, this is the first reported case of airway obstruction from fluid extravasation during shoulder arthroscopy in the beach-chair position. Airway management was complicated by marked edema, and *LMA Unique*TM insertion followed by fiberoptic intubation was life saving. Measures that should be observed to prevent this potentially fatal complication include maintaining a light degree of sedation, restricting the duration of the procedure, and minimizing the arthroscopy pump pressures and amount of fluid used for joint irrigation. In addition, hourly evaluation of the degree of neck swelling can forewarn the occurrence of severe edema and allow

cessation of the procedure and tracheal intubation if necessary.

References

1. Villar RN: Minimally invasive surgery: Arthroscopy. *BMJ* 1994; 308:51-3
2. Gartsman G: Arthroscopic rotator cuff repair. *Clin Orthop* 2001; 390:95-106
3. Brown AR, Weiss R, Greensburg C, Flatow EL, Bigliani LU: Interscalene block for shoulder arthroscopy: Comparison with general anesthesia. *Arthroscopy* 1993; 9:295-300
4. Hynson JM, Tung A, Guevara JE, Katz JA, Glick JM, Shapiro WA: Complete airway obstruction during arthroscopic shoulder surgery. *Anesth Analg* 1993; 76:875-8
5. Borgeat A, Bird P, Ekatothramis G, Dumont C: Tracheal compression caused by periarticular fluid accumulation: A rare complication of shoulder surgery. *J Shoulder Elbow Surg* 2000; 9:443-5
6. Lee H-C, Dewan N, Crosby L: Subcutaneous emphysema, pneumomediastinum and potentially life-threatening tension pneumothorax. *Chest* 1992; 101:1265-7
7. Lau K-Y: Pneumomediastinum caused by subcutaneous emphysema in the shoulder. *Chest* 1993; 103:1606-7
8. Small NC: Complications in arthroscopy: The knee and other joints. *Arthroscopy* 1986; 2:253-8
9. Bigliani LU, Flatow EL, Deliz ED: Complications of shoulder arthroscopy. *Orthop Rev* 1991; 20:743-50
10. Berjano P, Gonzalez BG, Olmedo JF, Perez-Espana LA, Munilla MG: Complications in arthroscopic shoulder surgery. *Arthroscopy* 1998; 14:785-8
11. Noyes FR, Spievack ES: Extraarticular fluid dissection in tissues during arthroscopy. *Am J Sports Med* 1982; 10:346-51
12. Matthews LS, Fadale P: Subacromial anatomy for the arthroscopist. *Arthroscopy* 1989; 5:36-40