

Effects of the α_2 -Adrenoceptor Agonist Dexmedetomidine on Bronchoconstriction in Dogs

Harald Groeben, M.D.,* Wayne Mitzner, Ph.D.,† Robert H. Brown, M.D., M.P.H.‡

Background: Tracheal intubation can elicit reflex bronchoconstriction in patients with asthma or chronic obstructive pulmonary disease, complicating mechanical ventilation and weaning from mechanical support. *In vitro* studies of human and animal bronchial tissue indicate that α_2 -adrenoceptor stimulation can lead to smooth muscle relaxation and prevention of bronchoconstriction. Dexmedetomidine is a selective α_2 -adrenoceptor agonist approved for sedation in the intensive care unit. Whether dexmedetomidine can affect reflex bronchoconstriction is unknown.

Methods: After the approval of the institutional animal care and use committee, five mongrel dogs were anesthetized with thiopental, endotracheally intubated, and ventilated, and their airways were challenged with histamine. High-resolution computed tomography was used to measure airway luminal areas at baseline and after nebulized histamine. After recovery to baseline, on separate days, dexmedetomidine (0.5 $\mu\text{g}/\text{kg}$) was administered either intravenously or as an aerosol, and the histamine challenge was repeated.

Results: At baseline, histamine constricted the airways to $66 \pm 27\%$ (mean \pm SD) ($P < 0.0001$) and $59 \pm 30\%$ ($P < 0.0001$) of maximum on the days dexmedetomidine was administered by intravenous and inhalational means, respectively. After recovery, intravenous administration of dexmedetomidine blocked the histamine-induced bronchoconstriction ($87 \pm 30.4\%$ of maximum, compared with histamine alone ($P < 0.0001$), whereas dexmedetomidine administered by inhalation showed no protective effect ($45 \pm 30\%$ of maximum; $P < 0.0001$ compared with histamine alone).

Conclusion: α_2 -Adrenoceptor stimulation with intravenous dexmedetomidine completely blocked histamine-induced bronchoconstriction in dogs. Therefore, dexmedetomidine might be beneficial to decrease airway reactivity in patients with chronic obstructive pulmonary disease or asthma, particularly during weaning from mechanical ventilation, when neurally mediated airway reflexes may be elicited.

APPROXIMATELY 5,000 patients die every year in the United States because of acute severe asthma attacks.¹ Moreover, acute exacerbations of chronic obstructive

pulmonary disease contribute to approximately another 110,000 deaths every year.² In acute asthma attacks or exacerbations of chronic obstructive pulmonary disease, tracheal intubation and mechanical ventilation can be required as a life-saving procedure. However, strong airway irritation, such as the introduction of an endotracheal tube into the larynx and trachea, can in itself elicit severe reflex bronchoconstriction and lead to prolonged weaning from mechanical ventilation.^{3–6}

In vitro studies of human and animal bronchial tissue indicate that α_2 -adrenoceptor stimulation can lead to attenuation and prevention of bronchoconstriction.^{7–11} This effect seems to be mediated *via* a presynaptic neural mechanism.^{7,8} Since 1999, dexmedetomidine, a specific α_2 -adrenoceptor agonist, has been approved for clinical use for sedation of patients who need mechanical ventilation in the intensive care unit.^{12,13} However, the effect of a selective α_2 -adrenergic agonist on airway reactivity is unknown. Therefore, we studied the effect of intravenous and aerosol administration of dexmedetomidine on histamine-induced bronchoconstriction in dogs using high-resolution computed tomographic (HRCT) imaging.

Materials and Methods

Animals

Our study protocol was approved by The Johns Hopkins Animal Care and Use Committee (Baltimore, Maryland). Five mongrel dogs that each weighed approximately 20 kg were anesthetized with thiopental (15-mg/kg induction dose followed by 10 $\text{mg} \cdot \text{kg}^{-1} \cdot \text{h}^{-1}$) and paralyzed with succinylcholine (0.5 mg/kg with supplemental doses as needed). After tracheal intubation, the dogs were placed in the supine position and ventilated with room air with a volume-cycled ventilator (Harvard Apparatus, Millis, MA). Heart rate was measured throughout the study period.

Imaging and Analysis of Airways. High-resolution computed tomographic scans were obtained with a Somatom PLUS 4 scanner (Siemens, Iselin, NJ) using a spiral mode to acquire 50 computed tomographic images during 12 s of breath holding at 120 kVp and 200 mA. The images were reconstructed with 1-mm slice thickness and a 512×512 matrix using a 125-cm field of view and a high spatial frequency (resolution) algorithm that enhanced edge detection (window level, -450 Hounsfield units; window width, 1,350 Hounsfield units). These settings provide accurate measurement of luminal size as small as 0.5 mm in diameter.^{14,15}

* Assistant Professor, Department of Anesthesiology and Critical Care Medicine and Department of Environmental Health Sciences/Division of Physiology, Johns Hopkins Medical Institutions. Associate Professor, Clinic of Anesthesiology and Critical Care Medicine, University Duisburg-Essen. † Professor, Department of Medicine/Division of Pulmonary Medicine and Environmental Health Sciences/Division of Physiology, Johns Hopkins Medical Institutions. ‡ Professor, Department of Anesthesiology and Critical Care Medicine, Department of Medicine/Division of Pulmonary Medicine and Environmental Health Sciences/Division of Physiology, Johns Hopkins Medical Institutions.

Received from The Johns Hopkins Medical Institutions, Baltimore, Maryland, and the Clinic of Anesthesiology and Critical Care Medicine, University Essen, Essen, Germany. Submitted for publication March 31, 2003. Accepted for publication October 15, 2003. Support was provided from departmental sources and a grant from the Max Kade Foundation, New York, New York. Presented in part at the Annual Meeting of the American Society of Anesthesiologists, Orlando, Florida, October 12–16, 2002.

Address reprint requests to Dr. Groeben: Department of Anesthesiology and Critical Care Medicine, University of Essen, Hufelandstrasse 55, 45122 Essen, Germany. Address electronic mail to: harald.groeben@uni-essen.de. Individual article reprints may be purchased through the Journal Web site, www.anesthesiology.org.

The HRCT images were analyzed using the airway analysis module of Volumetric Image and Display Analysis image analysis software (Department of Radiology, Division of Physiologic Imaging, University of Iowa, Iowa City, IA) as previously described and validated.^{16,17} Intraobserver and interobserver accuracy and variability of the software program using this HRCT technique in phantoms has been shown to be highly resistant to operator bias.^{16,17}

Protocol. To standardize lung volume history, the dogs were given an initial deep inspiration to 35 cm H₂O for 5 s. The first set of scans were taken as the first baseline measurement. Subsequently, the dogs received 10 puffs (5 s at 15 cm H₂O) of histamine (10 mg/ml in saline; Sigma Chemical, St. Louis, MO). Three minutes later, the HRCT scans were repeated. After a recovery period of 30 min and two times five deep inspirations to 35 cm H₂O for 5 s, HRCT scans were performed and taken as a new baseline (30 min after histamine).

In random order on different days, the animals were challenged with dexmedetomidine (donated by Abbott Laboratories, Abbott Park, IL) given as either an intravenous bolus or an aerosol. On one day, 0.5 μ g/kg dexmedetomidine was administered intravenously, and after 5 min, the HRCT scans were repeated. After another 5 min, the histamine challenge was repeated as described above. On another day (at least 3 days apart), 0.5 μ g/kg dexmedetomidine (diluted in 3 ml saline) was administered as an aerosol. Five minutes after completion of the aerosol administration, the HRCT scans were repeated, followed as before by a histamine challenge 5 min later. At the end of the experiments, the last HRCT scans were acquired after the airways of the dogs were relaxed with a high dose of atropine (0.2 mg/kg), which has been shown to maximally relax their airways.¹⁸ On a separate day, to confirm the absence of possible tachyphylaxis with repeated histamine challenges, *i.e.*, in two dogs the airways were challenged twice with histamine alone, the challenges were performed according to the protocol but without any dexmedetomidine administration.

Analysis

The airway area after atropine administration was defined as 100% (maximum). The airway luminal areas of all additional measurements were expressed as a percent of maximum. Each airway in each dog served as its own control. Analysis of variance was used to compare the airway size, controlling for dexmedetomidine, histamine, and route of administration, with Bonferroni corrections for multiple pairwise comparisons. In addition, paired *t* tests were used to compare airway areas after challenge with baseline. *P* values of 0.05 or less were considered to be significant.

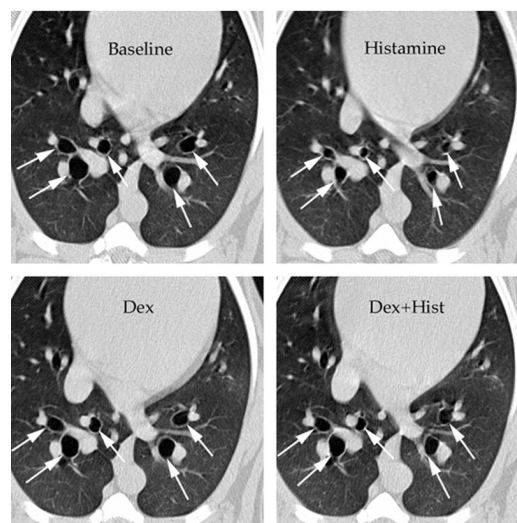


Fig. 1. Matched high-resolution computed tomographic images of airways from one dog at control (*upper left*), after a histamine challenge (*upper right*), after administration of 0.5 μ g/kg intravenous dexmedetomidine (Dex) (*lower left*), and after a repetition of the histamine (Hist) challenge (*lower right*). Nebulization of histamine led to marked bronchoconstriction. After intravenous administration of the α_2 -receptor agonist dexmedetomidine, the response to histamine was almost completely blocked.

Results

Histamine Challenge at Baseline

Baseline computed tomographic scans showed an airway area of $86.1 \pm 27.9\%$ (mean \pm SD) on the day of intravenous dexmedetomidine administration and $85.4 \pm 29.6\%$ on the day of aerosol administration compared with the airway area at bronchodilation after systemic administration of atropine. Histamine challenge led to a significant decrease in airway area to $65.8 \pm 26.9\%$ ($P < 0.0001$) and $59.2 \pm 29.9\%$ ($P < 0.0001$) on the intravenous and aerosol days, respectively. After at least 30 min of recovery and the described recruitment maneuvers, the airway area was similar to the baseline airway area. The mean airway areas were $89.5 \pm 29.1\%$ and $89.9 \pm 22.2\%$, respectively (figs. 1 and 2). There were no differences in baseline areas and responses to histamine between the days of intravenous or inhalational administration of dexmedetomidine ($P = 0.4177$).

Intravenous or Inhalational Dexmedetomidine

Intravenous administration of dexmedetomidine caused a small but significant bronchodilation. The airway area after intravenous dexmedetomidine administration was $95 \pm 20.2\%$ of maximum compared with the second baseline airway luminal area of $89.5 \pm 29.1\%$ of maximum after the initial histamine challenge ($P = 0.0003$). In contrast, inhalation of dexmedetomidine caused significant bronchoconstriction. The airway area after inhalational dexmedetomidine decreased significantly to $65.5 \pm 26.3\%$ ($P < 0.0001$; fig. 2).

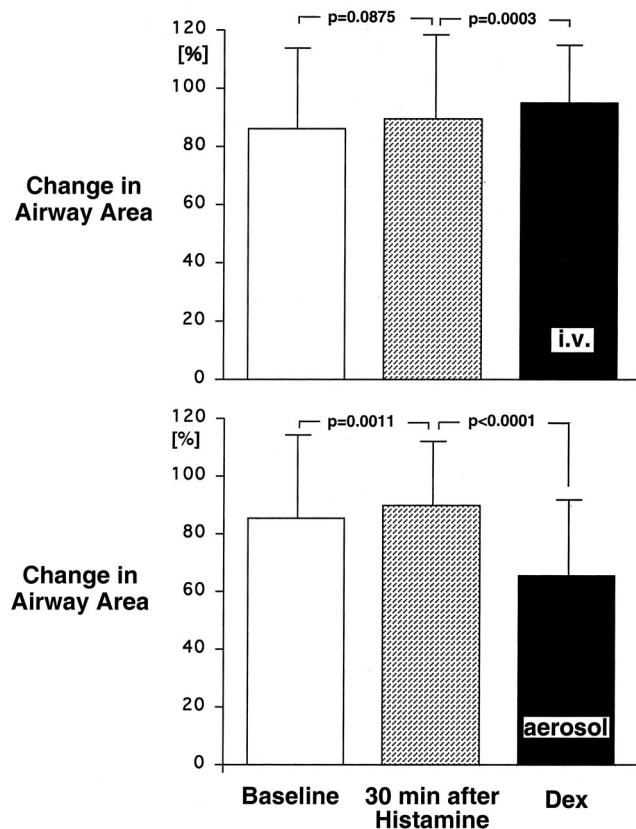


Fig. 2. Change in airway area at baseline, 30 min after histamine challenge, and after intravenous (i.v.) injection (*top*) or inhalation (*bottom*) of dexmedetomidine (Dex), compared with maximal bronchodilation with atropine (100%; mean \pm SD). Thirty minutes after histamine challenge and deep inspirations, the airway area fully recovered or even increased compared with prehistamine baseline. Intravenous administration of dexmedetomidine slightly but significantly increased the airway area, whereas inhalation of dexmedetomidine led to significant bronchoconstriction.

Histamine Challenge after Dexmedetomidine Administration

Histamine challenge after intravenous dexmedetomidine administration decreased the airway area slightly but significantly from the second baseline of $95 \pm 20.2\%$ to $87.1 \pm 30.4\%$ of maximum ($P < 0.0001$). However, compared with the first baseline airway area measurement before dexmedetomidine administration, the slight histamine-induced decrease in airway area after intravenous dexmedetomidine administration was not significant ($P = 0.1144$; figs. 1 and 3).

In contrast, inhalational dexmedetomidine had no protective effect on the histamine-induced bronchoconstriction. The histamine challenge after inhalation of dexmedetomidine decreased the airway area significantly to $45.9 \pm 30.4\%$ ($P < 0.0001$; fig. 3).

Repeated Histamine Challenge

On a separate day, in two different dogs, two histamine challenges were performed according to the protocol but without any dexmedetomidine administration.

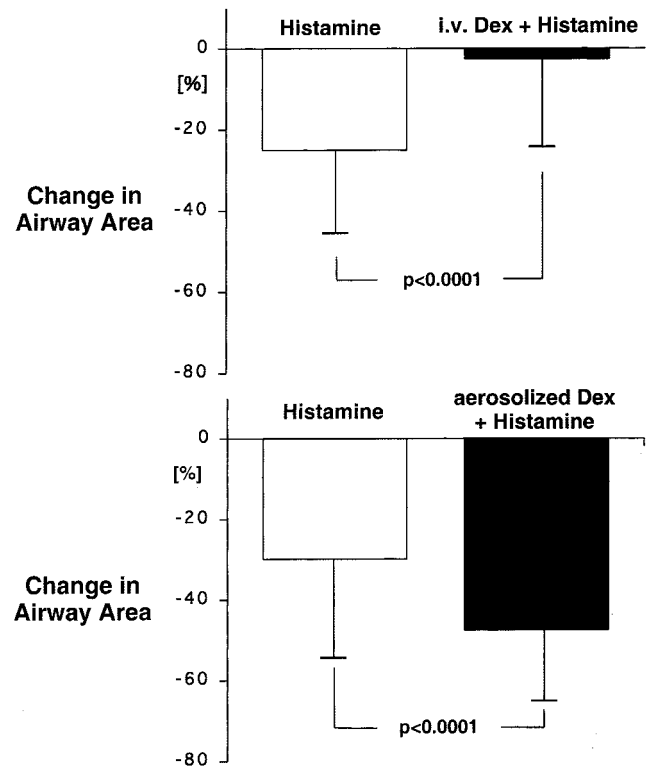


Fig. 3. Response to a histamine challenge expressed as a change in airway area at baseline and after intravenous (i.v.) (*top*) or inhalational (*bottom*) administration of dexmedetomidine (Dex). Changes refer to the respective baseline (mean \pm SD). The initial histamine challenge led to a decrease in airway area of $23.5 \pm 20.5\%$ (*top*) or $29.1 \pm 24.6\%$ (*bottom*). Intravenous dexmedetomidine significantly blocked this response, whereas dexmedetomidine as an aerosol did not ($47.5 \pm 17.8\%$; *bottom*).

Histamine led to a decrease in airway area in both dogs after the first and second histamine challenges. In one dog, the airway area decreased $58 \pm 15\%$ after the first challenge. After 30 min of recovery and the described recruitment maneuvers, the second challenge led to a decrease of $49 \pm 18\%$. In the other dog, the first challenge decreased the airway area $35 \pm 22\%$, whereas the second histamine challenge decreased the airway area $47 \pm 19\%$.

Heart Rate

Heart rate decreased significantly after intravenous administration of dexmedetomidine, from $135 \pm 21 \text{ min}^{-1}$ to $108 \pm 28 \text{ min}^{-1}$ ($P = 0.0002$). Parasympatholysis with atropine at the end of the study day with intravenous administration of dexmedetomidine increased the heart rate to $130 \pm 11 \text{ min}^{-1}$. Inhalation of dexmedetomidine did not change the heart rate. Parasympatholysis with atropine at the end of the study day with aerosol administration of dexmedetomidine increased the heart rate significantly to $172 \pm 10 \text{ min}^{-1}$ compared with the baseline value of $139 \pm 20 \text{ min}^{-1}$ ($P < 0.0001$).

Discussion

In dogs, intravenous administration of the α_2 -adrenergic agonist dexmedetomidine blocked the neurally mediated bronchoconstriction induced by aerosol histamine. In contrast, dexmedetomidine administered by the inhalational route elicited a significant bronchoconstrictor response and not only provided no bronchoprotection against aerosol histamine, but actually enhanced the bronchoconstrictor response.

Airway irritation leads to parasympathetically mediated reflex bronchoconstriction of airways of 1 mm and larger.¹⁹⁻²² Histamine inhalation elicits bronchoconstriction *via* reflex parasympathetic pathways and direct effects on smooth muscle cells, with more stimulation of irritant receptors than acetylcholine.²³ In bronchi larger than 1 mm, histamine-induced bronchoconstriction can be blocked by cooling or cutting of the vagal nerves or by high-dose administration of atropine, indicating a mainly reflex bronchoconstriction.¹⁹⁻²² HRCT can visualize airways of 0.5 mm and larger and is therefore a sensitive method to detect histamine-induced reflex bronchoconstriction.^{14,15} In fact, HRCT has been shown to be more sensitive to prove significant changes in bronchial area than measurements of airway pressure and derived measurements, such as airway resistance.¹⁴ Repeated inhalational challenges with histamine can lead to tachyphylaxis and decreasing airway responsiveness. However, this effect is dose dependent and occurs only in high doses, whereas in low doses, the airway response is reproducible.²⁴ The fact that the airway irritation by dexmedetomidine inhalation almost matches the effect of our histamine challenge shows that we used a low dose of histamine. Nevertheless, we performed control measurements without dexmedetomidine administration to exclude any significant tachyphylaxis in our study design.

Despite intensive medical treatment in near fatal asthma attacks and severe exacerbations of chronic obstructive pulmonary disease, mechanical ventilation often becomes necessary with the risk that instrumentation of the airway will worsen the existing bronchoconstriction. Mechanically ventilation of patients with severe asthma attacks is associated with a mortality rate up to 31%.²⁵⁻²⁷ In these patients, mechanical ventilation and weaning from mechanical ventilation can be further complicated by airway irritation.

In a previous study in subjects with only mild asthma, we showed that tracheal intubation elicited a reduction of forced expiratory volume in 1 s of more than 50%.⁶ In that study, the use of β_2 -adrenoceptor agonists attenuated the response to tracheal intubation by only approximately 10%.⁶ Therefore, when patients with severe asthma or severe bronchial hyperreactivity must be endotracheally intubated, additional prophylactic medication is beneficial.

Besides β_2 -adrenergic receptors and the three identified muscarinic receptors, there are α_1 - and α_2 -adrenergic receptors present in the bronchial mucosa and on parasympathetic bronchial ganglia.^{7,8,11,28} Although the β_2 -adrenergic receptors and muscarinic receptors have been successful targets for pharmacologic interventions for airway disease, the function and relevance of α -adrenergic receptors in the airways has been speculative. It has been shown that stimulation of α_1 adrenoceptors leads to bronchoconstriction, which can be blocked by α_1 -adrenoceptor antagonists.^{29,30} In contrast, studies of Grundström *et al.*^{7-9,28,30,31} suggest that α_2 -adrenergic receptors modulate parasympathetic tone and inhibit bronchoconstriction. Isolated guinea pig and human tracheal and bronchial rings were mounted for recording of isometric tension under electric field stimulation.⁷⁻⁹ During β_2 - and α_1 -adrenoceptor blockade, stimulation with noradrenaline could completely block contraction of the rings. This effect was antagonized by the α_2 -adrenoceptor antagonist yohimbine.⁹ Similar effects can be shown *in vivo* in humans on exercise-induced bronchoconstriction when β_2 - and α_1 -adrenoceptors are blocked, leaving α_2 -adrenoceptor function unaltered.⁷ Unfortunately, until the recent introduction of dexmedetomidine into clinical practice, there were no specific α_2 -adrenergic agonists available.^{12,32-35} Dexmedetomidine is a specific α_2 -adrenergic agonist with a ratio of 1,300:1 (α_2 : α_1 adrenoceptors), and it is eight times more specific than clonidine. Most of the effects of dexmedetomidine, such as sedation as well as cardiovascular effects, can be ascribed to the α_{2A} -adrenergic receptor subtype.^{32,35}

Dexmedetomidine effects are mediated through postsynaptic α_2 -adrenoceptors activating pertussis toxin-sensitive G proteins, which in turn increase conductance of potassium ion channels.¹²

As expected, dexmedetomidine prevents hypertension and tachycardia, leading to hemodynamic stability in stressful situations, such as weaning from mechanical ventilation or awakening from anesthesia, with a tendency toward possible side effects, such as hypotension and bradycardia.^{36,37} With respect to its effect on respiratory drive, dexmedetomidine begins to suppress respiratory drive in doses of 2.0 $\mu\text{g}/\text{kg}$ and higher.³⁸ Its sedative properties are unique in that it produces anxiety and only mild cognitive impairment, allowing easy communication between intensive care unit personnel and intubated patients.³³ This effect can be advantageous in patients who are difficult to wean from mechanical ventilation. In this situation, a substance that combines "cooperative sedation" and attenuation of reflex bronchoconstriction is desirable.

Our results showed that a dose of 0.5 $\mu\text{g}/\text{kg}$ dexmedetomidine almost completely blocked reflex-induced bronchoconstriction. Because the half-life of dexmedetomidine is 40-47 min and the time to complete all the scans and histamine challenge in our protocol was less than 30 min,

a continuous intravenous infusion of dexmedetomidine was not necessary in our study.³⁹ Furthermore, the dose used for the current study is on the low side of the doses typically used for sedation in the intensive care unit, where doses with an initial bolus of 2.0 $\mu\text{g}/\text{kg}$ followed by a continuous infusion have been used.

Topical administration of a drug can offer high local drug concentrations and drug-specific effects, with a low incidence of systemic side effects, as is the case with β_2 -adrenergic agonists and parasympatholytic bronchodilators. To evaluate this effect for an α_2 -adrenergic agonist, we administered dexmedetomidine as an aerosol. However, when dexmedetomidine was administered as an aerosol directly into the lungs, there was an initial and significant bronchoconstriction of the airways that was comparable with the response to the dose of histamine. This bronchoconstriction could be due at least in part to irritation of the airways. Airway irritation by aerosolized drugs is well described. Nevertheless, in certain instances, such as with local anesthetics, subsequent protection can be demonstrated.^{40,41} However, for dexmedetomidine, a subsequent inhalational challenge with histamine led to increased bronchoconstriction from the response to histamine challenge alone. However, because of the profound bronchoconstriction caused by aerosolized dexmedetomidine, it is difficult to define a response to a subsequent histamine challenge. With two bronchoconstrictive stimuli and possible different mechanisms, we cannot separate the effect of one on the other.

In conclusion, intravenous administration of dexmedetomidine in clinically relevant doses significantly attenuates histamine-induced reflex bronchoconstriction in canine airways. These results show that stimulation of α_2 -adrenoceptor agonists in the airways has bronchoprotective effects and might have additional advantages for patients with asthma or chronic obstructive pulmonary disease who are difficult to wean.

References

- Warren EL, McFadden ER: Sudden death in asthma. *Asthma*. By Barnes PJ, Grunstein MM, Leff AR, Wollcock AJ. Philadelphia, New York, Lippincott-Raven, 1997, pp 1945-54
- Bach PB, Brown C, Gelfand SE, McCrory DC: Management of acute exacerbations of chronic obstructive pulmonary disease: A summary and appraisal of published evidence. *Ann Intern Med* 2001; 134:600-20
- Warner DO, Warner MA, Offord KP, Schroeder DR, Maxson P, Scanlon PD: Airway obstruction and perioperative complications in smokers undergoing abdominal surgery. *ANESTHESIOLOGY* 1999; 90:372-9
- Maslow AD, Regan MM, Israel E, Darvish A, Mehrez M, Boughton R, Loring SH: Inhaled albuterol, but not intravenous lidocaine, protect against intubation-induced bronchoconstriction in asthma. *ANESTHESIOLOGY* 2000; 93:1198-204
- Kil HK, Rooke GA, Ryan-Dykes MA, Bishop MJ: Effect of prophylactic bronchodilator treatment on lung resistance after tracheal intubation. *ANESTHESIOLOGY* 1994; 81:43-8
- Groeben H, Schlicht M, Stieglitz S, Pavlakovic G, Peters J: Both local anesthetics and salbutamol pretreatment affect reflex bronchoconstriction in volunteers with asthma undergoing awake fiberoptic intubation. *ANESTHESIOLOGY* 2002; 97:1445-50
- Grundström N, Andersson RGG: Inhibition of the cholinergic neurotransmission in human airways via prejunctional α_2 -adrenoceptors. *Acta Physiol Scand* 1985; 125:513-7
- Grundström N, Andersson RGG, Wikberg JES: Prejunctional α_2 adrenoceptors inhibit contraction of tracheal smooth muscle by inhibiting cholinergic neurotransmission. *Life Sci* 1981; 28:2981-6
- Grundström N, Andersson RGG, Wikberg JES: Inhibition of the excitatory non-adrenergic, non-cholinergic neurotransmission in the guinea pig tracheo-bronchial tree mediated by α_2 adrenoceptors. *Acta Pharmacol Toxicol* 1984; 54:8-14
- Lou YP, Franco-Cereceda A, Lundberg JM: Variable α_2 -adrenoceptor-mediated inhibition of bronchoconstriction and peptide release upon activation of pulmonary afferents. *Eur J Pharmacol* 1992; 210:173-81
- Goldie RG: Receptors in asthmatic airways. *Am Rev Respir Dis* 1990; 141:S151-6
- Bhana N, Goa KL, McClellan KJ: Dexmedetomidine. *Drugs* 2000; 59:263-8
- Vitanen R, Savola JM, Saano V, Nyman L: Characterization of the selectivity, specificity and potency of medetomidine as an α_2 -adrenoceptor agonist. *Eur J Pharmacol* 1988; 150:9-14
- Herold CJ, Brown RH, Mitzner W, Links JM, Hirshman CA, Zerhouni EA: Assessment of pulmonary airway reactivity with high-resolution CT. *Radiology* 1991; 181:369-74
- Wood SA, Zerhouni EA, Hoford JD, Hoffman EA, Mitzner W: Measurement of three-dimensional lung tree structures by using computed tomography. *J Appl Physiol* 1995; 79:1687-97
- Amirav I, Kramer SS, Grunstein MM, Hoffman EA: Assessment of methacholine-induced airway constriction by ultrafast high-resolution computed tomography. *J Appl Physiol* 1993; 75:2239-50
- Brown RH, Zerhouni EA, Mitzner W: Visualization of airway obstruction in vivo during lung vascular engorgement and edema. *J Appl Physiol* 1995; 78:1070-8
- Brown RH, Mitzner W: Effect of lung inflation and airway muscle tone on airway diameter in vivo. *J Appl Physiol* 1996; 80:1581-8
- Seikizawa K, Yanai M, Shimizu Y, Sasaki H, Takishima T: Serial distribution of bronchoconstriction in normal subjects. *Am Rev Respir Dis* 1988; 137:1312-6
- Sellick H, Widdicombe JG: Stimulation of lung irritant receptors by cigarette smoke, carbon dust, and histamine aerosol. *J Appl Physiol* 1971; 31:15-9
- Nadel JA, Cabezas GA, Austin JHM: In vivo roentgenographic examination of parasympathetic innervation of small airways. *Invest Radiol* 1971; 6:9-17
- Shore SA, Bai TR, Wang CG, Martin LG: Central and local cholinergic components of histamine-induced bronchoconstriction in dogs. *J Appl Physiol* 1985; 58:443-51
- Dixon M, Jackson DM, Richards IM: The effects of histamine, acetylcholine and 5-hydroxytryptamine on lung mechanics and irritant receptors in the dog. *J Physiol* 1979; 287:393-403
- Shore S, Martin JG: Tachyphylaxis to inhaled aerosolized histamine in anesthetized dogs. *J Appl Physiol* 1985; 59:1355-63
- Alex CG, Tobin MJ: Ventilation of asthmatic patients. *Asthma*. By Barnes PJ, Grunstein MM, Leff AR, Wollcock AJ. Philadelphia, New York, Lippincott-Raven, 1997, pp 1977-2003
- Afessa B, Morales I, Curry JD: Clinical course and outcome of patients admitted to an ICU for status asthmaticus. *Chest* 2001; 120:1616-21
- Zimmermann JL, Dellinger RP, Shah AN, Taylor RW: Endotracheal intubation and mechanical ventilation in severe asthma. *Crit Care Med* 1993; 21:1727-30
- Barnes PJ, Karlinger JS, Dollery CT: Human lung adrenoceptors studied by radioligand binding. *Clin Science* 1980; 58:457-61
- Kneussl MP, Richardson JB: Alpha-adrenergic receptors in human and canine tracheal and bronchial smooth muscle. *J Appl Physiol* 1978; 45:307-11
- Patel KR, Kerr JW: The airways response to phenylephrine after blockade of α and β -receptors in extrinsic bronchial asthma. *Clin Allergy* 1973; 3:439-48
- Patel KR, Kerr JW: Alpha-receptor-blocking drugs in bronchial asthma (letter). *Lancet* 1975; 1:348-9
- Venn RM, Grounds RM: Comparison between dexmedetomidine and propofol for sedation in the intensive care unit: Patient and clinician perception. *Br J Anaesth* 2001; 87:684-90
- Kamibayashi T, Maze M: Clinical uses of α_2 -adrenergic agonists. *ANESTHESIOLOGY* 2000; 93:1345-9
- Hall JE, Uhrich TD, Barney JA, Arain SR, Ebert TJ: Sedative, amnestic, and analgesic properties of small-dose dexmedetomidine infusions. *Anesth Analg* 2000; 90:699-705
- Tan CM, Wilson MH, MacMillan LB, Kobilka BK, Limbrid LE: Heterozygous α_2A -adrenergic receptor mice unveil unique therapeutic benefits of partial agonists. *Proc Natl Acad Sci U S A* 2002; 99:12471-6
- Venn R, Bradshaw C, Spencer R, Brealey D, Caudwell E, Naughton C, Vedio A, Singer M, Feneck R, Treacher D, Willats SM, Grounds RM: Preliminary UK experience of dexmedetomidine, a novel agent for postoperative sedation in the intensive care unit. *Anaesthesia* 1999; 54:1136-42
- Venn R, Hell J, Grounds RM: Respiratory effects of dexmedetomidine in the surgical patient requiring intensive care. *Crit Care* 2000; 4:302-8
- Belleville JP, Ward DS, Bloor BC, Maze M: Effects of intravenous dexmedetomidine in humans. *ANESTHESIOLOGY* 1992; 77:1125-33
- Kuusela E, Raekallio M, Anttila M, Falck I, Mölsä S, Vainio O: Clinical effects and pharmacokinetics of medetomidine and its enantiomers in dogs. *J Vet Pharmacol Ther* 2000; 23:15-20
- Bulut Y, Hirshman CA, Brown RH: Prevention of lidocaine aerosol-induced bronchoconstriction with intravenous lidocaine. *ANESTHESIOLOGY* 1996; 85:853-9
- Groeben H, Großwendt T, Silvanus MT, Beste M, Peters J: Lidocaine inhalation for local anesthesia and attenuation of bronchial hyperreactivity with least airway irritation: Effect of three different dose regimens. *Eur J Anaesthesiol* 2000; 17:680-7