

Mandibular Advancement Improves the Laryngeal View during Direct Laryngoscopy Performed by Inexperienced Physicians

Miki Tamura, M.D.,* Teruhiko Ishikawa, M.D.,† Rie Kato, M.D.,† Shiroh Isono, M.D.,‡ Takashi Nishino, M.D.§

Background: When oral or nasal fiberoptic laryngoscopy is attempted, mandibular advancement has been reported to improve the laryngeal view. The authors hypothesized that mandibular advancement may also improve the laryngeal view during direct laryngoscopy.

Methods: Forty patients undergoing elective surgery under general anesthesia were included in this study. After establishment of an adequate level of anesthesia and muscle relaxation, direct laryngoscopy was performed by inexperienced physicians. Four different maneuvers—simple direct laryngoscopy without any assistance (C), simple direct laryngoscopy with mandibular advancement (M), simple direct laryngoscopy with the BURP maneuver (backward, upward, rightward pressure maneuver of the larynx; B), and simple direct laryngoscopy with both mandibular advancement and the BURP maneuver (BM)—were attempted in each subject, and the laryngeal aperture was videotaped with each procedure. An instructor in anesthesiology who was blinded to the procedure evaluated the visualization by reviewing videotape off-line, using the Cormack-Lehane classification system (grades I–IV) and a rating score within each subject (1 = best view; 4 = poorest view). The Friedman test followed by the Student-Newman-Keuls test was performed for statistical comparison. $P < 0.05$ was considered significant.

Results: The laryngeal view was improved with M and B when compared with C ($P < 0.05$ by both rating and Cormack-Lehane evaluation). BM was the most effective method to visualize the laryngeal aperture ($P < 0.05$, vs. B and M by rating evaluation), whereas B and M were the second and the third most effective methods, respectively. No statistical difference was observed between B and M with the Cormack-Lehane classification.

Conclusion: Mandibular advancement improves the laryngeal view during direct laryngoscopy performed by inexperienced physicians.

DIRECT laryngoscopy for tracheal intubation is often difficult, especially for inexperienced physicians. In most of these cases, a poor laryngeal view resulting from various factors makes tracheal intubation difficult. These factors include the operator's lack of skill and the anatomy of the patient. However, appropriate assistance may improve visualization of the larynx. Previous studies have reported that the BURP maneuver (backward, up-

ward, rightward pressure of the larynx) is effective in difficult laryngoscopy.^{1,2} In practice, this maneuver also improves poor visualization of the larynx resulting from insufficient skill in direct laryngoscopy.

When nasal fiberoptic laryngoscopy is attempted, mandibular advancement has been reported to improve the laryngeal view, probably by expanding the pharyngeal space and shifting the epiglottis ventrally,^{3,4} which is consistent with the fact that this maneuver is effective to keep the pharynx patent.⁵ Therefore, we hypothesized that mandibular advancement may also improve visualization of the larynx and be especially useful for inexperienced physicians during direct laryngoscopy.

Materials and Methods

Subjects

The project was approved by our institutional ethics committee (Chiba University, Chiba, Japan). Forty adult subjects with American Society of Anesthesiologists physical status classification I or II who gave informed consent participated in this study. The patients were scheduled to undergo elective surgery under general anesthesia in our hospital. None had clinical problems in the temporomandibular joints, the cervical spine, or any other regions that may hinder direct laryngoscopy. Each patient's airway was assessed preoperatively; the Mallampati score modified by Samsoon and Young,⁶ the thyromental distance, and the mouth opening distance were recorded.

Anesthesia

Routine monitoring, including electrocardiography, noninvasive blood pressure monitoring, and pulse oximetry, was performed. Anesthesia was induced intravenously with 50–100 μg fentanyl and 3–5 mg/kg thiopental or 1–2 mg/kg propofol, followed by inhalation of 3–5% sevoflurane. To facilitate direct laryngoscopy and tracheal intubation, 0.1–0.15 mg/kg vecuronium bromide was administered. Laryngoscopy was performed with use of a standard Macintosh No. 3 blade by relatively inexperienced physicians (< 100 laryngoscopies) with a soft pillow (height, 5 cm) under the occiput.

Protocol

Four different maneuvers—simple direct laryngoscopy without any assistance (control), simple direct laryngos-

* Resident in Anesthesiology, † Instructor, ‡ Assistant Professor, § Professor and Chairman.

Received from the Department of Anesthesiology, Graduate School of Medicine, Chiba University, Chiba, Japan. Submitted for publication March 20, 2003. Accepted for publication September 10, 2003. Supported by grant-in-aid No. 14571421 from the Ministry of Education, Culture, Sports, Science and Technology, Tokyo, Japan.

Address reprint requests to Dr. Ishikawa: Department of Anesthesiology (B1), Graduate School of Medicine, Chiba University, 1-8-1 Inohana, Chiba 260-8677, Japan. Address electronic mail to: tishikawa@faculty.chiba-u.jp. Individual article reprints may be purchased through the Journal Web site, www.anesthesiology.org.

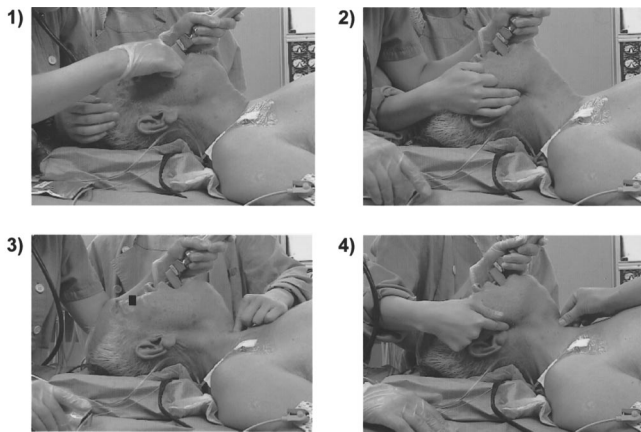


Fig. 1. The four procedures. (1) Simple direct laryngoscopy with no assistance. (2) Direct laryngoscopy with mandibular advancement. (3) Direct laryngoscopy with BURP maneuver. (4) Direct laryngoscopy both with mandibular advancement and with BURP maneuver. The procedures were performed with one laryngoscopist and two assistants. A cameraperson who videotapes the laryngeal aperture is not shown in the figure.

copy with mandibular advancement, simple direct laryngoscopy with the BURP maneuver, and simple direct laryngoscopy with the combination of mandibular advancement and the BURP maneuver—were performed in each subject (fig. 1). First, simple direct laryngoscopy was attempted with maximum efforts to visualize the larynx; visibility of the larynx was evaluated by means of the Cormack-Lehane classification system. We defined the Cormack-Lehane grade as follows: I = most of the glottis is visible; II = the posterior commissure is visible; III = no part of the glottis can be seen except the epiglottis; IV = not even the epiglottis can be seen.⁷ If the visualization of the glottis was categorized as Cormack-Lehane grade I, the pillow was removed and direct laryngoscopy was reattempted. If the visualization of the larynx was still categorized as Cormack-Lehane grade I even with this treatment, the subject was excluded from the study. Unless the visualization of the larynx was categorized as Cormack-Lehane grade I, the mandibular advancement and BURP procedures were attempted in random order with the blade of the laryngoscope that had been placed in the same position. Finally, the combination of mandibular advancement and the BURP maneuver was applied.

Evaluation

The laryngoscopic view in each procedure was videotaped with a camcorder (Digital Handycam, DCR-PC110; Sony, Tokyo, Japan) by another investigator. We used the built-in automatic focus and exposure function of the camcorder to obtain equivalent quality of images among the four procedures. The distance from the camcorder to the glottis was approximately 0.3 m, and maximum efforts were made to achieve the best laryngeal view by adjusting the angle of the camera in each procedure. A

Table 1. Demographic Data for the Subjects

No. of cases	40
Age, y	55.9 ± 15.3
Height, cm	161.3 ± 9.2
Weight, kg	58.8 ± 8.5
Sex (M/F)	26/14
Thyromental distance, cm	9.3 ± 1.2
Mouth opening, cm	4.7 ± 0.7

Data are presented as mean ± SD where appropriate. Excluded subjects (subjects with Cormack-Lehane grade I, even with no pillow) are not included in this table.

staff anesthesiologist who was naive to the procedure evaluated the visualization of the larynx by reviewing the videotape off-line, using the Cormack-Lehane classification system (grades I-IV).⁷ The laryngeal view of each procedure was also rated within the subject (1 = best view; 4 = worst view).

Statistical Analysis

The Friedman test followed by the Student-Newman-Keuls test was performed for statistical comparison. *P* < 0.05 was considered significant.

Results

In total, 14 physicians participated as laryngoscopists. Their experience ranged from 5 to 95 direct laryngoscopies. The demographic data of the subjects are presented in tables 1 and 2. More than 10 subjects were excluded from the study because the visibility of their glottis was classified as Cormack-Lehane grade I, even with no pillow. The data of these excluded subjects are not included in tables 1 and 2. Figure 2 shows typical visualization of the larynx with the four procedures. With simple direct laryngoscopy, the visualization of the larynx was categorized as Cormack-Lehane grade III. Significant improvement (Cormack-Lehane grade III to II) was observed either with mandibular advancement or with the BURP maneuver. Further improvement (Cormack-Lehane grade II to I) was achieved with the combination of mandibular advancement and the BURP maneuver. The laryngeal view provided by the BURP maneuver was better than that provided by mandibular advancement.

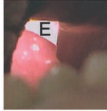

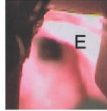
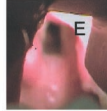
Figure 3A shows improvement of the laryngeal view

Table 2. Distribution of Mallampati and Cormack-Lehane Classifications

	I	II	III	IV
Mallampati	14	24	2	0
Cormack-Lehane	12	18	10	0

Cormack-Lehane classification was assessed by the laryngoscopists, with a soft pillow (height, 5 cm) under the occiput of each patient. Excluded subjects (subjects with Cormack-Lehane grade I, even with no pillow) are not included in this table. N = 40.

Fig. 2. Demonstrable laryngeal views during direct laryngoscopy with the four procedures along with Cormack-Lehane and rating evaluations in one individual subject. The epiglottis is labeled *E* in each laryngoscopic image. C = simple direct laryngoscopy; M = C with mandibular advancement; B = C with BURP maneuver; BM = C with both M and B.

Procedures	C	M	B	BM
Laryngeal view				
Cormack-Lehane	III	II	II	I
Rating score	4	3	2	1

with each procedure according to the Cormack-Lehane classification. Both the BURP maneuver and mandibular advancement improved the laryngeal view when compared with simple direct laryngoscopy ($P < 0.05$). We did not detect any significant difference between mandibular advancement and the BURP maneuver. The combination of the two maneuvers with simple direct laryngoscopy was the most effective to obtain a clear view of the glottis.

The rating scores are presented in figure 3B. The most effective procedure to improve visualization of the larynx was the combination of mandibular advancement and the BURP maneuver. The BURP maneuver was more effective at improving the laryngeal view than was mandibular advancement ($P < 0.05$).

Discussion

The new findings of this study are that (1) when direct laryngoscopy is attempted by inexperienced physicians, mandibular advancement is effective to improve the laryngeal view during direct laryngoscopy, and (2) further improvement can be obtained by the combination of the BURP maneuver and mandibular advancement.

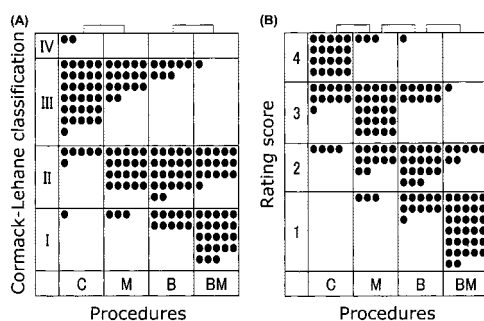


Fig. 3. Results of Cormack-Lehane classification (A) and rating score (B). Closed circle = single case; square bracket = statistical difference ($P < 0.05$, Friedman test followed by Student-Newman-Keuls test). Some of the brackets are omitted for clarity. C = simple direct laryngoscopy; M = C with mandibular advancement; B = C with BURP maneuver; BM = C with both M and B.

Study Design and Methodology

We used a camcorder to evaluate visualization of the larynx during direct laryngoscopy. This was necessary to keep the evaluation objective. However, the images from the laryngeal view obtained from the videotape might have been different from the view of laryngoscopists. The images from the tape were affected by various conditions such as focus, exposure time, and angle. We used the built-in automatic focus and exposure function to keep the quality of the images comparable among the four procedures. The angle of the camcorder was adjusted to maximize the visualization of the glottis. Therefore, we consider that using the camcorder for evaluation had little influence on the results.

Possible Mechanism of Improving Laryngeal View by Advancing the Mandible during Direct Laryngoscopy

Although this study was not designed to clarify the underlying mechanism by which mandibular advancement improved the laryngeal view during direct laryngoscopy, some possible explanations can be proposed from a biomechanical viewpoint. The sniffing position, extension of the upper and flexion of the lower cervical vertebrae, is recommended for direct laryngoscopy. Mandibular advancement may contribute to achieve an ideal sniffing position because the maneuver may extend the upper cervical vertebrae. Another possible explanation is that mandibular advancement expands the soft tissue around the glottis and improves visualization of the larynx.³ Moreover, the epiglottis is connected with the hyoid bone by the hyoepiglottic ligament, and the hyoid is joined with the mandible by the geniohyoid muscle; therefore, it is possible that mandibular advancement lifts the epiglottis upward through the anatomic connection. The fact that the combination of the BURP maneuver and mandibular advancement provided the best laryngeal view may suggest that the two maneuvers, mandibular advancement and the BURP maneuver, improve the visualization through different mechanisms.

Clinical Implications and Limitations

Mandibular advancement may be different from the BURP maneuver in regard to its mechanism and approach to improve the visualization of the glottis. The effect of mandibular advancement on improvement of laryngeal view was statistically less than that of the BURP maneuver according to the rating score; however, a better laryngeal view was obtained in some cases by mandibular advancement than by the BURP maneuver, and no statistical difference was detected with the Cormack-Lehane classification. Therefore, we believe that mandibular advancement is a good option when the glottic view during direct laryngoscopy is insufficient for tracheal intubation. In this study, direct laryngoscopy was performed by inexperienced physicians whose skills were not necessarily sufficient; mandibular advancement should provide appropriate assistance for these physicians on direct laryngoscopy. However, it is still uncertain whether the efficacy of the maneuver is also true for direct laryngoscopy performed by experienced anesthesiologists. We did not have enough cases of possible difficult laryngoscopy; only 10 subjects were categorized as Cormack-Lehane grade III or IV (table 2). Therefore, further investigations are necessary to conclude that mandibular advancement is also effective in difficult laryngoscopy.

In summary, we examined the effect of mandibular advancement on visualization of the larynx during direct laryngoscopy. Mandibular advancement was effective at improving the laryngeal view, at least when the laryngoscopy was attempted by inexperienced physicians. We believe that the maneuver has clinical significance because its approach and mechanism are different from that of the BURP maneuver.

References

1. Knill RL: Difficult laryngoscopy made easy with a "BURP." *Can J Anaesth* 1993; 40:279-82
2. Takahata O, Kubota M, Mamiya K, Akama Y, Nozaka T, Matsumoto H, Ogawa H: The efficacy of the "BURP" maneuver during a difficult laryngoscopy. *Anesth Analg* 1997; 84:419-21
3. Takenaka I, Aoyama K, Kadoya T, Sata T, Shigematsu A: Fiberoptic assessment of laryngeal aperture in patients with difficult laryngoscopy. *Can J Anaesth* 1999; 46:226-31
4. Aoyama K, Nagaoka E, Takenaka I, Kadoya T: The McCoy laryngoscope expands the laryngeal aperture in patients with difficult intubation. *ANESTHESIOLOGY* 2000; 92:1855-6
5. Isono S, Tanaka A, Sho Y, Konno A, Nishino T: Advancement of the mandible improves velopharyngeal airway patency. *J Appl Physiol* 1995; 79: 2132-8
6. Samsoon GL, Young JR: Difficult tracheal intubation: A retrospective study. *Anaesthesia* 1987; 42:487-90
7. Cormack RS, Lehane J: Difficult tracheal intubation in obstetrics. *Anaesthesia* 1984; 39:1105-11