

## An Unusual Cause of Airway Obstruction during General Anesthesia with a Laryngeal Mask Airway

Christopher M. Bernard, M.D.\*

VAGAL nerve stimulation is a new and increasingly common therapy for intractable seizures. We report a case of intermittent airway obstruction caused by the vagal nerve stimulator during general anesthesia with a laryngeal mask airway.

### Case Report

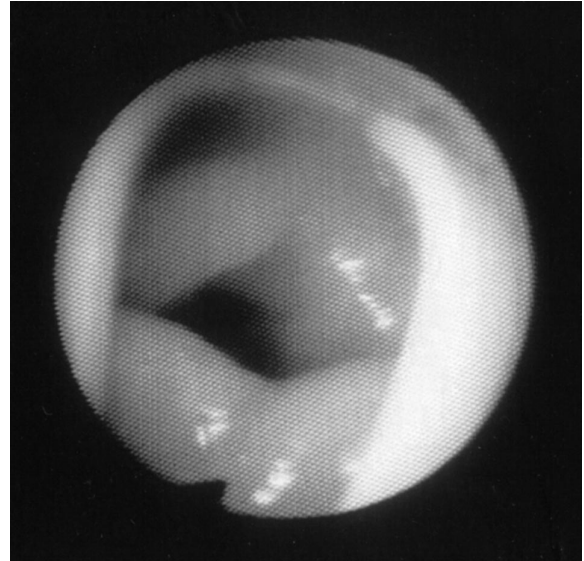S. E. C. is a 54-yr-old woman who was scheduled to undergo open reduction and internal fixation of an isolated trimalleolar ankle fracture that she sustained after a fall. Her medical history was significant for an idiopathic, partial-complex seizure disorder of approximately 25 years' duration. Her surgical history was significant for placement of a vagal nerve stimulator (VNS) approximately 2 yr previously to improve control of her seizures. Her current medications consisted of carbamazepine (1,200 mg/day), multivitamins, and calcium supplements.

The patient was premedicated with 1 mg intravenous midazolam and 50 µg intravenous fentanyl. General anesthesia was induced with 40 mg lidocaine-150 mg propofol, and a No. 4 laryngeal mask airway (LMA) was inserted without difficulty on the first attempt. Anesthesia was maintained with isoflurane (1-1.4%) in oxygen (50%, balance nitrogen).

Spontaneous respiration resumed almost immediately after LMA insertion. However, shortly thereafter, the patient was noted to have inspiratory stridor and sternal retractions suggesting partial obstruction. Continuous positive airway pressure was applied (approximately 20 cm H<sub>2</sub>O), resulting in markedly decreased stridor and retractions. Positive pressure was continued for approximately 1 min, after which the obstruction spontaneously resolved. Approximately 5 min later, partial obstruction and stridor recurred but were again relieved by continuous positive airway pressure. After approximately 1 min, the apparent obstruction resolved spontaneously, only to recur again approximately 5 min later.

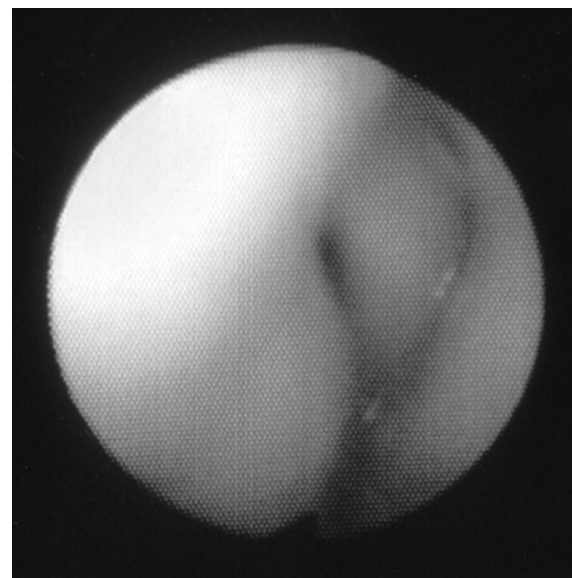This pattern of intermittent obstruction followed by an unobstructed interval recurred over approximately 40 min. It was then decided to perform fiberoptic laryngoscopy through the lumen of the LMA to identify the source of the obstruction. A fiberoptic bronchoscope swivel adapter was attached to the LMA to permit insertion of a fiberoptic bronchoscope without disconnecting the patient from the anesthetic circuit. Initial examination, during an unobstructed period, showed the LMA to be appropriately positioned and the cords to be fully open (fig. 1). The fiberoptic scope was left in place until the next obstructed episode, at which time the left arytenoid and aryepiglottic fold were seen to have been pulled across the midline to almost completely obstruct the glottic opening (fig. 2). Application of positive airway pressure moved the vocal fold part of the way back toward its normal position and improved ventilation; however, when positive airway pressure was released, the arytenoid would again move across the midline to obstruct the airway. This persisted for approximately 1 min, after which it spontaneously resolved.

Given the fixed periodicity of the patient's obstructive episodes, we



**Fig. 1.** View of airway through laryngeal mask airway during unobstructed period. The airway is open and symmetric. The bright reflection is the strut of the laryngeal mask airway.

began to suspect that her VNS was the source of the intermittent abnormal positioning of her arytenoid. Review of her records revealed that her VNS was set to fire at 30 Hz for 1 min followed by a 5-min off-time. This pattern exactly matched the pattern of intermittent obstruction. We reasoned that stimulation of the left vagus nerve resulted in stimulation of the recurrent and superior laryngeal nerves, which produced tetanic contraction of the musculature on the left side of the larynx.



**Fig. 2.** View of airway through laryngeal mask airway during obstructed period. The airway opening is no longer visible, and the left arytenoid has been pulled across the midline. The bright reflection is the strut of the laryngeal mask airway.

\* Professor of Anesthesiology.

Received from the Department of Anesthesiology, University of Washington, Seattle, Washington. Submitted for publication September 12, 2003. Accepted for publication October 17, 2003. Support was provided solely from institutional and/or departmental sources.

Address reprint requests to Dr. Bernard: Department of Anesthesiology, Box 356540, University of Washington, Seattle, Washington 98195. Address electronic mail to: chrisb@u.washington.edu. Individual article reprints may be purchased through the Journal Web site, www.anesthesiology.org.

## Discussion

Vagal nerve stimulators were approved by the US Food and Drug Administration in 1997 to control intractable seizures. They consist of a pulse generator and a bipolar lead that encircles the left vagus nerve in the neck. The generator is programmable, and the controllable variables include on-time, off-time, stimulus amplitude, and stimulus frequency. The mechanism by which VNSs reduce seizure severity is not known but is presumed to result from retrograde conduction of electrical impulses *via* the vagus nerve to stimulate brain structures known to influence seizures.

Although the VNS is effective in reducing seizure frequency,<sup>1,2</sup> it also produces noticeable side effects. Most problems relate to the period of vagal nerve stimulation, and the most common problem (66% of patients) is that of alterations in the voice, such as hoarseness or breathiness.<sup>3</sup> Other problems include dysphagia, dyspnea, aspiration, muscle pain, and paresthesias.

The VNS-mediated side effects associated with the voice are caused by stimulation of both the superior and the recurrent laryngeal nerve, which are branches of the vagus nerve. Together, these two nerves innervate all the muscles of the larynx. Several studies that have examined patients with voice abnormalities during vagal nerve stimulation have documented that the left vocal fold and arytenoids are displaced medially during the period of vagal stimulation. For example, Zalvan *et al.*<sup>4</sup> reported two adult cases of voice change after vagal nerve stimulation. During videoendoscopy, both patients' left vocal folds were noted to move to the midline and become immobile during vagal nerve stimulation. Interestingly, the immobility persisted for a brief period (5–7 s) after stimulation ceased. Similarly, Lundy *et al.*<sup>5</sup> demonstrated movement of the vocal folds to the midline during vagal nerve stimulation at 40 Hz. Interestingly, these investigators found that the direction of vocal fold movement was dependent on the frequency of stimulation. At a frequency of only 20 Hz, vagal nerve stimulation produced abduction of the vocal fold. Rate-related differences in movement of the vocal folds are presumably related to differences in which pharyngeal muscles are being stimulated at a given frequency.

The current patient did not volunteer any complaints of airway problems related to her VNS, nor was she

observed to have any voice alterations during the preoperative evaluation. After the fact, we contacted her attending neurologist, who confirmed that she has not had any airway-related problems (the new HIPPA law made direct contact with the patient to ask about airway problems inadvisable). Therefore, the patient seems to be a member of the large minority who do not experience noticeable airway side effects during VNS firing. Given the apparent absence of airway symptoms while awake, it is curious that she had such marked airway narrowing during anesthesia. It may be that while awake, she is able to subconsciously compensate for the effects of the VNS. Alternatively, it may be that general anesthesia unmasked the effect of the VNS on her airway. Regardless of the reason, her absence of airway symptoms suggests that this is not a guarantee that patients without noticeable airway problems while awake will not develop airway obstruction while anesthetized.

In summary, the VNS produces abnormal motion of the vocal folds during stimulation in many patients. In the current case, this abnormal motion was responsible for intermittent episodes of partial airway obstruction during general anesthesia with an LMA. When anesthetizing patients with a VNS, it may be prudent to consider turning the VNS off during anesthesia if an LMA is to be used. In addition, in those patients with a VNS in whom an endotracheal tube is indicated, one should consider the possibility of vocal fold trauma if the VNS intermittently adducts the vocal fold against the hard endotracheal tube. In these patients, it would also seem prudent to consider turning the VNS off during the duration of anesthesia.

## References

1. Murphy JV: Left vagal nerve stimulation in children with medically refractory epilepsy. The Pediatric VNS Study Group. *J Pediatr* 1999; 134:563–6
2. DeGiorgio CM, Schachter SC, Handforth A, Salinsky M, Thompson J, Uthman B, Reed R, Collins S, Tecoma E, Morris GL, Vaughn B, Naritoku DK, Henry T, Labar D, Gilmartin R, Labiner D, Osorio I, Ristanovic R, Jones J, Murphy J, Ney G, Wheless J, Lewis P, Heck C: Prospective long-term study of vagus nerve stimulation for the treatment of refractory seizures. *Epilepsia* 2000; 41:1195–200
3. Ramsay RE, Uthman BM, Augustinsson LE, Upton AR, Naritoku D, Willis J, Treig T, Barolat G, Wernicke JF: Vagus nerve stimulation for treatment of partial seizures: II. Safety, side effects, and tolerability. First International Vagus Nerve Stimulation Study Group. *Epilepsia* 1994; 35:627–36
4. Zalvan C, Sulica L, Wolf S, Cohen J, Gonzalez-Yanes O, Blitzer A: Laryngopharyngeal dysfunction from the implant vagal nerve stimulator. *Laryngoscope* 2003; 113:221–5
5. Lundy DS, Casiano RR, Landy HJ, Gallo J, Gallo B, Ramsey RE: Effects of vagal nerve stimulation on laryngeal function. *J Voice* 1993; 7:359–64

## Unilateral Diagnostic Infiltration of Lumbar L3 Nerve Root Resulting in an Inadvertent Discogram: The Importance of Fluoroscopic Guidance in Interventional Pain Therapy

Sara Haspeslagh, M.D.,\* Jan Van Zundert, M.D.,\* Martine Puylaert, M.D.,† Rene Heylen, M.D.,†  
Maarten van Kleef, M.D., Ph.D.,‡ Kris Vissers, M.D.†

SELECTIVE spinal injection procedures have become an integral part of the interdisciplinary treatment of patients with lumbar disc disease. These procedures can be powerful therapeutic tools in controlling pain and allowing early protected mobilization. Injection of the epidural space, spinal nerves, facet joints, and intervertebral discs cannot be performed safely and reliably without radiographic assistance.

Epidural steroids have been used for many years to manage low back pain and sciatica but are still controversial.<sup>1-3</sup> The anesthesiologist is totally dependent on the epidural anatomy and resistance to spread medication around or up to the front of the dural sac. In patients with lumbar disc herniations and radiculopathy, the target site is the interface between the posterior annulus of the intervertebral disc and the ventral dural sac or root sleeve. The commonly used transforaminal injection technique, as described in several reports, improves the delivery of a high concentration of medication to the ventral epidural space.<sup>4-7</sup>

Here, we describe a case of a transforaminal sleeve infiltration of the L3 nerve root. After positioning the needle, 2 ml dye was injected, and a discogram was visualized. In a MEDLINE search, we found no previous publications describing this inadvertent event. Possible implications for the interpretation of this observation in daily practice are discussed.

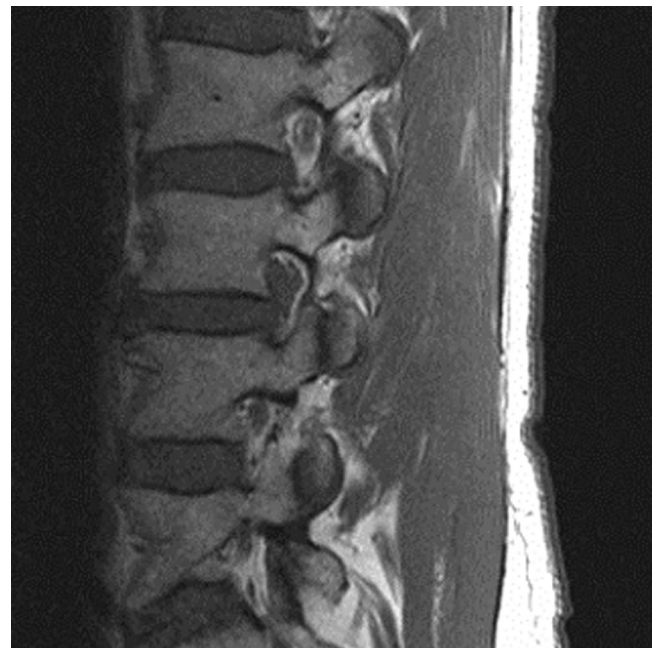### Case Report

A 50-yr-old man came to the pain clinic with subacute lumbar pain and radiation in the right leg by the L3 dermatome, with only a minor sensory deficit (paresthesia) and no motor deficits. A computed tomog-

\* Multidisciplinary Pain Center, Ziekenhuis Oost-Limburg, Campus A. Dumont, and Department of Anaesthesiology and Pain Management and Research Centre, University Hospital of Maastricht. † Multidisciplinary Pain Center, Ziekenhuis Oost-Limburg, Campus A. Dumont. ‡ Professor, Department of Anaesthesiology and Pain Management and Research Centre, University Hospital of Maastricht.

Received from the Multidisciplinary Pain Center, Ziekenhuis Oost-Limburg, Campus A. Dumont, Genk, Belgium, and the Department of Anaesthesiology and Pain Management and Research Centre, University Hospital of Maastricht, The Netherlands. Submitted for publication July 9, 2003. Accepted for publication November 19, 2003. Support was provided solely from institutional and/or departmental sources.

Address reprint requests to Dr. Vissers: Multidisciplinary Pain Center, Ziekenhuis Oost-Limburg, Campus André Dumont, Stalenstraat 2, B-3600 Genk, Belgium. Address electronic mail to: kris.vissers@skynet.be. Individual article reprints may be purchased through the Journal Web site, www.anesthesiology.org.

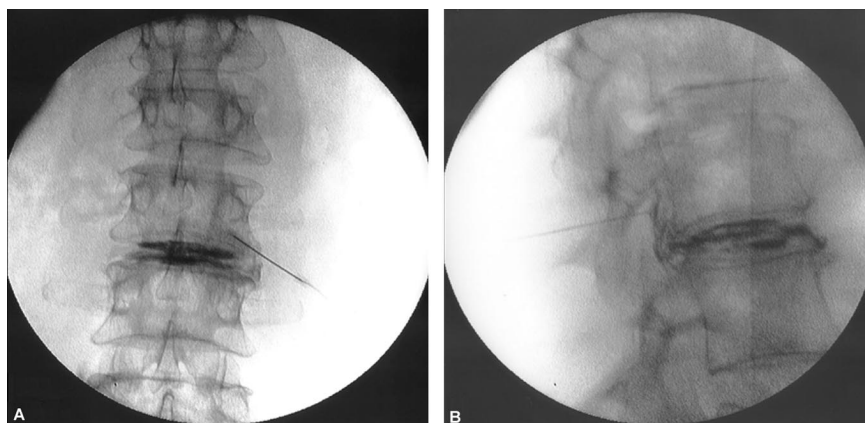


**Fig. 1.** Lateral magnetic resonance image showing the right-sided upward intraforaminal disc herniation at the L3-L4 level with compression on the L3 nerve root.

raphy scan of the lumbar spine showed a right lateral disc herniation of the L3-L4 intervertebral disc, with compression on the L3 nerve root and probably also on the right L4 nerve root. A lateral magnetic resonance image (fig. 1) also showed the right-sided, upward intraforaminal disc herniation at the L3-L4 level, with compression on the L3 nerve root and dehydration of the L2-L3 and L3-L4 intervertebral discs.

After a neurologic examination, the neurosurgeon initiated conventional pharmacologic treatment with intramuscular nonsteroidal anti-inflammatory drugs and a combination of paracetamol and a weak opioid (tramadol hydrochloride). Because of lack of efficacy, the patient was referred to the pain clinic for a transforaminal sleeve infiltration of the L3 nerve root with steroids as an initial, nonoperative treatment. After informed consent, this infiltration was performed using a conventional technique under strict sterile conditions with an image intensifier. The skin was anesthetized with 3 ml lidocaine, 2%. A 22-gauge needle (RCN-10 needle, 100 mm) was advanced obliquely toward the base of the corresponding pedicle of the L3 vertebra. The position of the needle was verified in a lateral view, where the ideal placement of the needle is with the tip in the cephaloventral corner of the neuroforamen.

Immediately after 0.5 ml dye (180 mg iodine per ml iohexol, Omnipaque<sup>®</sup>; Nycomed Ltd., Cork, Ireland) was injected, an intervertebral L3-L4 discogram was observed (fig. 2A), although the nerve root of L3 was our target. The injection was not painful and did not cause referring sensations. In the lateral view, dye was visible descending



**Fig. 2.** (A) Anteroposterior radioscopic view of the lumbar spine with the patient in the prone position. The x-ray module is positioned in a posterior-anterior position. Needle position under the L3 pedicle is visualized; 0.5 ml dye (180 mg iodine per ml iohexol, Omnipaque®) is injected through the needle, resulting in a clear discogram of the L3-L4 intervertebral disc (the right side of the figure is the right side of the patient). (B) Lateral radioscopic view with the patient in the prone position, showing descending dye from the tip of the needle in the neuroforamen to the intervertebral disc, beside the discogram.

from the tip of the needle in the neuroforamen to the intervertebral disc (fig. 2B).

The needle was withdrawn 2 mm, and another 0.5 ml dye was injected, resulting in a normal spread of the contrast medium in the neuroforamen as a sleeve nerve root infiltration. One milliliter bupivacaine, 0.5%, and 40 mg methylprednisolone acetate were injected. Thirty minutes after this injection, the patient's radicular pain was relieved, and he was sent home. Two weeks and 2 months later, the patient's condition was reevaluated. The radicular pain symptoms were resolved, making surgery unnecessary.

## Discussion

Correct positioning of the needle for a targeted sleeve infiltration is only reliable after radiologic control in at least two planes and the use of dye on the targeted nerve root. The transforaminal technique for epidural infiltration was suggested because of the better spread of the injected fluid to the irritated nerve root and to the ventral epidural space.<sup>4-7</sup> Complications of this technique and of the infiltration of local anesthetics and corticosteroids are rare but must not be overlooked. Complications may be attributed to poor or incorrect patient selection, drug-related reactions, and technique. There is also the risk of lasting paraplegia by injection of the artery of Adamkiewicz, so creating vascular ischemia of the spinal cord.<sup>8</sup>

Recently, in disc herniations, the involvement of an important inflammatory reaction coming from the intervertebral disc and nucleus pulposus has gained attention.<sup>9</sup> More specifically, the importance of phospholipase A2 was shown in the generation of symptoms resembling low back pain and sciatica.<sup>10</sup> Because most of the inflammatory reactions in the epidural space are found nearby the intervertebral disc and thus in the anterior plane of the epidural space, a more targeted infiltration of this corticosteroid is advocated. These sleeve infiltrations are becoming more commonly practiced for the treatment of (sub)acute lumbosciatica. For correct positioning of the needle, the use of x-ray facilities is indispensable. Here, we describe a case with an inadvertent easy injection of the intervertebral disc, resulting in a discogram that could be classified as irregu-

lar.<sup>11</sup> The unexpected spread of the contrast dye could be due to several reasons. First, because the magnetic resonance protocol described a right-sided, upward intraforaminal disc herniation at the L3-L4 level with compression on the L3 nerve root, a direct injection in this disc herniation could be supposed. Second, the leakage of inflammatory mediators through an annulus fibrosus tear can cause severe epidural fibrosis. The placement of the needle in this fibrosis at a distance of the disc can, through fibrotic canals, give a connection with the leaking disc. Third, a true delineated anatomic connection between a nerve root and the disc are not described but could be present because both structures are of mesodermal origin.

If the above-mentioned connections are possible, even then, easy injection of contrast dye without reports of pain or other sensations from the patient is not explained. A vacuum phenomenon of the intervertebral disc is described in cadavers and in degenerated discs.<sup>12</sup> A patient who is placed in a prone position with a pillow under his or her pelvis has an important passive lumbar spinal extension, and this can create a decrease in intervertebral disc pressure, therefore causing negative pressure in the intervertebral disc, which probably results in a suction force toward the disc. The infiltration of only 0.5 ml contrast dye allowed visualization of a whole disc. Discography is a reliable method of evaluating the integrity of the intervertebral disc. The normal annulus fibrosus offers fair resistance to distension, and the normal disc accepts only 1-1.5 ml contrast medium. Injection in the degenerated disc is often done without difficulty. The easy injection of 2 ml or more contrast medium into a disc is a sign of some degree of degeneration within the annulus fibrosus and the nucleus pulposus. Extravasation of contrast medium occurs through fissures and tears of the annulus and may be seen with both degeneration and herniation.

We do not support the infiltration of corticosteroids into the disc because of the lack of evidence of good outcome of this technique and because of the risk of complications.

Moreover, the target for application of corticosteroids

and local anesthetics here was the nerve root adjacent to the intervertebral disc. If we had injected our local anesthetics in this case without contrast dye control, a misinterpretation of this infiltration would have been possible. We believe that this observation is important for correct clinical practice.

### Conclusion

Meticulous care should be taken when a transforaminal sleeve injection of steroids, local anesthetics, or both is performed. All previous publications describe the leakage of contrast medium out of the disc by execution of a lumbar discography. There were no publications describing this event, the leakage of dye into the disc while injecting it into the neuroforamen.

This observation emphasizes the importance of the use of contrast dye and radiographic evaluation while performing a transforaminal sleeve injection to avoid inadvertent infiltrations of structures other than the target structure.

Anesthesiology 2004; 100:1021-3

### References

1. Koes BW, Scholten RJPM, Mens JMA, Bouter LM: Epidural steroid injections for low back pain and sciatica: An updated systematic review of randomized clinical trials. *Pain Digest* 1999; 9:241-7
2. Weinstein S, Herring S, Derby R: Contemporary concepts in spine care: Epidural steroid injections. *Spine* 1995; 20:1842-6
3. Slipman CW, Chow DW: Therapeutic spinal corticosteroid injections for the management of radiculopathies. *Phys Med Rehabil Clin North Am* 2002; 13:697-711
4. Barnsley L: Steroid injections: Effect on pain of spinal origin. *Best Pract Res Clin Anaesthesiol* 2002; 16:579-96
5. Karppinen J: Periradicular infiltration for sciatica: A randomized controlled trial. *Spine* 2001; 26:1059-67
6. Vad VB, Bhat AL, Lutz GE, Cammisia F: Transforaminal epidural steroid injections in lumbosacral radiculopathy: A prospective randomized study. *Spine* 2002; 27:11-6
7. Bogduk N: Epidural steroids. *Spine* 1995; 20:845-8
8. Houten JK, Errico TJ: Paraplegia after lumbosacral nerve root block: Report of three cases. *Spine J* 2002; 2:70-5
9. Saal JS: The role of inflammation in lumbar pain. *Spine* 1995; 20:1821-7
10. Saal JS, Franson RC, Dobrow R, Saal JA, White AH, Goldthwaite N: High levels of inflammatory phospholipase A2 activity in lumbar disc herniations. *Spine* 1990; 15:674-8
11. Adams MA, Dolan P, Hutton WC: The stages of disc degeneration as revealed by discograms. *J Bone Joint Surg Br* 1986; 68:36-41
12. Larde D, Mathieu D, Frija J, Gaston A, Vasile N: Spinal vacuum phenomenon: CT diagnosis and significance. *J Comput Assist Tomogr* 1982; 6:671-6

© 2004 American Society of Anesthesiologists, Inc. Lippincott Williams & Wilkins, Inc.

## Development of Osteomyelitis after Direct Laryngoscopy

Aaron G. Tucke, D.D.S.,\* Robert J. Diecidue, D.M.D., M.D.†

ORAL and oropharyngeal complications of intubations have been cited as some of the most common causes of complaints against anesthesiologists. Reviews of closed claims analyses have shown that dental injury accounts for approximately one third of all incidents reported.<sup>1</sup> In one prospective study, 745 patients were evaluated before and after anesthesia and were found to have dental trauma 12.1% of the time and an overall oral injury incidence of 18%.<sup>2</sup> In a similar study of 404 patients, an incidence of oral trauma of 6.9% was found.<sup>3</sup> Clearly, the literature places emphasis on damage limited to teeth. Less common complications include mucosal tears, dental alveolar fractures, dislocation of the temporomandibular joint, and injury to the hypoglossal and lingual nerves.<sup>4-7</sup> Most often, mucosal tears are the result of trauma from the blade of the laryngoscope, the tip of the endotracheal tube, or the fiberoptic endoscope and heal without incident. Here, we report adverse sequelae to mucosal lacerations not yet found in the literature. In both cases, the patients developed osteomyelitis of the

mandible after laceration of the overlying oral mucosa after a traumatic intubation.

### Case Reports

#### Case 1

A 55-yr-old man presented with the chief complaint of pain and paresthesia to the right lower jaw. The patient reported that approximately 2 months before, he had undergone left thyroid lobectomy for treatment of papillary carcinoma of the thyroid under general anesthesia *via* endotracheal tube. Review of hospital records confirmed such a procedure, and administration of anesthesia was noted to be routine, with use of a No. 3 Macintosh blade for direct laryngoscopy. The trachea was intubated on the first attempt without difficulty, and no mucosal lacerations were reported at the time of intubation. Immediately subsequent to the procedure, the patient noted an ulceration of the right posterior medial aspect of the mandible. After 1 month of persistent ulceration and new-onset lip numbness, the patient sought treatment.

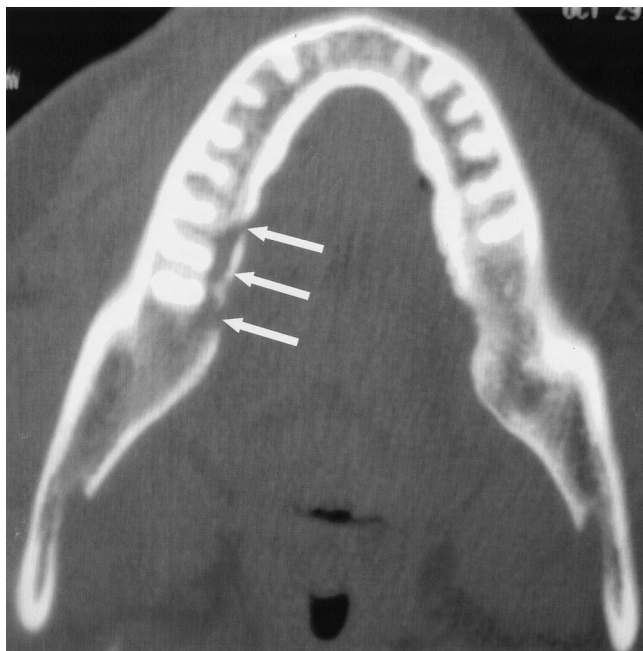
Intraoral examination revealed a 1 × 1-cm exposed bony sequestrum on the right posterior lingual cortex of the mandible, with ulceration of the overlying mucosa. There was also hypoesthesia to a small region on the patient's lower right lip. A computed tomography image was obtained and showed a linear lucency along the medial aspect of the body of the right mandible, with associated small defects in the lingual cortex at the level of the right second molar (fig. 1).

The patient underwent debridement and biopsy of the exposed bone in the operating room under general anesthesia. Results of the surgical pathology report revealed bone with marrow fibrosis and chronic inflammation consistent with osteomyelitis. Anaerobic and aerobic cultures of the soft tissue surrounding the lesion grew organisms commonly associated with osteomyelitis.

\* Resident, † Chairman.

Received from the Department of Oral and Maxillofacial Surgery, Thomas Jefferson University Hospital, Philadelphia, Pennsylvania. Submitted for publication August 18, 2003. Accepted for publication December 9, 2003. Support was provided solely from institutional and/or departmental sources.

Address reprint requests to Dr. Tucke: Department of Oral and Maxillofacial Surgery, Thomas Jefferson University Hospital, 130 South Ninth Street, 11th Floor Edison Building, Suite 1100, Philadelphia, Pennsylvania 19106. Address electronic mail to: atucke@yahoo.com. Individual article reprints may be purchased through the Journal Web site, www.anesthesiology.org.



**Fig. 1.** Axial view of a computed tomographic scan with contrast showing a linear lucency along the medial aspect of the body of the right mandible with associated defect in the lingual cortex and the level of the first and second molars.

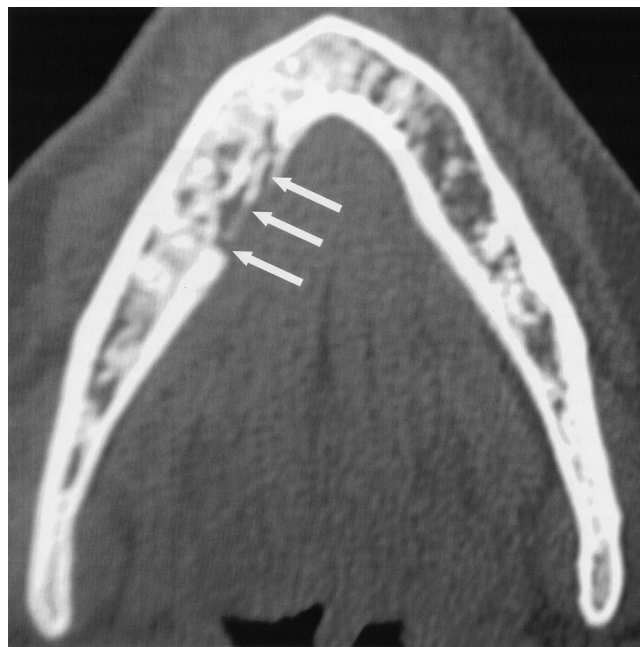
After review of antibiotic sensitivity reports and consultation with Infectious Disease, the course of therapy was decided to be 6 weeks of oral antibiotics. Although the patient's hypoesthesia progressively resolved and the mucosal ulceration completely healed, the patient noted persistent pain at the 6-week mark. Repeated cultures showed organisms associated with osteomyelitis; therefore, the patient continued oral antibiotics for a total of 6 months. The final follow-up after the 6-month course of therapy revealed a well-healed surgical site, normal lip sensation, and a pain-free patient.

#### Case 2

A similar case involved a 54-yr-old woman who, after a tracheal intubation for dilation and curettage, noticed an ulceration along the right mandible. Again, the anesthesia was noted to be uneventful, with intubation of the trachea on first attempt with a No. 3 Macintosh blade. No trauma to the oral mucosa was documented. On presentation to our office, a fluctuant swelling was noted on the mandibular right posterior lingual cortex on examination. The lower right second bicuspid had slight tenderness with pressure. The examination results were otherwise unremarkable. A computed tomography image was obtained and revealed erosion of the right mandibular body (fig. 2). The patient was taken to the operating room for biopsy, and results revealed osteomyelitis. Based on culture and sensitivity reports, a combination of long-term intravenous and oral antibiotics was deemed necessary. After 3 months of therapy, the mucosal laceration had healed, and the patient was pain-free. Repeat radiographs at the six-month follow-up appointment revealed a well-healing biopsy site with adequate bony fill.

#### Discussion

By strict definition, *osteomyelitis* is inflammation of the medullary portion of the bone, but it often progresses to involve the cortical bone and periosteum.<sup>8</sup>



**Fig. 2.** Axial view of a computed tomographic scan with contrast showing a lytic radiolucency along the medial aspect of the body of the right mandible with erosion of the lingual cortex in the region of the second bicuspid and first molar.

Most cases of osteomyelitis of the jaws in developed countries can be attributed to extension of a dentoalveolar infection or are in association with traumatic fractures of the jaws.<sup>9</sup> Predisposing factors, such as chronic systemic disease, immunocompromise, and disorders that lead to hypovascularity of bone, have been implicated. In addition, social history findings of tobacco use, alcohol, or intravenous drug abuse have been associated with an increased risk of developing osteomyelitis.<sup>8</sup>

Presentation is typically some combination of the usual signs of inflammation, including pain, swelling, trismus, erythema, and exudate. Fragments of nonviable bone called *sequestrum* may be present and protrude throughout the overlying mucosa. Radiographically, the bone may appear normal in early osteomyelitis or may present as an irregular radiolucent area after 4–6 months of progression of the infection.<sup>8,9</sup>

Diagnosis begins with clinical and radiologic findings. Adjunctive procedures include bone biopsies and cultures. Treatment varies depending on the extent of invasion and may range from intravenous or oral antibiotics alone to complete resection of the involved bone. Hyperbaric oxygen has been used in cases that are refractory to aggressive surgical and antibiotic intervention.<sup>8,9</sup> While cases of osteomyelitis usually resolve with treatment, the morbidity associated with the process is clear.

#### Summary

The majority of oral ulcerations from intubation may heal without incident; however, the potential to develop

a serious complication such as osteomyelitis does exist. Identification of risk factors, including irradiated bone or immunosuppression, should yield increased care during direct laryngoscopy. Further, if a mucosal tear is sustained, recommendation for follow-up with an oral and maxillofacial surgeon should be provided such that intervention may be initiated early, if required.

## References

1. Owen H, Waddell-Smith I: Dental trauma associated with anesthesia. *Anesth Intensive Care* 2000; 28:133-45

2. Chen JJ, Susetio L, Chao CC: Oral complications associated with endotracheal general anesthesia. *Anaesth Sin* 1990; 28:163-9
3. Fung BK, Chan MY: Incidence of oral tissue trauma after administration of general anesthesia. *Acta Anaesthesiol Sin* 2001; 39:163-7
4. Schwartz AS: Dislocation of the mandible: A case report. *AANA J* 2000; 68:507-13
5. Rastogi NK, Vakharia N, Hung OR: Perioperative anterior dislocation of the temporomandibular joint. *Anesth Analg* 1997; 84:924-6
6. Lang MS, Waite PD: Bilateral lingual nerve injury after laryngoscopy for intubation. *J Oral Maxillofac Surg* 2001; 59:1497-9
7. Loh KS, Irish JC: Traumatic complications of intubation and other airway management procedures. *Anesthesiol Clin North Am* 2002; 20:953-69
8. Neville BW, Damm DD, Allen CM, Bouquot JE: *Oral and Maxillofacial Pathology*, 2nd edition. Philadelphia, WB Saunders, 2001, pp 126-8
9. Marx RE, Stern D: *Oral and Maxillofacial Pathology: A Rationale for Treatment*. Chicago, Quintessence Publishing Company, 2002, pp 54-7

*Anesthesiology* 2004; 100:1023-5

© 2004 American Society of Anesthesiologists, Inc. Lippincott Williams & Wilkins, Inc.

# Rebound Pulmonary Hypertension and Cardiogenic Shock after Withdrawal of Inhaled Prostacyclin

John G. Augoustides, M.D.,\* Kym Culp, M.D.,† Steven Smith, B.S., R.R.T.‡

SEVERE pulmonary hypertension (PHTN) may cause right ventricular failure after heart surgery, significantly affecting mortality and morbidity.<sup>1,2</sup> Perioperative inhaled nitric oxide was a major clinical advance because it was the first purely selective pulmonary vasodilator that treated PHTN without systemic vasodilation.<sup>3,4</sup> Rebound PHTN is associated with withdrawal of nitric oxide; this may be due to its short duration of action.<sup>4,5</sup> Inhaled prostacyclin (iPGI<sub>2</sub>) has replaced nitric oxide at our institution after nitric oxide became too expensive after approval by the US Food and Drug Administration. There is no published report of rebound PHTN after withdrawal of iPGI<sub>2</sub>.<sup>6</sup> Because iPGI<sub>2</sub> has a duration of action similar to that of nitric oxide, it may also be associated with rebound PHTN. The following case report illustrates this possibility in the setting of severe PHTN after cardiac surgery.

## Case Report

A 74-yr-old man (height, 140 cm; weight, 52 kg) presented with congestive cardiac failure. The patient had undergone previous coronary artery bypass grafting in 1979 and 1999. His transthoracic echocardiogram revealed an ejection fraction of 35%, severe aortic stenosis (aortic valve area of 0.9 cm<sup>2</sup>), severe mitral regurgitation, significant

PHTN (estimated pulmonary artery systolic pressure 69 mmHg), moderate tricuspid regurgitation, and normal right ventricular function. Coronary catheterization revealed occluded saphenous venous grafts but a patent left internal mammary graft to the left anterior descending artery. There was no significant coronary stenosis amenable to surgical intervention.

The patient presented to the operating room for mitral and aortic valve replacement. Hemodynamic monitoring included arterial, central venous, and pulmonary artery catheterization. Aprotinin was administered without incident. The induction of anesthesia was with titrated intravenous midazolam and fentanyl. Tracheal intubation was uneventful. Anesthetic maintenance was with titrated midazolam, fentanyl, and isoflurane 0.5% in oxygen. Neuromuscular blockade was achieved with pancuronium. The hemodynamics before cardiopulmonary bypass were as follows: central venous pressure, 12-14 mmHg; pulmonary artery systolic/diastolic pressures, 44-55 mmHg/25-30 mmHg; systemic blood pressure, 110-140 mmHg/60-80 mmHg; heart rate, 80-100 beats/min; cardiac index, 1.8-2.0 l · min<sup>-1</sup> · m<sup>-2</sup>. Intraoperative transesophageal echocardiography was performed (Omniplane II probe, Sonos 5500; Philips Medical Systems, Amsterdam, The Netherlands). The preoperative findings were confirmed. The patient underwent uncomplicated bioprosthetic aortic and mitral valve replacement on cardiopulmonary bypass (myocardial ischemic time, 140 min; cardiopulmonary bypass time, 207 min).

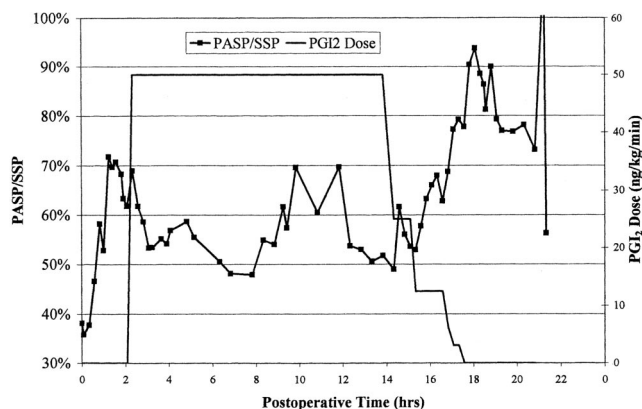
Separation from cardiopulmonary bypass was uneventful. The hemodynamics were as follows: central venous pressure, 14-18 mmHg; pulmonary artery systolic/diastolic pressures, 50-55 mmHg/30-35 mmHg; systemic blood pressure, 100-120 mmHg/50-60 mmHg; heart rate, 90-100 beats/min; cardiac index, 1.8-2.0 l · min<sup>-1</sup> · m<sup>-2</sup>. Intraoperative transesophageal echocardiography confirmed normal prosthetic valvular function, no change in the tricuspid regurgitation, moderate right ventricular dilation, and moderate biventricular dysfunction. Biventricular function was supported with infusions of epinephrine at 2 μg · kg<sup>-1</sup> · min<sup>-1</sup> and milrinone at 0.375 μg · kg<sup>-1</sup> · min<sup>-1</sup>. PHTN was managed with hyperventilation with 100% oxygen, titrated to arterial blood gas analysis. Despite aprotinin administration, there was significant coagulopathy after protamine reversal. This was corrected with transfusion of platelets and fresh frozen plasma. The patient was transferred to the intensive care unit while sedated on mechanical ventilation.

In the intensive care unit, the patient's admission hemodynamics were as follows: central venous pressure, 14 mmHg; pulmonary artery systolic/diastolic pressures, 58 mmHg/30 mmHg; systemic blood pres-

\* Assistant Professor of Anesthesia (Cardiothoracic Section), † Fellow in Cardiothoracic Anesthesia and Critical Care, Department of Anesthesia, ‡ Clinical Specialist, Respiratory Care Services, Hospital of the University of Pennsylvania.

Received from the Department of Anesthesia, Hospital of the University of Pennsylvania, Philadelphia, Pennsylvania. Submitted for publication September 10, 2003. Accepted for publication December 9, 2003. Supported by the Department of Anesthesia, Hospital of the University of Pennsylvania, Philadelphia, Pennsylvania. Presented at the Annual Meeting of the Society of Cardiovascular Anesthesiologists, Miami, Florida, April 30, 2003.

Address reprint requests to Dr. Augoustides: Department of Anesthesia, Hospital of the University of Pennsylvania, 3400 Spruce Street, Philadelphia, Pennsylvania 19104-4283. Address electronic mail to: viandoc@hotmail.com. Individual article reprints may be purchased through the Journal Web site, www.anesthesiology.org.



**Fig. 1. Relationship of pulmonary hypertension to withdrawal of inhaled prostacyclin.** PASP = pulmonary artery systolic pressure; PGI<sub>2</sub> = inhaled prostacyclin; SSP = systemic systolic pressure.

sure, 127 mmHg/66 mmHg; heart rate, 90–100 beats/min; cardiac index,  $2.1 \text{ l} \cdot \text{min}^{-1} \cdot \text{m}^{-2}$ . His PHTN increased despite sedation and hyperventilation with 100% oxygen (fig. 1) The right ventricular dysfunction was also progressive, as evidenced by a persistent increase in central venous pressure to 24–28 mmHg; cardiac index progressively decreased to below  $2.0 \text{ l} \cdot \text{min}^{-1} \cdot \text{m}^{-2}$ .

The milrinone infusion was increased to  $0.5 \mu\text{g} \cdot \text{kg}^{-1} \cdot \text{min}^{-1}$ , and iPGI<sub>2</sub> was commenced at  $50 \text{ ng} \cdot \text{kg}^{-1} \cdot \text{min}^{-1}$ . Sedation was maintained with an infusion of fentanyl at 200–300  $\mu\text{g}/\text{h}$ . These interventions decreased the PHTN by greater than 15%, expressed as systolic pulmonary arterial pressure/systemic systolic pressure. The PHTN was stabilized for 12 h in this fashion. Right ventricular function improved, as evidenced by a decrease in central venous pressure to 16–18 mmHg and a cardiac index of  $2.2\text{--}2.6 \text{ l} \cdot \text{min}^{-1} \cdot \text{m}^{-2}$ .

To facilitate tracheal extubation, a gradual withdrawal of the fentanyl infusion was begun. The iPGI<sub>2</sub> was then withdrawn in stages over 3 h while the patient was sedated with a fentanyl infusion at 50–75  $\mu\text{g}/\text{h}$ . Right ventricular function was maintained with a cardiac index above  $2.0 \text{ l} \cdot \text{min}^{-1} \cdot \text{m}^{-2}$  and a central venous pressure of 10–12 mmHg. The PHTN increased dramatically after cessation of iPGI<sub>2</sub>. This increase persisted, and the PHTN increased to parasystolic levels, beyond the 70% systemic level at which iPGI<sub>2</sub> was commenced. This rebound PHTN occurred despite unchanged mechanical ventilation and the absence of agitation.

Four hours later, the sedation was terminated to prepare for tracheal extubation. Despite significant PHTN, the patient was calm, with adequate hemodynamics. However, during a coughing spell, the PHTN deteriorated and became suprasystolic. Acute right ventricular failure ensued, with low pulmonary arterial pressure and a doubling of the central venous pressure from 10 to 20 mmHg; the patient became profoundly hypotensive. This cardiogenic shock responded to bolus epinephrine, sedation, and reinstitution of iPGI<sub>2</sub>. The hemodynamics rapidly recovered: central venous pressure, 13 mmHg; pulmonary artery systolic/diastolic pressures, 73 mmHg/24 mmHg; systemic blood pressure, 95 mmHg/50 mmHg; heart rate, 90–100 beats/min; cardiac index,  $2.0\text{--}2.2 \text{ l} \cdot \text{min}^{-1} \cdot \text{m}^{-2}$ . Transthoracic echocardiography at this time documented severe PHTN (estimated pulmonary artery systolic pressure, 78 mmHg), severe right ventricular dysfunction, and severe tricuspid regurgitation; these echocardiographic findings were all compatible with acute right heart failure associated with acute severe PHTN. The patient was ultimately successfully withdrawn from iPGI<sub>2</sub>. However, he later succumbed to sepsis, complicated by multisystem organ failure.

## Discussion

This case report details management of acute-on-chronic PHTN after mitral and aortic valve replacement. iPGI<sub>2</sub> allows direct administration to the pulmonary arterial bed for selective pulmonary vasodilation; its short half-life of 2.7 min and rapid hydrolysis in blood prevent systemic arterial effects.<sup>6</sup> The patient demonstrated an acute-on-chronic deterioration of PHTN that perhaps may stem in part from depletion of endogenous pulmonary endothelial nitric oxide due to cardiopulmonary bypass.<sup>6,7</sup> The lack of normal pulsatile pulmonary blood flow decreases nitric oxide production by constitutive nitric oxide synthase.<sup>4</sup> Coupled to this endogenous nitric oxide deficiency is a decrease in right ventricular reserve due in part to ischemia during aortic clamping and possible incomplete myocardial protection during cardiopulmonary bypass. Thus, the right ventricular failure is evident as afterload is increased while pump function is decreased.

This case also illustrates a tiered approach to management of PHTN.<sup>8</sup> Initial management of right ventricular failure includes hypocarbia, hyperoxia, inotropic support, and further afterload reduction with milrinone. Selective pulmonary vasodilation is indicated when these initial measures are inadequate. The addition of iPGI<sub>2</sub> in the intensive care unit facilitated adequate control of the PHTN.

During withdrawal of selective pulmonary vasodilation, right ventricular afterload was acutely increased. The right ventricle was unable to cope with any further increases in afterload. The rebound PHTN after iPGI<sub>2</sub> withdrawal was immediately apparent and is readily explained by the short half-life of iPGI<sub>2</sub>, as has been described for nitric oxide. This rebound PHTN predisposed the patient to cardiogenic shock, with further right ventricular challenge.

Although iPGI<sub>2</sub> offers significantly cheaper clinical equivalency compared with inhaled nitric oxide, it too has the clinical challenge of rebound PHTN on withdrawal in high-risk patients, as illustrated by this case report. Inhaled iloprost is a stable derivative of prostacyclin that can be administered intermittently because its effects last 1–2 h.<sup>9</sup> Inhaled iloprost has been used successfully in Europe for PHTN after cardiac surgery and may represent a solution for the rebound PHTN that we have observed with prostacyclin.<sup>10,11</sup> Because the effects of inhaled iloprost last up to 2 h, rebound PHTN may be less likely because acute loss of pulmonary vasodilation is unlikely. Rebound PHTN is a feature of inhaled pulmonary vasodilators with a half-life of minutes, previously described with nitric oxide and now also observed with iPGI<sub>2</sub>. Inhaled iloprost may allow gradual controlled withdrawal of perioperative inhaled selective pulmonary vasodilation.

Inhaled iloprost is not currently available in the United



States. Based on its favorable pharmacokinetics, it has great promise in the management of perioperative PHTN after cardiac surgery. It may represent another advance in perioperative inhaled pulmonary vasodilator therapy. Its place in perioperative management of PHTN and its integration with inhaled nitric oxide and  $i\text{PGL}_2$  will be elucidated with further investigation and clinical experience.

## References

1. Kaul TK, Fields BL: Postoperative acute right ventricular failure: Incidence, pathogenesis, management and prognosis. *Cardiovasc Surg* 200; 8:1-9
2. Zwissler B: Acute right heart failure: Etiology, pathophysiology, diagnosis, therapy. *Anaesthetist* 2000; 49:788-808
3. Girard C, Lehot JJ, Pannetier JC, Filley S, Ffrench P, Estanove S: Inhaled nitric oxide after mitral valve replacement in patients with chronic pulmonary hypertension. *ANESTHESIOLOGY* 1992; 77:880-3
4. Augoustides JG, Ochroch EA: Perioperative use of nitric oxide in cardiothoracic anesthesia and intensive care. *Progress in Anesthesiology*. Vol XV. Chapter 7. San Antonio, Texas, Dannemiller Foundation, 2001, pp 115-24
5. Miller O, Tang S, Keech A, Celermajer D: Rebound pulmonary hypertension on withdrawal from inhaled nitric oxide. *Lancet* 1995; 346:51-2
6. Lowson S: Inhaled alternatives to nitric oxide. *ANESTHESIOLOGY* 2002; 96:1504-13
7. Wessel DL, Adatia I, Giglia TM: Use of inhaled nitric oxide and acetylcholine in the evaluation of pulmonary hypertension and endothelial function after cardiopulmonary bypass. *Circulation* 1993; 88:2128-38
8. Augoustides JG, Mancini DJ: Postoperative care of the adult cardiac surgical patient. *Progress in Anesthesiology*. Vol XVI. Chapter 7. San Antonio, Texas, Dannemiller Foundation, 2002, pp 99-112
9. Hoepfer MM, Olschewski H, Ghofrani HA, Wilkens H, Winkler J, Borst MM, Niedermeier J, Fabel H, Seeger W: A comparison of the acute hemodynamic effects of inhaled nitric oxide and aerosolized iloprost in primary pulmonary hypertension. German PPH Study Group. *J Am Coll Cardiol* 2000; 35:176-82
10. Rex S, Busch T, Vettelschoss M, de Rossi L, Rossaint R, Buhre W: Intraoperative management of severe pulmonary hypertension during cardiac surgery with inhaled iloprost. *ANESTHESIOLOGY* 2003; 99:745-7
11. Muller M, Scolz S, Kwapisz M, Akinturk H, Thul J, Hempelmann G: Use of inhaled iloprost in a case of pulmonary hypertension during pediatric congenital heart surgery. *ANESTHESIOLOGY* 2003; 99:743-4