

Hemodynamic Compensation during Acute Normovolemic Hemodilution

To the Editor:—Acute normovolemic hemodilution (ANH) causes a reduction in arterial oxygen content because of reduced hemoglobin concentration. The primary compensatory mechanism during ANH is an increase in cardiac output to maintain systemic oxygen delivery.^{1,2} Therefore, the lower limit of an acceptable hemoglobin concentration is related to how low hemoglobin can be reduced without jeopardizing the ability of the heart to sustain an augmented pumping requirement. Previous studies have shown that the tolerance to ANH was diminished when the heart had a perfusion deficit, *e.g.*, critical coronary stenosis, or when it was pharmacologically depressed with either disopyramide or isoflurane.³⁻⁵ Not surprisingly, Van der Linden *et al.*⁶ demonstrated similar findings during pharmacologic depression by the anesthetics halothane and ketamine. The authors found that the critical hemoglobin concentration at low anesthetic doses was approximately 3 g/dl (a value consistent with that found by us in dogs anesthetized with “low doses” of either isoflurane or fentanyl-midazolam^{2,3}), whereas this value was increased to approximately 5 g/dl at high anesthetic doses. They explained their findings on a complete blunting of the compensatory increases in cardiac output during ANH and attribute this effect to an enhanced cardiodepressive action of the anesthetics at the high doses.

Although the current hemodynamic findings and previous pharmacologic studies^{7,8} are consistent with a more pronounced negative inotropic effect at the higher anesthetic doses, it is unlikely that this effect alone was responsible for the impaired cardiac output responses during ANH in the study of Van der Linden *et al.* In the case of halothane, the impact of a reduced arterial blood pressure, *i.e.*, coronary perfusion pressure, must also be considered; arterial blood pressure averaged only 43 ± 7 mmHg at the critical point during ANH (hemoglobin 4.5 ± 1.6 g/dl). Previous studies have suggested that this combination of arterial pressure and hemoglobin concentration results in a maldistribution of myocardial blood flow, *i.e.*, subendocardial hypoperfusion, leading to myocardial lactate production, ischemic changes in the electrocardiogram, and ultimately impairment in global cardiac function.^{2,3,9} A vulnerability of the subendocardium to hypoperfusion, secondary to reduced perfusion pressure, has been recognized for many years.¹⁰ This tendency is enhanced during ANH because vasodilation (as evidenced by blunted reactive hyperemic responses^{2,3}) reduces the autoregulatory capability of the coronary circulation.

The ketamine group in the study of Van der Linden *et al.* did not show a dose-related hypotensive effect during ANH; therefore, a lower

arterial pressure can be ruled out as contributing to the reduced tolerance to ANH under the higher dose of ketamine. However, this condition was accompanied by a paradoxical and unexplained reduction in heart rate, which limited the cardiac output responses. This mechanism was not acknowledged by the authors.

As a method of blood conservation, ANH has unique advantages relating to cost, simplicity, and practicality.¹¹ Although it is safe if performed properly by an experienced team, it is contraindicated in the presence of any coexisting disease that may jeopardize vital organ oxygen delivery. As underscored by the findings of Van der Linden *et al.*, ANH should not be performed if the anticipated hemodynamic compensatory mechanisms are neither possible nor desirable.

George J. Crystal, Ph.D.,* M. Ramez Salem, M.D. * Advocate Illinois Masonic Medical Center, Chicago, Illinois. gcrystal@uic.edu

References

- Crystal GJ, Rooney MW, Salem MR: Regional hemodynamics and oxygen supply during isovolemic hemodilution alone and in combination with adenosine-induced controlled hypotension. *Anesth Analg* 1988; 67:211-8
- Crystal GJ, Kim SJ, Salem MR: Right and left ventricular O₂ uptake during hemodilution and β -adrenergic stimulation. *Am J Physiol* 1993; 265(Heart Circ Physiol 34):H1769-77
- Levy PS, Kim SJ, Eckel PK, Chavez R, Ismail EF, Gould SA, Salem MR, Crystal GJ: Limit to cardiac compensation during acute isovolemic hemodilution: Influence of coronary stenosis. *Am J Physiol* 1993; 265(Heart Circ Physiol 34):H340-9
- Estafanous FG, Smith CE, Selim WM, Tarazi RC: Cardiovascular effects of acute normovolemic hemodilution in rats with disopyramide-induced myocardial depression. *Basic Res Cardiol* 1990; 85:227-36
- Schou H, Perez de Sa V, Larsson A, Roscher R, Kongstad L, Werner O: Hemodilution significantly decreases tolerance to isoflurane-induced cardiovascular depression. *Acta Anaesthesiol Scand* 1997; 41:218-28
- Van der Linden P, De Hert S, Mathieu N, Degroote F, Schmartz D, Zhang H, Vincent J-L: Tolerance to acute isovolemic hemodilution: Effect of anesthetic depth. *ANESTHESIOLOGY* 2003; 99:97-104
- Housmans PR: Negative inotropy of halogenated anesthetics in ferret ventricular myocardium. *Am J Physiol* 1990; 259(pt 2):H827-34
- Kongsayreong S, Cook DJ, Housmans PR: Mechanism of the direct, negative inotropic effect of ketamine in isolated ferret and frog ventricular myocardium. *ANESTHESIOLOGY* 1993; 79:313-22
- Brazier JN, Cooper N, Maloney JV, Buckberg: The adequacy of myocardial oxygen delivery during acute normovolemic anemia. *Surgery* 1974; 75:508-16
- Hoffman JIE, Spann JAE: Pressure-flow relations in the coronary circulation. *Physiol Rev* 1990; 20:331-89
- Crystal GJ, Salem MR: Acute normovolemic hemodilution. *Curr Rev Clin Anesth* 2002; 22:25-36

(Accepted for publication October 30, 2003.)

In Reply:—We thank Drs. Crystal and Ramez Salem for their interesting comments regarding our article.¹ This experimental study tested the hypothesis that the cardiodepressive effects of some anesthetic agents may exceed their effects on tissue oxygen demand, so that deepening the level of anesthesia may actually reduce tolerance to acute isovolemic anemia, as reflected by an increase in the critical hemoglobin concentration (*i.e.*, the value of hemoglobin below which oxygen consumption becomes supply dependent).

We agree with Drs. Crystal and Ramez Salem that the impaired cardiac output response observed during isovolemic hemodilution in

our experiments was not exclusively related to the more pronounced negative inotropic effect of the higher anesthetic dose. In the halothane study, we discussed the possible contribution of the depressant effect of halothane on the sympathetic system. Several authors emphasized the role the sympathetic system in the physiologic response to acute isovolemic anemia.^{2,3} The impact of reduced arterial blood pressure must also be considered. However, we think that the lower mean arterial pressure in the higher-dose halothane group was essentially related to the lower cardiac output because systemic vascular resistances were similar in the two halothane groups. Halothane is

known to have only minimal effects on vascular tone and, in particular, on coronary vascular tone.⁴ In addition, systemic vascular resistance decreased during acute isovolemic hemodilution, and the maintenance of arterial pressure in these conditions depends mainly on the increase in cardiac output.^{5,6}

In both the halothane and the ketamine studies, heart rate at critical point was lower in the higher-dose anesthetic group. Although these results might have been expected with halothane, they are more astonishing with ketamine. Other authors⁷ have observed a surprisingly low heart rate response in a dog model of hemorrhage. The mechanisms responsible for the effects of ketamine on the circulatory system are not completely understood because of its complexity and the lack of systematic investigation in this area. A better understanding of the effects of ketamine on the physiologic response to isovolemic hemodilution requires further investigation.

In contrast to Dr. Crystal and Ramez Salem, we think the maintenance of tissue oxygenation during acute isovolemic anemia depends on both an increase in cardiac output and an increase in tissue oxygen extraction. Several studies have shown that both mechanisms are already involved in the early stages of normovolemic hemodilution.⁸ Similar observations have been reported in a recent article evaluating the effects of β -adrenergic stimulation in fentanyl-isoflurane-anesthetized dogs undergoing severe normovolemic hemodilution.⁹ This interesting article showed that isoproterenol significantly increases the cardiac output response to hemodilution in the anesthetized animals. These observations may indicate that, during anesthesia, sympathetic stimulation may improve the tolerance of individuals to acute isovolemic anemia.

Philippe Van der Linden, M.D., Ph.D.,* Stefan De Hert, M.D., Ph.D. * CHU Brugmann-HUDERF, Brussels, Belgium.
philippe.vanderlinden@chu-brugmann.be

References

1. Van der Linden P, De Hert S, Mathieu N, Degroote F, Schmartz D, Zhang H, Vincent J-L: Tolerance to acute isovolemic hemodilution: Effects of anesthetic depth. *ANESTHESIOLOGY* 2003; 99:97-104
2. Glick G, Plauth WH Jr, Brauwald E: Role of the autonomic nervous system in the circulatory response to acutely induced anemia in unanesthetized dogs. *J Clin Invest* 1964; 43:2112-24
3. Clarke TNS, Foëx P, Roberts JG, Saner CA, Bennett MJ: Circulatory responses of the dog to acute isovolumic anaemia in the presence of high-grade beta-receptor blockade. *Br J Anaesth* 1980; 52:337-41
4. Hickey RF, Sybert PE, Verrier ED, Cason BA: Effects of halothane, enflurane, and isoflurane on coronary blood flow autoregulation and coronary vascular reserve in the canine heart. *ANESTHESIOLOGY* 1988; 68:21-30
5. Crystal GJ, Rooney MW, Ramez Salem M: Regional hemodynamics and oxygen supply during isovolemic hemodilution alone and in combination with adenosine-induced controlled hypotension. *Anesth Analg* 1988; 67:211-8
6. Crystal GJ, Ramez Salem M: Myocardial and systemic hemodynamics during isovolemic hemodilution alone and combined with nitroprusside-induced controlled hypotension. *Anesth Analg* 1991; 72:227-37
7. Weiskopf RB, Bogetz MS, Roizen MF, Reid IA: Cardiovascular and metabolic sequelae of inducing anesthesia with ketamine or thiopental in hypovolemic swine. *ANESTHESIOLOGY* 1984; 60:214-9
8. Spahn DR, Leone BJ, Reves JG, Pasch T: Cardiovascular and coronary physiology of acute isovolemic hemodilution: A review of nonoxygen-carrying and oxygen-carrying solutions. *Anesth Anal* 1994; 78:1000-21
9. Crystal GJ, Ramez Salem M: β -Adrenergic stimulation restores oxygen extraction reserve during acute normovolemic hemodilution. *Anesth Analg* 2002; 95:851-7

(Accepted for publication October 30, 2003.)

Anesthesiology 2004; 100:1035-6

© 2004 American Society of Anesthesiologists, Inc. Lippincott Williams & Wilkins, Inc.

Succinylcholine and the Open Globe: Questions Unanswered

To the Editor:—I enjoyed reading the Special Article in the July 2003 issue of *ANESTHESIOLOGY*, "Succinylcholine and the Open Globe," by Vachon *et al.*¹ My concern is with their comment, "To follow the dictum 'primum non nocere,' we thus avoid succinylcholine."

Their review is thorough, starting with the 1952 introduction of succinylcholine. They mention the anecdotal comments by ophthalmologists, relating loss of vitreous after succinylcholine, reminding us that there are no actual case reports of this problem. The authors mention the Libonati retrospective study, in which they reviewed 73 open globe surgeries, all induced using succinylcholine, and there were no incidents of vitreous extrusion. Libonati *et al.*² then extrapolated this to 10 yr at Wills Eye Hospital (Philadelphia, Pennsylvania), saying that there had been no vitreous loss in that time, with an average of 250 cases per year. The authors then remind us of the letter from Massachusetts Eye and Ear Infirmary in Boston, Massachusetts, where again, with a 10-yr history of using succinylcholine during open eye surgeries, they had no loss of vitreous.³

In general, I agree with Vachon *et al.*¹ that succinylcholine should be avoided in the induction of patients with open globes. However, at the Kresge Eye Institute in Detroit, Michigan, it is believed that there are situations in which succinylcholine should be used.

After institutional review board approval, I reviewed all open globe surgeries performed at my institution in a 24-month period. There were 59 cases. Of those, 1 was a planned fiberoptic intubation because of facial injuries; 8 received succinylcholine; and 5 were difficult intubations, requiring more than one attempt. In all 59 cases, comparing ophthalmologists' comments in the preoperative assessment and after induction, similar to the process used by Libonati *et al.*,² there were no increases in vitreous loss, no lens or uvea extrusion, and no excessive intraocular bleeding causing further extrusion.

I propose that two questions should be asked before the decision

about the use or the avoidance of succinylcholine in open globe surgeries:

1. Is this an easy airway? In that setting, regardless of the patient's aspiration risk and regardless of the viability of the eye, I believe that succinylcholine can be avoided and replaced with the currently available short- or intermediate-acting nondepolarizing muscle relaxants.
2. If the airway assessment, using whatever tools the anesthesiologist prefers, shows that this could be a difficult intubation, regardless of the patient's aspiration risk, a second question becomes important: *Is the eye viable?* In that setting, the anesthetic induction plan may need to be changed.

If, during the preoperative ophthalmologic examination, it is believed that the eye is not salvageable and if the surgery is to assess the damage and create a cosmetic closure, I prefer to use fiberoptic laryngoscopy. This, I realize, may increase intraocular pressure (gagging from local anesthetic spray, retching from local anesthetic nebulized breathing treatments, bucking from transtracheal injection, hypercarbia from sedation, and other problems), but this increase should be similar to that from blinking, crying, or rubbing the eye.

If the ophthalmologist believes that the eye is viable, I prefer using succinylcholine over any other modality. In this setting, the nondepolarizing drugs may have a prolonged effect, with increases in intraocular pressure from mask application, hypercapnia with multiple attempts, and a longer time with an unprotected airway. Awake fiberoptic laryngoscopy may cause the intraocular pressure problems mentioned above and is best avoided if the eye is viable. In this setting, when a decision is made that succinylcholine is the safest choice, I start with other drugs that attenuate the intraocular pressure effect of succi-

nylcholine, such as thiopental,⁴ propofol,⁵ narcotics,^{6,7} nifedipine,⁸ or lidocaine.⁹

In summary, this algorithm involves two questions: Is this an easy airway? Is the eye viable? It results in three decision limbs: If the airway is easy, the recommendation is to avoid succinylcholine. If the airway is difficult and the eye is not viable, the recommendation is fiberoptic laryngoscopy. If the airway is difficult and the eye is viable, the recommendation is to use succinylcholine. With this algorithm, as mentioned in the review, 8 patients (out of 59) received succinylcholine over a 2 year period, and none of the 59 patients had adverse outcomes.

In closing, I would like to compliment Vachon *et al.* on their review and on giving the issue a historical perspective. However, although I agree that *primum non nocere* is a good dictum, I am afraid that the fact that the Mayo Clinic avoids succinylcholine in open eye injuries may go against the process used at Wills Eye Hospital and Massachusetts Eye and Ear Infirmary. Granted, there are newer, shorter-acting nondepolarizing muscle relaxants that were not available to Libonati *et al.*² or to Donlon³ in the mid-1980s, but those drugs have yet to replace the fast-onset and short-duration profile of succinylcholine.¹⁰ Therefore, I believe that some situations may present themselves in which it is more harmful to avoid succinylcholine.

Elie Joseph Chidiac, M.D., Wayne State University School of Medicine, Kresge Eye Institute, Detroit, Michigan.
echidiac@med.wayne.edu

References

1. Vachon CA, Warner DO, Bacon DR: Succinylcholine and the open globe. *ANESTHESIOLOGY* 2003; 99:220-3
2. Libonati MM, Leahy JJ, Ellison N: The use of succinylcholine in open eye surgery. *ANESTHESIOLOGY* 1986; 64:517-9
3. Donlon JV: Succinylcholine and open eye injuries. *ANESTHESIOLOGY* 1986; 65:526-7
4. Mirakhor RK, Shepherd WF, Darrah WC: Propofol or thiopentone: effects on intraocular pressure associated with induction of anaesthesia and tracheal intubation (facilitated with suxamethonium). *Br J Anaesth* 1987; 59:431-6
5. Eti Z, Yayci A, Umuroglu T, Gogus FY, Bozkurt N: The effect of propofol and alfentanil on the increase in intraocular pressure due to succinylcholine and intubation. *Eur J Ophthalmol* 2000; 10:105-9
6. Zimmerman AA, Funk KJ, Tidwell JL: Propofol and alfentanil prevent the increase in intraocular pressure caused by succinylcholine and endotracheal intubation during a rapid sequence induction of anesthesia. *Anesth Analg* 1996; 83:814-7
7. Alexander R, Hill R, Lipham WJ, Weatherwax KJ, el-Moalem HE: Remifentanyl prevents an increase in intraocular pressure after succinylcholine and tracheal intubation. *Br J Anaesth* 1998; 61:606-7
8. Indu B, Batra YK, Puri GD, Singh H: Nifedipine attenuates the intraocular pressure response to intubation following succinylcholine. *Can J Anaesth* 1989; 36:269-72
9. Lerman J, Kiskis AA: Lidocaine attenuates the intraocular pressure response to rapid intubation in children. *Anaesth Soc J* 1985; 32:339-45
10. Cook DR: Can succinylcholine be abandoned? *Anesth Analg* 2000; 90: S24-8

(Accepted for publication November 24, 2003.)

Anesthesiology 2004; 100:1036

© 2004 American Society of Anesthesiologists, Inc. Lippincott Williams & Wilkins, Inc.

Role of Extraocular Pressure in Open Globe Injury

To the Editor:—We read with interest the article by Vachon *et al.*¹ entitled "Succinylcholine and the Open Globe," which was published in the July 2003 issue of *ANESTHESIOLOGY*. Although it is true that the risk of using succinylcholine in anesthesia for open globe injuries is still an open question, we would like to clear up a misconception in the article regarding why there might be such a risk. In their excellent article, Vachon *et al.* emphasized that succinylcholine has been shown to increase intraocular pressure. Although this is absolutely correct, it is irrelevant when it comes to injuries involving an open globe because, by definition, as soon as the globe is open, the intraocular pressure is zero. Because the globe is open, any medication that might be shown to increase the intraocular pressure in a closed globe will be unable to do so.

What is important in an open globe injury is the *extraocular* pressure. This is why it is critical that an open globe be handled with extreme dexterity and care by the surgeon, so as not to put any pressure on the tissues with the surgical instruments. Obviously, compressing an open globe from the outside leads to the possibility of extravasating the intraocular contents. This is why these cases are performed under general anesthesia, rather than injecting local anesthetic into the retrobulbar space. Cocontraction of the recti muscles could theoretically place pressure on the globe from the outside (*i.e.*, increase the extraocular pressure), leading to extrusion of the intraocular contents.

Therefore, the issue with succinylcholine is not that it increases the intraocular pressure but that it causes cocontraction of the four recti muscles, as was shown in electrophysiologic studies by Macri and Grimes² and clinically by Kornblueth *et al.*³ Vachon *et al.* correctly point out that although it has been clearly demonstrated that cocontraction of the recti muscles does occur in response to succinylcholine administration, it has not been clearly shown that this is of a magnitude

to produce extrusion of the intraocular contents in the clinical setting of an open globe injury.

Because the traditional teaching is that succinylcholine should be avoided in such cases but in practice many anesthesiologists use succinylcholine, only a prospective randomized clinical trial will settle the question. Assuming that an institutional review board would approve such a trial (and we think it would, given the fact that both the use of succinylcholine and the avoidance of succinylcholine are routinely practiced in such cases), we believe that such a study is feasible. There are many city and county hospitals that have well over 100 cases of open globe injuries per year, and therefore, such a study would be practical.

To reiterate, the main point we wish to convey is that if succinylcholine use in open globe injuries is dangerous, it is because of the cocontraction of the recti muscles increasing the extraocular pressure rather than any increase in intraocular pressure that may occur in studies performed with an intact globe.

James R. Brinkley, Jr., M.D.,* Andrew Henrick, M.D. * Doheny Eye Institute, University of Southern California, Keck School of Medicine, Los Angeles, California. drb@southcoasteye.com

References

1. Vachon CA, Warner DO, Bacon DR: Succinylcholine and the open globe. *ANESTHESIOLOGY* 2003; 99:220-3
2. Macri FJ, Grimes PA: The effects of succinylcholine on the extraocular striate muscles and on the intraocular pressure. *Am J Ophthalmol* 1957; 44: 221-30
3. Kornblueth W, Jampolsky A, Tamler E, Marg E: Contraction of the ocular muscles and intraocular pressure. *Am J Ophthalmol* 1960; 49:1381-7

(Accepted for publication November 24, 2003.)

Anesthesiology 2004; 100:1037

© 2004 American Society of Anesthesiologists, Inc. Lippincott Williams & Wilkins, Inc.

In Reply:—We would like to thank Drs. Chidiac, Brinkley, and Henrick for their thoughtful responses to our article.¹ The teaching about the use of succinylcholine for surgery to repair an open globe injury remains controversial. The major point of our article was to show that this teaching is based on anecdote rather than complete, well-documented case reports. Although scientific investigation supports the fact that succinylcholine causes contraction of the extraocular muscles, thus increasing intraocular pressure in the intact globe, no study to date has shown that these contractions are of a sufficient magnitude to cause extrusion of the vitreous. Drs. Brinkley and Henrick are quite correct in pointing out that when the globe is open, intraocular pressure is zero. We also agree that their proposed mechanism for the possible extrusion of vitreous is correct. Finally, these authors also agree that the magnitude of contraction has not been shown to cause the vitreous to be extruded. We agree with their call for a randomized, prospective, double-blind study and eagerly look forward to its publication.

Dr. Chidiac clearly misinterpreted our statement “To follow the dictum ‘*primum non nocere*,’ we thus avoid succinylcholine.” This sentence was meant to explain why anesthesiologists in general may

be reluctant to use succinylcholine for anesthetics involving open globe injury. In no way was this a declaration of policy at the Mayo Clinic. We (Drs. Vachon, Warner, and Bacon) agree with the intellectual framework Dr. Chidiac has proposed for the use of succinylcholine in open globe injuries, and all of us continue to use succinylcholine as an agent to facilitate rapid sequence induction in this setting. We intended the article to be a historic review of an interesting story and to stimulate discussion about how principles of evidence-based medicine might be applied to the evaluation of low-frequency events.

Claude Vachon, M.D., David O. Warner, M.D., Douglas R. Bacon, M.D., M.A.* * Mayo Clinic College of Medicine, Rochester, Minnesota. bacon.douglas@mayo.edu

Reference

1. Vachon CA, Warner DO, Bacon DR: Succinylcholine and the open globe. *ANESTHESIOLOGY* 2003; 99:220–3

(Accepted for publication November 24, 2003.)

Anesthesiology 2004; 100:1037

© 2004 American Society of Anesthesiologists, Inc. Lippincott Williams & Wilkins, Inc.

Electroencephalographic Monitoring Should Not Provide Risks of Intraoperative Memory Because of Aspired Faster Emergence and Reduction of Drug Consumptions

To the Editor:—Kreuer *et al.*¹ reported advantages of the new electroencephalographic system the Narcotrend monitor (MonitorTechnik, Bad Bramstedt, Germany) and the Bispectral Index from the BIS[®] monitor (Aspect Medical Systems, Inc., Newton, MA) to consider faster emergence from anesthesia and a reduction of propofol-remifentanyl consumption.

We want to congratulate Kreuer *et al.* for the interesting and detailed results about monitoring of anesthesia. They indicate the possibility of using the Narcotrend monitor as an alternative to the BIS[®] monitor in this issue. A recent study underlines the limitations of the Bispectral Index.²

Nevertheless, we think the study design should be debated. The propofol infusion was adjusted during the surgical procedure and maintenance of anesthesia to stages assumed as deeper Narcotrend stages (D₀), whereas anesthesia was reduced to lighter stages (C₁) 15 min before the end of surgery. In general, it should be questioned why the depth of anesthesia should be lightened at the end of surgery. Kreuer *et al.* reported that no patient had explicit intraoperative recall. The authors could not have known of the very recent results from Münte *et al.*³ with propofol-remifentanyl anesthesia that were published at the same time. They reported about increasing implicit memory function in the absence of explicit memory function during Narcotrend stages C₁ to D₂ compared with deeper stages.

In our opinion, electroencephalographic monitoring during anesthe-

sia is a useful tool to assess the drug effects, but electroencephalographic monitoring should not cause the risk of memory function resulting in potential awareness.⁴ Münte *et al.* demonstrated that even in the absence of explicit memories, implicit memory may occur during light anesthesia as used by Kreuer *et al.* Electroencephalographic monitoring should not become a risk for the patient because of aspired minimal depth of anesthesia to reduce the drug consumption.

Petra Bischoff, M.D.,* Thomas Standl, M.D., Gunter N. Schmidt, M.D. * University Hospital Hamburg-Eppendorf, Hamburg, Germany. bischoff@uke.uni-hamburg.de

References

1. Kreuer S, Biedler A, Larsen R, Altman S, Wilhelm W: Narcotrend monitoring allows faster emergence and a reduction of drug consumption in propofol-remifentanyl anesthesia. *ANESTHESIOLOGY* 2003; 99:34–41
2. Messner M, Beese U, Romstöck J, Dinkel M, Tschakowsky K: The Bispectral Index declines during neuromuscular block in fully awake persons. *Anesth Analg* 2003; 97:488–91
3. Münte S, Münte TF, Grotkamp J, Haeseler G, Raymonds K, Piepenbrock S, Kraus G: Implicit memory varies as a function of hypnotic electroencephalogram stage in surgical patients. *Anesth Analg* 2003; 97:132–8
4. Kalkman CJ, Drummond JC: Monitors of depth of anesthesia, quo vadis? *ANESTHESIOLOGY* 2002; 96:784–7

(Accepted for publication November 24, 2003.)

Anesthesiology 2004; 100:1037–8

© 2004 American Society of Anesthesiologists, Inc. Lippincott Williams & Wilkins, Inc.

In Reply:—We thank Dr. Bischoff *et al.* for their interest in our study on Narcotrend (MonitorTechnik, Bad Bramstedt, Germany) and Bispectral Index[®] (BIS[®]; Aspect Medical Systems Inc., Newton, MA) monitoring used for guidance of propofol titration during propofol-remifentanyl anesthesia.¹ The results of our study indicate that compared with

standard practice, patients with Narcotrend or BIS monitoring needed significantly less propofol, opened their eyes earlier, and were extubated sooner.

Bischoff *et al.* now discuss the possibility of an increased risk of memory function resulting in potential awareness if electroencephalo-

graphic monitoring is used to optimize recovery times and drug consumption. They do so especially in view of our study design, which included a lightening of anesthesia during the last 15 min before the end of surgery to a target value of C_1 for Narcotrend or 60 for BIS®.

Now, three questions must be discussed: First, should electroencephalographic monitoring in principle be used to fast track anesthesia; second, does monitoring of the depth of anesthesia result in an increased risk of awareness; and third, is it adequate to lighten anesthesia at the end of surgery?

First, electroencephalographic monitoring is a valuable tool to fast-track anesthesia. Several studies, including ours,¹⁻³ have shown that monitoring the depth of anesthesia clearly reduces the guesswork regarding how much of the anesthetic is necessary for the individual patient. Thus, this monitoring allows for individual titration of anesthesia, resulting in a reduction of drug consumption and recovery times.

Second, Myles *et al.*⁴ have now brought some light to the discussion about the impact of electroencephalographic monitoring on the risk of awareness. In their investigation, 1,227 patients were randomly assigned to a BIS-guided anesthetic protocol with BIS target values of 40–60, and 1,238 patients received “routine care,” with no electroencephalographic monitoring information available. With this study design, Myles *et al.* observed 2 cases of awareness in the BIS® group and 11 in the standard practice group ($P < 0.022$). Therefore, BIS-guided anesthesia reduced the risk of awareness by 82% and was also associated with a decreased time to eye opening.

Third, lightening of anesthesia at the end of surgery has been standard of care for many years without electroencephalographic monitoring. In particular, in our study, we used target values of 60 for BIS®

(being within the study range of Myles *et al.*) and C_1 for the Narcotrend. In a previous investigation, BIS values of 60 were matched to Narcotrend stages of C_1 ,⁵ and therefore, these results were used as target values for the guidance of propofol titration in our investigation.

In conclusion, we are convinced that it is possible to optimize recovery times, reduce drug consumption, and have a lower risk of awareness by using electroencephalographic monitoring during general anesthesia.

Wolfram Wilhelm, M.D., D.E.A.A.,* Sascha Kreuer, M.D.

* University of Saarland, Germany. wolfram.wilhelm@uniklinik-saarland.de

References

1. Kreuer S, Biedler A, Larsen R, Altman S, Wilhelm W: Narcotrend monitoring allows faster emergence and a reduction of drug consumption in propofol-remifentanyl anesthesia. *ANESTHESIOLOGY* 2003; 99:34–41
2. Gan TJ, Glass PS, Windsor A, Payne F, Rosow C, Sebel P, Manberg P: Bispectral Index monitoring allows faster emergence and improved recovery from propofol, alfentanil, and nitrous oxide anesthesia. *ANESTHESIOLOGY* 1997; 87:808–15
3. Song D, Joshi GP, White PF: Titration of volatile anesthetics using Bispectral Index facilitates recovery after ambulatory anesthesia. *ANESTHESIOLOGY* 1997; 87:842–8
4. Myles PS, Leslie K, Forbes A, Chan M, McNeil J: A large randomized trial of BIS monitoring to prevent awareness in high risk patients: The B-Aware Trial (abstract). *ANESTHESIOLOGY* 2003; 99:A320.
5. Kreuer S, Biedler A, Larsen R, Schoth S, Altmann S, Wilhelm W: The Narcotrend: A new EEG monitor designed to measure the depth of anaesthesia. A comparison with Bispectral Index monitoring during propofol-remifentanyl-anaesthesia. *Anaesthesist* 2001; 50:921–5

(Accepted for publication November 24, 2003.)

Anesthesiology 2004; 100:1038–9

© 2004 American Society of Anesthesiologists, Inc. Lippincott Williams & Wilkins, Inc.

Sevoflurane or Desflurane Anesthesia plus Postoperative Propofol Sedation Attenuates Myocardial Injury after Coronary Surgery in Elderly High-risk Patients

To the Editor:—We read with interest the article recently published by Dr. De Hert *et al.*,¹ “Effects of Propofol, Desflurane, and Sevoflurane on Recovery of Myocardial Function after Coronary Surgery in Elderly High-risk Patients.” In this study, the authors observed that sevoflurane or desflurane anesthesia in combination with continuous intravenous propofol sedation for 4 h postoperatively better preserved cardiac mechanics than using propofol alone for anesthesia and postoperative sedation in elderly high-risk patients. These approaches were also associated with significantly reduced plasma concentrations of cardiac troponin I, a sensitive marker for myocardial cellular damage. This is very interesting. This anesthetic “cocktail,” especially when further modified, may prove to be a promising approach. Unexpectedly, however, the authors have not appreciated the potential contribution propofol may have made to the manifested additional cardiac protection seen in the sevoflurane and the desflurane groups in their study.

Postischemic reperfusion can result in further damage to the myocardium through an acute inflammatory response mediated by cytokines, neutrophils, macrophages, and reactive oxygen species. These events can trigger cardiomyocyte death through either necrosis or apoptosis. Recent study has shown that apoptosis of coronary endothelial cells, which peaked at 1 h of reperfusion, precedes cardiac myocyte apoptosis in ischemia-reperfusion injury.² Apoptosis

spreads radially to the surrounding cardiac myocytes. After 2 h of reperfusion, apoptotic cardiac myocytes assumed a more homogeneous distribution around the vessels.² This suggests that reperfusion induces the release of soluble proapoptotic mediators from endothelial cells that promote myocyte apoptosis.² Our recent study shows that propofol can significantly reduce tumor necrosis factor (TNF) α -induced human endothelial cells apoptosis when applied at a clinically relevant low concentration of 12.5 μM (approximately 2 $\mu\text{g}/\text{ml}$), although most significant effect is manifested at a propofol concentration of 50 μM or greater.* Propofol’s inhibition of TNF- α -induced human endothelial cell apoptosis is attributable, at least in part, to its antioxidant property. This is because the low concentration of hydrogen peroxide significantly enhanced TNF- α -induced human endothelial cell apoptosis, while propofol prevented this synergistic effect between hydrogen peroxide and TNF- α and significantly attenuated hydrogen peroxide and TNF- α -induced human endothelial cell apoptosis (unpublished data, Luo and Xia *et al.*, Wuhan, Hubei Province, China, October 2003, Propofol Dose-dependently Reduces TNF- α Induced Human Umbilical Vein Endothelial Cell Apoptosis: Effects on bcl-2 and bax Expression And Nitric Oxide Generation).

It is well known that endogenous antioxidant capacity decreases with aging. Interestingly, propofol, when applied at a clinically achievable high dose primarily during ischemia and the early phase of reperfusion followed by a relatively low dose during reperfusion, seems able to provide better cardiac protection against ischemia injury in hearts from middle-aged rats than from young rats.³ Taken together, we suggest that the potential of propofol in reducing cytokines and reac-

* Xia Z, Godin DV, Ansley DM: Propofol reduces TNF-alpha induced human umbilical vein endothelial cell apoptosis (abstract). Available at: www.asa-abstracts.com. Go to Abstract Archive, 2003 Meeting Abstracts, p 737. Accessed November 10, 2003.

tive oxygen species-induced (coronary) endothelial cell and myocyte injury during reperfusion should have contributed, in part, to the attenuated myocardial cellular damage seen in the sevoflurane and the desflurane groups in the study of De Hert *et al.*¹

It should be noted that postoperative recovery was relatively eventful in the desflurane group as compared with the sevoflurane group in the study of De Hert *et al.*¹ This is likely because desflurane anesthesia could significantly enhance both local and systemic oxidative stress.⁴ Although a small amount reactive oxygen species produced by volatile anesthetics (including desflurane) before ischemia may serve to trigger anesthetic preconditioning,⁵ a significant amount of reactive oxygen species that could be produced by desflurane during ischemia and reperfusion is obviously detrimental. Therefore, it is reasonable for us to speculate that postoperative recovery in the desflurane group could have been otherwise more eventful if propofol were not supplemented as a sedative during the first several hours after reperfusion.

Zhengyuan Xia, M.D.,* Tao Luo, M.D. *Renmin Hospital of Wuhan University, Wuhan, China, and University of British Columbia, Vancouver, British Columbia, Canada. zhengyuan_xia@yahoo.com

Anesthesiology 2004; 100:1039–40

In Reply:—We read with interest the letter of Drs. Xia and Luo regarding our recent article on the cardioprotective effects of volatile anesthetic agents in elderly high-risk coronary artery patients.¹ The authors propose an interesting hypothesis, which is that the use of propofol as sedation in the postoperative period on the intensive care unit may have added to the cardioprotective effects observed with sevoflurane and desflurane. Postischemic reperfusion is associated with an acute inflammatory response, involving a number of mediators, which ultimately may trigger cardiomyocyte death within the first hours after reperfusion. Drs. Xia and Luo propose that the potential of propofol in reducing cytokines and reactive oxygen species induced myocardial injury during reperfusion is responsible for the additional cardioprotective effect. It should be noted, however, that in our study, propofol administration was only started after arrival in the intensive care unit. This implies that in the sevoflurane and desflurane groups, during the first period of reperfusion (from the opening of the proximal anastomoses until the end of the operation), anesthesia was still obtained with the volatile anesthetic. If the beneficial effects of propofol during the first 2 h of reperfusion are assumed to be of major importance in the cardioprotective effects observed in the sevoflurane and desflurane groups, one would expect this effect also to be present in the propofol group, which was not the case in our study protocol.

Different research groups have demonstrated that propofol has antioxidant activity and may even inhibit tumor necrosis factor α -induced human (umbilical vein) endothelial cell apoptosis,² but the clinical relevance of these properties for myocardial protection remains to be established. Until now, all data published on the cardioprotective effects of propofol were obtained at higher concentrations than those used in clinical practice. For example, the cardioprotective effects observed by Ko *et al.*³ were obtained at propofol concentrations of 100 μM . Similarly, in the study of Xia *et al.*⁴ in isolated rat hearts, the enhanced ischemic tolerance of middle-aged rats was observed with a propofol perfusion at 12 $\mu\text{g}/\text{ml}$ during the first 15 min of reperfusion, which was subsequently reduced to 5 $\mu\text{g}/\text{ml}$. Ebel *et al.*,⁵ on the contrary, found no effect of propofol on reperfusion injury when it was administered at concentrations of 1 $\mu\text{g}/\text{ml}$.

The pathophysiology of myocardial reperfusion injury is extremely complex, with several pathways involved, ultimately resulting in myocardial dysfunction. As such, it is conceivable that different therapeutic interventions may act at different levels and have an additive cardioprotective effect. In addition to their pharmacologic preconditioning effect, volatile anesthetics also seem to have cardioprotective effects

References

1. De Hert SG, Cromheecke S, ten Broecke PW, Mertens E, De Blier IG, Stockman BA, Rodrigus IE, Van der Linden PJ: Effects of propofol, desflurane, and sevoflurane on recovery of myocardial function after coronary surgery in elderly high-risk patients. *ANESTHESIOLOGY* 2003; 99:314–23
2. Scarabelli T, Stephanou A, Rayment N, Pasini E, Comini L, Currello S, Ferrari R, Knight R, Latchman D: Apoptosis of endothelial cells precedes myocyte cell apoptosis in ischemia/reperfusion injury. *Circulation* 2001; 104:253–6
3. Xia Z, Godin DV, Ansley DM: Propofol enhances ischemic tolerance of middle-aged rat hearts: Effects on 15-F(2D)-isoprostane formation and tissue antioxidant capacity. *Cardiovasc Res* 2003; 59:113–21
4. Allaouchiche B, Debon R, Goudable J, Chassard D, Dufflo F: Oxidative stress status during exposure to propofol, sevoflurane and desflurane. *Anesth Analg* 2001; 93:981–5
5. Kevin LG, Novalija E, Riess ML, Camara AK, Rhodes SS, Stowe DF: Sevoflurane exposure generates superoxide but leads to decreased superoxide during ischemia and reperfusion in isolated hearts. *Anesth Analg* 2003; 96:949–55

(Accepted for publication December 11, 2003.)

© 2004 American Society of Anesthesiologists, Inc. Lippincott Williams & Wilkins, Inc.

when administered only during the reperfusion period.^{6,7} Although the underlying mechanisms for these effects remain to be elucidated, there is now evidence that a reduction in postischemic adhesion of neutrophils may be involved.^{8,9} At the moment, it remains an open question how all these experimental observations may translate to clinical pathophysiology and even more to clinical treatment of myocardial ischemia-reperfusion injury.

Therefore, although it is conceptually attractive, the hypothesis proposed by Drs. Xia and Luo lacks experimental and clinical evidence. To date, there are indeed no published data available supporting the hypothesis that the administration of propofol as a sedative in the intensive care unit contributes to the cardioprotective effects of perioperatively administered sevoflurane and desflurane. Elucidation of this question would require a study protocol comparing sedation in the intensive care unit with propofol to another sedative agent without antioxidant properties.

Stefan G. De Hert, M.D., Ph.D., * Philippe J. Van der Linden, M.D., Ph.D. * University Hospital Antwerp, Belgium. stefan.dehert@ua.ac.be

References

1. De Hert SG, Cromheecke S, ten Broecke PW, Mertens E, De Blier IG, Stockman BA, Rodrigus IE, Van der Linden PJ: Effects of propofol, desflurane, and sevoflurane on recovery of myocardial function after coronary surgery in elderly high-risk patients. *ANESTHESIOLOGY* 2003; 99:314–23
2. Xia Z, Luo T, Ansley DM, Ouyang J, Xia ZY: Propofol reduces TNF- α induced human umbilical vein endothelial cell apoptosis (abstract). *ANESTHESIOLOGY* 2003; 99:A737
3. Ko SH, Yu CW, Lee SK, Choe H, Chung MJ, Kwak YG, Song HS: Propofol attenuates ischemia-reperfusion injury in the isolated rat heart. *Anesth Analg* 1997; 85:719–24
4. Xia Z, Godin DV, Ansley DM: Propofol enhances ischemic tolerance of middle-aged rats: Effects on 15-F(2D)-isoprostane formation and tissue antioxidant capacity. *Cardiovasc Res* 2003; 59:113–21
5. Ebel D, Schlack W, Comfère T, Preckel B, Thämer V: Effect of propofol on reperfusion injury after regional ischaemia in the isolated rat heart. *Br J Anaesth* 1999; 83:903–8
6. Preckel B, Schlack W, Comfère T, Barthel H, Obal D, Thämer V: Effects of enflurane, isoflurane, sevoflurane and desflurane on reperfusion injury after regional myocardial ischaemia in the rabbit heart *in vivo*. *Br J Anaesth* 1998; 81:905–12
7. Schlack W, Preckel B, Stunnecke D, Thämer V: Effects of halothane, enflurane, isoflurane, sevoflurane and desflurane on myocardial reperfusion injury in the isolated rat heart. *Br J Anaesth* 1998; 81:913–9

8. Kowalski C, Zahler S, Becker BF, Flaucher A, Conzen P, Eckerhart G, Klaus P: Halothane, isoflurane, and sevoflurane reduce postischemic adhesion of neutrophils in the coronary system. *ANESTHESIOLOGY* 1997; 86:188-95

9. Heindl B, Reichle FM, Zahler S, Conzen PF, Becker BF: Sevoflurane and

isoflurane protect the reperfused guinea pig heart by reducing postischemic adhesion of polymorphonuclear neutrophils. *ANESTHESIOLOGY* 1999; 91:521-30

(Accepted for publication December 11, 2003.)

Anesthesiology 2004; 100:1040

© 2004 American Society of Anesthesiologists, Inc. Lippincott Williams & Wilkins, Inc.

Impact of Heparin Management on Release of Tissue Factor Pathway Inhibitor during Cardiopulmonary Bypass

To the Editor:—In a recent investigation published in *ANESTHESIOLOGY*,¹ we reported on the effects of activated clotting time–based heparin management (ACT group) compared with a heparin concentration–based anticoagulation strategy (HMS group) on hemostatic activation and inflammatory response during cardiopulmonary bypass (CPB). Results of this investigation revealed that a heparin concentration–based management was associated with higher heparin concentrations and decreased thrombin activation, whereas fibrin generation levels were comparable in the two groups. We assumed that, because of the decreased concentrations of antithrombin during CPB, even the higher concentrations of heparin in the HMS group were less effective in complete attenuation of fibrin formation. However, for inhibition of central upstream coagulation cascades, which finally lead to thrombin activation, heparin action also requires antithrombin. Therefore, a mechanism of heparin action independent of antithrombin must be responsible for the observed differences in thrombin activation in the two groups.

Endothelial release of tissue factor is a central mechanism for the initiation of coagulation. The pivotal role of tissue factor in hemostatic activation during CPB is increasingly appreciated.² Physiologically, the effect of tissue factor is balanced by tissue factor pathway inhibitor (TFPI). However, the endothelial release of TFPI is a powerful antithrombin-independent anticoagulant effect of heparin. In human plasma, 85–90% of TFPI is bonded to the different lipoprotein fractions, and the remaining 10–15%, representing the active antithrombotic fraction, circulates as free TFPI and reduces thrombin activation by inhibition of the tissue factor–FVIIa complex and the protease FXa. Previous investigations³ assessing hemostatic activation during CPB revealed a positive correlation between concentrations of heparin and TFPI and negative correlations between TFPI and tissue factor concentrations. We speculated that the underlying mechanism for the reduced thrombin activation in the HMS group was increased endothelial release of TFPI with subsequent inhibition of the extrinsic coagulation pathway.

In the current study, we analyzed samples obtained during our previous investigation (plasma from citrated whole blood, which was immediately separated and stored at -80°C for a maximum of 3 months) and compared concentrations of free TFPI (TFPI_f) and total TFPI (TFPI_t) between the ACT and HMS groups. Samples were measured using enzyme-linked immune assays (Asserachrom[®] Free/Total TFPI; Diagnostica Stago, Asnières-sur-Seine, France). Statistical analysis was performed using the Student *t* test. Data are given in table 1.

The administration of high doses of heparin during CPB resulted in a more than 10-fold increase in TFPI_f and an approximately 3-fold increase in TFPI_t (which is attributed to the strong increase in TFPI_f) in

both groups. However, unexpectedly, the concentrations of TFPI_f were significantly increased in the ACT group, in which lower heparin concentrations had been measured before.¹ Direct effects of heparin may be responsible for these results. However, this observation must be characterized in further studies.

Recently, Kemme *et al.*⁴ reported that a continuous infusion of low-dose heparin (2,000 U over 40 min) resulted in a peak of TFPI release (and peak concentrations of TFPI_{f+t}) that were almost comparable with our findings after CPB) after 17 min, indicating fast exhaustion of endothelial TFPI pools even at this low heparin dosage (estimated heparin concentration, 0.2–0.4 U/ml). In our patients, the nearly 10-fold concentrations of heparin (2–3 U/ml) were maintained over a more extended period of time (approximately 80 ± 21 min).

Massive release of TFPI after administration of heparin may present an important mechanism for attenuation of hemostatic activation during CPB. However, considering the long half-life of TFPI (107 min)⁵ and fast exhaustion of TFPI at low concentrations of heparin,⁴ the reduced thrombin activation in the HMS group clearly cannot be attributed to a mechanism in which TFPI plays a pivotal role.

Thomas Fischer, M.D., Herman Kuppe, M.D., Andreas Koster, M.D.* * Deutsches Herzzentrum Berlin, Berlin, Germany.
koster@dhzb.de

References

1. Koster A, Fischer T, Praus M, Haberzettl H, Kuebler W, Hetzer R, Kuppe H: Hemostatic activation and inflammatory response during cardiopulmonary bypass: Impact of heparin management. *ANESTHESIOLOGY* 2002; 97:837–41
2. Chandler W, Velan T: Estimating the rate of fibrin and thrombin formation in vivo during cardiopulmonary bypass. *Blood* 2003; 101:4355–62
3. Kojima T, Gando S, Kemmotsu O, Mashio H, Goda Y, Kawahigashi N, Watanabe N: Another point of view on the mechanism of thrombin generation during cardiopulmonary bypass: Role of tissue factor pathway inhibitor. *J Cardiothorac Vasc Anesth* 2001; 15:60–4
4. Kemme MJ, Burggraaf J, Schoemaker RC, Kluff C, Cohen AF: Quantification of heparin-induced TFPI release: A maximum release at low heparin dose. *Br J Clin Pharmacol* 2002; 54:627–34
5. Kamikubo Y, Hamuro T, Matsuda J, Kamei S, Jyu-ri K, Miyamoto S, Funatsu A, Kato H: The clearance of proteoglycan-associated recombinant tissue factor pathway inhibitor (h-r-TFPI) in rabbits: A complex formation of h-r-TFPI with factor Xa promotes a clearance rate of h-r-TFPI. *Thromb Res* 1996; 83:161–73

(Accepted for publication October 20, 2003.)

Supported by the Humboldt University Berlin, Berlin, Germany.

Table 1. Concentration of TFPI_f and TFPI_t before and after CPB

	ACT _{pre-CPB}	HMS _{pre-CPB}	P Value	ACT _{post-CPB}	HMS _{post-CPB}	P Value
TFPI _f , ng/ml	11.2 ± 0.5	9.1 ± 0.7	0.89	162.5 ± 46.6	125.8 ± 35.2	<0.01
TFPI _t , ng/ml	59 ± 9.5	62.1 ± 9.7	0.87	192.3 ± 69.4	175.9 ± 63.4	0.58

ACT = group of patients treated according to an activated clotting time–based heparin protocol; CPB = cardiopulmonary bypass; HMS = group of patients treated according to a heparin concentration–based protocol; TFPI_f = free tissue factor pathway inhibitor; TFPI_t = total tissue factor pathway inhibitor.

Extracardiac Radiofrequency Ablation Interferes with Pacemaker Function but Does Not Damage the Device

To the Editor:—Radiofrequency ablation is becoming an important therapy but can cause a problem if applied very close to pacer leads. Hayes *et al.*¹ reported no problems with distant extracardiac ablation. We report an extracardiac case with a different finding.

The patient was admitted for radiofrequency ablation of a right adrenal metastasis. He also had heart block that was shown on electrophysiologic testing to be a high-grade suprahisian block. A permanent dual-chamber pacemaker (Meridian 1276; Cardiac Pacemakers Inc., St. Paul, MN) was implanted and programmed to Dual Chambers paced, Dual Chambers sensed, Dual response to sensing with Rate modulation (DDDR) mode (rate, 60–120 beats/min; output, 2.5 V/0.5 ms; sensitivity: atrium, 0.75 mV, ventricle, 2.5 mV). The radiofrequency equipment used was Cool-tip model 1025 (Radio Frequency Ablation System; Radionics, Tyco, Burlington, MA). Energy was delivered at a maximum of 200 W, 480 kHz at the lowest possible impedance, and achieved a treatment volume of 4.2–7.0 cm. Under intravenous general anesthesia, four 12-min radiofrequency ablations were performed, two in the inferior and two in the superior portions of the tumor mass. At the start of radiofrequency ablation, the pacemaker rate immediately changed from 63 to 96 beats/min (fig. 1A) and then showed an irregular pacing rhythm with intermittent runaway pacing during application of the radiofrequency current (fig. 1B). The underlying problem of complete atrioventricular block was also identified. However, pacing rhythm resumed in the postoperative care unit, without any device malfunctions.

The literature on intracardiac radiofrequency ablation is not applicable to this patient. Differences relate to time of current use, surface area, and target organ. The devices used for extracardiac radiofrequency ablation may have a continuous higher energy supply and a longer duration of ablation to provide a maximized ablation zone. Hayes *et al.* reported no electromagnetic interference with the pacemaker during intrahepatic radiofrequency ablation. In our case, electrocardiographic monitoring clearly demonstrated an influence on the pacemaker that inhibited the implanted pulse generator but did not permanently damage or reprogram it. This effect may be a manifestation of the extremely high field strengths induced by ablation in close proximity to the permanent pacing lead.² When we estimated and compared the distance between the delivery system and the pacing lead with that reported by Hayes *et al.*, no cases were found to be closer than 5 cm. However, the radiofrequency equipment used in our case has a higher energy supply and a larger treatment volume when compared with what Hayes *et al.* used in their patients. The other reasons for the differences may be a different pacemaker manufacturer and a variable programmed mode during radiofrequency ablation.³ Based on these observations and the limited information obtained from the reported cases, we propose the following as precautions for extracardiac radiofrequency ablation in patients with a permanent pacing

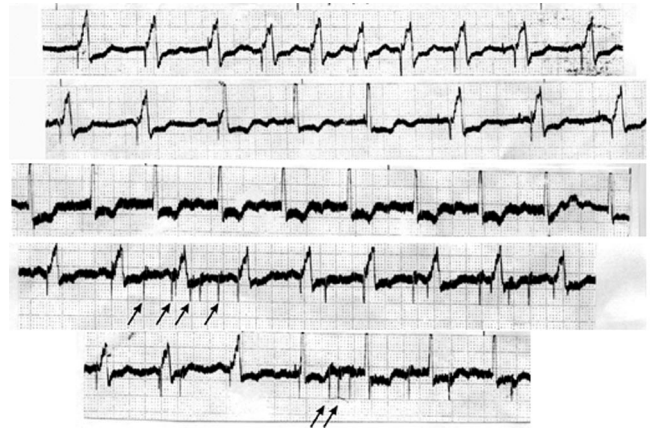


Fig. 1. (A) The rhythm was paced at 100%. At the start of radiofrequency ablation, the heart rate pace changed from 63 to 96 beats/min. (B) The intermittent temporary runaway pacing and the underlying complete atrioventricular block were identified. Arrows show the pacing rate increase at a rate analogous to the periodicity of the radiofrequency field modulation. Pacing resumes after termination of radiofrequency ablation.

system: (1) The distance between the extracardiac radiofrequency delivery system and the ventricular pacing lead must be 5 cm or more, depending on the power and treatment volume of the radiofrequency equipment used.^{1,2} (2) Temporary external sources of pacing should be available as a standby, should the permanent system be inhibited.² (3) The generator should be examined before and after the procedure in case any changes occur that necessitate reprogramming.²

Ng Yuet Tong, M.D., Hsieh Jing Ru, M.D., Hui Yu Ling, M.D., Yu Chun Cheung, M.D., Lau Wai Meng, M.D., Peter Chi Ho Chung, M.D.* * Chang Gung Memorial Hospital at Keelung, Keelung, Taiwan. p654084@cgmh.org.tw

References

- Hayes DL, Charboneau JW, Lewis BD, Asirvatham SJ, Dupuy DE, Lexvold NY: Radiofrequency treatment of hepatic neoplasms in patients with permanent pacemakers. *Mayo Clin Proc* 2001; 76:950–2
- Chin MC, Rosenqvist M, Lee MA, Griffin JC, Langberg JJ: The effect of radiofrequency catheter ablation on permanent pacemakers: An experimental study. *Pacing Clin Electrophysiol* 1990; 13:23–9
- Ellenbogen KA, Wood MA, Stambler BS: Acute effects of radiofrequency ablation of atrial arrhythmias on implanted permanent pacing systems. *Pacing Clin Electrophysiol* 1996; 19:1287–95

Support was provided solely from departmental sources.

(Accepted for publication October 30, 2003.)

Suicide Bombing: Professional Eyewitness Report

To the Editor:—At 2:12 PM on Saturday, October 4, 2003, while sitting in a car wash in Haifa with my wife, I heard the explosion. I turned and saw a thick black pillar of smoke. It was a blast detonated by a suicide bomber.

My first thought as an attending anesthesiologist at the Jerusalem Hadassah-Hebrew University Medical Center was, "This shouldn't be happening! I'm not in Jerusalem."

I grabbed my first aid kit and instructed my wife to stay put. Then I sprinted the 100 ft separating me from the bombed restaurant. As I was running, I was dialing the equivalent of 911 on my mobile phone. In the midst of all this anxiety, I was trying to describe my location. Although I thought I was being factual and coherent, they kept asking me, "What is the name of the restaurant?" I simply didn't know. Suddenly I noticed a sign on the building giving me the exact name of the restaurant.

The restaurant was quiet when I reached it. I saw a scene of total devastation. There was total silence: no crying, no screaming, no groaning, a paradoxical transient calmness. Glass and rubble crunched under my feet. Anyone who was able had fled from the scene. Those who were unable to flee lay silently on the floor. The interior of the restaurant was flattened—a miniature "Ground Zero." Exposed electric wires sparked, water poured out of destroyed piping. Pieces of wood and masonry crumbled and fell. Among all this destruction lay dozens of people who were seriously hurt and many unfortunately already dead.

I have worked at the Hadassah's emergency department after some 40 terror attacks over the past 3 yr. I was with my young daughter, yards away from a pizzeria in downtown Jerusalem, when a suicide bomber destroyed it in August 2001. But the nature of the destruction I witnessed after the attack on Haifa's Maxim Restaurant was of an entirely different magnitude. There was a sense of total desecration of human life. My emotions were distorted. I walked around with a feeling of dread. The visions of destruction included jumbles of human bodies lying in nonphysiologic postures, puddles of blood, extensive third-degree burns, distorting maxillofacial injuries, open wounds exposing internal organs (mainly brains), and a decapitated head.

I did not know what to do. Should I choose one survivor, giving him or her the best treatment I could, and abandon the others? My first aid kit seemed ridiculous among the multiple casualties. I quickly decided that my trauma skills could best be utilized by performing a preliminary triage. As I moved from one body to another, I checked for signs of life (size and reactivity of pupils, central pulse and respiratory efforts). I labeled as dead anybody that lacked *all* these criteria. For those who had signs of life, I performed a shortened primary evaluation ("A + B + half C," patency of airway, symmetry of chest rising/air entrance and major external bleeding). When I had completed this initial triage, there was still no ambulance at the scene. Outside, I saw a crowd in the distance. They did not disturb, nor did they help. Only two or three people remained with me inside the restaurant. I tried to use these individuals to evacuate two survivors, but they were stunned and would not cooperate. Seeing I had no help, I then focused on the one survivor that I believed had an excellent chance of survival. She was responsive to pain and snoring because of maxillofacial burns and fractures. I asked for help from these remaining people in the restaurant to pull away two bodies so I could get free access to her face. They just stared at me. I tried to intubate her but failed because she was

semiconscious and resisting, and the airway was full of blood. Then, to my relief, exactly when I raised my head looking for help, I saw the first paramedic enter. It seemed like an eternity until they arrived, but in fact, it was only 10 min.

The crews ran into the wreckage with stretchers, ventilators, infusions, and other equipment. I introduced myself by name and profession. Some of them were so shocked by the scene I had to shout at them to get their cooperation. Then, I directed these first-line emergency helpers away from the dead. However, some of the patients I had seen at the time of my initial triage were now dead.

When further manpower and equipment arrived, I started resuscitation procedures as we do in the emergency department in a multiple-casualty situation: I went back with a paramedic to the patient who I had failed to intubate earlier. Together, we were able to intubate her, and I gave the paramedic instructions on how to continue therapy. Then, I moved on to intubate the next survivor, leaving him with another paramedic. After this, I went back to see how the first paramedic was doing, and moved to a third survivor with severe head injury. After this intubation, I went back to check as to how the first and second were doing.

Then, I helped to load the stretchers onto the ambulances with the help of policemen and fire fighters. Nonprofessional help was available only from the firemen and police because all the other people were frozen with fear. I too was emotionally numb, unaware of feelings, sounds, or smells. A shard of glass cut my elbow, but this remained unnoticed for 3 h.

It was 25 min after the explosion when I rode in the ambulance with the third patient I had treated. We exposed the whole body for assessment and obtained venous access on the way to the nearest hospital. The hospital's emergency department was already overwhelmed when we arrived. Nurses helped me to locate medical instruments and supplies, inserting an additional large bore intravenous catheter, sending blood tubes to laboratories, measuring vital signs, and arranging for x-rays and ultrasound, until a local physician was free and took over.

My wife met me outside the hospital and we drove home. On the way, I was thinking about the decision I made after running to help inside the first pizzeria bombing in Jerusalem and how dangerous it was. Wouldn't anyone with a healthy sense of self-preservation run in the opposite direction? Now it had happened to me again, and all rational thinking disappeared. I ran to the restaurant and acted on a professional instinct, and I do not regret that.

The next day, I went to work, a hundred miles away. There was no way I could really share this experience because I (wrongly) believed it was inappropriate to describe the sights in detail. The next three nights, I woke every half hour, thinking of what I did in the wreckage, how I could have done things better. Sights and even smells of the violently desecrated bodies flashed into my mind constantly. It was as if all the emotions suppressed in the restaurant had been stored in memory, and I was now unzipping the file. It was difficult admitting that I was taking it so hard. I have seen trauma patients since I was a 16-yr-old volunteer with the emergency medical service in Jerusalem. As an anesthesiologist, I have specialized in trauma anesthesia. I teach trauma care. I am soon to spend a year in Miami's Ryder Trauma center (Jackson Memorial Hospital), further specializing in the field. But I could not free myself.

I realized I should share my first-hand experience and personal conclusions from these two events with non-emergency medical service first responders. I hope that knowing what to expect will help others in case they find themselves in a similar situation:

Support was provided solely from institutional and/or departmental sources. The author thanks Wendy Elliman, B.A. (Jerusalem, Israel), and Michael C. Lewis, M.D. (Associate Professor, Anesthesiology, University of Miami School of Medicine, Miami, Florida), who helped with converting a difficult experience to words.

1. Call for help (911).
2. If you are accompanied by a non-medical professional (e.g., family), make sure they stay in a safe place, out of view.
3. Be ready for sights unfamiliar in the emergency department. Anticipate the normal state of shock and helplessness so you can fight it.
4. Until the emergency medical service arrives, you are in a real *mass-casualty event*. The best thing to do is start triaging. Identify the dead (reactivity and size of pupils, central pulse, and respiratory efforts). Perform a short primary survey of the survivors (A, B, and half C).
5. After the emergency medical service arrives, it is the simpler *multiple-casualty event* scenario. Introduce yourself repeatedly by name and medical profession; give your triage information to the first paramedic, and only then start treating survivors.
6. If you are asked to step out, obey.
7. The environment is dangerous: The broken glass and metal shards are a real hazard, as well as the danger of a collapsing ceiling. More important is the danger of a second explosion resulting from a

- combination of exposed electric wires, perforated water, and gas pipes, as well as a second bomb scheduled to hurt the rescuers. Quick evacuation of survivors is therefore mandatory, thus enabling firemen and bomb squads to prevent further injuries. I believe that clearing the scene to protect survivors and rescuers justifies compromise of meticulous spinal cord immobilization.
8. In an urban area with the existence of many evacuating vehicles, only a limited number of interventions are indicated on scene: airway secure, tension pneumothorax relief, major external bleeding control, and spine immobilization. All other things can be done *en route*.
 9. Do not hesitate to seek early psychological consultation to prevent chronic posttraumatic stress disorder.

Micha Y. Shamir, M.D., Hadassah-Hebrew University Medical Center, Jerusalem, Israel, and University of Miami School of Medicine, Miami, Florida. shamir61@bezeqint.net

(Accepted for publication November 14, 2003.)

Anesthesiology 2004; 100:1043

© 2004 American Society of Anesthesiologists, Inc. Lippincott Williams & Wilkins, Inc.

Myocardial Ischemia Induced by Intramyometrial Injection of Methylergonovine Maleate

To the Editor:—The anesthesiology literature describing coronary spasm after intravascular injection of an ergot alkaloid used for the treatment of uterine atony is limited to one case report.¹ I herein report a similar case in association with intramyometrial injection of the drug. An otherwise healthy (there were, specifically, no coronary risk factors) 36-year-old white woman (height, 165 cm; weight, 71 kg; gravida 2, para 1) at 39 weeks' gestation required an elective repeat cesarean delivery for fetal macrosomia, which was conducted under spinal anesthesia. After the uneventful delivery of the fetus and despite uterine massage and a continuous intravenous oxytocin infusion, the uterus remained atonic. A single intramyometrial injection of 0.2 mg methylergonovine maleate was administered by the obstetrician. The patient reported the almost immediate onset of a severe left-sided substernal chest pain, radiating to her left arm, and shortness of breath. Blood pressure was 110/61 mmHg, heart rate was 86 beats/min, respiratory rate was 18 breaths/min, and oxygen saturation was 100%. The electrocardiogram revealed normal sinus rhythm with nonspecific T-wave abnormalities and transient ST-segment elevation. The rapid onset of chest pain after administration of Methergine (Novartis Pharmaceuticals, East Hanover, NJ) and the patient's report of chest tightness after a drug given to help the uterus contract at the time of her first cesarean delivery (which had not been conveyed to the anesthesiologist and the obstetrician before the current event) led, in this case, to the prompt diagnosis and immediate treatment of myocardial ischemia. The clinical symptoms (chest pain) and the electrocardiographic changes were reversed with intravenous injection of 3.5 μ g/kg nitroglycerin, for a total dose of 250 μ g. A postoperative 12-lead electrocardiogram and creatine phosphokinase enzyme analysis did not show any evidence of myocardial ischemia or infarction, and cardiology

evaluation was noncontributory. Ergot derivatives can induce coronary spasm, and their use as a diagnostic agent in cardiac catheterization laboratories is well established. Nitroglycerin can be useful in reversing Methergine-induced coronary spasm and preventing subsequent development of myocardial ischemia and infarction.¹ Although other conditions, such as esophageal spasm, are known to mimic angina and are accompanied by nonspecific electrocardiographic changes, the onset of clinical symptoms of left-sided substernal chest pain, radiating to the left upper extremity, with associated shortness of breath, and electrocardiographic changes almost immediately after intramyometrial administration of Methergine suggest cardiac etiology (coronary vasospasm). In addition, the patient's admission of a similar symptomatology after the previous administration of ergot alkaloids should not be ignored. Because the myometrium is a highly vascular tissue, the intramyometrial injection of methylergonovine maleate might behave as an intravascular injection (which is not routinely recommended in the obstetric patient population). In conclusion, it is difficult to speculate whether different outcomes would have been reported (cardiovascular morbidity as described by Tsui *et al.*¹) if the diagnosis (based in this case primarily on clinical symptoms) and nitroglycerin injection to reverse the coronary spasm had been delayed.

Krzysztof M. Kuczkowski, M.D., University of California San Diego, San Diego, California. kkuczkowski@ucsd.edu

Reference

1. Tsui BCH, Stewart B, Fitzmaurice A, Williams R. Cardiac arrest and myocardial infarction induced by postpartum intravenous ergonovine administration. *ANESTHESIOLOGY* 2001; 94:363-4

Support was provided solely from institutional and/or departmental sources.

(Accepted for publication November 19, 2003.)