

Moderate Increase in Intraabdominal Pressure Attenuates Gastric Mucosal Oxygen Saturation in Patients Undergoing Laparoscopy

Lothar A. Schwarte, M.D.,* Thomas W. L. Scheeren, M.D.,† Christel Lorenz, M.D.,† Filip De Bruyne, M.D.,‡
Artur Fournell, M.D.†

Background: Perioperative disturbances of microvascular blood flow and oxygenation in the intestinal tract have been hypothesized to play an important role in development of the multiple organ dysfunction syndrome. Herein, increased intra-abdominal pressure (IAP) has been identified as a key factor in the initiation of the pathophysiologic cascade. The authors hypothesized that increasing the IAP by intraperitoneal insufflation of carbon dioxide attenuates microvascular oxygen saturation in gastric mucosa. They tested this hypothesis in a prospective, observational study in 16 patients scheduled to undergo elective diagnostic laparoscopy.

Methods: The authors continuously assessed microvascular oxygen saturation in gastric mucosa by reflectance spectrophotometry. Simultaneously systemic oxygen saturation, heart rate, arterial blood pressure, and ventilation-derived variables were measured noninvasively. During general anesthesia and controlled mechanical ventilation, baseline values were obtained. Thereafter, the IAP was increased to 8 and 12 mmHg, respectively, followed by a control period after desufflation.

Results: The increase in IAP from baseline to 8 mmHg decreased microvascular oxygen saturation in gastric mucosa from $69 \pm 7\%$ (mean \pm SD) to $63 \pm 8\%$ at 8 mmHg IAP ($P < 0.05$), with a further significant reduction to $54 \pm 13\%$ at 12 mmHg IAP ($P < 0.01$). Microvascular oxygen saturation in gastric mucosa recovered rapidly to baseline level ($66 \pm 10\%$) after release of increased IAP. In striking contrast to regional mucosal oxygen saturation, systemic oxygenation did not change with either of the interventions.

Conclusions: The results suggest that increasing intraabdominal pressure to moderate levels, commonly applied to induce a surgical pneumoperitoneum, decreases gastric mucosal oxygen saturation.

INTRAABDOMINAL hypertension is a clinical condition associated with high morbidity and mortality. With a cutoff at 12 mmHg, the intraabdominal pressure (IAP) has been shown to be an independent predictive factor for intensive care unit and hospital mortality with high specificity (91.6% and 81.7%, respectively) and accuracy (86.9% and 79.8%, respectively); the higher the IAP value, the poorer the survival.¹ Within this concept, increased IAP has been identified as a major component

in the development of the multiple organ dysfunction syndrome.^{1,2} In view of the hypothesized pivotal role of the gut in the pathogenesis of this syndrome,³ *i.e.*, by disturbances of microvascular blood flow and mucosal barrier function,⁴⁻⁷ possible adverse effects of increased IAP on splanchnic circulation and oxygenation are of pertinent interest. Increases in IAP to 25 mmHg for 60 min have been implicated in the occurrence of decreased mesenteric blood flow and hence the loss of mucosal barrier function.⁸

In experimental animals, increasing the IAP by different techniques, *e.g.*, insufflation of an intraabdominal balloon, intraperitoneal insufflation of carbon dioxide, helium, or air, has been shown to compromise splanchnic perfusion.⁹⁻¹¹ Consequently, a decrease in tissue partial pressure of oxygen (P_{O_2}) in the ileum in response to increased IAP has been documented in a porcine model of abdominal hypertension.¹⁰ However, because of the lack of applicable methods in patients to directly assess tissue oxygenation, measurements of splanchnic mucosal oxygenation during increased IAP have been restricted to experimental settings.¹⁰ No data have been published on this issue in patients so far.

We hypothesized that the increase in IAP decreases microvascular oxygen saturation in gastric mucosa (μHbO_2) pressure level dependently. To test this hypothesis, we studied the effect of different levels of IAP on μHbO_2 and the reversibility of these effects in anesthetized patients. In this setting, μHbO_2 was assessed directly in gastric mucosa by reflectance spectrophotometry.¹² This method allows for continuous measurement of microvascular oxygen saturation in volunteers and patients.¹³⁻¹⁵

Materials and Methods

Patients

The study protocol was approved by the local Institutional Review Board (Ethics Committee, Medical Faculty, Heinrich-Heine-University, Düsseldorf, Germany) and performed in compliance with the principles established in the Helsinki Declaration. Sixteen patients scheduled to undergo elective, diagnostic laparoscopy were included consecutively after a full explanation of the study and obtaining written informed consent. Exclusion criteria included withdrawal of consent, history of gastrointestinal illness, cardiopulmonary diseases, and diabetes mellitus. Patients had ovary cysts, myoma, endometri-

* Research Fellow, † Staff Anesthesiologist, Department of Anesthesiology, ‡ Staff Obstetrician, Department of Gynecology and Obstetrics.

Received from the Departments of Anesthesiology and Gynecology and Obstetrics, Heinrich-Heine-University, Düsseldorf, Germany. Submitted for publication August 20, 2003. Accepted for publication December 10, 2003. Supported by departmental funds and a grant from the Research Commission, Medical Faculty, Heinrich-Heine-University, Düsseldorf, Germany. Presented in part at the 29th Annual Meeting of the International Society on Oxygen Transport to Tissue, Philadelphia, Pennsylvania, August 11-15, 2001.

Address reprint requests to Dr. Fournell: Department of Anesthesiology, Heinrich-Heine-University, Düsseldorf, Moorenstrasse 5, D-40225 Düsseldorf, Germany. Address electronic mail to: fournell@uni-duesseldorf.de. Individual article reprints may be purchased through the Journal Web site, www.anesthesiology.org.

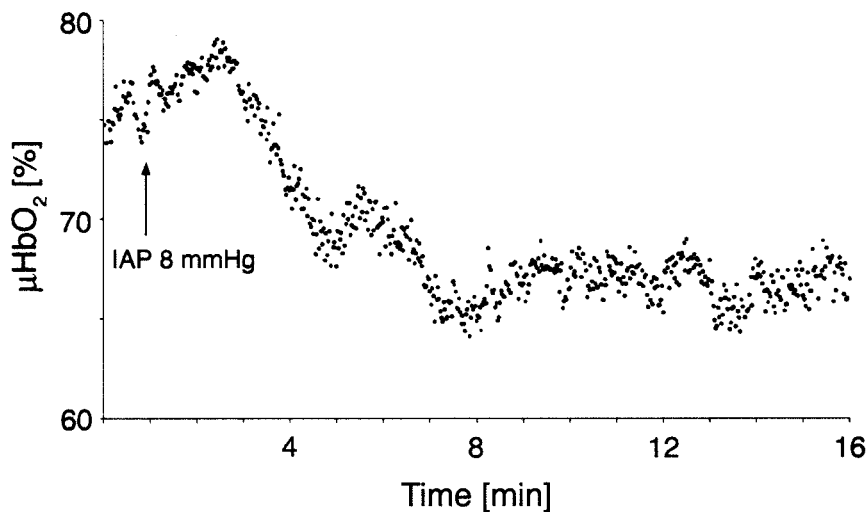


Fig. 1. Representative on-line tracing of gastric mucosal oxygen saturation (μHbO_2) in a patient before and during induction of a carbon dioxide-pneumoperitoneum. The high resolution of reflectance spectrophotometry (each data point represents the mean of 100 recorded spectra, measured in 1.6 s) unveils the physiologic changes of μHbO_2 over time. Starting from a mean value of 76%, the elevation of intraabdominal pressure (IAP) elicited a biphasic response on μHbO_2 . Initially, with the elevation of IAP to 8 mmHg (indicated by arrow), μHbO_2 showed a brief tendency to increase slightly, probably because of the squeezing of intraabdominal veins and, hence, possibly augmentation of venous return and cardiac output; but after approximately 2 min, μHbO_2 started to decline to, finally, a mean value of 67%.

sis, or infertility. The average patient age was 31 ± 9 yr (mean \pm SD). The patients' mean size and body weight were 167 ± 7 cm and 64 ± 14 kg, respectively, resulting in an average body mass index of 22.9 ± 4.5 kg/m². Nine patients had American Society of Anesthesiologists physical status class I, and three patients had class II.

Anesthesia and Ventilation

Food was withheld for 8 h before the measurements to ensure gastric depletion. Premedication consisted of 7.5 mg midazolam orally. Anesthesia was induced with thiopentone (3–5 mg/kg) and was maintained with sevoflurane (end-tidal concentration, 1.6–1.8 vol%) in 30% oxygen balanced in air. Analgesia was supplemented with alfentanil (10 $\mu\text{g}/\text{kg}$, followed by 10–30 $\mu\text{g} \cdot \text{kg}^{-1} \cdot \text{h}^{-1}$). Tracheal intubation was facilitated with rocuronium (0.6 mg/kg); neuromuscular block was maintained with 0.1-mg/kg increments. Mechanical ventilation (Cicero EM; Dräger, Lübeck, Germany; tidal volume, 9 ml/kg; inspiratory:expiratory cycle time, 1:1.7; positive end-expiratory pressure, 0 cmH₂O) was set meticulously to maintain normocapnia (end-tidal partial pressure of carbon dioxide [ETCO₂], 36 ± 3 mmHg, verified by continuous capnography) by adjusting respiratory rate.

The patients were hydrated with lactated Ringer's solution (10 ml \cdot kg⁻¹ \cdot h⁻¹). During the study, the patients were lying in the supine position and were covered with warming blankets (Bair Hugger; Arizant Inc., Eden Prairie, MN) to preserve body temperature.

Measurements

Tissue Reflectance Spectrophotometry. We applied reflectance spectrophotometry (Erlangen Microlichtguide Spectrophotometer, EMPHO II; Bodensee Gerätetechnik GmbH, Überlingen, Germany) to assess microvascular oxygen saturation of hemoglobin in gastric mucosa as previously reported in patients and volunteers.^{14,15} The EMPHO consists of four functional

modules: a light source, a micro-light guide probe, a detection device, and a personal computer. The light from a xenon high-pressure arc lamp is transmitted by a highly flexible micro-light guide (250- μm diameter) to the tissue. The color of this light changes corresponding to the oxygen saturation of hemoglobin in tissue. The reflected light in the tissue is transferred back by a hexagon of six light guides (250- μm diameter) surrounding the illuminating light guide. All light guides are encased in a flexible rubber tube with an OD of approximately 2.0 mm. The backscattered light is passed through a rotating interference bandpass filter disk, where it is split into its spectral components. These spectra are fitted to known spectra, starting with the spectra of fully oxygenated and fully deoxygenated hemoglobin, in an iteration process with a resolution of 1 nm to provide absolute data of μHbO_2 (EMPHO II software, version 2.0; Bodensee Geräte Technik, Friedrichshafen, Germany).¹²

The light guide probe was introduced *via* an orogastric tube (14 Charrière) inserted for 50 cm from the upper row of teeth into the stomach. The position of the tube in the stomach was identified by insufflating a small volume (approximately 20 ml) of ambient air into the tube during auscultation over the epigastrium^{14,15} and by the aspiration of gastric contents.¹⁶ During the study period, the stomach was drained *via* this tube to prevent gastric distension.

The measuring probe was introduced *via* the orogastric tube (length marker on the probe to assure that the tip of the probe was 1 cm beyond the distal opening of the orogastric tube after inserted up to the length marker). The precise contact of the measuring probe with the gastric mucosa was ascertained by continuous evaluation of the shape of the absorption curve on the monitor screen of the EMPHO as detailed previously.^{14,15,17,18} The scattering of μHbO_2 data points from the average value during steady state conditions was

below $\pm 2\%$ (fig. 1). Values given refer to the mean value over the last 2 min at the end of each intervention.

Intraabdominal Pressure. Measurement of IAP was accomplished by the introduction of a Veress cannula (OD, 2.1 mm; Karl Storz GmbH & Co KG, Tuttlingen, Germany) into the abdominal cavity *via* a periumbilical incision. Medical carbon dioxide was insufflated intermittently at a flow of 1.5 l/min through this cannula until the IAP reached and maintained the target level (Thermoflator; Karl Storz GmbH & Co KG).

Systemic Hemodynamics and Oxygenation. We assessed systemic hemodynamics, *i.e.*, heart rate (electrocardiographically triggered cardiometer) and arterial blood pressure, noninvasively (automatic oscillometer, Cardiocap II; Datex-Engstrom, Helsinki, Finland). We continuously measured systemic oxygen saturation by pulse oximetry (Cardiocap II).

Study Protocol

At least 20 min were allowed after induction of anesthesia and instrumentation to establish steady state conditions with respect to anesthesia, hemodynamics, ventilation, metabolism (constant inspiratory-to-expiratory gradient of oxygen concentration, ET_{CO_2}), and systemic and regional oxygen saturation before collection of data was started. Thereafter, the IAP was increased to 8 and 12 mmHg, respectively, followed by release of increased IAP. Data were compared during steady state conditions at four time points: (1) baseline measurements, performed with the Veress cannula *in situ* with 0 mmHg superimposed IAP (baseline); (2) during an IAP of 8 mmHg; (3) during an IAP of 12 mmHg; and (4) after release of increased IAP (control). Each measurement period lasted 15 min, a time sufficient to achieve stable values of the assessed variables.

Statistical Analysis

Statistical calculations and analysis were performed using StatView (version 5.0; SAS Institute, Inc., Cary, NC) and JMP software (version 5.0.1a; SAS Institute, Inc.). Patient group size calculations were derived from a previous study in volunteers,¹⁵ according to which we calculated that at least 13 patients had to be studied to detect a 10% diminution in μHbO_2 with an α error of 0.05 and a power of 0.95 based on a SD of 9% within μHbO_2 measurements. We decided to consecutively include 16 patients in the study group.

The results obtained are given as mean \pm SD. After confirming normal distribution of our data (Kolmogorov-Smirnov test), one-way analysis of variance for repeated measurements was used to analyze continuous variables measured over time. The following hypotheses were tested: Increases in IAP cause a pressure level-dependent reduction in μHbO_2 , and there is no significant difference in values of μHbO_2 during baseline and control measurements after release of increased IAP. In case

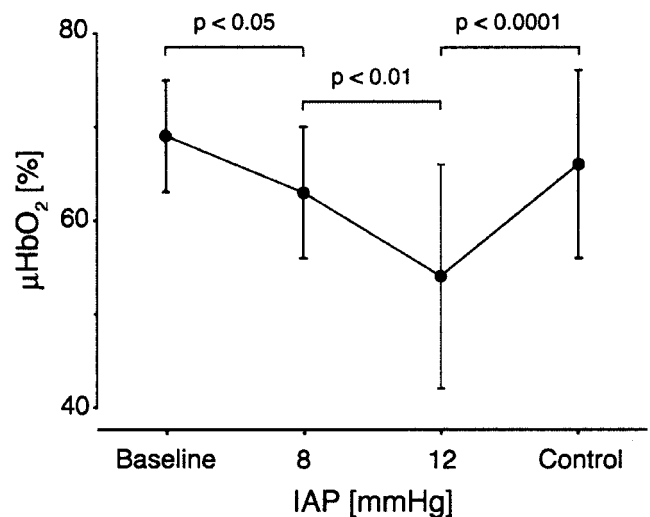


Fig. 2. Variability in microvascular oxygen saturation in gastric mucosa (μHbO_2) during graded elevation of intraabdominal pressure (IAP), and after release of increased IAP in anesthetized patients. Data are expressed as mean \pm SD for $n = 16$ patients. Elevating IAP decreased the μHbO_2 pressure level dependently, whereas pressure release returned the μHbO_2 almost to baseline values. Baseline = baseline measurements; Control = measurements after desufflation, control period; IAP 8 = measurements during 8 mmHg IAP; IAP 12 = measurements during 12 mmHg IAP.

of significance, Scheffé *post hoc* test was applied to identify significant differences. Statistical significance was assumed if the α error was smaller than 5%.

Results

All patients fulfilled the study protocol, and none had to be excluded because of missing data. They experienced an uneventful course and recovery from anesthesia, and none of them developed clinically significant signs of gastrointestinal complications before hospital discharge. Because of dislocation, the probe for μHbO_2 measurements had to be repositioned in three patients. Reposition was not followed by different readings.

Gastric Mucosal Oxygen Saturation

Analysis of variance for repeated measurements showed significant effects of the level of IAP on μHbO_2 ($P < 0.0001$). Increasing IAP pressure level dependently attenuated μHbO_2 (fig. 2), resulting in a decrease from $69 \pm 7\%$ at baseline to $63 \pm 8\%$ (mean \pm SD) at 8 mmHg IAP ($P < 0.05$). The decrease in μHbO_2 was even more pronounced with the increase in IAP from 8 to 12 mmHg, *i.e.*, from $63 \pm 8\%$ to $54 \pm 13\%$ ($P < 0.01$). Release of increased IAP resulted in a rapid return in μHbO_2 almost to baseline, *i.e.*, to $66 \pm 10\%$.

Systemic Oxygen Saturation

In striking contrast to regional oxygen saturation, the stepwise increase and subsequent release in IAP did not

Table 1. Effects of Incremental Increases and Subsequent Release of IAP on Systemic Hemodynamics and Systemic Oxygen Saturation

	Baseline	IAP 8	IAP 12	Control
MAP, mmHg	70 ± 9	84 ± 20*	89 ± 15†	80 ± 13
HR, min ⁻¹	77 ± 8	81 ± 10	81 ± 12	73 ± 12
SpO ₂ , %	98 ± 1	98 ± 1	97 ± 1	98 ± 1

Data are expressed as mean ± SD for n = 16 patients.

* $P < 0.02$ baseline vs. IAP-8. † $P < 0.001$ baseline vs. IAP-12.

Baseline = measurements during 0 mmHg superimposed intraabdominal pressure (IAP), baseline measurements; control = measurements after desufflation, control period; HR = heart rate; IAP 8 = measurements during 8 mmHg IAP; IAP 12 = measurements during 12 mmHg IAP; MAP = mean arterial pressure; SpO₂ = systemic oxygen saturation.

influence systemic oxygen saturation, which remained stable throughout all interventions (table 1).

Systemic Hemodynamics and Ventilation

The increase in IAP from baseline to 8 mmHg increased mean arterial pressure (MAP) by 14 mmHg ($P < 0.05$), whereas the increase in IAP from 8 to 12 mmHg had no significant additional effect on MAP (table 1). Heart rate increased slightly with the increase in IAP and decreased with release of increased IAP, although these changes did not reach the level of significance (table 1).

End-tidal carbon dioxide remained stable during all interventions by increasing respiratory rate to adjust minute ventilation (table 2). Peak and mean airway pressure increased slightly in order with the increases in IAP to 8 and 12 mmHg, respectively (table 2). Both pressures returned to their respective baseline levels during the control period after desufflation, despite still-increased minute ventilation compared with baseline measurements. End-tidal concentrations of sevoflurane did not vary significantly during the anesthetic procedure (table 2).

Table 2. Course of Ventilation-derived Variables and End-tidal Sevoflurane Concentration during Graded Increases and Subsequent Release of IAP

	Baseline	IAP 8	IAP 12	Control
ETCO ₂ , mmHg	35 ± 2	37 ± 2	37 ± 3	36 ± 3
RR, min ⁻¹	9 ± 2	10 ± 3	13 ± 3*	12 ± 4†
V, l/min	5.0 ± 0.6	5.7 ± 0.9	7.0 ± 1.7*	6.9 ± 2.1†
P _{aw} peak, cmH ₂ O	15 ± 5	17 ± 5‡	20 ± 4§	17 ± 6#
P _{aw} mean, cmH ₂ O	4 ± 2	5 ± 1‡	6 ± 2§	4 ± 1#
ET sevoflurane, vol%	1.6 ± 0.5	1.7 ± 0.3	1.8 ± 0.3	1.6 ± 0.6

Data are expressed as mean ± SD for n = 16 patients.

* $P < 0.01$ baseline vs. IAP-12. † $P < 0.01$ baseline vs. control. ‡ $P < 0.05$ baseline vs. IAP-8. § $P < 0.002$ IAP-8 vs. IAP-12. || $P < 0.0001$ baseline vs. IAP-12. # $P < 0.001$ IAP-12 vs. control.

Baseline = measurements during 0 mmHg superimposed intraabdominal pressure (IAP), baseline measurements; control = measurements after desufflation, control period; ETCO₂ = end-tidal partial pressure of carbon dioxide; ET sevoflurane = end-tidal concentration of sevoflurane; IAP 8 = measurements during 8 mmHg IAP; IAP 12 = measurements during 12 mmHg IAP; P_{aw} peak and mean = peak and mean airway pressure, respectively; RR = respiratory rate; V = minute volume.

Discussion

This is the first study in patients directly assessing microvascular oxygen saturation in gastric mucosa during increased intraabdominal pressure. The main finding is that the increase in IAP to moderate levels, *i.e.*, 12 mmHg or less, significantly decreased gastric mucosal oxygen saturation despite stable systemic oxygen saturation. These effects were rapidly and completely reversed by the release of increased IAP.

Critique of Methods

We applied reflectance spectrophotometry to continuously assess μHbO_2 . The validity of oxygen saturation measurements in intestinal mucosa using reflectance spectrophotometry has been demonstrated by Hasibeder *et al.*,¹⁹ comparing μHbO_2 data with simultaneously recorded microvascular Po₂ values provided by surface Po₂ electrodes. Moreover, spectrophotometric measurements have been shown to be consistent with regional perfusion data in gastroduodenal mucosa assessed by the hydrogen gas clearance technique.²⁰ Normal values of μHbO_2 in volunteers spontaneously breathing ambient air have been reported to be 59 ± 7%.¹⁵

Oxygen saturation measurements applying reflectance spectrophotometry comprise arterial, capillary, and venous blood; although the exact proportions are unknown, capillary blood probably represents the major source of the reflected light from tissue.²¹ The EMPHO detects this light from a depth of less than 1 mm, *i.e.*, only from gastric mucosa.²¹

Our technique to place the micro-light guide *via* an orogastric tube allowed identification of the location of the measuring probe in the stomach but did not provide information regarding the precise area of gastric mucosa being monitored. However, μHbO_2 values in humans do not show major variability between various mucosal observation sites in the stomach and in the upper small intestine.¹³ In addition, although the changes in μHbO_2 in gastric mucosa in our patients during increased IAP might not represent the absolute values of what is occurring in the entire splanchnic region, it can be speculated that the changes in μHbO_2 during increased IAP were mirrored by comparative concurrent alterations in other splanchnic organs. This view is supported by simultaneous laser Doppler flow measurements in patients undergoing laparoscopy with a carbon dioxide pneumoperitoneum showing decreases in mucosal blood flow in all intestinal organs up to 54%.²²

The supine position of the patients on the table was standardized and maintained throughout the entire observation period because positional changes could have affected systemic and regional circulation.²³ During the study period, all patients received a standardized inhalation anesthesia regimen with sevoflurane, carefully adjusted to meet the anesthetic requirements. The varia-

tion in μHbO_2 with increasing IAP should not have been influenced by sevoflurane because end-tidal concentrations of this anesthetic did not differ significantly between the measurement phases (table 2).

We used the intermittent flow mode of the Thermoflator to induce and control the level of intraabdominal pressure. In this mode, the IAP is measured during the no-flow phases, *i.e.*, it cannot be confounded by flow dynamics.

End-tidal carbon dioxide was assessed by capnography. This method has been shown to adequately guide ventilation during laparoscopy in patients with a carbon dioxide pneumoperitoneum.²⁴ We maintained ETCO_2 stable throughout the entire study period, a regimen that compensates for the acid-base disturbances elicited by intraabdominal insufflation of carbon dioxide.²⁵

Furthermore, our results could have been influenced by the selection of carbon dioxide to increase IAP. In patients undergoing laparoscopic surgery, gastric mucosal partial pressure of carbon dioxide (Pco_2) increased slightly from 39 mmHg at baseline to 44 mmHg during a carbon dioxide pneumoperitoneum at 12 mmHg IAP despite stable ETCO_2 .²⁶ We cannot supply data on mucosal Pco_2 in our patients. However, on a theoretical basis, an increase in mucosal Pco_2 in an extent of 5 mmHg could elicit a modest rightward shift of the respective oxyhemoglobin dissociation curve and hence a minor decrease in μHbO_2 of 1–2%.

In a porcine model with stable ETCO_2 , the insufflation of air decreased mesenteric artery blood flow during the entire bandwidth of increased intraabdominal pressures, whereas the insufflation of carbon dioxide reduced the flow only at an IAP level greater than 12 mmHg.¹¹ Thus, one might speculate that in our study, the attenuation of μHbO_2 would probably have been even more pronounced with the insufflation of air compared with the insufflation of carbon dioxide.

Interpretation of Results

The baseline values of μHbO_2 in our patients were within the physiologic range observed in healthy volunteers.¹⁵ Direct measurements of splanchnic mucosal oxygenation during increased IAP in patients have not yet been reported. However, similar to our results, indicating reduced regional despite unchanged systemic oxygen saturation during increased IAP, Bongard *et al.*¹⁰ reported in a porcine model a decrease in Po_2 in the ileum in response to an increase in IAP despite unaltered Po_2 in the subcutaneous tissue. Comparable to our data, an impairment of splanchnic perfusion-oxygenation corresponding to the level of IAP has been demonstrated in patients by gastric tonometry and the calculation of intramucosal pH.^{27,28} Furthermore, these studies reported a direct relation between abnormally low intramucosal pH and outcome.^{27,28}

Microvascular oxygen saturation reflects the balance of local oxygen influx to consumption.¹³ Therefore, the

attenuation of μHbO_2 during increased IAP could be attributed to increased consumption, to decreased systemic or regional oxygen supply, or to a combination of both. Increased regional oxygen consumption cannot be excluded completely in our study, although there is no experimental evidence supporting the idea of enhanced mucosal oxygen consumption during increased IAP. However, even though MAP and heart rate were well maintained during abdominal hypertension in our patients, compromised systemic or regional oxygen supply with incremental levels of IAP might have contributed to the decrease in μHbO_2 . Intraabdominal hypertension and its transmission to the thoracic cavity increases venous resistance and may thus decrease both inferior and superior vena cava flow, resulting in reduced preload and consequently decreased cardiac output.^{29–32} However, the cutoff point for the impairment of venous return at 15 mmHg IAP is well above the levels of IAP applied in our study; actually, IAP pressures of 10–15 mmHg have been reported to enhance venous return by the mobilization of blood from capacitance vessels in the abdomen.³³ This may account for the slight increase in cardiac output demonstrated with moderate increases in IAP.^{30,34}

The increase in MAP in our study with increasing IAP probably reflects an increase in systemic vascular resistance as recently reported in patients during laparoscopic surgery.³⁵ However, because the increases in MAP were counterbalanced in part by the simultaneous increase in IAP, the abdominal perfusion pressure³⁶ remained fairly stable, *e.g.*, MAP increased only by 5 mmHg during the pressure step in IAP from 8 to 12 mmHg (table 1). In addition, in view of a considerably broad range of autoregulation of perfusion in the gut,³⁷ it is unlikely that changes in MAP in a range as observed in our study can account for the alterations in μHbO_2 .

From a mechanistic point of view, the abdominal cavity can be viewed as a single compartment of limited space.³⁸ Therefore, any increase in one of its components amplifies mesenteric vascular resistance and may thus decrease perfusion.²⁹ This view is corroborated by the study of Caldwell *et al.*⁹ The authors showed in a canine model that the organ blood flow decreased significantly during increased IAP for all intraabdominal viscera except the renal cortex and the adrenal gland. Moreover, the changes in regional perfusion could not be predicted from systemic values, *i.e.*, they were more pronounced than could be derived from the alterations in systemic hemodynamics alone. Therefore, the authors suggested that systemic effects together with local control mechanisms might be responsible for the changes in organ blood flow.⁹

Impairment of perfusion in splanchnic organs during increased IAP has been reported in other studies—however, usually at higher levels than those applied in our

patients.^{9,39,40} These discrepancies might be explained by differences in the ventilatory regimen: ET_{CO_2} or arterial pH were not kept stable in these studies.^{9,39,40} We hypothesize that the resultant hypercapnia might have increased organ perfusion and thus outweighed the depressant effect of moderately increased IAP. This view is supported by findings of Akca *et al.*⁴¹ showing that hypercapnia improves tissue oxygenation.

Microvascular oxygen saturation in gastric mucosa recovered to baseline values after release of increased IAP, although minute ventilation remained increased almost to the same extent as during the increase in IAP to 12 mmHg (approximately 40% compared with baseline; table 2). Therefore, we suggest that the decrease in μHbO_2 during increased IAP was mediated primarily by the increase in IAP, whereas the increases in minute ventilation after desufflation (control period) to maintain ET_{CO_2} within the physiologic range did not affect μHbO_2 to a measurable extent. This view is supported by our finding of increased peak and mean airway pressures during the increase in IAP to 8 and 12 mmHg, respectively, whereas both pressures returned to their respective baseline levels after release of increased IAP (table 2).

Clinical Implications

The gut is exceptionally susceptible to hypoperfusion and hence impaired oxygen supply during trauma and stress,⁴²⁻⁴⁴ e.g., it is most sensitive to the increase in IAP.⁴⁵ The gut shows evidence of end-organ damage during intraabdominal hypertension well before the appearance of any classic clinical signs, *i.e.*, renal, pulmonary, and cardiovascular symptoms.^{45,46} Therefore, early recognition of compromised oxygen availability due to increased IAP and on-time intervention are recommended. This highlights the need for diagnostic tools to reliably monitor splanchnic oxygenation in clinically susceptible patients. As shown in our study, reflectance spectrophotometry meticulously measured μHbO_2 during the various stages of increased IAP. Because none of our patients developed clinically significant signs of gastrointestinal complications in the postoperative period, it seems unlikely that a short-term increase in IAP within the pressure and time limits in our study is sufficient to cause significant harm in patients with American Society of Anesthesiologists physical status class I or II. However, whether this also applies to prolonged surgical procedures and especially to patients with compromised cardiorespiratory function has yet to be determined.

To conclude, we detected significant reductions in μHbO_2 at low levels of IAP despite unchanged systemic oxygen saturation. These findings suggest that levels of IAP applied on a routine basis during laparoscopic surgery might actually compromise splanchnic oxygenation.

References

1. Malbrain ML: Abdominal pressure in the critically ill: Measurement and clinical relevance. *Intensive Care Med* 1999; 25:1453-8
2. Sugerman HJ, Bloomfield GL, Saggi BW: Multisystem organ failure secondary to increased intraabdominal pressure. *Infection* 1999; 27:61-6
3. Carrico CJ, Meakins JL, Marshall JC, Fry D, Maier RV: Multiple-organ-failure syndrome. *Arch Surg* 1986; 121:196-208
4. Parrillo JE: Pathogenetic mechanisms of septic shock. *N Engl J Med* 1993; 328:1471-7
5. Hinshaw LB: Sepsis/septic shock: Participation of the microcirculation: An abbreviated review. *Crit Care Med* 1996; 24:1072-8
6. De Backer D, Creteur J, Preiser JC, Dubois MJ, Vincent JL: Microvascular blood flow is altered in patients with sepsis. *Am J Respir Crit Care Med* 2002; 166:98-104
7. Doig CJ, Sutherland LR, Dean Sandham J, Fick GH, Verhoef M, Meddings JB: Increased intestinal permeability is associated with the development of multiple organ dysfunction syndrome in critically ill ICU patients. *Am J Respir Crit Care Med* 1998; 158:444-51
8. Diebel LN, Dulchavsky SA, Brown WJ: Splanchnic ischemia and bacterial translocation in the abdominal compartment syndrome. *J Trauma* 1997; 43:852-5
9. Caldwell CB, Ricotta JJ: Changes in visceral blood flow with elevated intraabdominal pressure. *J Surg Res* 1987; 43:14-20
10. Bongard F, Pianim N, Dubez S, Klein SR: Adverse consequences of increased intra-abdominal pressure on bowel tissue oxygen. *J Trauma* 1995; 39:519-24
11. Blobner M, Bogdanski R, Kochs E, Henke J, Findeis A, Jelen-Esselborn S: Effects of intraabdominally insufflated carbon dioxide and elevated intraabdominal pressure on splanchnic circulation: An experimental study in pigs. *ANESTHESIOLOGY* 1998; 89:475-82
12. Frank KH, Kessler M, Appelbaum K, Dümmler W: The Erlangen micro-lightguide spectrophotometer EMPHO I. *Phys Med Biol* 1989; 34:1883-900
13. Temmesfeld-Wollbrück B, Szalay A, Mayer K, Olschewski H, Seeger W, Grimminger F: Abnormalities of gastric mucosal oxygenation in septic shock: Partial responsiveness to doxepamine. *Am J Respir Crit Care Med* 1998; 157:1586-92
14. Fournell A, Schwarte LA, Scheeren TWL, Kindgen-Milles D, Feindt P, Loer SA: Clinical evaluation of reflectance spectrophotometry for the measurement of gastric microvascular oxygen saturation in patients undergoing cardiopulmonary bypass. *J Cardiothorac Vasc Anesth* 2002; 16:576-81
15. Fournell A, Schwarte LA, Kindgen-Milles D, Müller E, Scheeren TWL: Assessment of microvascular oxygen saturation in gastric mucosa in volunteers breathing continuous positive airway pressure. *Crit Care Med* 2003; 31:1705-10
16. Kavarana MN, Frumento RJ, Hirsch AL, Oz MC, Lee DC, Bennett-Guerrero E: Gastric hypercarbia and adverse outcome after cardiac surgery. *Intensive Care Med* 2003; 29:742-8
17. Fournell A, Scheeren TWL, Schwarte LA: PEEP decreases oxygenation of the intestinal mucosa despite normalization of cardiac output. *Adv Exp Med Biol* 1998; 454:435-40
18. Scheeren TWL, Schwarte LA, Loer SA, Picker O, Fournell A: Dopexamine but not dopamine increases gastric mucosal oxygenation during mechanical ventilation in dogs. *Crit Care Med* 2002; 30:881-7
19. Hasibeder W, Germann R, Sparr H, Haisjackl M, Friesenecker B, Luz G, Pernthaler H, Pfaller K, Maurer H, Ennemoser O: Vasomotion induces regular major oscillations in jejunal mucosal tissue oxygenation. *Am J Physiol* 1994; 266:G978-86
20. Machens HG, Pallua N, Mailaender P, Pasel J, Frank KH, Reimer R, Berger A: Measurements of tissue blood flow by the hydrogen clearance technique (HCT): A comparative study including laser Doppler flowmetry (LDF) and the Erlangen micro-lightguide spectrophotometer (EMPHO). *Microsurgery* 1995; 16:808-17
21. Severinghaus JW: Continuous positive airway pressure, shock therapy, and gastric mucosal oxygenation. *Crit Care Med* 2003; 31:1870-1
22. Schilling MK, Redaelli C, Krahenbuhl L, Signer C, Buchler MW: Splanchnic microcirculatory changes during CO_2 laparoscopy. *J Am Coll Surg* 1997; 184:378-82
23. Rist M, Rauh R, Klingel R, Jacobi K, Siebzehrubel E: Hemodynamic effects of pneumoperitoneum in lithotomy position. *Zentralbl Chir* 2001; 126:75-9
24. Bhavani-Shankar K, Steinbrook RA, Brooks DC, Datta S: Arterial to end-tidal carbon dioxide pressure difference during laparoscopic surgery in pregnancy. *ANESTHESIOLOGY* 2000; 93:370-3
25. Sefr R, Puskailer K, Frana J, Penka I: Effect of carbon dioxide pneumoperitoneum on selected parameters of the acid-base equilibrium in laparoscopic cholecystectomy. *Rozhl Chir* 2001; 80:206-12
26. Mäkinen MT, Heinonen PO, Klemola UM, Yli-Hankala A: Gastric air tonometry during laparoscopic cholecystectomy: A comparison of two PCO_2 levels. *Can J Anaesth* 2001; 48:121-8
27. Sugrue M, Jones F, Lee A, Buist MD, Deane S, Bauman A, Hillman K: Intraabdominal pressure and gastric intramucosal pH: Is there an association? *World J Surg* 1996; 20:988-91
28. Ivatury RR, Porter JM, Simon RJ, Islam S, John R, Stahl WM: Intra-abdominal hypertension after life-threatening penetrating abdominal trauma: Prophyl-

laxis, incidence, and clinical relevance to gastric mucosal pH and abdominal compartment syndrome. *J Trauma* 1998; 44:1016-21

29. Diamant M, Benumof JL, Saidman IJ: Hemodynamics of increased intra-abdominal pressure: Interaction with hypovolemia and halothane anesthesia. *ANESTHESIOLOGY* 1978; 48:23-7

30. Kashtan J, Green JF, Parsons EQ, Holcroft JW: Hemodynamic effect of increased abdominal pressure. *J Surg Res* 1981; 30:249-55

31. Robotham JL, Wise RA, Bromberger-Barnea B: Effects of changes in abdominal pressure on left ventricular performance and regional blood flow. *Crit Care Med* 1985; 13:803-9

32. Ivatury RR, Diebel L, Porter JM, Simon RJ: Intra-abdominal hypertension and the abdominal compartment syndrome. *Surg Clin North Am* 1997; 77:783-800

33. Kelman GR, Swapp GH, Smith I, Benzie RJ, Gordon NL: Cardiac output and arterial blood-gas tension during laparoscopy. *Br J Anaesth* 1972; 44:1155-62

34. Richardson JD, Trinkle JK: Hemodynamic and respiratory alterations with increased intra-abdominal pressure. *J Surg Res* 1976; 20:401-4

35. Andersson L, Lindberg G, Bringman S, Ramel S, Anderberg B, Oderberg-Werman S: Pneumoperitoneum versus abdominal wall lift: Effects on central hemodynamics and intrathoracic pressure during laparoscopic surgery. *Acta Anaesthesiol Scand* 2003; 47:838-46

36. Cheatham ML, White MW, Sagraves SG, Johnson JL, Block EJJ: Abdominal perfusion pressure: A superior marker in the assessment of the abdominal compartment syndrome. *J Trauma* 2000; 49:621-7

37. Lehtipalo S, Biber B, Frojse R, Amerlov C, Johansson G, Winso O: Effects

of dopexamine and positive end-expiratory pressure on intestinal blood flow and oxygenation: The perfusion pressure perspective. *Chest* 2003; 124:688-98

38. Ishizaki Y, Bandai Y, Shimomura K, Abe H, Ohtomo Y, Idezuki Y: Changes in splanchnic blood flow and cardiovascular effects following peritoneal insufflation of carbon dioxide. *Surg Endosc* 1993; 7:420-3

39. Gudmundsson FF, Gislason HG, Dicko A, Horn A, Viste A, Grong K, Svanes K: Effects of prolonged increased intra-abdominal pressure on gastrointestinal blood flow in pigs. *Surg Endosc* 2001; 15:854-60

40. Yavuz Y, Ronning K, Lyng O, Marvik R, Gronbech JE: Effect of increased intraabdominal pressure on cardiac output and tissue blood flow assessed by color-labeled microspheres in the pig. *Surg Endosc* 2001; 15:149-55

41. Akca O, Doufas AG, Morioka N, Iscoe S, Fisher J, Sessler DI: Hypercapnia improves tissue oxygenation. *ANESTHESIOLOGY* 2002; 97:801-6

42. Mythen MG, Webb AR: The role of gut mucosal hypoperfusion in the pathogenesis of post-operative organ dysfunction. *Intensive Care Med* 1994; 20:203-9

43. Hamilton-Davies C, Mythen MG, Salmon JB, Jacobson D, Shukla A, Webb AR: Comparison of commonly used clinical indicators of hypovolaemia with gastrointestinal tonometry. *Intensive Care Med* 1997; 23:276-81

44. Price HL, Deutsch S, Marshall BE, Stephen GW, Behar MG, Neufeld GR: Hemodynamic and metabolic effects of hemorrhage in man, with particular reference to the splanchnic circulation. *Circ Res* 1966; 18:469-74

45. Saggi BH, Sugerman HJ, Ivatury RR, Bloomfield GL: Abdominal compartment syndrome. *J Trauma* 1998; 45:597-609

46. Sieh KM, Chu KM, Wong J: Intra-abdominal hypertension and abdominal compartment syndrome. *Langenbecks Arch Surg* 2001; 386:53-61