

# Do Indomethacin and Propofol Cause Cerebral Ischemic Damage?

## Diffusion-weighted Magnetic Resonance Imaging in Patients Undergoing Craniotomy for Brain Tumors

Mads Rasmussen, M.D., Ph.D.,\* Leif Østergaard, M.Sc., M.D., Ph.D.,† Niels Juul, M.D.,‡ Carsten Gyldensted, M.D., Ph.D.,§ Peter V. Poulsen, M.Sc., Ph.D.,† Georg E. Cold, M.D., Ph.D.¶

**Background:** Diffusion-weighted magnetic resonance imaging was used to determine whether indomethacin and propofol induce cerebral ischemic damage in patients undergoing craniotomy for cerebral tumors. As a secondary aim, the authors investigated whether low jugular bulb oxygen saturation values were associated with brain parenchymal damage as evaluated by diffusion-weighted imaging.

**Methods:** Nine patients subjected to craniotomy for supratentorial brain tumors in propofol-fentanyl anesthesia were studied. Magnetic resonance imaging including diffusion- and perfusion-weighted and structural sequences were performed (1) on the day before surgery, (2) before and (3) 20 min after administration of indomethacin (bolus of 0.2 mg/kg followed by infusion of 0.2 mg · kg<sup>-1</sup> · h<sup>-1</sup>) in the propofol-fentanyl-anesthetized patient, and (4) 2 days after surgery. Apparent diffusion coefficient maps were calculated. Jugular bulb oxygen saturation, arteriovenous oxygen difference, mean arterial blood pressure, and arterial oxygen and carbon dioxide tensions were measured simultaneously with the magnetic resonance examinations performed during anesthesia.

**Results:** No ischemic lesions were detected in the diffusion-weighted or apparent diffusion coefficient images. A nonsignificant decrease in jugular bulb oxygen saturation from 51% (range, 40–61%) to 43% (range, 37–63%) and increase in arteriovenous oxygen difference from 4.4 mm (range, 2.7–4.6 mm) to 4.7 mm (range, 2.9–5.2 mm) was observed after indomethacin administration.

**Conclusion:** Administration of indomethacin during propofol anesthesia is not associated with evidence of ischemic damage in patients with brain tumors, as evaluated by diffusion-weighted imaging.

INDOMETHACIN, a fatty acid cyclooxygenase inhibitor, is a cerebral vasoconstrictor and reduces cerebral blood flow (CBF) without affecting cerebral oxygen metabolism (CMRO<sub>2</sub>) in clinical<sup>1</sup> and experimental studies.<sup>2,3</sup> Clinical studies have shown that injection of indometh-

acin effectively reduces intracranial pressure (ICP) and improves cerebral perfusion pressure in tumor patients during isoflurane anesthesia<sup>4</sup> and in patients with severe head injury.<sup>5-7</sup> In spite of the beneficial effects in decreasing ICP and improving cerebral perfusion pressure, the use of indomethacin is still controversial because of the presumed risk of inducing severe cerebral ischemia in patients with brain pathology. Previous clinical reports have not demonstrated evidence of indomethacin-induced cerebral ischemic damage. However, global values of CBF<sup>4,6,7</sup> below 30 ml · 100g<sup>-1</sup> · min<sup>-1</sup> and jugular bulb oxygen saturation (Sjvo<sub>2</sub>) values<sup>4,6,8</sup> below 45% were reported, indicating a risk of regional cerebral ischemia.

Propofol has been suggested as the drug of choice for brain tumor surgery.<sup>9</sup> However, several reports have demonstrated that low jugular bulb oxygen saturations are believed to indicate global cerebral hypoperfusion or cerebral ischemia during brain tumor surgery in propofol anesthesia.<sup>9-11</sup> Although clinical signs of propofol-induced cerebral ischemia in these patients have never been reported,<sup>12</sup> no study has evaluated whether propofol induces regional ischemic damage in patients with space-occupying brain pathology.

*Diffusion-weighted imaging* (DWI) is an established magnetic resonance imaging (MRI) technique that is widely used in the diagnosis of acute stroke because of its extreme sensitivity to acute ischemic damage.<sup>13,14</sup> The technique measures the diffusion of water molecules, and because of the altered hindrance of their brownian motions caused by cytotoxic edema after adenosine triphosphate depletion, DWI hyperintensities appear within minutes after ischemic tissue damage.<sup>15</sup> In the current study, DWI was used to determine whether indomethacin and propofol induces cerebral ischemic damage defined as DWI hyperintensities in patients subjected to craniotomy for cerebral tumors. As a secondary aim, we investigated whether low Sjvo<sub>2</sub> values were associated with ischemic tissue damage as evaluated by DWI.

## Materials and Methods

The Research Ethics Committee of the County of Aarhus, Denmark, approved the study. The investigation was conducted in accordance with the "Note for Guid-

\* Research Fellow, Department of Neuroanesthesia, Århus University Hospital and Department of Anesthesia and Intensive Care, Viborg County Hospital, Viborg, Denmark. † Associate Professor, § Professor, Department of Neuroradiology, ‡ Staff Anesthesiologist, Department of Neuroanesthesia, Århus University Hospital. ¶ Associate Professor, Department of Neuroradiology, and Assistant Professor, Department of Neuroanesthesia, Århus University Hospital.

Received from the Department of Neuroanesthesia, Århus University Hospital, Århus, Denmark. Submitted for publication November 26, 2003. Accepted for publication June 25, 2004. Supported by grants from The Western Danish Research Forum for Health Sciences, Århus, Denmark; Oberstinde Jensa de La Cours's Foundation, Copenhagen, Denmark; the Danish Medical Research Council, Copenhagen, Denmark (Dr. Østergaard); and the Danish National Research Foundation, Copenhagen, Denmark (Drs. Østergaard and Poulsen).

Address reprint requests to Dr. Rasmussen: Department of Neuroanesthesia, Århus Kommunehospital, Århus University Hospital, Nørrebrogade 44, 8000 Århus C, Denmark. Address electronic mail to: maras@akh.aaa.dk. Individual article reprints may be purchased through the Journal Web site, www.anesthesiology.org.

ance on Good Clinical Practice.” Monitoring of the study was performed by the Good Clinical Practice Unit, Århus University Hospital, Århus, Denmark.

#### Patient Population

After written informed consent was obtained, nine patients (American Society of Anesthesiologists physical status I or II) undergoing supine-positioned elective craniotomy for supratentorial brain tumors of 3 cm or larger (measured as largest diameter in any plane on magnetic resonance [MR] images) were included in the study. Exclusion criteria were age younger than 18 yr or older than 70 yr, pregnancy or nursing, history of allergic reactions to prostaglandin inhibitors, arterial hypertension (diastolic pressure > 110 mmHg), cardiac failure (New York Heart Association class III or IV), moderate to severe chronic pulmonary insufficiency, renal or hepatic dysfunction/disease, peptic ulcer, and treatment with indomethacin or other nonsteroidal antiinflammatory drugs.

#### Experimental Protocol

The first MRI examination was performed in the awake patient the day before surgery. Magnetic resonance imaging sequences consisted of a three-plane localizer followed by three axial, anatomical scans: a three-dimensional T1-weighted spoiled gradient recall sequence, a T2-weighted sequence, and a fluid-attenuated inversion recovery (FLAIR) sequence, to obtain images for outlining the extent of tumor, edema, and older (> 12 h) ischemic lesions. All three sequences were recorded in a 24 × 24-cm field of view, with image acquisition parameters (time of repetition – TR/time of echo – TE/time of inversion – TI) being TR/TE = 30/2.8 ms (ms), flip angle 20°, TR/TE = 4,000/102 ms, and TR/TE/TI = 9,000/120/2,200 ms. The slice thickness was 1.2 mm (120 slices) for the three-dimensional spoiled gradient recall sequence and 5 mm with a 1.5-mm gap (24 slices in 256 × 256 resolution) for the T2 and FLAIR sequences. To detect acute ischemia, an axial DWI sequence was acquired (spin-echo echo planar imaging, TR/TE = 5,000/81.5 ms, slice number and dimensions as for the FLAIR/T2 scans in a 96 × 96 resolution). The diffusion-

weighted scan consisted of one unweighted scan followed by three scans with diffusion-weighting gradients applied in three orthogonal directions (diffusion weighting factor  $b = 1,000$ ). Based on this, maps of the apparent diffusion coefficient (ADC) were calculated. In cases where lesions are observed on DWI, ADC allows acute lesions (lesion ADC is lower than that of normal tissue up to 5 days after an infarct) to be distinguished from older lesions or edema (ADC is higher than that of normal tissue in vasogenic edema and necrosis for detection of previous cerebral injuries or acute cerebral ischemia).<sup>16,17</sup>

Perfusion imaging was performed by dynamic (spin-echo echo planar imaging) tracking of a bolus of 0.2 mmol/kg gadolinium-DTPA (Magnevist®; Schering AG, Berlin/Bergkamen, Germany), injected at a rate of 5 ml/s, with an 8-s delay, using an MR-compatible power injector (Medrad, Pittsburgh, PA). This bolus was immediately followed by injection of an equal volume of physiologic saline, also at a rate of 5 ml/s. Eleven or twelve slices were obtained, covering the tumor area. The acquisition parameters were TR/TE = 1,500/75 ms, flip angle 20°, 96 × 96 resolution, 24 cm field of view, 5-mm slice thickness, and 1.5-mm interslice gap with a 55-s acquisition time.

A postcontrast T1-weighted spoiled gradient recall sequence was acquired for determination of tumor-contrast enhancement and to assess tumor grade. The duration of the examination was 30–35 min.

On the day of surgery, the patient was anesthetized and transported to the MR scanner. The second MRI examination was performed before administration of indomethacin to evaluate possible ischemic effects of the initial propofol–fentanyl anesthesia (MRI was performed approximately 70 min after induction of anesthesia). Indomethacin was then administered as an intravenous bolus dose of 0.2 mg/kg followed by infusion at 0.2 mg · kg<sup>-1</sup> · h<sup>-1</sup>. The third MRI examination was initiated 5 min after administration of the indomethacin bolus dose, with the DWI sequence performed 20 min after indomethacin administration. Both MRI examinations consisted of the same sequences as the initial scan (see above), except for the FLAIR sequence, which

**Table 1. Patient Characteristics, Histopathologic Diagnosis, and Neuroradiologic Data**

Patient No.	Age/Sex	Tumor Type	Tumor Localization	Size, cm <sup>3</sup>	Midline Shift, mm
1	41/M	Neuroepithelial tumor	Frontal	6.5	0
2	29/M	Oligodendroglioma, grade 3	Frontoparietal	73.3	3
3	57/M	Oligodendroglioma, grade 2	Temporal	69.1	6
4	63/F	Unspecified tumor	Temporal	6.3	0
5	57/F	Oligodendroglioma, grade 2	Temporo-occipital	47.1	0
6	57/F	CNS lymphoma	Temporal	9.4	0
7	68/M	Glioblastoma, grade 4	Parieto-occipital	28.3	3
8	48/M	Oligodendroglioma, grade 2	Temporofrontal	69.1	2
9	53/M	Gliosarcoma	Temporoparietal	113.1	12

CNS = central nervous system.

**Table 2. Physiologic Data**

Patient No.	MRI 2 Propofol-Fentanyl				
	MABP, mmHg	Sjvo <sub>2</sub> , %	AVDo <sub>2</sub> , mm	Paco <sub>2</sub> , mmHg	Pao <sub>2</sub> , mmHg
1	74	53.6	4.2	41	211
2	117	49.8	4.6	30	326
3	65			36	156
4	89	51.1	3.3	31	240
5	99	40.2	4.6	30	231
6	113	50.5	4.5	33	275
7	93	61.1	2.7	34	85
8	68	50.9	4.5	38	207
9	100	52.9	3.5	39	137
Median (range)	93 (65–117)	51 (40–61)	4.4 (2.7–4.6)	34 (30–41)	211 (85–326)
P value					

Physiologic parameters were measured before and after indomethacin administration in the propofol-fentanyl-anesthetized patients. MRI 2 refers to values measured immediately before the second magnetic resonance imaging examination. MRI 3 refers to values measured immediately after the third magnetic resonance imaging examination. Data are presented as "raw" data, median and ranges. Paired analysis was performed with Wilcoxon's signed rank test.

AVDo<sub>2</sub> = arteriovenous oxygen difference; MABP = mean arterial blood pressure; Paco<sub>2</sub> = arterial carbon dioxide tension; Pao<sub>2</sub> = arterial oxygen tension; Sjvo<sub>2</sub> = jugular bulb oxygen saturation.

would be insensitive to acute ischemic lesions. The indomethacin infusion was terminated after completion of the third MRI examination. Data regarding mean arterial blood pressure, Sjvo<sub>2</sub>, arteriovenous oxygen difference (AVDo<sub>2</sub>), arterial oxygen tension (Pao<sub>2</sub>), and arterial carbon dioxide tension (Paco<sub>2</sub>) was collected immediately before commencement of the second MRI examination and again immediately after termination of the third MRI examination. The duration of the two examinations, including indomethacin administration, was approximately 60 min. After completion of the MRI examinations, the patient was transported to the operating room for surgery. The fourth MRI examination was performed in the awake patient 2 days after surgery to detect possible "late" ischemic lesions, using the same MRI protocol as the first MRI examination.

#### *Tumor size, Tumor Localization, and Histopathologic Diagnosis*

Tumor size (calculated from the modified spheric volume equation:  $\frac{4}{3} \times \pi \times r_1 \times r_2 \times r_3$ ), tumor localization, and the degree of midline shift were determined by an experienced neuroradiologist (C. G.) from the structural MR images obtained from the first MRI examination. The histopathologic diagnosis was obtained from the neuropathology report.

#### *Anesthesia and Monitoring*

The patients were premedicated with diazepam (5–15 mg) orally 1 h before anesthesia. For induction, propofol (1.2–2.5 mg/kg) supplemented with fentanyl (2–4  $\mu\text{g} \cdot \text{kg}^{-1} \cdot \text{h}^{-1}$ ) was used. Cisatracurium (0.2 mg/kg) was administered to facilitate tracheal intubation. Anesthesia was maintained with propofol (6–12  $\text{mg} \cdot \text{kg}^{-1} \cdot \text{h}^{-1}$ ) and fentanyl (1.5–3  $\mu\text{g} \cdot \text{kg}^{-1} \cdot \text{h}^{-1}$ ).

Neuromuscular blockade was maintained with cisatracurium and monitored by train-of-four stimulation. Controlled ventilation (fraction of inspired oxygen [FIO<sub>2</sub>] 50–60% by oxygen-air) was applied, and the patients were ventilated with Paco<sub>2</sub> and Pao<sub>2</sub> levels that we attempted to keep between 30–40 mmHg and greater than 100 mmHg, respectively. A decrease in systolic pressure exceeding 20 mmHg compared with the preoperative level was treated with 5–10 mg intravenous ephedrine. Normal saline, 15 ml/kg, was infused for the first hour after induction, followed by normal saline at 2–4  $\text{ml} \cdot \text{kg}^{-1} \cdot \text{h}^{-1}$ . Moreover, to counteract the blood pressure decrease observed after induction of anesthesia, 6% hydroxyethyl starch, 500 ml, was infused over a period of 30 min. Monitoring consisted of continuous electrocardiography, pulse oximetry (Datex<sup>®</sup> AS3; Datex, Helsinki, Finland), and rectal temperature monitoring. After induction of anesthesia, a radial artery catheter was inserted for continuous mean arterial pressure monitoring and blood sampling. A jugular bulb catheter was inserted retrogradely into the internal jugular vein for jugular bulb pressure monitoring and jugular venous blood sampling. The tip of the catheter was placed high in the jugular bulb, and the position was confirmed by x-ray control. After stable physiologic conditions were ensured, the patient was transferred to the MR scanner. During the MRI examinations, hemodynamic parameters were continuously monitored with an MR-compatible monitor, and controlled ventilation was applied with an MR-compatible ventilator.

#### *Postoperative Clinical Evaluation*

Observation of clinical signs of cerebral ischemic damage associated with the anesthetic regimen and administration of indomethacin was based on a thorough neu-

Table 2. Continued

MABP, mmHg	Sjvo <sub>2</sub> , %	MRI 3 Propofol-Fentanyl + Indomethacin		
		AVDO <sub>2</sub> , mm	Paco <sub>2</sub> , mmHg	Pao <sub>2</sub> , mmHg
81	42.7	4.9	40	246
122	48.5	4.7	29	338
76			36	178
79	63.1	2.9	31	307
104	39.9	4.6	31	261
98	39.4	4.7	31	348
99	52.6	3.5	33	108
74	44.2	4.9	38	317
110	37.3	5.2	37	109
98 (74-122)	43 (37-63)	4.7 (2.9-4.9)	33 (29-40)	263 (108-348)
0.41	0.12	0.075	0.31	0.03

rologic examination performed by a neurosurgeon 1 or 2 days after the operation.

#### Data Analysis and Statistics

Diffusion-weighted images (together with ADC maps) and FLAIR images were reviewed systematically, supplemented by the use of T1- and T2-weighted images by a board-certified neuroradiologist with extensive experience in interpretation of DWI images (C. G.). The neuroradiologist evaluated the DWI and ADC maps from the four MRI examinations obtained in each patient in random order and was blinded to the sequence in which they appeared. In all cases, DWI and ADC maps were analyzed first, followed by FLAIR images. A DWI scan was considered positive if the scan revealed an area of hyperintensity on DWI and hypointensity on ADC maps not present in the first MRI examination, thus signifying a newly developed acute ischemic lesion.

Physiologic parameters are presented as "raw" data and median values and ranges. Paired analysis of physiologic parameters obtained before and after indomethacin administration was performed with the Wilcoxon signed rank test. Statistical significance was considered at the 5% level.

#### Perfusion-weighted Information

The purpose of the perfusion-weighted information was to determine the effects of indomethacin and propofol on cerebral blood flow physiology. These results will be presented elsewhere.

## Results

Patient characteristics, neuroradiologic data (tumor size, tumor localization, and midline shift), and histopathologic diagnoses are given in table 1. In patient 5, it was not possible for the neuropathologist to determine the tumor type.

Induction doses of fentanyl and propofol were 2.5 (1.8-3.2)  $\mu\text{g}/\text{kg}$  and 1.2 (0.7-1.80)  $\text{mg}/\text{kg}$ , respectively, and maintenance doses were 1.8 (1.4-2.20)  $\mu\text{g} \cdot \text{kg}^{-1} \cdot \text{h}^{-1}$  and

7.0 (4.5-10)  $\text{mg} \cdot \text{kg}^{-1} \cdot \text{h}^{-1}$ , respectively. The interval from induction of anesthesia to DWI was 86 (71-91) min.

#### Physiologic Parameters

Changes in physiologic parameters before and after indomethacin administration are demonstrated in table 2. In patient 3, it was not possible to insert a jugular bulb catheter; therefore, no Sjvo<sub>2</sub> or AVDO<sub>2</sub> measurements were performed. Except for patients 4 and 6, all patients experienced an increase in mean arterial blood pressure after indomethacin administration; however, there was no statistically significant difference in the paired analysis. There was a nonsignificant tendency toward lower Sjvo<sub>2</sub> values ( $P = 0.12$ ) and higher AVDO<sub>2</sub> ( $P = 0.075$ ) values after administration of indomethacin. The Pao<sub>2</sub> values were higher during the third MRI examination ( $P = 0.03$ ).

#### MR Imaging of Ischemic Lesions

Ischemic lesions were not detected in the DWI, ADC, and FLAIR images in any of the nine patients. An example of DWI and FLAIR images obtained in a patient with gliosarcoma is shown in figure 1.

#### Postoperative Neurologic Evaluation

Because of insufficient emergence from anesthesia, probably caused by 5 h of surgery and hence anesthesia, patient 2 was transported to the neurointensive ward for further artificial ventilation. Three hours later, the patient underwent extubation and was fully awake and conscious, without neurologic symptoms. The remaining patients had an uneventful emergence from anesthesia and underwent extubation in the operating room. The patients were fully awake and conscious before transfer to the postoperative ward. Based on the postoperative neurologic examination by the neurosurgeon, none of the patients experienced any aggravation of their preoperative neurologic deficits (table 3).



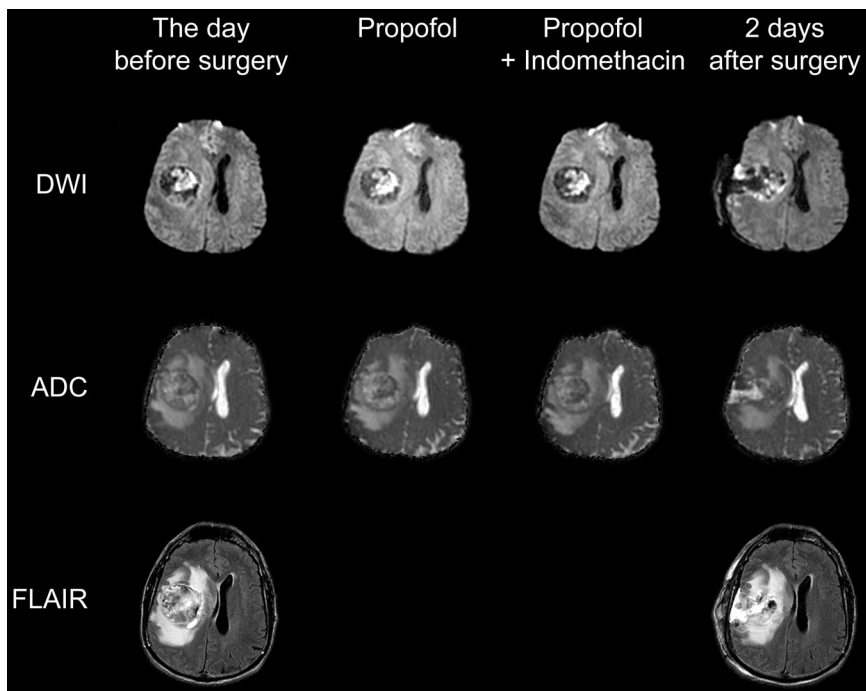


Fig. 1. Magnetic resonance images of a 55-yr-old man with a gliosarcoma located in the right temporoparietal region. Diffusion-weighted imaging (DWI) sequences (top row) and apparent diffusion coefficient (ADC) maps (middle row) were obtained (1) on the day before surgery, (2) before and (3) 20 min after administration of indomethacin (bolus of 0.2 mg/kg followed by infusion of  $0.2 \text{ mg} \cdot \text{kg}^{-1} \cdot \text{h}^{-1}$ ) in the propofol-fentanyl-anesthetized patient, and (4) 2 days after surgery. Fluid attenuated inversion recovery (FLAIR) sequences (bottom row) were performed (1) on the day before surgery and (2) 2 days after surgery. Despite considerable mass effect of the tumor, DWI and FLAIR images revealed no ischemic tissue damage. The finger-shaped surgical cavity appears *black* on DWI and *white* on ADC pictures in the last column (2 days after surgery). The area in the right frontal operculum just anterior to the surgical cavity, which appears *white* on DWI and *black* on ADC images, represents a small cortical lesion during the partial tumor resection.

## Discussion

Experimental data<sup>18</sup> and clinical studies<sup>4-7</sup> suggest that indomethacin may be useful in the management of increased ICP. The vasoconstriction and associated reduction in CBF induced by indomethacin decrease elevated ICP and improve cerebral perfusion pressure. However, the use of indomethacin is controversial because the indomethacin-induced decrease in CBF may lead to critical hypoperfusion and ischemic damage. Nilsson *et al.*<sup>18</sup> reported that indomethacin elicited progressive changes in  $\text{AVDO}_2$  and pH and slowing of the electroencephalogram, suggesting development of cerebral ischemia in a porcine model of intracranial hypertension. In patients with severe head injury and isoflurane anesthetized patients with cerebral tumors, indomethacin administered as a bolus dose alone or followed by infusion caused an average decrease in CBF to  $31\text{--}20 \text{ ml} \cdot 100 \text{ g}^{-1} \cdot \text{min}^{-1}$  accompanied by increases in arteriovenous difference of lactate and  $\text{AVDO}_2$  and a decrease in  $\text{Sjvo}_2$  values.<sup>4,6,7</sup> In the current study,  $\text{Sjvo}_2$  averaged 43%, which is in accordance with a study in propofol-fentanyl-anesthetized tumor patients where a continuous indomethacin infusion was associated with an average  $\text{Sjvo}_2$  value of 46%.<sup>8</sup> The reported low CBF and  $\text{Sjvo}_2$  and high  $\text{AVDO}_2$  values in the above-mentioned studies suggest that the level of CBF under these conditions is critically low and eventually surpasses ischemic threshold. To our knowledge, this is the first study that addresses the question whether indomethacin induces ischemic brain damage. Using DWI, we were not able to demonstrate any ischemic brain lesions after indomethacin administration. It is important to note that DWI is not sensitive to ischemia *per se* but detects ischemic injury. In view of the low  $\text{Sjvo}_2$

values, we cannot rule out that ischemia occurred in these patients. However, our results suggest that CBF was not reduced to such an extent that ischemic damage occurred on the DWI images. We observed a minor increase in  $\text{AVDO}_2$ , suggesting limited decrease in CBF after indomethacin. This observation is in contrast to previous studies in which indomethacin caused a pronounced decrease in CBF<sup>4,7</sup> but agree with the findings of a recent study in propofol-fentanyl-anesthetized patients undergoing craniotomy.<sup>8</sup> We suggest that the limited reduction in CBF after indomethacin may be explained by the propofol-induced cerebral vasoconstriction.<sup>8</sup> Propofol may hence have caused vasoconstriction of the cerebral vessels to the extent that they had a limited capacity to constrict further during the influence of indomethacin. As a note of caution, our sample size is relatively small, and patient 4 seems to be an outlier with an  $\text{Sjvo}_2$  of 63%; the removal of this value would have

Table 3. Preoperative and Postoperative Neurologic Deficits

Patient No.	Preoperative Neurologic Deficits	Postoperative Neurologic Deficits
1	None	None
2	None	None
3	Mild left hemiparesis	Mild left hemiparesis
4	Epilepsy, well controlled with antiepileptic drugs	No seizures
5	Severe headache	None
6	None	None
7	None	None
8	None	None
9	Left facial nerve palsy	Left facial nerve palsy

Postoperative evaluation was performed by the neurosurgeon 1–2 days after surgery.

resulted in a significant decrease in  $Sjvo_2$  after indomethacin administration. Therefore, interpretation of the  $Sjvo_2$  and  $AVDO_2$  values after indomethacin must be cautious, and we cannot exclude a type II error in this study.

Diffusion-weighted imaging is an established MRI technique that is very sensitive to acute cerebral ischemic damage. In experimental stroke models, ischemic regions become hyperintense on DWI within minutes,<sup>15,19</sup> and this seems to be similar in humans, where DWI lesions have been detected as early as 39 min after stroke onset.<sup>20</sup> Early ischemic brain injury detected by DWI correlates with postmortem infarction,<sup>21</sup> acute and chronic clinical severity,<sup>22</sup> and clinical outcome<sup>23,24</sup> and can approach a 100% detection rate for ischemic lesions in the hyperacute period.<sup>25,26</sup>

The DWI measurements were performed 20 min after indomethacin administration. We cannot exclude that a longer duration of indomethacin infusion or another (longer) time interval between indomethacin administration and DWI acquisition would have produced different acute DWI results. However, previous studies have demonstrated that intravenously administered indomethacin elicits a pronounced decrease in CBF and mean cerebral artery blood flow velocity within 30–60 s after administration.<sup>4,8</sup> Therefore, ischemic changes on the postindomethacin DWI are time and flow dependent, and this examination therefore rules out any immediate damage with uncertainty. Although we believe that the damage would coincide with maximum pharmacologic action, we cannot exclude that later damage would escape this examination. However, this would be detected on the follow-up scan (structural as well as DWI images) performed 2 days after the operation.

Clinical<sup>27,28</sup> and experimental studies<sup>29</sup> have demonstrated that propofol elicits a decrease in CBF and  $CMRO_2$ . Propofol is widely used for neurosurgical procedures, and a recent study demonstrated that ICP is lower and cerebral perfusion pressure is higher during propofol-fentanyl anesthesia as compared with isoflurane or sevoflurane.<sup>9</sup> However, a high incidence of  $Sjvo_2$  values less than 50% have been reported in propofol-anesthetized brain tumor patients<sup>8–11</sup> and nonneurosurgical patients.<sup>30</sup> The reported low  $Sjvo_2$  values reflect an imbalance between global cerebral oxygen supply and demand and may be indicative of cerebral hypoperfusion and ischemia. A number of studies have demonstrated that the percentage reduction of CBF after administration of propofol is larger than the reduction of  $CMRO_2$ .<sup>10,31,32</sup> These findings suggest that propofol may have a direct cerebral vasoconstricting effect, beyond the associated decrease in  $CMRO_2$  leading to a decrease of the CBF: $CMRO_2$  ratio. The current study, however, demonstrates for the first time that low  $Sjvo_2$  values are not associated with ischemic damage as evaluated with DWI. Furthermore, no aggravation of clinical neurologic signs of cerebral ischemia were disclosed in the current

study or in clinical studies of patients with cerebral tumors.<sup>8,12</sup> These observations naturally lead to the question whether the established thresholds of  $Sjvo_2$  for detection of cerebral ischemia apply to these patients. In acute head injury,  $Sjvo_2$  values less than 50% suggest hypoperfusion and  $Sjvo_2$  values less than 40% are supposed to be associated with the development of global cerebral ischemia.<sup>33</sup> In awake, nonmedicated subjects, the mean value of  $Sjvo_2$  ranges between 54.6%, 55.0%, and 57.1%,<sup>34–36</sup> with the lowest individual value of 44.7%.<sup>34</sup> In propofol-fentanyl-anesthetized patients undergoing craniotomy for cerebral tumor,  $Sjvo_2$  averaged 57%.<sup>9</sup> If normal values of CBF and  $Sjvo_2$  are considered to be  $50 \text{ ml} \cdot 100 \text{ g}^{-1} \cdot \text{min}^{-1}$  and 55%, respectively, a 40% decrease in CBF caused by cerebral vasoconstriction would decrease CBF to  $30 \text{ ml} \cdot 100 \text{ g}^{-1} \cdot \text{min}^{-1}$  and  $Sjvo_2$  to 42%. Under this circumstance, the vasoconstriction is accompanied by cerebral oligemia, but not ischemic changes detectable on DWI images. The value of 42% corresponds to the median value of 43% observed in the current study during indomethacin administration. Comparing absolute levels of  $Sjvo_2$  or  $AVDO_2$  between patients with severe head injury and patients subjected to elective tumor resection in propofol-fentanyl anesthesia may be misleading. An  $Sjvo_2$  of approximately 40% may not have the same significance in patients with cerebral tumors compared with head-injured patients with different pathology. Therefore, the ischemic threshold of  $Sjvo_2$  (*i.e.*, 50%) in patients with severe head injury should not be applied to propofol-anesthetized patients. We therefore suggest a redefinition of the ischemic threshold for  $Sjvo_2$  during propofol anesthesia.

The dose of indomethacin administered in the current study is based on a recent study in which indomethacin (bolus of 0.2 mg/kg followed by  $0.2 \text{ mg} \cdot \text{kg}^{-1} \cdot \text{h}^{-1}$ ) caused a significant decrease in cerebral blood flow velocity before induction of anesthesia.<sup>8</sup> This finding is in accord with a study in healthy volunteers where indomethacin (bolus of 0.2 mg/kg followed by  $0.2 \text{ mg} \cdot \text{kg}^{-1} \cdot \text{h}^{-1}$ ) caused a significant decrease in CBF, ranging between 29% and 37%, equal to a clinical study in head-injured patients where indomethacin (bolus of 30 mg followed by 30 mg/h) reduced ICP and caused a reduction in CBF averaging 15–26%.<sup>1,7</sup>

In conclusion, the current study could not demonstrate any evidence of ischemic brain tissue damage associated with indomethacin and propofol, as evaluated by DWI.

The authors thank language secretary Anita Pachai for spell checking the manuscript; research radiographers Dora Zeidler and Anne Dorthe Blankholm, Department of Neuroradiology, Århus University Hospital, Århus, Denmark; and staff at the Department of Neuroradiology, Århus University Hospital, for their professional assistance with the magnetic resonance imaging examinations. Staff anesthesiologist Alp Tankisi, M.D., Department of Neuroanesthesia, Århus University Hospital, is acknowledged for his help with analysis of the blood samples.

## References

1. Jensen K, Kjaergaard S, Malte E, Bunemann L, Therkelsen K, Knudsen F: Effect of graduated intravenous and standard rectal doses of indomethacin on cerebral blood flow in healthy volunteers. *J Neurosurg Anesthesiol* 1996; 8:111-6
2. Pickard JD, and MacKenzie ET: Inhibition of prostaglandin synthesis and the response of baboon cerebral circulation to carbon dioxide. *Nature New Biol* 1973; 245:187-8
3. Rasmussen M, Poulsen PH, Treiber A, Delahaye S, Tankisi A, Cold GE, Therkelsen K, Gjedde A, Astrup J: No influence of the endothelin receptor antagonist bosentan on basal and indomethacin-induced reduction of cerebral blood flow in pigs. *Acta Anaesthesiol Scand* 2003; 47:200-7
4. Bundgaard H, Jensen K, Cold GE, Bergholt B, Frederiksen R, Pless S: Effects of perioperative indomethacin on intracranial pressure, cerebral blood flow, and cerebral metabolism in patients subjected to craniotomy for cerebral tumors. *J Neurosurg Anesthesiol* 1996; 8:273-9
5. Biestro AA, Alberti RA, Soca AE, Cancela M, Puppo CB, Borovich B: Use of indomethacin in brain-injured patients with cerebral perfusion pressure impairment: Preliminary report. *J Neurosurg* 1995; 83:627-30
6. Dahl B, Bergholdt B, Cold GE, Astrup J, Mosdal B, Jensen K, Kjærsgaard J: CO<sub>2</sub> and indomethacin vasoreactivity in patients with head injury. *Acta Neurochir* 1996; 138:265-73
7. Jensen K, Ohrstrom J, Cold GE, Astrup J: The effects of indomethacin on intracranial pressure, cerebral blood flow and cerebral metabolism in patients with severe head injury and intracranial hypertension. *Acta Neurochir* 1991; 108:116-21
8. Rasmussen M, Tankisi T, Cold GE: The effects of indomethacin on intracranial pressure and cerebral haemodynamics in patients undergoing craniotomy: A randomised prospective study. *Anaesthesia* 2004; 59:229-36
9. Petersen KD, Landsfeldt U, Cold GE, Petersen CB, Mau S, Hauerberg J, Holst P, Olsen KS: Intracranial pressure and cerebral hemodynamic in patients with cerebral tumors: A randomized prospective study of patients subjected to craniotomy in propofol-fentanyl, isoflurane-fentanyl, or sevoflurane-fentanyl anesthesia. *ANESTHESIOLOGY* 2003; 98:329-36
10. Jansen GF, van Praagh BH, Kedaria MB, Odom JA: Jugular bulb oxygen saturation during propofol and isoflurane/nitrous oxide anesthesia in patients undergoing brain tumor surgery. *Anesth Analg* 1999; 89:358-63
11. Munoz HR, Nunez GE, de la Fuente JE, Campos MG: The effect of nitrous oxide on jugular bulb oxygen saturation during remifentanyl plus target-controlled infusion propofol or sevoflurane in patients with brain tumors. *Anesth Analg* 2002; 94:389-92
12. Todd MM, Warner DS, Sokoll MD, Maktabi MA, Hindman BJ, Scamman FL, Kirschner J: A prospective, comparative trial of three anesthetics for elective supratentorial craniotomy: Propofol/fentanyl, isoflurane/nitrous oxide, and fentanyl/nitrous oxide. *ANESTHESIOLOGY* 1993; 78:1005-20
13. Röhl L, Østergaard L, Simonsen CZ, Vestergaard-Poulsen P, Andersen G, Sakoh M, Le Bihan D, Gyldensted C: Viability thresholds of ischemic penumbra of hyperacute stroke defined by perfusion-weighted MRI and apparent diffusion coefficient. *Stroke* 2001; 32:1140-6
14. Warach S, Chien D, Li W, Ronthal M, Edelman RR: Fast magnetic resonance diffusion-weighted imaging of acute human stroke. *Neurology* 1992; 42:1717-23
15. Moseley M, Cohen Y, Mintorovitch J, Chileuitt L, Shimizu H, Kucharczyk J, Wendland MF, Weinstein PR: Early detection of regional cerebral ischemia in cats: Comparison of diffusion- and T<sub>2</sub>-weighted MRI and spectroscopy. *Magn Reson Med* 1990; 14:330-46
16. Röhl L, Sakoh M, Simonsen CZ, Vestergaard-Poulsen P, Sangill R, Sorensen JC, Bjarkam CR, Gyldensted C, Østergaard L: Time evolution of cerebral perfusion and apparent diffusion coefficient measured by magnetic resonance imaging in a porcine stroke model. *J Magn Reson Imag* 2002; 15:123-9
17. Schlaug G, Siewert B, Benfield A, Edelman RR, Warach S: Time course of the apparent diffusion coefficient (ADC) abnormality in human stroke. *Neurology* 1997; 49:113-9
18. Nilsson F, Bjorkman S, Rosen I, Messeter K, Nordstrom CH: Cerebral vasoconstriction by indomethacin in intracranial hypertension: An experimental investigation in pigs. *ANESTHESIOLOGY* 1995; 83:1283-92
19. Mintorovitch J, Moseley ME, Chileuitt L, Shimizu H, Cohen Y, Weinstein PR: Comparison of diffusion- and T<sub>2</sub>-weighted MRI for the early detection of cerebral ischemia and reperfusion in rats. *Magn Reson Med* 1991; 18:39-50
20. Yoneda Y, Tokui K, Hanihara T, Kitagaki H, Tabuchi M, Mori E: Diffusion-weighted magnetic resonance imaging: Detection of ischemic injury 39 minutes after onset in a stroke patient. *Ann Neurol* 1999; 45:794-7
21. Minematsu K, Li L, Fisher M, Sotak CH, Davis MA, Fiandaca MS: Diffusion-weighted magnetic resonance imaging: Rapid and quantitative detection of focal brain ischemia. *Neurology* 1992; 42:235-40
22. Lovblad KO, Baird AE, Schlaug G, Benfield A, Siewert B, Voetsch B, Connor A, Burzynski C, Edelman RR, Warach S: Ischemic lesion volumes in acute stroke by diffusion-weighted magnetic resonance imaging correlate with clinical outcome. *Ann Neurol* 1997; 42:164-70
23. van Everdingen KJ, van der Grond J, Kappelle IJ, Ramos LM, Mali WP: Diffusion-weighted magnetic resonance imaging in acute stroke. *Stroke* 1998; 29:1783-90
24. Warach S, Dashe JF, Edelman R: Clinical outcome in ischemic stroke predicted by early diffusion-weighted and perfusion magnetic resonance imaging: A preliminary analysis. *J Cereb Blood Flow Metab* 1996; 16:53-9
25. Gonzalez RG, Schaefer PW, Buonanno FS, Schwamm LH, Budzik RF, Rordorf G, Wang B, Sorensen AG, Koroshetz WJ: Diffusion-weighted MR imaging: diagnostic accuracy in patients imaged within 6 hours of stroke symptom onset. *Radiology* 1999; 210:155-62
26. Sorensen AG, Buonanno FS, Gonzalez RG, Schwamm LH, Lev MH, Huang-Hellinger FR, Reese TG, Weisskoff RM, Davis TL, Suwanwela N, Can U, Moreira JA, Copen WA, Look RB, Finklestein SP, Rosen BR, Koroshetz WJ: Hyperacute stroke: Evaluation with combined multisection diffusion-weighted and hemodynamically weighted echo-planar MR imaging. *Radiology* 1996; 199:391-401
27. Kaisti KK, Metsahonkala L, Teras M, Oikonen V, Aalto S, Jaaskelainen S, Hinkka S, Scheinin H: Effects of surgical levels of propofol and sevoflurane anesthesia on cerebral blood flow in healthy subjects studied with positron emission tomography. *ANESTHESIOLOGY* 2002; 96:1358-70
28. Ludbrook GL, Visco E, Lam AM: Propofol: relation between brain concentrations, electroencephalogram, middle cerebral artery blood flow velocity, and cerebral oxygen extraction during induction of anesthesia. *ANESTHESIOLOGY* 2002; 97:1363-70
29. Lagerkranser M, Stange K, Sollevi A: Effects of propofol on cerebral blood flow, metabolism, and cerebral autoregulation in the anesthetized pig. *J Neurosurg Anesthesiol* 1997; 9:188-93
30. Nandate K, Vuylsteke A, Ratsep I, Messahel S, Oduro-Dominah A, Menon DK, Matta BF: Effects of isoflurane, sevoflurane and propofol anaesthesia on jugular venous oxygen saturation in patients undergoing coronary artery bypass. *Br J Anaesth* 2000; 84:631-3
31. Cenic A, Craen RA, Lee TY, Gelb AW: Cerebral blood volume and blood flow responses to hyperventilation in brain tumors during isoflurane or propofol anesthesia. *Anesth Analg* 2002; 94:661-6
32. Ederberg S, Westerlind A, Houtz E, Svensson SE, Elam M, Ricksten SE: The effects of propofol on cerebral blood flow velocity and cerebral oxygen extraction during cardiopulmonary bypass. *Anesth Analg* 1998; 86:1201-6
33. Gopinath SP, Cormio M, Ziegler J, Raty S, Valadka A, Robertson CS: Intraoperative jugular desaturation during surgery for traumatic intracranial hematomas. *Anesth Analg* 1996; 83:1014-21
34. Chieragato A, Calzolari F, Trasforini G, Targa L, Latronico N: Normal jugular bulb oxygen saturation. *J Neurol Neurosurg Psych* 2003; 74:784-6
35. Datsur DK, Lane MH, Hansen DB, Kety SS, Butler RN, Perlin S, Sokoloff L: Effects of aging on cerebral circulation and metabolism in man. *Human Aging: A Biological and Behavioural Study*. Edited by Birren JE, Butler RN, Greenhouse SW, Sokoloff L, Yarrow MR. Washington, D.C., US Government Printing Office, 1963, pp 59-76
36. Gibbs EL, Lennox WG, Nims LF, Gibbs FA: Arterial and cerebral venous blood: Arterial-venous differences in man. *J Biol Chem* 1942; 144:325-32