

Auto-Positive End-expiratory Pressure Masquerading as Loss of Lung Separation during Thoracoscopy

Jerome M. Klafta, M.D.,* Mary C. Mathew, M.D.†

AUTO-positive end-expiratory pressure (auto-PEEP) is well described in patients with expiratory airflow obstruction, including those who require one-lung ventilation.¹⁻⁴ Unfortunately, detecting auto-PEEP with most anesthesia ventilators is difficult.^{5,6} We report an unusual presentation of auto-PEEP during one-lung ventilation in which a reliable method of confirming lung separation quickly directed us to the correct diagnosis.

Case Report

A 72-yr-old woman diagnosed with a 2 × 3-cm right upper lobe lung mass was scheduled for thoracoscopic biopsy and possible wedge resection. She was 150 cm tall and weighed 67.3 kg. Her medical history was significant for hypertension, coronary artery disease, hiatal hernia, chronic renal insufficiency, and chronic obstructive pulmonary disease. Her medications included atenolol, albuterol, ipratropium, montelukast, furosemide, atorvastatin, and famotidine. Physical examination revealed a blood pressure of 141/72 mmHg, a heart rate of 71 beats/min, a respiratory rate of 20 breaths/min, clear lungs, and a normal airway. Preoperative pulmonary function testing demonstrated a forced expiratory volume in 1 s of 0.45 l (44% of predicted), a forced vital capacity of 1.02 l (92% of predicted), a total lung capacity of 3.81 l (97% of predicted), a functional residual capacity of 3.19 l (139% of predicted), and a residual volume of 2.37 l (147% of predicted). Arterial blood gas on room air revealed a pH of 7.41, a partial pressure of carbon dioxide of 43.5 mmHg, and a partial pressure of oxygen of 64.9 mmHg.

General anesthesia was induced with 100 mg propofol, 50 μg fentanyl, and 14 mg cisatracurium. Bag mask ventilation was easy, and inhalational anesthesia was deepened with sevoflurane, which was continued throughout the case in end-tidal concentrations between 1.0% and 1.8%. The patient was intubated with an 8.0-mm-ID single-lumen endotracheal tube to facilitate diagnostic bronchoscopy by the surgeon. The tube was then replaced with a 37-French left-sided double-lumen endotracheal tube (Broncho-Cath; Mallinckrodt Inc., St. Louis, MO). The size was determined by measuring the left mainstem bronchus on the chest computerized tomography scout film. The position of the double-lumen endotracheal tube was confirmed with a fiberoptic bronchoscope, and the patient was repositioned in the left lateral decubitus position. After confirming excellent double-lumen endotracheal tube position through both lumens with the fiberoptic bronchoscope (unimpeded view of the left upper and lower lobe orifices as well as a completely subcarinal bronchial cuff), lung separation was achieved and confirmed using the positive-pressure underwater bubble test⁷ with 1.5 ml air in the bronchial cuff. Using an

Aestiva/5 anesthesia machine (Datex-Ohmeda, Helsinki, Finland) in volume control mode, the patient's lungs were ventilated with 100% oxygen and a tidal volume of 400 ml, a respiratory rate of 6 breaths/min, and an inspiratory:expiratory ratio of 1:2.5 with a resultant peak airway pressure of 40 cm H₂O and end-tidal carbon dioxide readings of approximately 47 mmHg. Approximately 20 min after beginning thoracoscopy, the surgeon remarked that the right lung was increasingly impeding surgical exposure. He was concerned that lung separation may have been lost. The patient's vital signs, capnograph, and airway pressures were unchanged. Adequate lung separation was immediately reconfirmed with the positive-pressure test used earlier.⁷ Because of the patient's baseline irreversible airflow obstruction, the hypothesis that significant auto-PEEP might be present in the dependent, ventilated lung was considered. Mechanical ventilation was discontinued, and the patient was allowed to exhale for approximately 60 s (fig. 1). At this time, the quality of thoracoscopic visualization in the right hemithorax had returned to its previous level. The ventilator was adjusted to increase the inspiratory:expiratory ratio to 1:3.5, allowing the patient more expiratory time, and the surgery concluded uneventfully.

Discussion

We believe that this patient with expiratory airflow obstruction developed auto-PEEP in the dependent lung during one-lung ventilation. Auto-PEEP during one-lung ventilation is well described¹⁻⁴ in patients with expiratory airflow obstruction. This patient's preoperative pulmonary function testing values demonstrated expiratory flow limitation, and we initiated one-lung mechanical ventilation with this in mind. The initial respiratory rate of 6 breaths/min and the inspiratory:expiratory ratio of 1:2.5 resulted in an inspiratory time of 2.84 s and an expiratory time of 7.14 s. Normally, significant amounts of auto-PEEP in the lungs increase airway and intrathoracic pressures and cause a decrease in venous return, cardiac output, and blood pressure. In the current patient, the operative hemithorax was open to atmosphere through trocar sites and served as a "pop off," allowing the ventilated lung to expand unencumbered and to shift the mediastinum and the deflated right lung into the right hemithorax.

It is difficult to detect auto-PEEP with most anesthesia machines because the proximal position at which airway pressure is measured may not reflect or detect the increased alveolar pressure.¹ Auto-PEEP can be measured accurately using the end-expiratory occlusion method in a ventilator capable of producing an end-expiratory hold.¹⁻⁴ However, auto-PEEP can be expeditiously recognized and definitely treated using the apnea test described by Myles *et al.*,^{5,8} which consists of disconnecting the patient from the ventilator and allowing the lungs to deflate passively to functional residual capacity. As with our patient, the expiratory flow may continue for a

* Associate Professor, † Resident.

Received from the Department of Anesthesia and Critical Care, The University of Chicago, Chicago, Illinois. Submitted for publication January 23, 2004. Accepted for publication May 6, 2004. Support was provided solely from institutional and/or departmental sources.

Address reprint requests to Dr. Klafta: Department of Anesthesia and Critical Care, The University of Chicago, 5841 South Maryland Avenue, MC 4028, Chicago, Illinois 60637. Address electronic mail to: jklafta@airway.uchicago.edu. Individual article reprints may be purchased through the Journal Web site, www.anesthesiology.org.

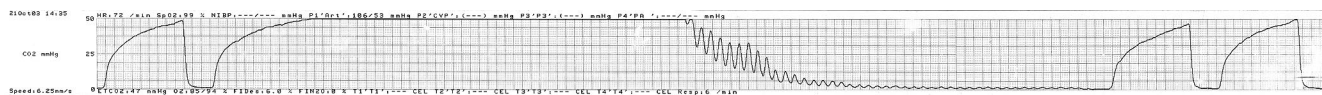


Fig. 1. Capnograph showing markedly prolonged alveolar plateau during the apnea test. Normal mechanical breaths precede and follow.

considerable time if exhalation is severely obstructed (fig. 1). Auto-PEEP is best managed by using low respiratory rates, long expiratory times, and permissive hypercapnea.⁹

A number of techniques have been described to confirm and in fact quantify lung separation.^{7,10-12} We routinely use the positive-pressure or bubble test, which was particularly useful in this setting. The most obvious reason that the operative hemithorax becomes filled with lung tissue after initial deflation is that some ventilation reaches that lung when lung separation is incomplete. A common response (with or without confirming adequate double-lumen endotracheal tube position) is to inject more air into the bronchial cuff. Inflation of more air into the bronchial cuff than is needed to achieve an airtight seal may predispose to cuff herniation, bronchial mucosal ischemia, or even rupture.^{10,13,14} Confirming adequate lung separation definitively using the bubble test enabled us to recognize auto-PEEP quickly and to treat it effectively.

References

1. Bardoczky GI, Yernault JC, Engelman EE, Velghe CE, Cappello M, d'Hollander AA: Intrinsic positive end-expiratory pressure during one-lung ventilation for thoracic surgery: The influence of preoperative pulmonary function. *Chest* 1996; 110:180-4

2. Ducros L, Moutafis M, Castelain MH, Liu N, Fischler M: Pulmonary air trapping during two-lung and one-lung ventilation. *J Cardiothorac Vasc Anesth* 1999; 13:35-9

3. Yokota K, Toriumi T, Sari A, Endou S, Mihira M: Auto-positive end-expiratory pressure during one-lung ventilation using a double-lumen endobronchial tube. *Anesth Analg* 1996; 82:1007-10

4. Slinger PD, Kruger M, McRae K, Winton T: Relation of the static compliance curve and positive end-expiratory pressure to oxygenation during one-lung ventilation. *ANESTHESIOLOGY* 2001; 95:1096-102

5. Myles PS, Ryder IG, Weeks AM, Williams T, Esmore DS: Case 1—1997: Diagnosis and management of dynamic hyperinflation during lung transplantation. *J Cardiothorac Vasc Anesth* 1997; 11:100-4

6. Slinger PD, Hickey DR: The interaction between applied PEEP and auto-PEEP during one-lung ventilation. *J Cardiothorac Vasc Anesth* 1998; 12:133-6

7. Spragg RG, Benumof JL, Alfery DD: New methods for the performance of unilateral lung lavage. *ANESTHESIOLOGY* 1982; 57:535-8

8. Myles PS, Madder H, Morgan EB: Intraoperative cardiac arrest after unrecognized dynamic hyperinflation. *Br J Anaesth* 1995; 74:340-2

9. Szegedi LL, Barvais L, Sokolow Y, Yernault JC, d'Hollander AA: Intrinsic positive end-expiratory pressure during one-lung ventilation of patients with pulmonary hyperinflation: Influence of low respiratory rate with unchanged minute volume. *Br J Anaesth* 2002; 88:56-60

10. Guyton DC, Besselièvre TR, Devidas M, DeLima LG, Eichhorn JH: A comparison of two different bronchial cuff designs and four different bronchial cuff inflation methods. *J Cardiothorac Vasc Anesth* 1997; 11:599-603

11. Hannallah MS, Benumof JL, McCarthy PO, Liang M: Comparison of three techniques to inflate the bronchial cuff of left polyvinylchloride double-lumen tubes. *Anesth Analg* 1993; 77:990-4

12. Hannallah MS, Gharagozloo F, Gomes MN, Chase GA: A comparison of the reliability of two techniques of left double-lumen tube bronchial cuff inflation in producing water-tight seal of the left mainstem bronchus. *Anesth Analg* 1998; 87:1027-31

13. Benumof JL: *Anesthesia for Thoracic Surgery*, 2nd edition. Philadelphia, WB Saunders, 1995, pp 330-89

14. Fitzmaurice BG, Brodsky JB: Airway rupture from double-lumen tubes. *J Cardiothorac Vasc Anesth* 1999; 13:322-9

Anesthesiology 2004; 101:1230-2

© 2004 American Society of Anesthesiologists, Inc. Lippincott Williams & Wilkins, Inc.

Emergency Treatment of Tracheobronchial Stent Migration

Julien Amour, M.D.,* Alexis Soummer, M.D.,† Olivier Langeron, M.D., Ph.D.,‡ Bruno Riou, M.D., Ph.D.§

TRACHEOBRONCHIAL stents are widely used in patients with tracheal obstruction due to malignant tumors, benign tracheal stenosis complicating prolonged tracheal intubation, tracheostomy, and anastomotic resection or graft.^{1,2} Various tracheobronchial stent models have been developed, and increasing use is made of the silicone stent

designed by Dumon, which is easily inserted and removed, and more than 15,000 stents have been placed since 1987.¹ These stents are well tolerated and efficacious in relieving respiratory symptoms caused by tracheal stenosis. Nevertheless, tracheobronchial stent migration is a relatively common complication, occurring in 9.5-24% of cases.^{1,3,4}

We report a case of silicone tracheobronchial stent migration that resulted in acute respiratory distress. We performed a simple technique to replace the tracheobronchial stent in the correct position, using a flexible fiberoptic bronchoscope and a Fogarty catheter, circumventing the need for rigid bronchoscopy.

Case Report

A 25-yr-old man was referred to our intensive care unit for acute respiratory distress related to an airway obstruction. This patient presented with a motor cerebral palsy that was complicated by a history

* Assistant Professor of Anesthesiology, † Resident of Anesthesiology, ‡ Staff Anesthesiologist, Department of Anesthesiology and Critical Care, § Professor of Anesthesiology and Critical Care and Chairman, Department of Emergency Medicine and Surgery.

Received from the Department of Anesthesiology and Critical Care and the Department of Emergency Medicine and Surgery, Centre Hospitalo-Universitaire Pitié-Salpêtrière, Assistance Publique-Hôpitaux de Paris, Université Pierre et Marie Curie, Paris, France. Submitted for publication February 6, 2004. Accepted for publication May 20, 2004. Support was provided solely from institutional and/or departmental sources.

Address reprint requests to Pr. Riou: Service d'Accueil des Urgences, Centre Hospitalo-Universitaire Pitié-Salpêtrière, 47-83 Boulevard de l'Hôpital, 75651 Paris Cedex 13, France. Address electronic mail to: bruno.riou@psl.ap-hop-paris.fr. Individual article reprints may be purchased through the Journal Web site, www.anesthesiology.org.

of uncontrolled epilepsy. Several months previously, he had undergone prolonged tracheal intubation for status epilepsy requiring tracheostomy. A tracheal stenosis had complicated this tracheostomy, and a Dumon silicone tracheobronchial stent was placed using a rigid bronchoscope.

This patient presented with a dry cough associated with acute dyspnea during meals, suggesting pulmonary inhalation. The tolerance was so poor that the patient was brought to the hospital in an emergency. At admission in the emergency department, the patient was hemodynamically stable, with an arterial blood pressure of 140/60 mmHg and a heart rate of 105 beats/min, whereas polypnea persisted and was associated with confusion. There was an inspiratory dyspnea complicated by hypoxemia. Arterial blood gas analysis performed while the patient breathed room air showed a pH of 7.49, an arterial oxygen tension of 62 mmHg, and an arterial carbon dioxide tension of 47 mmHg. Results of a clinical examination of the oropharynx were normal. A chest radiograph showed a foreign body in the right main bronchus, which corresponded to the silicon tracheobronchial stent migration. Rigid bronchoscopy, which is the method of choice, was unavailable in this emergency situation. Therefore, diagnostic fiberoptic bronchoscopy was chosen.

Anesthesia was induced with propofol, and muscular relaxation was obtained using succinylcholine. Tracheal intubation was performed using a large (9-mm) endotracheal tube (Portex, Tijuana, Mexico). The fiberoptic bronchoscopy enabled us to observe a nearly complete tracheal obstruction by the endotracheal granuloma and to confirm the migration of the tracheobronchial stent below the endotracheal granuloma in the right main bronchus. Consequently, a nearly complete obstruction of the left main stem bronchus was observed. Because a rapid therapeutic response was needed and because rigid bronchoscopy was not available, we used a new technique to replace the tracheobronchial stent. We placed an arterial embolectomy catheter (Bard, Rancho Santa Margarita, CA) beside the flexible fiberoptic bronchoscope (fig. 1A). The balloon of the catheter was placed distal to the extremity of the tracheobronchial stent and then inflated. Thereafter, we pulled this Fogarty catheter under the fiberoptic bronchoscope control and gently repositioned the tracheobronchial stent (fig. 1B). Then, we aspirated all bronchial secretions accumulated beyond the stent and verified the absence of inhalation of any alimentary debris. The patient was awakened and rapidly extubated. Chest radiography confirmed a good position of the stent. Two days later, rigid bronchoscopy also confirmed the correct position of the stent.

Discussion

A silicone tracheal stent provides prompt and durable palliation in patients with unresectable central airway obstruction,¹ although multiple procedures are often necessary to maintain a satisfactory airway.⁵ In nonurgent tracheobronchial stenosis, flexible fiberoptic bronchoscopy is used for silicone stent placement by a modified Seldinger technique followed by balloon dilatation.^{6,7}

However, silicone stent migrations are a common complication, with an incidence between 9.5% and 24%.^{1,3,4} Silicone stents migrate more than metal stents because of the inherent properties of stents. Moreover, metal stents are expanded with a balloon in the collapse portion so they become as close to a custom fit as possible. In comparison, silicone stents, with numerous studs along the outer surface designed to prevent migration, are usually folded and released in place to expand to their preformed shape.

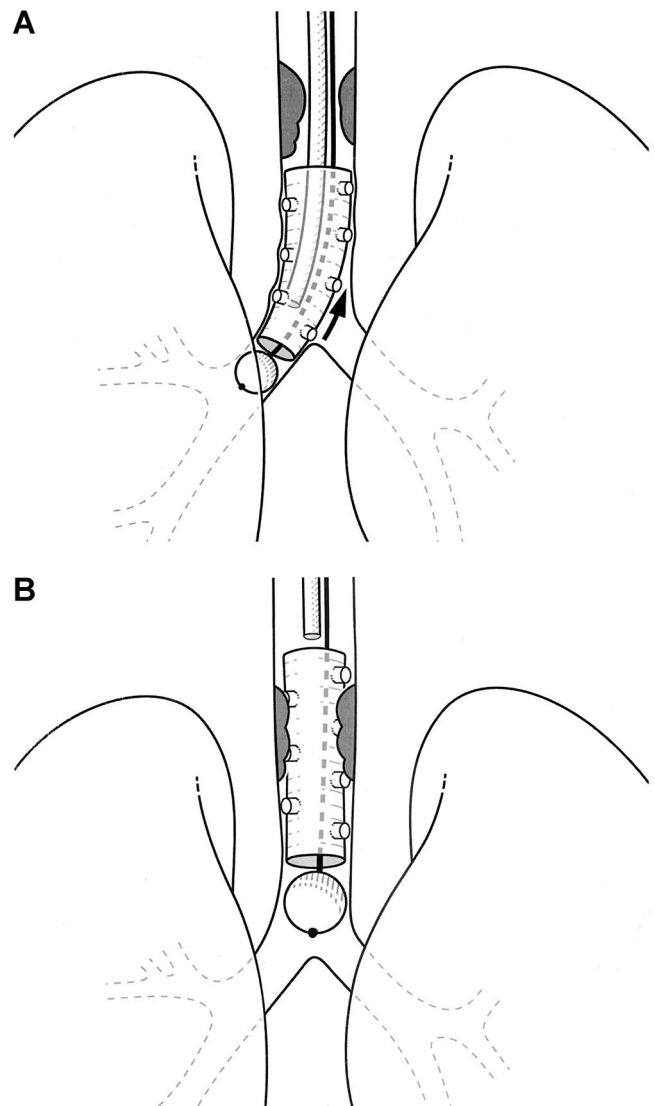


Fig. 1. Silicon tracheal stent replacement technique. (A) A Fogarty catheter is placed under the supervision of the flexible fiberoptic bronchoscope and inflated. (B) After inflation of the balloon of the catheter, this catheter is pulled, allowing replacement of the silicon stent.

Although the fiberoptic bronchoscope is now available in nearly every center for difficult tracheal intubation, this is not the case with rigid bronchoscopy. Moreover, mobilization of the stent required dedicated materials that are not widely available in emergency conditions.

In the current case, foreign body inhalation was suspected by clinical history and chest radiography. Because of the respiratory distress, we decided to perform tracheal intubation and fiberoptic bronchoscopy. We performed anesthesia induction using succinylcholine to prevent pulmonary regurgitation in a full-stomach context. The migration of the tracheal stent was obvious only during fiberoptic bronchoscopy, and radiographic evidence of the stent migration was only understood afterward. The respiratory distress could be related to two phenomena: the tracheal obstruction related to the

granuloma and the stent migration into the origin of the right main stem bronchus, leading to partial left main stem bronchus obstruction (fig. 1A).

Several points should be discussed to analyze the potential limitations of our technique. First, mobilization of the stent was easy because of the type of stent, which is known to be easy to mobilize. This would not be the case with every type of stent (*e.g.*, metal stents), and information regarding the type of stent is often lacking in emergency conditions. A card indicating the type and indication of the stent should be provided to each patient. Second, mobilization of the stent should be done carefully to avoid any traumatic lesion of the trachea that could result in hemorrhage or rupture. These complications might be more frequent in cases of tumors. Third, this technique is easy for a distal stent migration but could be more difficult for a proximal stent migration because it is difficult to push the stent with the balloon in this case. Last, the correct replacement of the tracheal stent and the lack of a traumatic lesion should always be confirmed later by a specialized endoscopist using rigid bronchoscopy, as we did here.

In conclusion, in emergency conditions, when rigid

bronchoscopy is unavailable, silicon tracheal stent migration can be successfully and rapidly treated under fiberoptic bronchoscopy using a Fogarty catheter. Anesthesiologists and emergency physicians should be aware of this simple technique because it requires materials that are widely available in most operating rooms.

References

1. Dumon MC, Dumon JF, Perrin C, Blaive B: Endoprothèses trachéobronchiques en silicone. *Rev Mal Respir* 1999; 16:641-51
2. Noppen M, Poppe K, D'Haese J, Meysman M, Velkeniers B, Vincken W: Interventional bronchoscopy for treatment of tracheal obstruction secondary to benign or malignant thyroid disease. *Chest* 2004; 125:723-30
3. Martinez-Ballarín JI, Diaz-Jimenez JP, Castro MJ, Moya JA: Silicone stents in the management of benign tracheobronchial stenoses: Tolerance and early results in 63 patients. *Chest* 1996; 109:626-9
4. Noppen M, Meysman M, Claes I, D'Haese J, Vincken W: Screw-thread vs Dumon endoprosthesis in the management of tracheal stenosis. *Chest* 1999; 115:532-5
5. Wood DE, Liu YH, Vallieres E, Karmy-Jones R, Mulligan MS: Airway stenting for malignant and benign tracheobronchial stenosis. *Ann Thorac Surg* 2003; 76:167-72
6. Sheski FD, Mathur PN: Long-term results of fiberoptic bronchoscopic balloon dilation in the management of benign tracheobronchial stenosis. *Chest* 1998; 114:796-800
7. Noppen M, Schlessler M, Meysman M, D'Haese J, Peche R, Vincken W: Bronchoscopic balloon dilatation in the combined management of postintubation stenosis of the trachea in adults. *Chest* 1997; 112:1136-40

Anesthesiology 2004; 101:1232-4

© 2004 American Society of Anesthesiologists, Inc. Lippincott Williams & Wilkins, Inc.

Perioperative Compartment Syndrome of the Hand

Susan J. Kies, M.D.,* David R. Danielson, M.D.,† David G. Dennison, M.D.,‡ Mary E. Warner, M.D.,§ Mark A. Warner, M.D.||

COMPARTMENT syndrome is a potentially devastating perioperative complication that typically involves the legs or arms.¹ Most surgical patients have this problem while anesthetized and positioned in lithotomy or lateral decubitus positions.² We recently observed compartment syndrome of the hand in a patient who was anesthetized and positioned supine for a surgical procedure, a previously unreported perioperative complication in the absence of trauma or vascular obstruction in the upper extremity. A potential positioning cause for the compartment syndrome prompts this case report. To supplement this case report, we also have reviewed our experience with this perioperative problem during the past 15 yr, using a robust perioperative database to determine the frequency ratio and outcomes of this event.

* Resident, Mayo School of Graduate Medical Education, † Assistant Professor, § Associate Professor, || Professor, Department of Anesthesiology, ‡ Instructor, Department of Orthopedic Surgery, Mayo Clinic College of Medicine.

Received from the Department of Anesthesiology, Mayo Clinic College of Medicine, Rochester, Minnesota. Submitted for publication January 15, 2004. Accepted for publication June 1, 2004. Support was provided solely from institutional and/or departmental sources.

Address reprint requests to Dr. Mark Warner: Department of Anesthesiology, Mayo Clinic College of Medicine, Rochester, Minnesota 55905. Address electronic mail to: warner.mark@mayo.edu. Individual article reprints may be purchased through the Journal Web site, www.anesthesiology.org.

Representative Case Report

A 43-yr-old man with a body mass index (BMI) of 36 kg/m² came to the operating room for colostomy takedown and simultaneous revision of a complex abdominal scar. He was positioned supine on the operating room table, and 18-gauge intravenous catheters were placed bilaterally in veins on the dorsum of his hands. General endotracheal anesthesia was initiated without difficulty. Subsequently, experienced personnel tucked the patient's arms at his sides, with his palms facing inward against the lateral thighs. The elbows were padded with foam cushions, and the upper arms were externally rotated to reduce extrinsic pressure on the ulnar nerves in the medial epicondylar grooves. The tucks were then performed using a standard draw sheet under the patient's back, looped over his arms while they were resting at his sides, and tucked under his chest, abdomen, and buttocks. Both intravenous catheters functioned well after the arms were tucked and throughout the case. The procedure lasted 5 h, and the patient received 5.2 l crystalloid during the procedure.

On arrival to the postanesthesia care unit, the patient reported severe, unrelenting left hand pain. He described his pain as burning and constant. It was not improved with several boluses of intravenous fentanyl. Examination of his left arm and hand revealed dorsal topography consistent with pressure caused by constrictive fabric (*i.e.*, the draw sheet) across the dorsal wrist and medial hand. The 18-gauge intravenous catheter in the forearm continued to function and was not infiltrated. The left palm was hyperemic, had distal phalangeal pallor, and was tense, swollen, and exquisitely tender over the thenar and hypothenar prominences. He could not actively abduct or oppose his thumb, and he could not tolerate passive extension of his thumb

Table 1. Patient and Procedure Characteristics and Outcomes

Year	Age, yr	Sex	BMI, kg/m ²	Surgical Procedure	Procedure Duration, h	Highest Compartment Pressure, mmHg	No. of Fasciotomies	6-Month Outcome
1990	51	M	39	Sigmoid colectomy	3.4	72	3	Complete resolution
1992	62	F	28	Radical hysterectomy	4.6	62	2	Little pain and minor dysfunction
1998	34	M	41	Cystectomy	4.1	79	2	Complete resolution
2003	43	M	36	Colostomy takedown	5.0	81	3	Persistent pain and significant dysfunction
2003	56	M	37	Retropubic prostatectomy	3.2	69	3	Persistent discomfort and minor dysfunction

because of pain. Neither ice nor elevation relieved the pain, and a hand surgeon was rapidly consulted. The patient was returned to the operating room for tissue pressure measurement and fasciotomy. Pressures of the thenar, hypothenar, and first dorsal interosseous compartments were 81, 53, and 36 mmHg, respectively. The patient has not recovered well from this complication. Ten months after his fasciotomies, he had pain that awakened him at night and with any use of the hand, plus dysfunction that prevented him from using his hand for lifting or gripping most objects.

Retrospective Study Methodology

With Mayo Institutional Review Board approval, the medical database at the Mayo Medical Center, Rochester, Minnesota, was reviewed to glean all cases of patients who had undergone an index (*i.e.*, initial) surgical episode and within 5 days a subsequent fasciotomy of the hand during the 15-yr period of July 1, 1988, to June 30, 2003. Each unique anesthetic was considered to represent a single surgical episode, regardless of the number of procedures performed during that anesthetic. We attempted to glean only cases in which perioperative positioning or some unrecognized characteristic or event may have caused compartment syndrome of the hand. Therefore, cases of compartment syndrome that occurred in traumatized hands or hands that may have been subject to ischemia from vascular surgical procedures of the upper extremities were excluded. All surgical episodes must have been performed while patients underwent general anesthesia, regional anesthesia, or both or local anesthesia with or without sedation. A single trained reviewer abstracted all records. Outcomes of these patients at least 6 months after the index surgeries were obtained.

Description of Surgical Population and Report of Cases

During the study period, 782,883 patients underwent 902,412 surgical episodes. Nineteen percent (148,703) underwent more than one surgical episode. Slightly more than half of the 782,883 patients were female (52.6%, $n = 411,796$). The mean age (\pm SD) of the surgical population was 51.2 ± 19.1 yr, with ages ranging from 0 to 110 yr.

Overall, 79 of the 782,883 patients (1:9,909 or 10.1 per 100,000) underwent a fasciotomy of the hand within 5 days of their index procedures. Nearly two thirds of these patients (62.0%, $n = 49$) underwent this procedure secondary to trauma. Sixteen of these patients (20.2%) experienced a compartment syndrome of the hand and required fasciotomy within 48 h after a vascular surgical procedure. Six patients (7.6%) experienced the syndrome after an arterial embolic event, and 3 others had miscellaneous medical conditions that contributed to the compartment syndrome. There was no apparent preexisting cause for the compartment syndrome of the hand in 5 patients (6.3%), including the patient noted in the representative case reported here. However, 4 of these 5 patients were large men with BMIs greater than 35 kg/m² who underwent abdominal or pelvic procedures of at least 3 h in duration, were given more than 4 l intravenous fluids intraoperatively, had their arms tucked at their sides during the pro-

cedures, and received general anesthetics. The patient and procedure characteristics and outcomes of all five of these patients are described in table 1.

The overall frequency ratio of compartment syndrome of the hand requiring fasciotomy and with no apparent preexisting cause was 1:156,576 (0.6 per 100,000). These five cases occurred in 1990, 1992, 1998, 2003, and again in 2003. The outcomes of this problem in patients 6 months after their fasciotomies varied. Two patients had complete resolution of their symptoms and no disability or pain. One patient had no pain and only minor residual weakness of opposition, resulting in difficulty holding objects with handles (*e.g.*, golf clubs, racquets, hammers). The remaining two patients had significant pain and loss of hand function that prevented them from many routine uses of their upper extremity (*e.g.*, writing with a pen, typing, gripping a steering wheel, holding a glass).

Discussion

We believe that this perioperative complication has not been previously reported. Fortunately, it is a rare event and, in four of our five cases, the outcomes have been reasonably good. However, prompt recognition of compartment syndrome of the hand in the immediate postoperative period is important to prevent muscle and nerve necrosis and, ultimately, severe disability.³

Importantly, these cases suggest that the frequency of this event can be reduced or its occurrence can be potentially eliminated. Four of the five cases were obese men undergoing prolonged abdominal or pelvic procedures. Their arms were tucked under a looped draw sheet at their sides. The representative case reported above describes the potential tourniquet effect of the distal (caudad) end of the draw sheet. Figure 1A shows how a tightly looped draw sheet in this patient, especially at the wrist, could have contributed to prolonged partial venous obstruction from the hand and possibly even reduced arterial blood flow. Another potential risk of the use of a looped draw sheet may be direct compression of the musculature of the hand, especially in the thenar and hypothenar regions. Increased pressure on the musculature may directly occlude small arterioles and venules, or it may generate a compartment pressure higher than the arteriolar pressure and indirectly prevent blood inflow. This effect may be compounded in the presence of intravenous fluid infiltration or tissue edema.

Many of the operating room tables in use today are

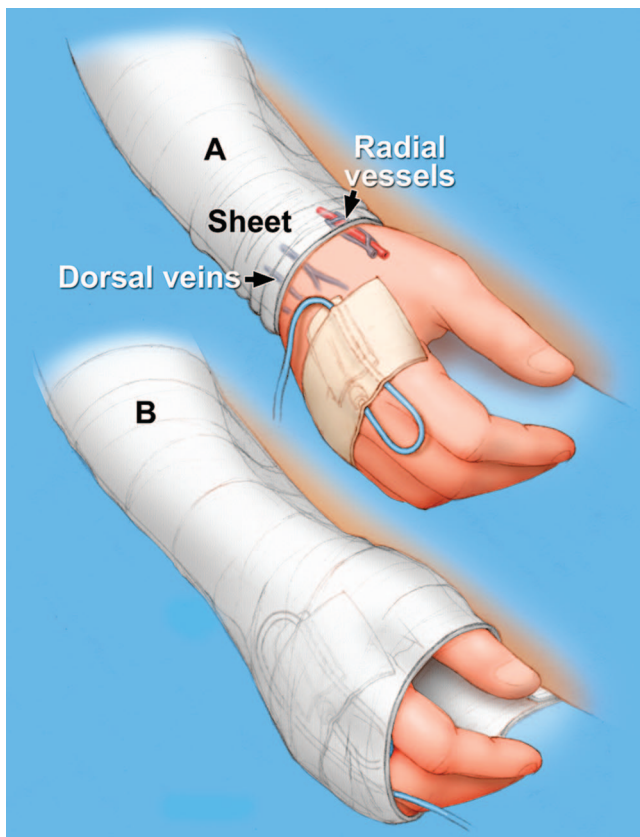


Fig. 1. Use of a draw sheet to secure an arm to a patient's side. (A) This drawing depicts the looped draw sheet tightly wrapped around the wrist, acting as a tourniquet by reducing venous outflow and, potentially, arterial inflow. (B) This drawing shows the draw sheet loosely looped over the entire dorsum of the hand. This use of a draw sheet may decrease the risk of perioperative compartment syndrome of the hand.

similar in width to those used several decades ago. Over this period of time, the mean BMI of the surgical population has increased considerably. For example, at our institution, the mean (\pm SD) BMI of all of our adult surgical patients in 1990 was 23.1 ± 6.3 kg/m². In 2000,

the mean BMI had increased to 25.7 ± 6.6 kg/m², an increase of 11% in just one decade. Continued requests by surgeons to tuck patients' arms at their sides for many abdominal and pelvic procedures may result in vigorous or overzealous use of the draw sheet as a mechanism for positioning the arms.

We propose that, whenever possible, alternatives to the use of draw sheets for arm positioning should be considered when the arms do not rest easily and with ample room at the patient's sides. Two simple alternatives include adding width to the operating room table with expander attachments and abducting one or both arms to the sides and supporting them on arm boards. If the use of a draw sheet is used to tuck patients' arms at their sides, we suggest that anesthesia providers and others confirm that the proximal (cephalad) and distal (caudad) ends of the draw sheet are loose and, for the hand, draped over the entire surface of its dorsum (fig. 1B). This confirmation should reduce the risk of vascular obstruction and potential for compartment syndrome of the upper extremity and hand.

In summary, we found that compartment syndrome of the hand with no apparent preexisting cause and requiring fasciotomy occurred rarely and, in most cases, resulted in minor disability after 6 months. Although it is possible that a tourniquet effect at the ends of draw sheets used to retain the arms of patients at their sides during the intraoperative period may be a contributing factor, other unknown mechanisms may be responsible, and additional investigations are needed.

References

1. Martin JT: Compartment syndromes: Concepts and perspectives for the anesthesiologist. *Anesth Analg* 1992; 75:275-83
2. Warner ME, LaMaster LM, Thoeming AK, Marienau ME, Warner MA: Compartment syndrome in surgical patients. *ANESTHESIOLOGY* 2001; 94:705-8
3. Ortiz JA Jr, Berger RA: Compartment syndrome of the hand and wrist. *Hand Clin* 1998; 14:405-18

Severe Subluxation in the Sniffing Position in a Rheumatoid Patient with Anterior Atlantoaxial Subluxation

Ichiro Takenaka, M.D.,* Yasunari Urakami, M.D.,† Kazuyoshi Aoyama, M.D.,‡ Tadanori Terada, M.D.,† Hiroshi Ishimura, M.D.,† Tamao Iwagaki, M.D.,† Tatsuo Kadoya, M.D.§

SPECIAL attention should be paid to airway management in rheumatoid patients with atlantoaxial subluxation (AAS) because they may be at risk of life-threatening neurologic injury caused by worsening the subluxation in the head and neck position during airway maneuver.¹⁻⁵ Atlantoaxial subluxation is found in 11-46% of patients with rheumatoid arthritis and is classified into four groups according to the direction of the subluxation, including anterior AAS, posterior AAS, vertical AAS, and lateral AAS.^{6,7} Anterior AAS is the most prevalent form, accounting for 80% of all types of subluxations.^{6,7} In rheumatoid patients with anterior AAS, the degree of subluxation has been estimated in association with flexion and extension at the entire cervical spine (the head and neck) as a functional unit.^{6,7} During flexion of the entire cervical spine, the atlas separates anteriorly from the axis, and the subluxation is worsened. On the contrary, during extension, the atlas slides backward until it rests against the dens of the axis, and the subluxation is reduced. Therefore, standard anesthesia textbooks advocate avoiding flexion of the head and neck in rheumatoid patients with anterior AAS.^{3,4} The sniffing position is widely recommended as the standard head and neck position for conventional laryngoscopy.^{8,9} This position consists of two components, which are severe extension of the head at the occipitoatlantoaxial (OAA) complex and slight flexion of the neck at the subaxial cervical segments.^{8,9} In this position, the direction of movement of the OAA complex (head movement) and that of the subaxial segments (neck movement) are opposite.^{8,9} Theoretically, extension of the OAA complex reduces the subluxation, and flexion of the subaxial segments makes it worse in rheumatoid patients with anterior AAS. In general, it is believed that accomplishment of the sniffing position is tolerated in these patients because the OAA complex where the subluxation occurs is extended, and the degree of the subaxial flexion is mild.^{2,10} However, whether this

position is safe is still unknown. We report a case of the rheumatoid patient with anterior AAS that was markedly worsened by the sniffing position.

Case Report

A 61-yr-old, 160-cm, 47-kg woman with rheumatoid arthritis was admitted for reconstruction of the rheumatoid distal radioulnar joint. She had had rheumatoid arthritis for 18 yr. Three years previously, the patient had undergone bilateral total knee replacements during combined spinal epidural anesthesia. Airway examination consisted of Mallampati class 2 with a hyomental distance of 5 cm and a mouth opening of 5 cm. The patient could move her head and neck without limitation and was asymptomatic in every head and neck position. Radiographic examination of the cervical spine for rheumatoid patients was performed in our radiology center the day before surgery. When the patient lay down on a flat table, lateral cervical radiographs were taken in three head and neck positions, which were the head on the flat table without a pillow, extension of the entire cervical spine obtained by bending part of the table, and the sniffing position obtained by placing 7 cm of a pillow under the head.^{8,9} These positions were determined by actively positioning with the patient's effort. Radiographs revealed marked AAS of the anterior atlas-dens interval (AADI) of 10 mm and the posterior atlas-dens interval (PADI) of 12 mm in the sniffing position, compared with an AADI of 2 mm with both the head on the flat table without a pillow and extension of the entire cervical spine (fig. 1). The AADI and PADI were defined as the distance between the posterior surface of the anterior arch of the atlas and the anterior surface of the dens and the distance between the posterior surface of the dens and the anterior surface of the posterior arch of the atlas, respectively.⁷ Preoperative laboratory results were normal except for mild anemia. The patient requested to have general anesthesia because of the stress she had experienced during regional anesthesia during a previous operation. We planned fiberoptic intubation, with the patient awake and under sedation, using manual in-line stabilization because of the necessity of providing a guaranteed airway for the surgical procedure lasting for 1.5-3 h and the technique minimizing the head and neck motion with which we had the most expertise. After the patient was counseled, she agreed to the procedure.

The patient received atropine (0.5 mg) 30 min before surgery. In the operating room, the patient lay supine on the operating table, and her head was placed on the flat table without a pillow. We confirmed that the patient was neurologically asymptomatic in this position. The standard monitors, including electrocardiography, indirect arterial pressure, pulse oximetry, and capnography, were applied, and midazolam (2 mg) was administered intravenously. After appropriate topical anesthesia, fiberoptic intubation was performed with manual in-line stabilization while the patient was awake. After successful intubation was confirmed, anesthesia was induced with propofol. Oxygen saturation did not decrease below 98% throughout intubation. The operation proceeded uneventfully. After the patient fully awakened, the trachea was extubated using manual in-line stabilization. We confirmed that the patient did not have any neurologic deficits.

* Director of Surgical Center, † Staff Anesthetist, § Chief Anesthetist, Department of Anesthesia, Nippon Steel Yawata Memorial Hospital. ‡ Chief Anesthetist, Department of Anesthesia, Moji Rosai Hospital, Kitakyushu, Japan.

Received from the Department of Anesthesia, Nippon Steel Yawata Memorial Hospital, Kitakyushu, Japan. Submitted for publication March 23, 2004. Accepted for publication June 22, 2004. Support was provided solely from institutional and/or departmental sources.

Address correspondence to Dr. Takenaka: Department of Anesthesia, Nippon Steel Yawata Memorial Hospital, 1-1-1 Harunomachi, Yahatahigashi-ku, Kitakyushu 805-8508, Japan. Address electronic mail to: takenaka.i@ns.yawata-mhp.or.jp. Individual article reprints may be purchased through the Journal Web site, www.anesthesiology.org.

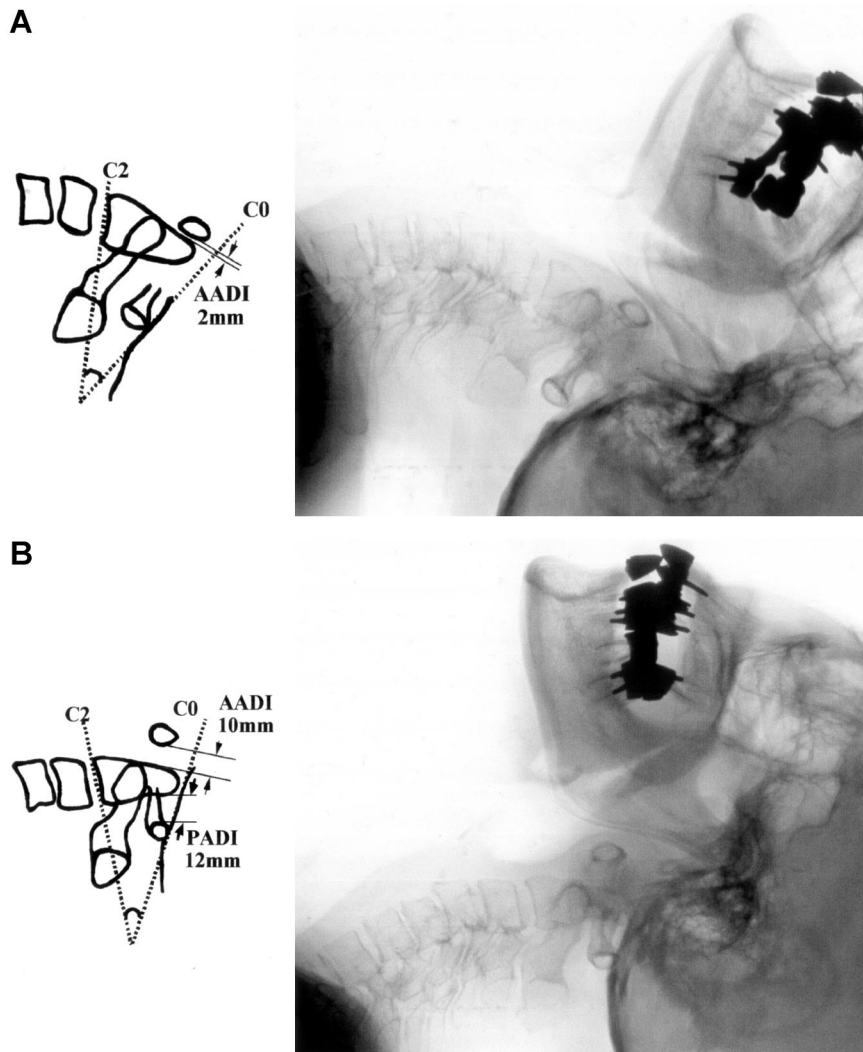


Fig. 1. Lateral radiographs and diagrams in extension of the entire cervical spine (A) and the sniffing position (B) showing marked atlantoaxial subluxation of the anterior atlas–dens interval (AADI) of 10 mm and the posterior atlas–dens interval (PADI) of 12 mm in the sniffing position, compared with an AADI of 2 mm in extension of the entire cervical spine. The AADI and PADI are defined as the distance between the posterior surface of the anterior arch of the atlas and the anterior surface of the dens and the distance between the posterior surface of the dens and the anterior surface of the posterior arch of the atlas, respectively.⁷ In addition, the subluxation occurs at the C4–C5 level in the sniffing position (B). Radiographs are taken when the patient lies down on the flat table, and the head and neck position is determined by actively positioning with the patient's effort. The sniffing position is achieved by placement of 7 cm of a pillow under the head,^{8,9} and extension of the entire cervical spine is accomplished by bending part of the table. Despite the same degree of occipitoatlantoaxial extension, severe subluxation occurs only in the sniffing position. Reference lines for the occiput (C0) and the axis (C2) are defined as the McGregor line and the line passing through anterior and posterior basal plate of the C2 vertebral body, respectively.¹⁴

Discussion

The stability of the OAA complex is mainly maintained by the transverse, apical, and alar ligaments.^{1,7} Of these, the transverse ligament is pivotal for keeping the dens securely in place, but it is prone to be affected by synovial inflammation and hyperemia of the adjacent articulations related to rheumatoid arthritis.^{1,7} When the transverse ligament alone is disrupted, AAS of the AADI of up to 5 mm occurs.^{1,7} If the apical and alar ligaments in addition to the transverse ligament are disrupted, the AADI amounts to more than 10 mm.^{1,7} At this stage, the occiput and the atlas are separated from the axis and the lower cervical vertebrae, and the cervical spine is divided into the occiput–atlas component and the axis–lower component. In the current patient, all of the ligaments stabilizing the OAA complex were disrupted because of an AADI of more than 10 mm. We considered mechanisms for occurrence of the subluxation in the sniffing position in our patient as follows. When the neck was flexed by placing a pillow under the occiput for achieving the sniffing position, the occiput–atlas

component was pushed forward, leaving the axis–lower component behind, and AAS occurred. Head extension was expected to correct the subluxation as a result of placement of the pillow. However, because all of the ligaments contributing to the stability of the OAA complex were disrupted, force at the occiput–atlas component producing by head extension was not transmitted to the axis–lower component, and the AAS remained unchanged. If the apical and alar ligaments were intact even with disruption of the transverse ligament, the AAS might be corrected because the occiput–atlas component was connected to the axis–lower component. Whether AAS is corrected may depend on degree of disruption of ligaments stabilizing the OAA complex. That is, AAS is not always corrected by head extension in rheumatoid patients with anterior AAS. Therefore, achievement of the sniffing position is dangerous in these patients.

Compression of the spinal cord occurs when the AADI is more than 9 mm or the PADI is less than 14 mm in patients with anterior AAS.^{1,7,11} However, despite an

AADI of 10 mm and a PADI of 12 mm in the sniffing position, our patient was asymptomatic. There are some patients with AAS who are entirely asymptomatic, and AAS can occur without obvious abnormalities at other peripheral joints.^{1,4,7} The subluxation, even if severe, is not always easy to diagnose with only symptoms and signs. Also, in the current patient, the head and neck position during radiography was determined by actively positioning with the patient's effort. Dvorak *et al.*¹² showed that the degree of the cervical spine motion found by passively positioning by an examiner was greater than that by actively positioning with the patient's effort. Moreover, when general anesthetics, muscle relaxants, or both are used, the splinting action of the cervical muscles on the cervical spine is lost, which may enhance motion of the cervical spine by passively positioning. Calder *et al.*¹⁰ reported that the prevalence of difficult laryngoscopy was high in patients with rheumatoid arthritis. Also, with routine preoperative airway evaluation tests, prediction of difficult laryngoscopy is often difficult. These facts indicate that preoperatively undiagnosed AAS can be worsened in patients with rheumatoid arthritis as a result of excessive motion of the cervical spine if a laryngoscopist passively achieves the sniffing position while the patient is under general anesthesia, muscle relaxation, or both to improve the view of the larynx during direct laryngoscopy when unanticipated difficult laryngoscopy is encountered, which may cause life-threatening neurologic injury. Bollensen *et al.*⁵ reported a case of a patient with rheumatoid arthritis and unrecognized AAS in whom tetraplegia with respiratory insufficiency due to dislocation of the dens occurred after airway management. To overcome this problem, it is essential to recognize AAS and to plan an appropriate strategy for airway management. Therefore, the cervical spine should be evaluated radiographically before anesthesia in all patients with rheumatoid arthritis. Airway techniques minimizing head and neck movement are recommended in rheumatoid patients with anterior AAS. Fiberoptic intubation is useful not only for this purpose but also for managing difficult airways. Wattenmaker *et al.*¹³ demonstrated that the fiberoptic intubation reduced postoperative upper airway complications in patients who had posterior operations on the cervical

spine for rheumatoid arthritis. Fiberoptic intubation is a reliable method. When conventional laryngoscopy is necessary for tracheal intubation, attention must be paid to the head and neck position during the maneuver.

In summary, this case illustrates that accomplishment of the sniffing position for laryngoscopy can result in exacerbation of the subluxation with resultant neurologic injury in rheumatoid patients with anterior AAS. Therefore, these patients' tracheas should be intubated in a manner in which head and neck movement is minimized. In addition, preoperative radiologic assessment of the cervical spine is recommended because of the difficulty in diagnosis of AAS with merely clinical evaluation in these patients.

References

1. Crosby ET, Lui A: The adult cervical spine: Implications for airway management. *Can J Anaesth* 1990; 37:77-93
2. Macarthur A, Kleiman S: Rheumatoid cervical joint disease: A challenge to the anaesthetist. *Can J Anaesth* 1993; 40:154-9
3. Sharrock NE, Savarese JJ: Anesthesia for orthopedic surgery, Anesthesia, 5th edition. Edited by Miller RD. Philadelphia, Churchill Livingstone, 2000, pp 2118-39
4. Dierdorf SF: Anesthesia for patients with rare and coexisting diseases, *Clinical Anesthesia*, 4th edition. Edited by Barash PG, Cullen BF, Stoelting RK. Philadelphia, Lippincott Williams & Wilkins, 2001, pp 491-520
5. Bollensen E, Schonle PW, Braun U, Prange HW: An unnoticed dislocation of the dens axis in a patient with primary chronic polyarthritis undergoing intensive therapy. *Anaesthesist* 1991; 40:294-7
6. Bland JH: Rheumatoid subluxation of the cervical spine. *J Rheumatol* 1990; 17:134-7
7. Resnick D, Niwayama G: Rheumatoid arthritis and the seronegative spondyloarthropathies: Radiographic and pathologic concepts, *Diagnosis of Bone and Joint Disorders*, 3rd edition. Edited by Resnick D. Philadelphia, WB Saunders, 1995, pp 807-970
8. Horton WA, Fahy L, Charters P: Disposition of cervical vertebrae, atlantoaxial joint, hyoid and mandible during x-ray laryngoscopy. *Br J Anaesth* 1989; 63:435-8
9. Benumof JL: Conventional (laryngoscopic) orotracheal and nasotracheal intubation (single-lumen tube), *Airway Management; Principles and Practice*, 1st edition. Edited by Benumof JL. St. Louis, Mosby, 1995, pp 261-76
10. Calder I, Calder J, Crockard HA: Difficult direct laryngoscopy in patients with cervical spine disease. *Anaesthesia* 1995; 50:756-63
11. Weissman BNW, Alibadi P, Weinfeld MS, Thomas WH, Sosman JL: Prognostic features of atlanto-axial subluxation in rheumatoid arthritis. *Radiology* 1982; 144:745-51
12. Dvorak J, Froehlich D, Penning L, Baumgartner H, Panjabi MM: Functional radiographic diagnosis of the cervical spine: Flexion/extension. *Spine* 1988; 13:748-55
13. Wattenmaker I, Concepcion M, Hibberd P, Lipson S: Upper-airway obstruction and perioperative management of the airway in patients managed with posterior operations on the cervical spine for rheumatoid arthritis. *J Bone Joint Surg (Am)* 1994; 76:360-5
14. Urakami Y, Takenaka I, Nakamura M, Fukuyama H, Aoyama K, Kadoya T: The reliability of the Bellhouse test for evaluating extension capacity of the occipitoatlantoaxial complex. *Anesth Analg* 2002; 95:1437-41