

Severe Thrombocytopenia, Type 2B von Willebrand Disease and Pregnancy

David L. Hepner, M.D.,* Lawrence C. Tsen, M.D.†

VON Willebrand's Disease (vWD) is the most common inherited bleeding disorder in humans with an estimated incidence as high as 2-3% in the general population.¹ Characterized by abnormal platelet interactions with the subendothelium or other platelets, the disease is caused by changes in the multimeric glycoprotein, von Willebrand's Factor (vWF).¹ Types 1 and 3 vWD are associated with relative or absolute quantitative defects in the protein, respectively. Type 1 vWD accounts for 70% of all cases and is likely to temporally improve in parturients as a result of an increase in vWF and factor VIII with pregnancy.² Type 2 vWD has qualitative abnormalities and comprises 20-30% of all vWD diagnoses. A unique subtype, type 2B, accounts for less than 20% of all type 2 vWD and is characterized by an increased affinity of vWF for platelet glycoprotein Ib, resulting in spontaneous binding and clearance of both vWF and platelets.^{3,4} This feature allows type 2B, unlike most other vWD variants, to be exacerbated by pregnancy and to exhibit a poor or worsening response to desmopressin (DDAVP; Aventis, Bridgewater, NJ).^{5,6} We present the management of a parturient with type 2B vWD who had severe thrombocytopenia during the peripartum period.

Case Report

A 35-yr-old, 157-cm, 71-kg, uniparous woman, gravida 2 presented to our high-risk anesthesia consultation service at 36 weeks' gestation. Although the patient reported no known drug allergies, the use of aspirin was associated with prolonged bleeding. Her history was notable for chronic hepatitis C, with no associated liver dysfunction, resulting from a blood transfusion and type 2B vWD, which was diagnosed as a child because of a strong family history (grandmother, mother, uncle, and brother) of type 2B vWD. Her obstetric history included a normal spontaneous vaginal delivery at 39 weeks' gestation 2 yr previously without neuraxial analgesia. The platelet count at the time of her first delivery was 20,000 giga/l, and the patient was given antihemophilic factor (factor VIII) (Humate-P; Aventis, Bridgewater, NJ) 3,000 ristocetin cofactor units intravenously on becoming fully dilated and per day for 48 h. Five days postpartum, the patient was readmitted for a perineal bleeding from a laceration, which was treated

successfully with vaginal packing, four units of packed red blood cells, factor VIII 3,000 ristocetin cofactor units intravenously, and aminocaproic acid (Amicar; Immunex, Seattle, WA) 5 g *per os* loading dose followed by 3 g *per os* every 3 h.

The current pregnancy had a breech presentation, for which the patient was scheduled for a cesarean delivery. The platelet count at the time of consultation was 46,000 giga/l and the international normalized ratio 1.0; consultation with the hematologist included a plan to give factor VIII 4,000-4,500 ristocetin cofactor units followed by a unit of pheresis platelets starting 1 h before the procedure. On the day of the delivery, 2 weeks later, the initial platelet count was 36,000 giga/l and factor VIII and platelets were given. Within 30 min of the transfusion and before a planned spinal anesthetic technique, a repeat platelet count was drawn; the results demonstrated a platelet count of 30,000 giga/l. An additional unit of platelets was given in anticipation of bleeding during the cesarean delivery and the anesthetic plan was changed to a general anesthetic. Anesthesia was induced *via* rapid sequence with 250 mg sodium thiopental, 100 mg of succinylcholine, and 100 µg of fentanyl. A male infant with Apgar scores of 8¹ and 9⁵ was delivered 3 min after the anesthetic induction. On closing the abdomen, no excessive intraoperative bleeding was observed, the total blood loss was estimated at 1,000 ml, and the patient had received a total of 2,800 ml of lactated Ringer's solution. After tracheal extubation, an intraoperative sample sent for a platelet count was reported as 10,000 giga/l. The hematology consultant recommended additional factor VIII (5,000 units every 12 h for 3 days) to be commenced immediately. The obstetric team followed the recommendation and gave an additional unit of pheresis platelets as well. Six hours after delivery, serial platelet counts revealed progressive increases from 20,000 giga/l to 31,000 giga/l at 24 h, 42,000 giga/l at 48 h, and 53,000 giga/l at the time of discharge on postoperative day four. No postpartum hemorrhagic complications occurred and no additional thrombogenic products were needed. At time of hospital discharge, vWF ristocetin cofactor activity (vWF:RCO) and factor VIII concentrations were 454% and 258%, respectively.

Discussion

Previously defined by multimer analysis, the current classification scheme recognizes three general types of vWD based on molecular mechanisms.⁷ Types 1 and 3 represent partial and severe quantitative deficiencies of vWF and type 2 exhibits a qualitative deficiency. A characteristic gain-of-function phenotype, subtype 2B, may be the result of single amino acid substitutions within the A1 domain of vWF.^{4,8,9} These changes result in an increased interaction between vWF and the glycoprotein Ib-IX-V complex in platelets¹⁰ and an acceleration in binding and clearance of vWF and platelets; this interaction can be exacerbated by an increased production of vWF that can be produced with stressful clinical situations, of which pregnancy is well recognized.^{2,11,12} The resulting thrombocytopenia can be impressive, as observed in our case, and of sufficient concern as to allow

* Assistant Professor of Anaesthesia, † Associate Professor of Anaesthesia.

Received from Harvard Medical School and the Department of Anesthesiology, Perioperative and Pain Medicine, Brigham and Women's Hospital, Boston, Massachusetts. Submitted for publication February 27, 2004. Accepted for publication June 22, 2004. Support was provided solely from institutional and/or departmental sources.

Address reprint requests to Dr. Tsen: Department of Anesthesiology, Perioperative and Pain Medicine, Brigham and Women's Hospital, 75 Francis Street, Boston, MA 02115. Address electronic mail to ltsen@zeus.bwh.harvard.edu. Individual article reprints may be purchased through the Journal Web site, www.anesthesiology.org.

some hematologists to support vWD testing for all women with thrombocytopenia in pregnancy.⁵

Neonatal thrombocytopenia may also occur with parturients with type 2B vWD,^{1,4} and in our case, the initial platelet count in the newborn was 35,000 giga/l. Antenatal testing for fetal vWD is possible but not often recommended; fetal morbidity and mortality may be associated with testing and the results are not always predictive of neonatal bleeding. The collection of cord blood at the time of delivery for vWD testing is preferable, and in our case, although the neonatal plasma vWF quantity was normal, the vWF activity and the amount of plasma factor VIII were markedly decreased. The possibility of neonatal vWD should not, however, prompt a cesarean delivery, as increased maternal bleeding may occur.¹³ Instead, a vaginal delivery with the avoidance of an episiotomy or instrumented delivery is preferable.² The decision for cesarean delivery in our case was based on the breech presentation and an appropriate obstetric reluctance to perform either an external cephalic version or a vaginal breech delivery. All intramuscular injections were avoided in the mother and neonate, and a planned circumcision in the male infant was postponed.

Although desmopressin, a vasopressin analog that raises plasma vWF, is a common therapy for vWD, in type 2B vWD it can increase the abnormal vWF, resulting in further binding of platelets, depletion of high molecular weight multimers, and potentially greater bleeding.^{10,14-16} As such, the preferred therapy for this specific vWD subtype is factor VIII plasma concentrate (FVIII) (Humate-P or Alphanate; Grifols, Los Angeles, CA), which, although FDA approved for hemophilia and not vWD, provides the following corrective components: 2.5 IU vWF:RCo, 1 IU of FVIII, and a near-normal count of high molecular weight multimers.^{1,14,17,18} Threshold values of vWF:RCo and FVIII greater than 50 IU/dl at the time of delivery and for 72-96 h after an uncomplicated vaginal delivery and for 96-120 h after a cesarean section have been proposed.¹⁸

Although the treatment and goals for vWF:RCo and FVIII are relatively straightforward, the response to thrombocytopenia remains controversial. In part, this is because of the variation in thrombocytopenia observed in patients with type 2B vWD, which can be both intermittent and variable in expression, from mild to severe. In addition, the etiology of the thrombocytopenia is often unclear. Platelet aggregation has been confirmed by a number of investigations to occur spontaneously and with the use of desmopressin in patients with type 2 vWD.^{15,19} However, recent work suggests that desmopressin with this subtype may cause a "false" thrombocytopenia, resulting from short-term agglutination, but not aggregation.²⁰ Moreover, the significance of the thrombocytopenia is unclear; some have suggested that the thrombocytopenia *per se* observed in type 2B vWD is not a major risk factor for bleeding, representing

sequestration and margination of platelets, with later availability, rather than consumption.⁵

In our case, FVIII was given to increase the vWF:RCo and FVIII concentrations. The decision to transfuse platelets was prompted by the desire to have a platelet count greater than an arbitrary threshold of 50 giga/l for the spinal anesthesia and cesarean section. Although these platelets may have provided additional substrate for further aggregation and consumption of both vWF and platelets,⁴ we hypothesized that the degree of thrombocytopenia would be further accentuated by the surgical stress. Moreover, therapy with platelet transfusions has been found useful in some patients with type 2B vWD.¹⁵ Whether FVIII given simultaneously with platelet transfusions is more efficacious in treating type 2B vWD induced thrombocytopenia is currently unknown. What our case demonstrates, however, is that the quantitative response to FVIII and platelet transfusions is slow.

Ultimately, our decision to proceed with general anesthesia was based on a risk-benefit analysis, weighing the risk of neuraxial bleeding with a regional anesthetic *versus* the more common failed airway scenario observed in the parturient.²¹⁻²³ Although difficult airways can not always be identified *a priori*,^{24,25} especially during pregnancy,^{22,26} we elected the general anesthetic based on our patient having a Mallampati class 2 airway, a wide mouth opening, a 5 cm thyromental distance, and a reasonable body mass index. If a more challenging airway had been observed, a regional anesthetic would have been more strongly considered, however, not before adequate vWF:RCo, FVIII, and platelet concentrations were obtained. Had our parturient presented in labor with a vertex presentation, intravenous patient-controlled analgesia with opioids would have been offered; were the desire for additional analgesia requested and hematologic goals achieved, a regional labor analgesic would have been considered. Despite these care algorithms, which were consistent with the desire of the patient to remain awake during her cesarean delivery, the falling platelet concentration despite hematologic intervention resulted in a general anesthetic being used.

This report emphasizes the severity of thrombocytopenia that can result in parturients with type 2B vWD. Early consultation with all involved healthcare providers, including obstetricians, hematologists, and anesthesiologists, and appropriate considerations should be made. Experience with this subtype of vWD suggests a correlation between vWF:RCo and FVIII concentrations and normal hemostasis exists,¹ and therapy should be directed to these endpoints. The implications and treatment of thrombocytopenia deserve further investigation. Consideration of neuraxial analgesic or anesthetic techniques in these patients should weigh the risks and benefits of various approaches and the observation that certain therapies for type 2B vWD may be ineffective or slow.

References

- Nichols WC, Ginsburg D: von Willebrand Disease. *Medicine* 1997; 76:1-20
- Fausett B, Silver RM: Congenital disorders of platelet function. *Clin Obstet Gynecol* 1999; 42:390-405
- Ruggeri ZM, Pareti FI, Mannucci PM, Ciavarella N, Zimmerman TS: Heightened interaction between platelets and factor VIII/von Willebrand factor in a new subtype of von Willebrand's disease. *N Engl J Med* 1980; 302:1047-51
- Mathew P, Greist A, Maahs JA, Lichtenberg EC, Shapiro AD: Type 2B vWD: The varied clinical manifestations in two kindreds. *Haemophilia* 2003; 9:137-44
- Giles AR, Hoogendoorn H, Benford K: Type IIB von Willebrand's disease presenting as thrombocytopenia during pregnancy. *Br J Haematol* 1987; 67:349-53
- Conti M, Mari D, Conti E, Muggiasca ML, Mannucci PM: Pregnancy in women with different types of von Willebrand Disease. *Obstet Gynecol* 1986; 68:282-5
- Sadler JE, Grainick HR: A new classification for von Willebrand disease. *Blood* 1994; 84:676-9
- Ginsberg D, Bowie EJ: Molecular genetics of von Willebrand disease. *Blood* 1992; 79:2507-19
- Ginsberg D, Sadler JE: von Willebrand disease: A database of point mutations, insertions, and deletions. *Thromb Haemost* 1993; 69:177-84
- Facey DA, Favalaro EJ, Koutts J, Berndt MC, Hertzberg MS: Identification and characterization of a novel mutation in von Willebrand factor causing type 2B von Willebrand's disease. *Br J Haematol* 1999; 105:538-41
- Kadir RA, Lee CA, Sabin CA, Pollard D, Economides DL: Pregnancy in women with von Willebrand's disease or factor XI deficiency. *Br J Obstet Gynaecol* 1998; 105:314-21
- Chediak JR, Alban GM, Maxey B: von Willebrand's disease and pregnancy: Management during delivery and outcome of offspring. *Am J Obstet Gynecol* 1986; 155:618-24
- Burlingame J, McGaraghan A, Kilpatrick S, Hambleton J, Main E, Laros RK: Maternal and fetal outcomes in pregnancies affected by von Willebrand disease type 2. *Am J Obstet Gynecol* 2001; 184:229-30
- Nitu-Whalley IC, Griffioen A, Harrington C, Lee CA: Retrospective review of the management of elective surgery with desmopressin and clotting factor concentrates in patients with von Willebrand disease. *Am J Hematol* 2001; 66:280-4
- Rick ME, Williams SB, Sacher RA, McKeown LP: Thrombocytopenia associated with pregnancy in a patient with type IIB von Willebrand's disease. *Blood* 1987; 69:786-9
- Rauch R, Budde U, Schneppenheim R, Ries M, Girisch M, Klinge J: A 2-year old boy with recurrent severe bleeding: von Willebrand type 2B and ITP-or von Willebrand type 2B alone? *Eur J Pediatr* 1999; 158:S171-3
- United Kingdom Haemophilia Centre Doctors' Organisation (UKHCO): Guidelines on the selection and use of therapeutic products to treat haemophilia and other hereditary bleeding disorders. *Haemophilia* 2003; 9:1-23
- Walker ID, Walker JJ, Colvin BT, Letsky EA, Rivers R, Stevens R: Investigation and management of haemorrhagic disorders in pregnancy. *J Clin Path* 1994; 47:100-8
- Holmberg L, Nilsson IM, Borge L, Gunnarsson M, Sjorin E: Platelet aggregation induced by 1-desamino-8-D-arginine vasopressin (DDAVP) in type IIB von Willebrand's disease. *N Engl J Med* 1983; 309:816-21
- Casonato A, Steffan A, Pontara E, Zucchetto A, Rossi C, De Marco L, Girolami A: Post-DDAVP thrombocytopenia in type 2B von Willebrand disease is not associated with platelet consumption: failure to demonstrate glycoalbumin increase or platelet aggregation. *Thromb Haemost* 1999; 81:224-8
- Rocke DA, Murray WB, Rout CC, Gouws E: Relative risk analysis of factors associated with difficult intubation in obstetric anesthesia. *ANESTHESIOLOGY* 1992; 77:67-73
- Hawthorne L, Wilson R, Lyons G, Dresner M: Failed intubation revisited: 17-yr experience in a teaching maternity unit. *Br J Anaesth* 1996; 76:680-4
- Pilkington S, Carli F, Dakin MJ, Romney M, De Witt KA, Dore CJ, Cormack RS: Increase in Mallampati score during pregnancy. *Br J Anaesth* 1995; 74:638-42
- Tse JC, Rimm EB, Hussain A: Predicting difficult endotracheal intubation in surgical patients. *Anesth Analg* 1995; 81:254-8
- Bellhouse CP, Dore C: Criteria for estimating likelihood of difficulty of endotracheal intubation with the Macintosh laryngoscope. *Anaesth Intensive Care* 1988; 16:329-337
- Barnardo PD, Jenkins JG: Failed tracheal intubation in obstetrics: A 6-year review in a UK region. *Anaesthesia* 2000; 55:690-4

Anesthesiology 2004; 101:1467-70

© 2004 American Society of Anesthesiologists, Inc. Lippincott Williams & Wilkins, Inc.

Spinal Epidural Hematoma after Spinal Anesthesia in a Patient Treated with Clopidogrel and Enoxaparin

Rainer J. Litz, M.D.,* Birgit Gottschlich, M.D.,* Sebastian N. Stehr, M.D.†

IN recent years newly developed antiplatelet drugs such as the thienopyridine derivatives ticlopidine and clopidogrel are being increasingly used in patients with cardiovascular disease. Knowledge of their pharmacokinetics is crucial for appropriate perioperative care. Therefore, updated guidelines for the concomitant use of these drugs and locoregional anesthesia have been issued by the American Society of Regional Anesthesia and Pain Medicine¹ and by European societies of anesthesiologists² concerning a risk-benefit ratio as well as specific time intervals that should be maintained between the last drug administration and performance of neuroaxial blocks or withdrawal of catheters. Because of

differences in pharmacokinetics, a free interval of at least 7 days for clopidogrel and of 10-14 days for ticlopidine is recommended before performance of central neuraxial blocks (provided that platelet count and coagulation time are in a normal range). Concurrent use of additional medication affecting clotting mechanisms may increase the risk of bleeding disorders. We report a patient transferred to our hospital with a history of clopidogrel intake who received low molecular weight heparin for prophylaxis of thromboembolism in the perioperative course of difficult and traumatic spinal anesthesia. Despite maintaining a free interval of 7 days after the last clopidogrel intake, adhering to guidelines concerning low molecular heparin application, and despite the fact that clotting tests were normal, spinal epidural hematoma developed after spinal anesthesia.

* Staff Anesthesiologist, † Resident, Department of Anesthesiology and Critical Care Medicine, University Hospital Dresden, Technical University Dresden.

Received from the Department of Anesthesiology and Critical Care Medicine, University Hospital Dresden, Technical University Dresden, Dresden, Germany. Submitted for publication March 16, 2004. Accepted for publication July 2, 2004. Support was provided solely from institutional and/or departmental sources.

Address correspondence to Dr. Litz: Department of Anesthesiology and Critical Care Medicine, University Hospital Carl Gustav Carus, Fetscherstrasse 74, 01307 Dresden, Germany. Address electronic mail to: rainer.litz@mailbox.tu-dresden.de. Individual article reprints may be purchased through the Journal Web site, www.anesthesiology.org.

Case Report

A 81-yr-old woman (height, 160 cm; weight, 75 kg) with American Society of Anesthesiologists physical status III had received spinal anesthesia for elective fasciotomy and perforator vein ligation because of a lower limb ulceration. Her medical history included ischemic heart

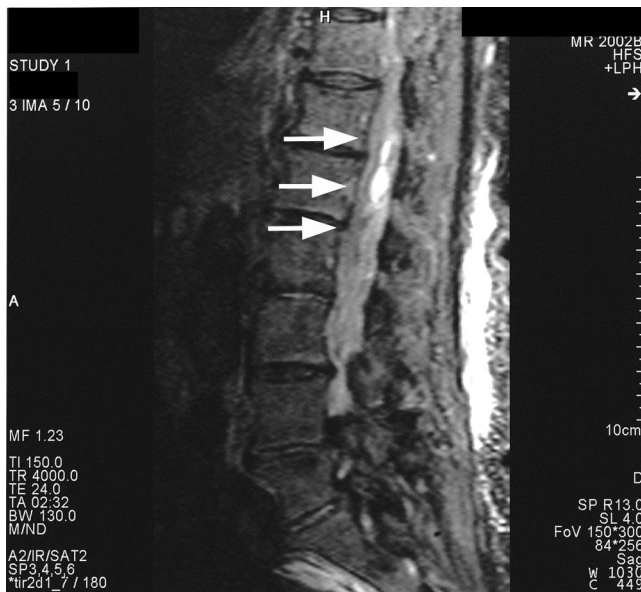

Fig. 1. T2 sagittal magnetic resonance image showing the large extension of the hematoma (arrows), as well as its heterogeneity.

disease grade II (Canadian Cardiovascular Society angina classification) with atrial fibrillation, compensated renal insufficiency (creatinine clearance 34 ml/min), hypertension, and insulin-dependent diabetes. Her oral medication included molsidomine (Corvaton™; Aventis Pharma Deutschland GmbH, Bad Soden, Germany), pirtanide/ramipril (Arelis ACE™; Aventis Pharma Deutschland GmbH), spironolactone/furosemide (Furorese™; Hexal AG, Holzkirchen, Germany), metoprolol (Beloc zok™; AstraZeneca GmbH, Wedel, Germany), and xipamid (Aquaphor™; Lilly Deutschland GmbH, Bad Homburg, Germany) for treatment of hypertension, ischemic heart disease, and renal insufficiency. Diabetes was treated with subcutaneous insulin. In addition, she was treated daily with 75 mg clopidogrel (Iscover™; Bristol-Myers Squibb GmbH, München, Germany) for ischemic heart disease which was discontinued 7 days before surgery.

Preoperatively the activated partial thromboplastin time was 39 s (normal range, 30–40 s), the prothrombin time was 85% (normal range, 70–120%) and the international normalized ratio was 1.02 (therapeutic level, 2–4.5), platelet count was $161 \times 10^9/l$, at the lower limit of the normal range ($150 \times 10^9/l - 400 \times 10^9/l$).

Spinal anesthesia was performed by an experienced staff anesthesiologist using a 22-gauge Sprotte needle. However, the first attempt failed at L3–4 because of repeated bone contact as well as a sanguine puncture presumed to be outside the epidural space. At the L4–5 level subarachnoid puncture was performed uneventfully in the first attempt and 3 ml of plain bupivacaine 0.5% was injected. Within 10 min maximum level of sensory block reached the T8 dermatome. Surgery was performed uneventfully and the regression of the block was complete within 4 h. The patient was mobilized on the evening of the day of surgery. For prophylaxis of thromboembolism the patient received two doses of low molecular weight heparin (enoxaparin) 40 mg 8 and 36 h after lumbar puncture. During the second postoperative night, 4 h after the second enoxaparin administration, the patient complained of voiding difficulty, and a urinary catheter was applied. At that time neither sensory nor motor deficiency was observed. On the morning of the second postoperative day the patient complained of numbness and weakness in both lower limbs. No back pain was reported. Emergency magnetic resonance imaging revealed spinal epidural hematoma extending from T12 to L3, with a maximum diameter between T12 and L1 (figs. 1–3). The patient was transferred to the university hospital and presented with lower paraplegia and a Th12

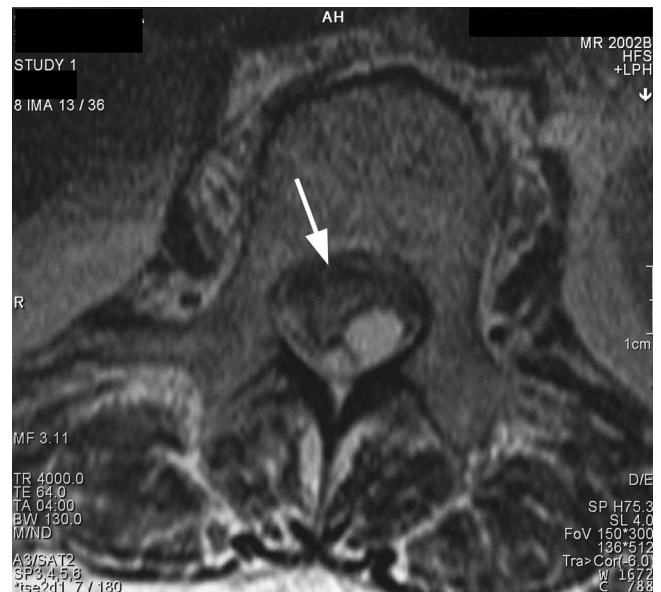


Fig. 2. T2 axial magnetic resonance image showing the hematoma (L2).

sensory loss. Emergency decompressive laminectomy was performed 20 h after the first signs of bladder dysfunction were observed. Before the second surgical procedure coagulation profile was documented as activated partial thromboplastin time 44, prothrombin time 81, international normalized ratio 1.22, and a platelet count of $216 \times 10^9/l$. The operative site showed a partially liquid and partially organized hematoma, which was difficult to resect as organized parts showed strong adhesion to the conus and seemed to obstruct epidural veins. No lesions related to puncture or vessel malformations were seen.

Postoperatively, the patient could partially be mobilized and only slowly recovered from her neurologic deficiencies. Three weeks after laminectomy sensory deficiency up to T12 and motor block Bromage 2 were documented.

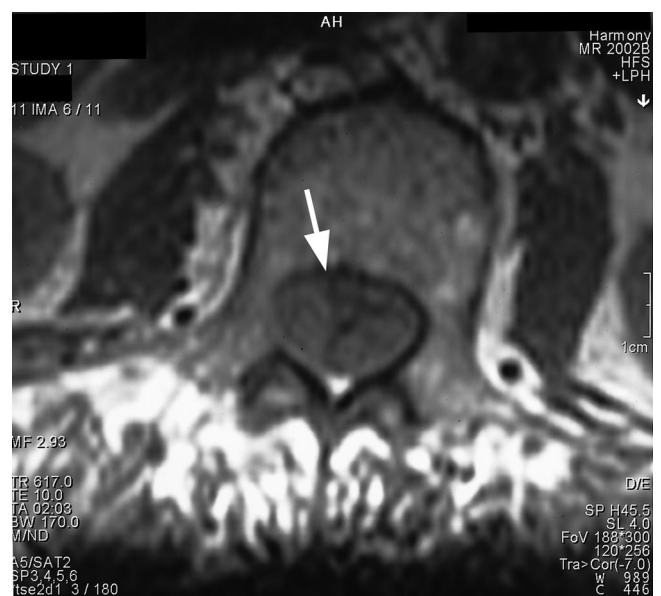

Fig. 3. T1 axial magnetic resonance image showing the hematoma (L2).

Discussion

Beneficial effects have been demonstrated for new antiplatelet drugs in cardiovascular patients, especially for thienopyridine derivatives in preventing stroke.³⁻⁵ As an increasing number of patients is treated with these drugs, anesthetists must be familiar with their mechanism of action. In Europe two orally applicable adenosine diphosphate receptor antagonists are available that differ in clinical pharmacology. Both drugs inhibit platelet aggregation by noncompetitive nonreversible interaction with the adenosine diphosphate (P2Y₁₂) receptor on the outer platelet surface. Blockade leads to an inhibition of adenosine diphosphate mediated platelet activation *via* an increase in intracellular cyclic adenosine monophosphate. In addition, release of calcium, fibrinogen, and serotonin that usually boost platelet activation is averted. Concurrently, alteration of GP IIb/IIIa conformation is inhibited.⁶

Clopidogrel is six times more potent than ticlopidine⁷ and is therefore effective within 3–7 (ticlopidine, 8–10) days after its application.⁸ Normalization of platelet function is restored accordingly to the half-life time of platelets within 7 days (ticlopidine, 7–14 days).⁹ In an animal model high-dose aprotinin partially reversed the effects of clopidogrel.¹⁰ Platelet transfusion is the only effective treatment in cases of severe bleeding in humans.⁶

For clopidogrel a therapy-free interval of 7 days is recommended before performance of neuraxial blocks.^{1,11} In our patient 7 days, as recommended, were maintained and no sustaining clopidogrel impact was suspected.

Nevertheless, an epidural hematoma developed after spinal anesthesia. No case of epidural hematoma occurrence after central neuraxial block performance has been previously reported in patients shortly after a 7 day clopidogrel therapy-free interval. The first sign of epidural bleeding was bladder dysfunction, which was not considered unusual by the nursing staff at that time after spinal anesthesia in a patient of that age. Onset of sensory and motor deficiencies were delayed by approximately 12 h. Once discovered, magnetic resonance imaging was performed immediately and the patient was transferred to our hospital for laminectomy.

We consider four points to be of possible importance in this case:

- First, sanguine puncture occurred, which has been shown to be a general risk factor in development of spinal hematoma.^{12,13} Even though in the first attempt it was presumed that the epidural space was not reached, puncture of an epidural vein can not be excluded.
- Second, as the platelet count was at the lower limit of normal range, platelet regeneration may have been reduced, hence prolonging the effect of the adenosine diphosphate antagonist.
- Third, the exact response to subcutaneous low molec-

ular weight heparin therapy in our patient remains speculative, as subcutaneous blood flow may vary considerably interindividually in the elderly and may result in therapeutic anticoagulation. A further risk factor might have been the moderate impairment of renal function. A linear correlation between antifactor Xa concentrations and renal function has recently been demonstrated in patients receiving low molecular weight heparin, and the authors concluded that a dose adjustment is necessary in patients with a creatinine clearance of less than 30 ml/min.¹⁴ In an older retrospective study even clearance rates lower than 40 ml/min were associated with higher antifactor Xa concentrations.¹⁵ In our patient the clearance was slightly greater than 30 ml/min.

- Finally, a 7–10 day therapy-free interval before operative procedures is recommended according to some manufacturer guidelines.¹⁶ The additive effect of anticoagulatory drugs acting at different sites of the coagulatory cascade should not be underestimated.

In summary, several factors may have equally contributed to the occurrence of an epidural hematoma in our patient. For thienopyridine derivatives clinical possibilities of testing thrombocyte function are limited.¹⁷ This case further underscores the necessity of close neurologic monitoring after spinal anesthesia, especially in applying locoregional anesthetic techniques shortly after the recommended therapy-free interval of clopidogrel.

References

1. Horlocker TT, Wedel DJ, Benzon H, Brown DL, Enneking FK, Heit JA, Mulroy MF, Rosenquist RW, Rowlingson J, Tryba M, Yuan CS: Regional anesthesia in the anticoagulated patient: Defining the risks (the second ASRA Consensus Conference on Neuraxial Anesthesia and Anticoagulation). *Reg Anesth Pain Med* 2003; 28:172-97
2. Buerkle H, Van Aken H, Buettner J, Riess H: Regional anaesthesia and thromboembolism prophylaxis/anticoagulation: Revised guidelines of the German Society of Anaesthesiology and Intensive Care Medicine [in German] *Anästhesiologie und Intensivmedizin* 2003; 44:218-30
3. Hass WK, Easton JD, Adams HP Jr, Pryse-Phillips W, Molony BA, Anderson S, Kamm B: A randomized trial comparing ticlopidine hydrochloride with aspirin for the prevention of stroke in high-risk patients. Ticlopidine Aspirin Stroke Study Group. *N Engl J Med* 1989; 321:501-7
4. Albers GW, Amarenco P, Easton JD, Sacco RL, Teal P: Antithrombotic and thrombolytic therapy for ischemic stroke. *Chest* 2001; 119:300S-20
5. A randomised, blinded, trial of clopidogrel versus aspirin in patients at risk of ischaemic events (CAPRIE). CAPRIE Steering Committee. *Lancet* 1996; 348:1329-39
6. Kam PC, Nethery CM: The thienopyridine derivatives (platelet adenosine diphosphate receptor antagonists), pharmacology and clinical developments. *Anaesthesia* 2003; 58:28-35
7. Steinhubl SR, Tan WA, Foody JM, Topol EJ: Incidence and clinical course of thrombotic thrombocytopenic purpura due to ticlopidine following coronary stenting. EPISTENT Investigators. Evaluation of Platelet IIb/IIIa Inhibitor for Stenting. *JAMA* 1999; 281:806-10
8. Savcic M, Hauert J, Bachmann F, Wyld PJ, Geudelin B, Cariou R: Clopidogrel loading dose regimens: Kinetic profile of pharmacodynamic response in healthy subjects. *Semin Thromb Hemost* 1999; 25 Suppl 2:15-9
9. Weber AA, Braun M, Hohlfeld T, Schwippert B, Tschöpe D, Schrör K: Recovery of platelet function after discontinuation of clopidogrel treatment in healthy volunteers. *Br J Clin Pharmacol* 2001; 52:333-6
10. Herbert JM, Bernat A, Maffrand JP: Aprotinin reduces clopidogrel-induced prolongation of the bleeding time in the rat. *Thromb Res* 1993; 71:433-41
11. Gogarten W, Van Aken H, Buettner J, Riess H, Buerkle H: Neuroaxial regional anaesthesia in patients receiving antithrombotic drugs [in German]. *Anästhesiologie und Intensivmedizin* 2003; 44:218-30

12. Vandermeulen EP, Van Aken H, Vermeylen J: Anticoagulants and spinal-epidural anesthesia. *Anesth Analg* 1994; 79:1165-77
13. Schmidt A, Nolte H: Subdural and epidural hematomas following epidural anesthesia: A literature review [in German]. *Anaesthesist* 1992; 41:276-84
14. Chow SL, Zammit K, West K, Dannenhoffer M, Lopez-Candales A: Correlation of antifactor Xa concentrations with renal function in patients on enoxaparin. *J Clin Pharmacol* 2003; 43:586-90
15. Becker RC, Spencer FA, Gibson M, Rush JE, Sanderink G, Murphy SA, Ball

- SP, Antman EM: Influence of patient characteristics and renal function on factor Xa inhibition pharmacokinetics and pharmacodynamics after enoxaparin administration in non-ST-segment elevation acute coronary syndromes. *Am Heart J* 2002; 143:753-9
16. Kozek-Langenecker SA: Locoregional anesthesia and blood coagulation: Impact of new antiplatelet drugs [in German]. *Anaesthesist* 2003; 52:549-63
17. Narchi P: Spinal anaesthesia and the use of anticoagulants. *Best Pract Res Clin Anaesthesiol* 2003; 17:443-9

Anesthesiology 2004; 101:1470-1

© 2004 American Society of Anesthesiologists, Inc. Lippincott Williams & Wilkins, Inc.

Transient Profound Neurologic Deficit Associated with Thoracic Epidural Analgesia in an Elderly Patient

Adam K. Jacob, M.D.,* James C. Borowiec, M.D.,* Timothy R. Long, M.D.,† Michael J. Brown, M.D.,† Charlotte H. Rydberg, M.D.,‡ C. Thomas Wass, M.D.§

PERIOPERATIVE epidural analgesia has been reported to improve patient outcome after thoracic surgery. Unfortunately, this procedure is not devoid of inherent potential risk. Specifically, numerous case reports describing neurologic deficits resulting from direct needle trauma or epidural mass effect (e.g., hematoma or abscess) have been published.¹⁻³ We report a unique case of transient, yet profound, neurologic deficit that resulted from an unusual epidural mass.

Case Report

A 91 yr-old, 152-cm, 52-kg female was scheduled to undergo elective thoracotomy for repair of a symptomatic type III paraesophageal hiatal hernia using the Belsey Mark intravenous procedure. Her past medical history was remarkable for well-controlled hypertension, primary cancer of the breast, colon, and bladder (all treated without recurrence), chronic anemia, glaucoma, and profound kyphosis (Cobb angle 72°) secondary to osteoporosis. Medications included ranitidine, raloxifene hydrochloride, verapamil, vitamin B12, iron supplements, latanoprost, and timolol maleate.

Two hours before surgery she received 5000 U unfractionated heparin subcutaneously for deep venous thrombosis prophylaxis. On arrival in the operating room, sterile placement of a T6-7 epidural catheter was attempted unsuccessfully. The patient was repositioned, and catheter placement attempted at the T7-8 interspace resulted in dural puncture. A third attempt at the T8-9 level proved successful, as there was a discrete identification of the epidural space (i.e., loss-of-resistance) and the catheter was advanced 4 cm without difficulty. Catheter aspiration was negative for blood, and no discernible neurologic or hemodynamic changes resulted from a 3-ml test dose of lidocaine 1.5% with 1:200,000 epinephrine. Subsequently, the patient was placed supine, general anesthesia was induced, and the epidural catheter was loaded with 4 ml bupivacaine 0.25% plus 0.4 mg hydromorphone. Shortly thereafter, an epidural infusion of 0.075% bupiva-

caine with hydromorphone 5 µg/ml was initiated (and maintained postoperatively) at 6 ml/h.

Postoperatively, she reported good analgesia from the time of arrival in the postanesthesia care unit through the morning hours of the second postoperative day. During the afternoon of postoperative day 2, she developed profound bilateral lower extremity weakness. She denied back pain and was noted to be afebrile. Physical examination confirmed complete bilateral lower extremity paralysis with areflexia and absence of bilateral great toe proprioception. Light touch and temperature sensations were also diminished. Of note, she had received a total volume of approximately 220 ml of epidural infusate since the time of catheter placement. After confirming her coagulation status was normal, the epidural catheter was promptly removed, and emergent neurosurgical consultation and magnetic resonance imaging were obtained. Magnetic resonance imaging revealed an epidural mass in the dorsal left lateral aspect of the spinal canal extending from T6 to T9 with anterolateral spinal cord displacement and compression (fig. 1). Interestingly, the mass was initially thought to be an epidural hematoma. However, upon closer scrutiny of the magnetic resonance scan with our neuroradiologist (Dr. Rydberg), these images revealed features that were more characteristic of a nonheme-containing fluid. Specifically, the T2-weighted image intensity of the mass was consistent with a high water-content containing fluid (e.g., cerebrospinal fluid, local anesthetic, or opioid) with only a scant amount of blood (fig. 1).

The duration from discontinuation of the epidural infusion and completion of magnetic resonance imaging was approximately 90 min. During this time, the patient gradually regained lower extremity motor function. Within 2 h of discontinuing the epidural infusion, the neurologic deficits completely resolved, thereby circumventing the need for emergent surgical decompression. The remainder of her hospital stay was uneventful and she was discharged to an acute rehabilitation facility on postoperative day 7 with no adverse sequelae.

Discussion

We report a unique case of transient profound neurologic deficit in an elderly patient. To our knowledge, this is the first reported case of analgesic infusate and epidural cerebrospinal fluid causing clinically significant spinal cord compression.

Complications of epidural anesthesia include but are not limited to back pain, postdural puncture headache, infection, intravascular injection, inadvertent subdural or intrathecal injection resulting in high neuraxial blockade, arachnoiditis, epidural hematoma, anterior spinal artery thrombosis, and transient or persistent neurologic

* Resident in Anesthesiology, † Assistant Professor of Anesthesiology, § Associate Professor of Anesthesiology, Department of Anesthesiology; ‡ Assistant Professor of Radiology, Department of Radiology.

Received from the Departments of Anesthesiology and Radiology, Mayo Clinic and Mayo Foundation, Rochester, Minnesota. Submitted for publication March 25, 2004. Accepted for publication July 2, 2004. Support was provided solely from institutional and/or departmental sources.

Address reprint requests to Dr. Wass: Department of Anesthesiology, Mayo Clinic, 200 First Street, S.W., Rochester, MN 55905. Address electronic mail to: wass.thomas@mayo.edu. Individual article reprints may be purchased through the Journal Web site, www.anesthesiology.org.

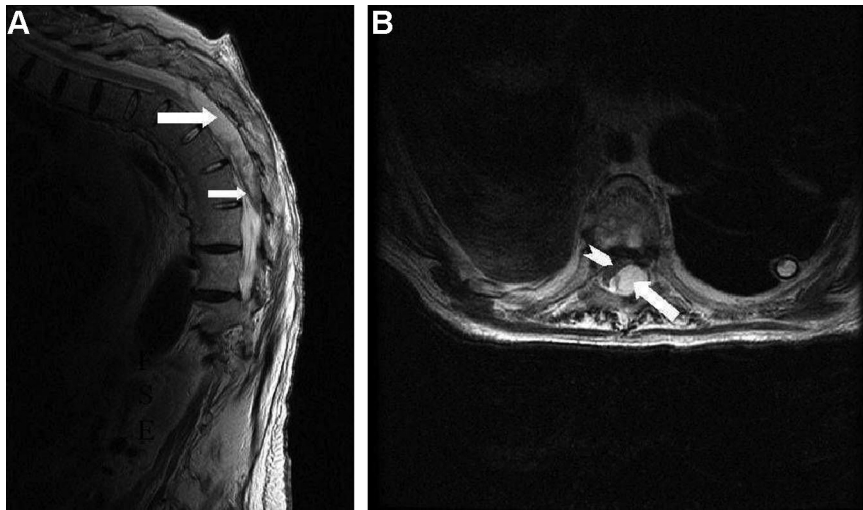


Fig. 1. T2 weighted sagittal (a) and axial (b) magnetic resonance images depicting a large epidural mass (arrows) in the dorsal left lateral aspect of the spinal canal extending from T6 to T9 with anterolateral spinal cord displacement and compression (chevron). The epidural mass was predominantly clear fluid (i.e., cerebrospinal fluid and analgesic infusate; large arrows) with only a scant amount of blood (small arrow).

injury.¹⁻³ With regard to neurologic injury, spinal cord damage may result from direct needle trauma, epidural hematoma formation, epidural abscess, arachnoiditis, or compromised vascular supply (e.g., injury or spasm of the spinal arteries).³ We believe the etiology of our observation was multifactorial. Specifically, dural puncture likely caused extravasation of cerebrospinal fluid into the epidural space. More importantly, the epidural infusate continuously added further volume to this expanding mass, which was particularly problematic because of the advanced age of the patient and severe kyphosis.

In the setting of normal neuraxial anatomy, epidural fluid is readily redistributed longitudinally along the craniocaudal axis, laterally towards the paravertebral region, or anteriorly.⁴ In elderly patients or patients with abnormal anatomy (i.e., severe kyphosis), dispersion of the fluid longitudinally and laterally may be limited, thereby resulting in anterior dispersion (i.e., the pathway offering minimal tissue resistance).⁴ In our patient, this resulted in mass effect and spinal cord compression. Motor deficit without sensory deficit likely resulted from disruption of anterior horn cells as the spinal cord was compressed against the thoracic vertebral bodies.

When faced with new onset neurologic deficits in

patients receiving epidural analgesia, a neuraxial mass must be expeditiously excluded from the differential diagnosis. In addition to making a prompt diagnosis, it has been suggested that surgical decompression should be performed within 8 h of neurologic deficit onset for complete recovery to occur.⁵

In summary, we report a unique case of transient profound neurologic deficit resulting from accumulation of epidural analgesic infusate and epidural cerebral spinal fluid. In our case, we observed early recognition of the epidural mass and discontinuation of the epidural infusion circumvented surgical intervention yet resulted in complete resolution of the profound deficit.

References

1. Brookman CA, Rutledge ML: Epidural abscess: case report and literature review. *Reg Anesth Pain Med.* 2000; 25:428-31
2. Stroud CC, Markel D, Sidhu K: Complete paraplegia as a result of regional anesthesia. *J Arthroplasty* 2000; 15:1064-7
3. Kasai T, Yaegashi K, Hirose M, Tanaka Y: Spinal cord injury in a child caused by an accidental dural puncture with a single-shot thoracic epidural needle. *Anesth Analg* 2003; 96:65-7
4. Usubiaga JE, Wikinski JA, Usubiaga LE: Epidural pressure and its relation to spread of anesthetic solutions in epidural space. *Anesth Analg* 1967; 46:440-6
5. Vandermeulen EP, Van Aken H, Vermeylen J: Anticoagulants and spinal-epidural anesthesia. *Anesth Analg* 1994; 79:1165-77

Sacral Postherpetic Neuralgia and Successful Treatment Using a Paramedial Approach to the Ganglion Impar

Russell K. McAllister, M.D.,* Brad W. Carpentier, M.D.,† Gerald Malkuch, M.D.‡

POSTHERPETIC neuralgia (PHN) is one of the most difficult problems encountered by physicians.¹ Sympathetic nerve blockade has been used with variable success as a component of therapy for PHN in cranial, cervical, thoracic, and lumbar distributions. Sacral dermatomal involvement of PHN occurs in only 3% of patients.² To our knowledge, sympathetic blockade of the ganglion impar (Ganglion of Walther) has never been described as a useful therapy for PHN of the sacral dermatomes. We present a patient with PHN in a sacral distribution who had an excellent response to blockade of the ganglion impar using a paramedial approach to the ganglion.

Case Report

A 74-yr-old woman presented to the pain clinic for evaluation of PHN in the sacral distribution. Her zoster outbreak had occurred 7 months previously with severe rectal and vaginal pain followed several days later by a characteristic cutaneous eruption in the vulvar and perianal distribution. She was diagnosed with acute herpes zoster infection and treated with a course of valacyclovir. Within a few weeks, the cutaneous eruptions cleared; however, the perineal pain persisted. Further evaluation revealed no evidence of gynecologic or rectal abnormalities. Work-up for kidney, bladder, or sexually transmitted infections was negative. She denied any urinary frequency or incontinence. A diagnosis of PHN in the sacral distribution was made, and the patient was treated with Neurontin and tramadol with limited improvement in symptoms.

She was referred to our clinic for further evaluation. Initial physical examination revealed that she sat on one hip on a padded cushion as a result of her discomfort. Examination of the genital and rectal areas revealed no visible abnormalities. She was noted to have allodynia of the external genitalia and in the perirectal area. There were no areas of anesthesia noted. She described her pain as sharp and burning and noted painful bowel movements as well as dyspareunia. She initially received a caudal epidural steroid injection, which gave some mild relief of her symptoms near the coccyx but no relief of her vaginal and rectal pain. On her follow-up visit, she was treated with blockade of the ganglion impar using 12 ml of 0.25% bupivacaine and 40 mg of triamcinolone using a paramedial approach and 22-gauge 3.5-inch spinal needle (Becton-Dickinson, Franklin Lakes, NJ) prepared with

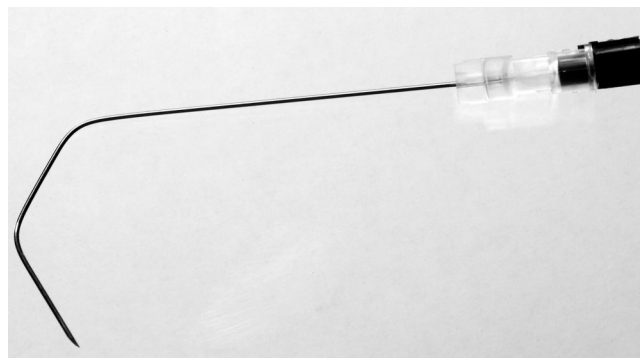


Fig. 1. Preparation of 22-gauge 3.5" spinal needle.

two 110-degree bends (fig. 1). She reported immediate relief of her painful symptoms in the perineal area. Telephone follow-up at 1 week and 2 and 3 months revealed continued relief of 85-90% of her painful symptoms. She reported that she was able to return to normal activities and only occasionally experienced "minimal" pain in the perineum. At 5-month follow-up, the pain had gradually returned to approximately 80% of the pretreatment level. Repeat blockade of the ganglion impar in the same manner reestablished the pain relief. She has now received three ganglion impar blocks with an average period of relief lasting approximately 5 months. She has been extremely pleased with the results.

Discussion

Varicella zoster virus, a member of the herpes virus family, is a significant cause of morbidity. The incidence of *Varicella* (chickenpox) is over 4 million cases per year whereas the incidence of zoster is 300,000 cases per year.³ Primary infection with *Varicella zoster* virus results in *Varicella* (chickenpox); this is followed by a latent phase where the virus remains sequestered in dorsal root ganglia or the trigeminal ganglion. The virus usually remains dormant; however, it may be reactivated, leading to herpes zoster (shingles). Reactivation may be triggered by infection, immunosuppression, trauma, irradiation, malignancy, and advancing age.^{4,5} Herpes zoster is characterized as severe pain in one or more dermatomes usually followed by a vesicular skin eruption 7 to 10 days later. Persistence of painful symptoms for 4-6 weeks after the termination of the acute phase of infection is referred to as PHN.⁶ Prevalence of PHN is 9-45% of all cases of herpes zoster.⁷ Early institution of sympathetic blockade has been advocated to decrease the incidence and severity of PHN.^{8,9} This therapy remains controversial because a direct correlation

* Assistant Professor, ‡ Resident, Department of Anesthesiology, Scott and White Memorial Hospital and Clinic, Scott, Sherwood and Brindley Foundation, and The Texas A&M University System Health Science Center College of Medicine. † Consultant, Pacific Care Institute.

Received from the Department of Anesthesiology, Scott and White Memorial Hospital and Clinic, Scott, Sherwood and Brindley Foundation, and The Texas A&M University System Health Science Center College of Medicine, Temple, Texas, and Pacific Care Institute, Monterey, California. Submitted for publication March 12, 2004. Accepted for publication July 14, 2004. Support was provided solely from institutional and/or departmental sources.

Address reprint requests to Dr. McAllister: Scott and White Memorial Hospital, Department of Anesthesiology, 2401 South 31st Street Temple, TX 76508. Address electronic mail to: rmcallister@swmail.sw.org. Individual article reprints may be purchased through the Journal Web site, www.anesthesiology.org.

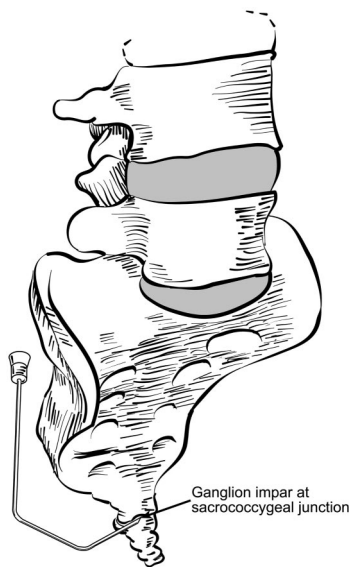


Fig. 2. Needle placement for the paramedial approach to the ganglion impar.

between sympathetic blockade and prevention of PHN has not been proven by randomized prospective trials.

The ganglion impar is a solitary retroperitoneal structure. It is the fused terminal end of the paravertebral sympathetic chain and is found at the level of the sacrococcygeal junction (fig. 2). Neural blockade of the ganglion impar has been advocated as a means of managing intractable pelvic and perineal pain in cancer patients.¹⁰ A review of the literature reveals very limited information on the usefulness of blockade of the ganglion impar for pain other than that of neoplastic origin.

The original technique for blockade of the ganglion impar described by Plancarte and Valazquez¹⁰ involves a midline approach through the anococcygeal ligament with advancement of the needle tip cephalad to the anterior surface of the sacrococcygeal ligament. This technique involves placing one or two bends near the tip of the needle to more easily approximate the location of the ganglion.¹⁰ However, a gently curved needle has also been advocated to negotiate around the natural curve of the coccyx.¹¹ Insertion of a finger in the rectum has been advocated as a safeguard against perforation of the rectum because it lies in close proximity to the solitary ganglion.¹⁰ This technique can be quite uncomfortable in a patient with rectal pathology and also makes it difficult to maintain sterility during the procedure. Wemm Jr. and Saberski¹² advocate passing directly through the sacrococcygeal ligament to reach the ganglion impar. This approach can be useful in patients with normal anatomy but may prove challenging in patients with arthritic changes in the bones and calcification of the ligaments of the sacrum and coccyx. Raj *et al.*¹³ briefly describe a paramedial approach to the ganglion which we have utilized in our clinic for several years.

Huang¹⁴ recently described a lateral approach to the ganglion approaching from below the transverse process of the coccyx inferior to the level of the sacrococcygeal junction. We believe a paramedial approach to the ganglion impar is a beneficial alternative because this technique does not require insertion of a finger in the rectum and may allow a greater tolerance of the procedure for patients and physicians.

The pain caused by postherpetic neuralgia may involve both peripheral and central mechanisms.¹ This understanding likely explains why postherpetic neuralgia is so difficult to treat effectively and also stresses the importance of multiple modality therapy.

The role of corticosteroids in pain relief for this patient is uncertain. Corticosteroid injections with nerve blocks have had unpredictable and limited success in treatment of PHN.¹ Perhaps if further treatment is required for this patient, blockade of the ganglion impar with local anesthetic and no corticosteroid would offer some clarification of the role of corticosteroid in this instance.

Sacral dermatomal distribution of zoster and PHN is unusual but can lead to severe and disabling pain. Blockade of the ganglion impar may play a significant role in treatment of this disabling pain; however, the dramatic results in this patient should be interpreted cautiously. Further investigation is needed to determine efficacy of this sympathetic block in the treatment of the pain of zoster and PHN in the sacral dermatomes. Because of the low incidence of complications with blockade of the ganglion impar, it may have a role in early aggressive therapy of zoster in the sacral dermatomes.

The authors wish to thank Jeff R. Gibson, M.D. (Assistant Professor, Department of Anesthesiology, Scott & White Memorial Hospital, Texas A&M University, Temple, Texas), for valuable comments in the preparation of this manuscript; Bryan Moss (Medical Illustrator, Scott & White Memorial Hospital) for his illustration; Gary Hansen (Corporate Photographer, Scott & White Memorial Hospital) for photography; and Glen Cryer (Publications Manager, Scientific Publications, Scott & White Memorial Hospital, Temple, Texas), Stacy Maness and Julia Blackwell (Medical Editors, Scientific Publications, Scott & White Memorial Hospital, Temple, Texas) for assistance in preparation of this manuscript.

References

1. Raj PP: Postherpetic neurologia, Practical Pain Management, 3rd edition. Edited by Tollison CD, Satterthwaite JR, Tollison JW. Philadelphia, Lippincott Williams & Wilkins, 2002, pp 530-45
2. Peter C, Watson N, Loeser JD: Herpes zoster and postherpetic neurologia, Bonica's Management of Pain, 3rd edition. Edited by Loeser JD, Butler SH, Chapman CR, Turk DC. Philadelphia, Lippincott Williams & Wilkins, 2001, pp 424-32
3. Weller TH: Varicella and herpes zoster: A perspective and overview. *J Infect Dis* 1992; 166:S1-6
4. Kennedy PG, Johnson RT: Neurological complications of Varicella zoster virus, Infections of the Nervous Systems. Edited by Kennedy PG, Johnson RT. London, Butterworths, 1987, pp 177-208
5. Cunningham AL, Dworkin RH: The management of post-herpetic neurologia. *BMJ* 2000; 321:778-9
6. Sharma HV, Gregg RV: Postherpetic neurologia, Essentials of Pain Medicine and Regional Anesthesia. Edited by Benzon HT. Philadelphia, Churchill Livingstone, 1999, pp 267-70

7. Pasqualucci A, Pasqualucci V, Galla F, DeAngelis V, Marzocchi V, Colussi R, Paoletti F, Girardis M, Lugano M, Del Sindaco F: Prevention of post-herpetic neuralgia: Acyclovir and prednisolone versus epidural local anesthetic and methylprednisolone. *Acta Anesthesiol Scand* 2000; 44:910-8
8. Bowsher D: Post-herpetic neuralgia in older patients: Incidence and optimal treatment. *Drugs Aging* 1994; 5:411-8
9. Winnie AP, Hartwell PW: Relationship between time of treatment of acute herpes zoster with sympathetic blockade and prevention of post-herpetic neuralgia: Clinical support for a new theory of the mechanism by which sympathetic blockade provides therapeutic benefit. *Reg Anesth* 93; 18:277-82
10. Plancarte R, Valazquez P: Neurolytic blocks of the sympathetic axis, *Cancer Pain*. Edited by Patt R. Philadelphia, Lippincott Williams & Wilkins, 1993, pp 417-20
11. Nebab EG, Florence IM: An alternative needle geometry for interruption of the ganglion impar. *ANESTHESIOLOGY* 1997; 86:1213-4
12. Wemm K Jr., Saberski L: Modified approach to block the ganglion impar (ganglion of Walther). *Reg Anesth* 1995; 20:544-5
13. Raj PP, Lou L, Erdine S, Staats PS: Ganglion impar block, *Radiographic Imaging for Regional Anesthesia and Pain Management*. New York, Churchill Livingstone, 2003, pp 238-41
14. Huang JJ: Another modified approach to the ganglion of Walther block (ganglion impar). *J Clin Anesth* 2003; 15:282-3