

Double Epidural Catheter with Ropivacaine versus Intravenous Morphine: A Comparison for Postoperative Analgesia after Scoliosis Correction Surgery

Stephan Blumenthal, M.D.,* Kan Min, M.D.,† Marco Nadig, M.D.,* Alain Borgeat, M.D.‡

Background: Major spine surgery with a dorsal or ventrodorsal approach causes severe postoperative pain. The use of continuous epidural analgesia through one or two epidural catheters placed intraoperatively by the surgeon has been shown to provide efficient postoperative pain control. In this prospective unblinded study, the authors compared the efficacy of continuous intravenous morphine with a continuous double epidural catheter technique with ropivacaine after scoliosis correction.

Methods: Thirty patients with American Society of Anesthesiology physical status I-III were prospectively randomized to either the morphine group or the epidural group. At the end of surgery, patients in the epidural group received two epidural catheters placed by the surgeon, one directed cephalad and one caudally. Correct placement was checked radiographically. Postoperative analgesia until the first postoperative morning was performed with remifentanyl target-control infusion for all patients. From that time remifentanyl was stopped and continuous intravenous analgesia with morphine or double epidural analgesia with ropivacaine 0.3% was initiated (T_0 = beginning of study). Pain at rest and pain in motion (using a visual analog scale from 0-100), the amount of rescue analgesics, sensory level, motor blockade, postoperative nausea and vomiting, and pruritus were assessed every 6 h and bowel function was assessed every 12 h until T_{72} (end of study). Two days later, patient satisfaction was assessed.

Results: Pain scores at rest were significantly decreased in the epidural group at all time points except at T_{12} , T_{60} , and T_{72} . Pain scores in motion were significantly decreased in the epidural group at T_{24} , T_{48} , and T_{72} . Bowel activity was significantly better in the epidural group at T_{24} , T_{36} , T_{48} , and T_{60} . Postoperative nausea and vomiting and pruritus occurred significantly less frequently in the epidural group. No complications related to the epidural catheter occurred.

Conclusions: Both methods provide efficient postoperative analgesia. However, double epidural catheter technique provides better postoperative analgesia, earlier recovery of bowel function, fewer side effects, and a higher patient satisfaction.

MAJOR spine surgery with a dorsal or ventrodorsal approach for correction of scoliosis deformation with or without thoracotomy causes severe postoperative pain.¹ Patients undergoing these operations are most often children or adolescents and are known to suffer from increased pain sensation compared to adults.^{2,3} Postoperative pain treatment after spinal surgery is usually

performed with intravenous morphine either continuously applied or with a patient-controlled analgesia device.¹ Epidural analgesia with local anesthetics or opioids is frequently performed after major surgical procedures,^{4,5} and continuous epidural analgesia through one⁶⁻¹⁰ or two^{11,12} epidural catheters placed by the surgeon at the end of the procedure has been shown to provide efficient postoperative pain control after scoliosis correction.

The aim of this prospective unblinded study was to compare the efficacy of continuous double epidural catheter technique with plain ropivacaine with continuous intravenous morphine after a dorsal approach for scoliosis correction. As the appearance of severe neurologic complications occurs during the first 14-16 postoperative hours,¹³⁻¹⁵ the beginning of the ropivacaine infusion was postponed until the next morning to avoid interfering with the neurologic evaluation.

Materials and Methods

After obtaining institutional approval of the local ethics committee (Gesundheitsdirektion des Kantons Zürich, Kantonale Ethik-Kommission, Zürich, Switzerland) and written informed consent, 30 patients were prospectively randomized according to a computer randomization list to either the intravenous morphine group or the double epidural catheter group.

Inclusion criteria were elective correction of idiopathic scoliosis with a dorsal approach over at least seven vertebral levels, American Society of Anesthesiology physical status I-III, 10-30 yr of age, body weight of 30-90 kg, and body height of 130-180 cm. Exclusion criteria were any contraindication for epidural catheter placement, known allergy to drugs used in the study, drug abuse, pregnancy, cardiac arrhythmia or myocardial infarction within the previous 6 months, preoperative neurologic deficit, and inability to use a visual analog scale (VAS) with a scaled ruler for assessing adequately postoperative pain. Exclusion criteria during the study were incorrect epidural catheter placement, accidental perforation of the dura while placing the epidural catheter, or occurrence of postoperative neurologic deficit.

One hour before the beginning of anesthesia all patients were orally premedicated with midazolam 0.1 mg/kg. After arrival in the preoperative anesthetic area, standard monitoring (electrocardiography, blood oxygen saturation, and noninvasive blood pressure measurement) and peripheral venous access was obtained. Anesthesia was induced and

* Consultant, ‡ Professor and Chief-of-Staff, Department of Anesthesiology, † Consultant, Department of Orthopedic Surgery, Orthopedic University Hospital Balgrist, Zurich, Switzerland.

Received from the Orthopedic University Hospital Balgrist, Zurich, Switzerland. Submitted for publication April 27, 2004. Accepted for publication August 24, 2004. Support was provided solely from institutional and/or departmental sources.

Address reprint requests to Dr. Borgeat: Chief-of-Staff of Anesthesia, Orthopedic University Clinic Zurich/Balgrist, Forchstrasse 340, CH-8008 Zurich, Switzerland. Address electronic mail to: aborgeat@balgrist.unizh.ch. Individual article reprints may be purchased through the Journal Web site, www.anesthesiology.org.

maintained performing target-controlled infusion (TCI) with propofol TCI (Deltec Graseby 3500, Laubscher Basel, Basel, Switzerland, and Diprifusor subsystem, AstraZeneca Ltd., Macclesfield, Cheshire, United Kingdom) and with remifentanyl TCI (Deltec Graseby 3500, Laubscher Basel, including a commercially unavailable computer program to calculate the remifentanyl target concentration, according to Minto *et al.*¹⁶). To facilitate tracheal intubation, rocuronium 0.8 mg/kg was given and could be repeated intraoperatively according to surgical needs. After induction of anesthesia, all patients received a urinary catheter and if indicated, a central venous catheter or peripheral arterial catheter. All operations were performed by the same surgeon. The posterior instrumentation of the spine was done with pedicle screws in the thoracic and lumbar spine using universal spine system (USS®, Stratec, Oberdorf, Luzern, Switzerland). The procedures were performed over a minimum of seven or maximum of eleven vertebral levels. Intraoperative monitoring of posterior spinal cord function was assessed with somatosensory evoked potentials.¹⁷ Blood loss was assessed routinely, and a cell saver (Hemonetics Cell Saver 5®; Hemonetics, Signy, Switzerland) was used in all patients. At the end of the scoliosis correction, before wound closure, patients in the epidural group received two multiport (three lateral holed with closed end) epidural catheters (Perifix® 18-gauge Tuohy needle, 20-gauge catheter; B. Braun Melsungen AG, Melsungen, Germany) placed by the surgeon with the loss of resistance technique. The epidural space was assessed through the ligamentum flavum at the appropriate level. The upper catheter was inserted at the cranial end of the wound and the tip was directed 4–5 cm cephalad to Th1–4. The lower catheter was inserted at the caudal end of the wound and the tip was directed 4–5 cm to a position L1–4. Correct placement was checked radiographically at the end of the operation twice with 3 ml contrast medium (Iopamiro®, Bracco s.p.a.; Milano, Italy) through each catheter to obtain anteroposterior and lateral chest radiographs. Propofol TCI was then terminated and remifentanyl TCI reduced until patients fulfilled extubation criteria. The patients were then transferred to the intensive care unit, where a complete neurologic examination was performed. Patients showing any neurologic disorders were excluded from the study.

For all patients, postoperative analgesia was maintained with the ongoing remifentanyl TCI device until the first postoperative morning without activation of the epidural catheters to allow neurologic assessment. The catheters were flushed every 8 h with 2 ml saline before activation. The remifentanyl concentration was titrated to have a patient with VAS less than 20 who could be readily aroused and had a respiratory frequency of ≥ 8 breaths/min. On the first postoperative morning at 08:00 AM (T_0), study medication was initiated as follows: continuous intravenous morphine with $0.05 \text{ mg}\cdot\text{kg}^{-1}\cdot\text{h}^{-1}$ in the morphine group or, in the epidural group, epidural

ropivacaine 0.3% with 4–8 ml boluses according to the height of the patients through each catheter followed by a continuous epidural infusion of ropivacaine 0.3% with two infusion pumps (IVAC P 4000; Welmed, Hampshire, UK). The epidural infusion rate was maintained between 4–10 ml/h in each catheter to obtain a sensory blockade from T_2 to T_{12} . The sensory levels were assessed with pinprick stimulation, using a safety pin and a cold test to assess intact, reduced, or abolished perception. Motor block was evaluated by means of a modified four-grade Bromage scale¹⁸ (0 = no paralysis; 1 = inability to lift the thigh (only able to move knee and feet); 2 = inability to flex the knee (only able to move feet); 3 = inability to move any joint in the legs) every hour for the first 6 h and then every 6 h until T_{72} . Within 3 h after T_0 , remifentanyl was gradually reduced and stopped. All patients received oral rofecoxib once a day (25 mg when < 50 kg or 50 mg when > 50 kg) and intravenous acetaminophen 1 g every 6 h was provided for patients weighing more than 40 kg and 25 mg/kg every 6 h for patients weighing less than 40 kg. As a rescue analgesic, intravenous morphine 0.025 mg/kg was administered if VAS was greater than 30 and titrated to keep a respiratory rate greater than 8 breaths/min.

Hypotension was defined as a decrease of mean arterial pressure of more than 20% compared with the preoperative value. Pulmonary complications were defined as respiratory rate less than 8/min, oxygen saturation less than 92%, or apparent lobar atelectasis on chest radiograph.

Data were assessed by a research nurse not involved with and not aware of the aim of the study and started at T_0 until T_{72} , in all patients. Postoperative pain at rest was assessed at 6-h intervals by means of a VAS from 0–100, where 0 = no pain and 100 = the worst pain imaginable. Pain in motion (during coughing) was assessed at T_{24} , T_{48} , and T_{72} . VAS less than 20 was considered as good, 20–30 was acceptable, and greater than 30 was unacceptable; those patients received supplementary intravenous morphine boluses as rescue analgesia. Pruritus and postoperative nausea and vomiting were assessed every 6 h. Pruritus was rated as 0 = no pruritus and 1 = pruritus. Nausea was defined as an unpleasant feeling in the stomach with or without retching and vomiting was defined as expulsion of gastric content. Every episode of postoperative nausea and vomiting was treated with 1–2 mg intravenous tropisetron. If this therapy was not successful, propofol TCI with target concentration of 0.5–0.8 $\mu\text{g}/\text{ml}$ was initiated.¹⁹ We assessed bowel activity every 12 h and used the following scale: 0 = no bowel activity, 1 = bowel sounds, 2 = first flatus, 3 = first tolerated meal, 4 = first bowel movement. At T_{72} the epidural infusion was stopped and the epidural catheter was removed. Analgesia was then continued with intravenous morphine. Two days later, patients were asked to rate their satisfaction with postoperative pain and analgesia management during the study period on a scale from 0 (not satisfied at all) to 10 (very satisfied).

Table 1. Patient characteristics

	E group (n = 15)	M group (n = 15)
age (y)	17 (± 5)	17 (± 5)
weight (kg)	49 (± 8)	49 (± 9)
height (cm)	156 (± 8)	158 (± 11)
female/male (n)	11/4	12/3
vertebral level fused (n)	9 (± 1)	9 (± 1)
operation time (min)	309 (± 43)	297 (± 42)
time from extubation to start of the study (h ± min)	18 ± 31	18 ± 19

Data are given as mean (± SD).

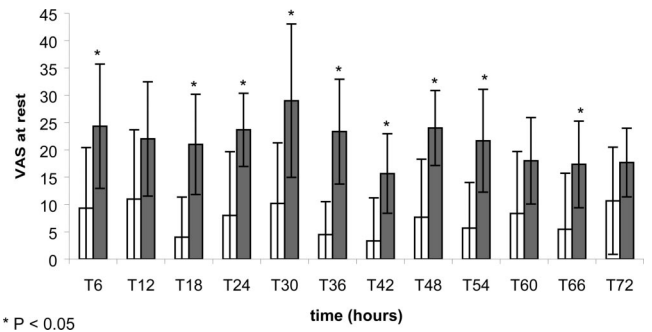
Statistical Analysis

Based on our experience, pain severity in this surgical context was unacceptable in 25% of the patients at rest in the morphine group. A clinical improvement of the pain scores in the epidural group should include a 30% reduction of pain to be considered significant. Based on this data, a power analysis indicated that a sample size of 15 patients per group was sufficient to have 80% power at the 95% significance level.

Demographic data, rescue morphine consumption and patient satisfaction were assessed using the Mann-Whitney U test. VAS values and bowel activity were analyzed using the Mann-Whitney U test with Bonferroni correction for multiple comparisons. Categorical data were analyzed using the Fisher exact test. For all determinations a P value < 0.05 was considered significant.

Results

Thirty patients with idiopathic scoliosis were included over an 18-month period, 15 in the epidural group and 15 in the morphine group. Patient and surgical characteristics are summarized in table 1. No surgical complications occurred. No patient had iliac crest bone harvest. The intraoperative monitoring of dorsal horn activity with somatosensory evoked potentials was unremarkable at any time. Intraoperative blood loss was between 950 and 3000 ml. Re transfusion volumes from the cell saver were between 300 and 960 ml. One patient in each group received one unit of erythrocytes. Radiologic verification ensured that epidural catheters were placed correctly, with the cephalad catheter tip positioned at T4-6 and the lower catheter tip positioned at T10-L1. No technical problem occurred with the epidural catheters during the course of the study. Postoperative clinical neurologic assessment was uneventful. No patient had to be excluded during the course of the study. Patients were extubated under remifentanyl concentrations of 2.5 to 4.5 ng/ml at the effect site. Remifentanyl concentrations of 1.5 to 3 ng/ml at the effect site were sufficient for the control of postoperative pain until the beginning of the study, with awake patients having a respiratory rate greater than 8 breaths/min. After admin-



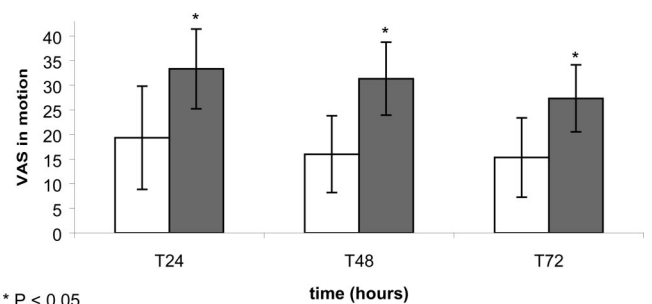
* $P < 0.05$

Fig. 1. Pain at rest was assessed in the epidural group (open bars) and in the morphine group (filled bars) every 6 h from T₆ until T₇₂ using a visual analog scale (VAS) from 0 – 100, where 0 = no pain and 100 = worst pain imaginable. Data are presented as mean ± SD.

istration of the two epidural bolus injections through the epidural catheters, all patients in the epidural group had a homogenous spread of sensory anesthesia within the levels Th1 cranially and L2 caudally.

After the initial epidural ropivacaine bolus, four patients showed a transient motor blockade of more than 1 (one patient had Bromage 2, three patients had Bromage 3) on the modified Bromage scale, which spontaneously resolved within 180 min and did not recur during the continuous epidural infusion until the end of the study (T₇₂).

VAS values were significantly decreased in the epidural group at rest at T₆, T₁₈, T₂₄, T₃₀, T₄₂, T₄₈, T₅₄, and T₆₆ and in motion at T₂₄, T₄₈, and T₇₂ (figs. 1 and 2). At T₇₂, the mean total intravenous morphine consumption for rescue analgesia was significantly decreased in the epidural group (6 ± 3 mg versus 12 ± 5 mg in the morphine group; $P < 0.05$). The occurrence of postoperative nausea and vomiting and pruritus was significantly decreased in the epidural group (figs. 3 and 4). Bowel activity was significantly better in the epidural group compared with the morphine group at T₂₄-T₆₀ (fig. 5). First bowel movement was noted at T₂₄ in 13% and 0%, at T₄₈ in 60% and 6.5%, and at T₇₂ in 66.5% and 40% in the epidural and morphine groups, respectively. In the epidural group, patient satisfaction was 8.3 ± 0.9 as compared with 6.8 ± 0.6 in the morphine group ($P < 0.05$).



* $P < 0.05$

Fig. 2. Pain in motion was assessed in the epidural group (open bars) and in the morphine group (filled bars) at T₂₄, T₄₈ and at T₇₂ using a visual analog scale (VAS) from 0 – 100, where 0 = no pain and 100 = worst pain imaginable. Data are presented as mean ± SD.

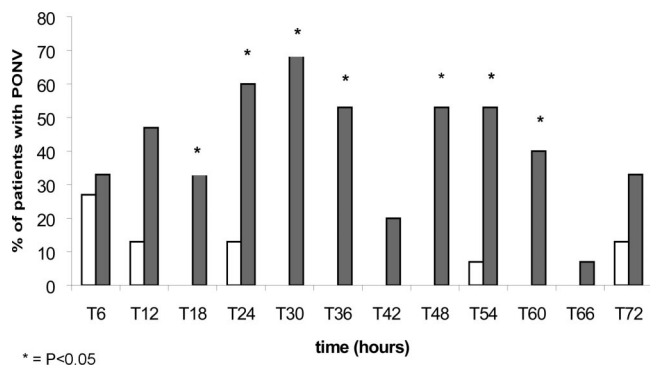


Fig. 3. Postoperative nausea and vomiting (PONV) was assessed in the epidural group (open bars) and in the morphine group (filled bars) every 6 h from T₆ until T₇₂. Data are presented as mean \pm SD.

Discussion

This study demonstrated that continuous epidural infusion with plain ropivacaine 0.3% through two epidural catheters after major scoliosis correction is associated with better pain control, less pruritus and nausea/vomiting, and earlier return of bowel function as compared with intravenous morphine. To our knowledge this is the first controlled prospective randomized study demonstrating the efficacy of the double epidural catheter technique after correction of scoliosis of homogeneous underlying conditions.

Epidural analgesia with local anesthetics or opioids is performed routinely after major thoracic, abdominal and orthopedic surgery, and has proven to be superior to conventional intravenous analgesia providing equal or better pain control with less side effects.^{4,5} The use of ropivacaine 0.3% was chosen because a preliminary pilot study showed this concentration to be associated with better control of pain and without major blockade of the lower limbs as compared with ropivacaine 0.2%. This point is important in this surgical context because early motor block is an issue that has to be recognized quickly.

Turner *et al.*¹⁰ demonstrated in a prospective observational study that surgically placed and radiographically

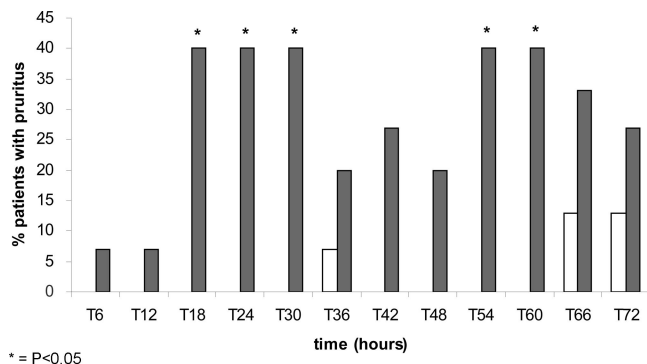


Fig. 4. Pruritus was assessed in the epidural group (open bars) and in the morphine group (filled bars) every 6 h from T₆ until T₇₂. Data are presented as mean \pm SD.

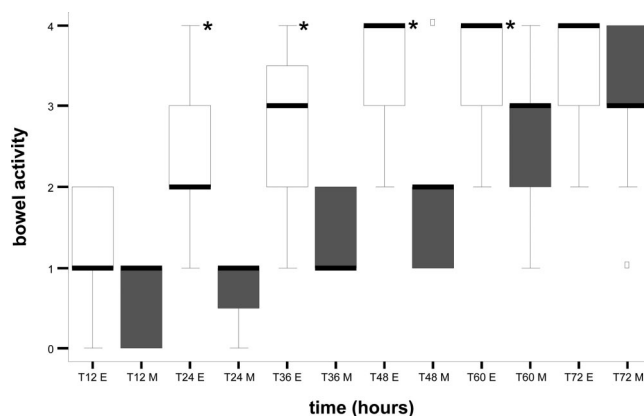


Fig. 5. Bowel activity was assessed in the epidural group (open box plots) and in the morphine group (filled box plots) every 12 h: 0 = no bowel activity; 1 = bowel sounds; 2 = first flatus; 3 = first tolerated meal; 4 = first bowel movement. Box plots show median and 25th and 75th percentiles, whiskers denote 10th and 90th percentiles, and circles indicate outliers. * $P < 0.05$, epidural group compared with the morphine group at the corresponding time point.

verified single thoracic epidural catheters provided a successful pain control in only 64% of the children after posterior spinal fusion. In this study, a mixture of bupivacaine 0.1% with 5 $\mu\text{g/ml}$ fentanyl at a rate up to 15 ml/h was administered through the epidural catheter. Importantly, this trial confirms that clinical experience with a single epidural catheter in this context emphasizes the frequent occurrence of pain localization to the upper or lower parts of the surgical field as a result of incomplete analgesia administration. The only prospective randomized trial comparing a single epidural catheter for postoperative analgesia with intravenous patient-controlled morphine analgesia after posterior spinal fusion could not demonstrate any difference in analgesic efficacy.²⁰ In this study a mixture of bupivacaine 0.125% with fentanyl 2.5 $\mu\text{g/ml}$ was administered at a rate of 0.3 ml/kg per hour. This lack of analgesic benefit, noted by Cassady *et al.*²⁰ may have resulted from the use of the low concentrated bupivacaine with the addition of a low dose of the lipophilic opioid fentanyl to cover 10–12 dermatomes. These results were in contrast with the findings of Tobias *et al.*,¹¹ Ekatodramis *et al.*,¹² and the current study, in which double epidural catheter techniques were used. Tobias *et al.*¹¹ investigated, in an uncontrolled study, the efficacy of dual epidural catheter technique to provide analgesia after posterior spinal fusion in 14 children with mixed underlying conditions. After a bolus with plain ropivacaine 0.2% in volumes of 0.2 ml/kg and 0.1 ml/kg into the lower and upper catheters, a continuous infusion of ropivacaine 0.1% plus hydromorphone 10 $\mu\text{g/ml}$ was infused at 0.2 ml·kg⁻¹·h⁻¹ and 0.1 ml·kg⁻¹·h⁻¹ into the lower and upper catheters, respectively. The authors found that nine of their patients (62%) had episodes of significant pain, which is much higher than our results. Compared with the loss of resistance technique with a

Tuohy needle in our patients, Tobias *et al.* removed a portion of the ligamentum flavum to insert the epidural catheter. It is possible that the opening of the epidural space allows some drug to escape from the epidural space, therefore explaining the decreased percentage of successful analgesia.

Ekatodramis *et al.*¹² performed, in an uncontrolled study, a double epidural catheter technique for postoperative analgesia after spine deformity surgery in 23 adolescents with mixed underlying conditions. The application of a mixture of bupivacaine 0.0625%, fentanyl 2 $\mu\text{g}/\text{ml}$, and clonidine 3 $\mu\text{g}/\text{ml}$ at 10 ml/h for 48 h provided complete analgesia at rest and acceptable analgesia during mobilization in 83% of patients. These results are comparable with ours, although the population in our study was homogenous and no adjuvants to local anesthetic were used.

The analgesic efficacy of 0.3% ropivacaine solution in our study was in accordance with the results of Zaric *et al.*²¹ and Scott *et al.*²². In these studies, a more extensive analgesia with increasing concentrations of ropivacaine 0.1%, 0.2%, and 0.3% was demonstrated. The patients in the epidural group had significantly lower pain scores at rest during the entire study, except at T₁₂, T₆₀, and T₇₂ (fig. 1). The pain was also significantly better controlled during coughing in the epidural group at T₂₄, T₄₈, and T₇₂ (fig. 2). This is in accordance with investigations showing that epidural opioids do not improve the quality of analgesia on dynamically evoked pain like coughing or mobilization.²³ It is therefore unlikely that the addition of an opioid to ropivacaine 0.2% would improve the control of pain in motion.

The decision to use plain ropivacaine in the epidural group was initially based on a desire to avoid the side effects of epidural opioids, such as sedation, nausea and vomiting, pruritus, delayed respiratory depression, urinary retention, and postoperative ileus,^{24,25} conditions which may compromise and delay the early postoperative rehabilitation period. Our results (figs. 3 and 4) were in accordance with the findings of Moriarty *et al.*,²⁵ who had less frequent incidences of nausea and vomiting and pruritus in children who received epidural ropivacaine compared to those who had an epidural bupivacaine/hydromorphone mixture. Our study further showed that the recovery of bowel function was significantly faster in the epidural group from T₂₄-T₆₀ (fig. 5). These results were in accordance with those of Jorgensen *et al.*,^{26,27} who compared epidural local anesthetics with epidural morphine. They acknowledged a better gastrointestinal motility in the epidural group, but this advantage was not sustained beyond the 48 h of epidural infusion.²⁷

Motor blockade of the lower limbs >1 on the modified Bromage scale was observed in four of 15 patients (27%) in the epidural group immediately after the initial bolus. In all four patients, the degree of the motor blockade progressively decreased during the subsequent 180 min

to 1 or 0 on the modified Bromage scale. No patient showed increasing motor blockade during the 72 h of ropivacaine infusion, an observation in accordance with the results of Scott *et al.*²² The possibility of an early motor blockade resulting from ropivacaine led us to continue the infusion of remifentanyl until the first postoperative morning for all patients. This allowed a continuous neurologic assessment during the first 14-18 postoperative hours; this period is the most critical for the development of early secondary neurologic complications.¹³⁻¹⁵ The recognition of motor blockade is therefore mandatory because early detection may prevent the occurrence of irreversible deficits.

This study could be criticized because it was not blinded. However, to minimize bias in the postoperative observations, the nurse responsible for collecting the data were unaware of the aim of the study and not informed about the potential benefits or risks of the treatments. Although it was technically difficult to blind this study, it was possible to reduce the bias in the postoperative measurements by not informing the nurse of the hypothesis of the study.

In conclusion, our results demonstrated that continuous epidural plain ropivacaine 0.3% through two epidural catheters provided better postoperative analgesia at rest and in motion, less side effects, earlier return of bowel function, and higher patient satisfaction compared with intravenous morphine after scoliosis correction.

The association of a continuous infusion of remifentanyl during the first postoperative day with a double epidural technique for subsequent days has the following advantage: it allows a close neurologic assessment during the first postoperative hours, the most likely time for the occurrence of severe neurologic complications, and gives the patient the opportunity to take advantage of good pain control with local anesthetic through epidural catheters without the residual side effects secondary to prolonged opioid infusion.

The authors thank Paul Harpes, Dr. Math., Department of Biostatistics, University of Zurich, Zurich, Switzerland, for his help in performing the statistical analysis.

References

- Joshi GP, McCarroll SM, O'Rourke K: Postoperative analgesia after lumbar laminectomy: epidural fentanyl infusion versus patient-controlled intravenous morphine. *Anesth Analg* 1995; 80:511-4
- Johnston CC, Strada ME: Acute pain response in infants: A multidimensional description. *Pain* 1986; 24:373-82
- Gillies ML, Smith LN, Parry-Jones WL: Postoperative pain assessment and management in adolescents. *Pain* 1999; 79:207-17
- Liu S, Carpenter RL, Neal JM: Epidural anesthesia and analgesia: Their role in postoperative outcome. *ANESTHESIOLOGY* 1995; 82:1474-506
- Block BM, Liu SS, Rowlingson AJ, Cowan AR, Cowan JA, Wu CL: Efficacy of postoperative epidural analgesia: A meta-analysis. *JAMA* 2003; 290:2455-63
- Cohen BE, Hartman MB, Wade JT, Miller JS, Gilbert R, Chapman TM: Postoperative pain control after lumbar spine fusion: Patient-controlled analgesia versus continuous epidural analgesia. *Spine* 1997; 22:1892-6
- Shaw BA, Watson TC, Merzel DI, Gerardi JA, Birek A: The safety of contin-

- uous epidural infusion for postoperative analgesia in pediatric spine surgery. *J Pediatr Orthop* 1996; 16:374-7
8. Arms DM, Smith JT, Osteyee J, Gartrell A: Postoperative epidural analgesia for pediatric spine surgery. *Orthopedics* 1998; 21:539-44
 9. Van Boerum DH, Smith JT, Curtin MJ: A comparison of the effects of patient-controlled analgesia with intravenous opioids versus epidural analgesia on recovery after surgery for idiopathic scoliosis. *Spine* 2000; 25:2355-7
 10. Turner A, Lee J, Mitchell R, Berman J, Edge G, Fennelly M: The efficacy of surgically placed epidural catheters for analgesia after posterior spinal surgery. *Anaesthesia* 2000; 55:370-3
 11. Tobias JD, Gaines RW, Lowry KJ, Kittle D, Bildner C: A dual epidural catheter technique to provide analgesia following posterior spinal fusion for scoliosis in children and adolescents. *Paediatr Anaesth* 2001; 11:199-203
 12. Ekatodramis G, Min K, Cathrein P, Borgeat A: Use of a double epidural catheter provides effective postoperative analgesia after spine deformity surgery. *Can J Anaesth* 2002; 49:173-7
 13. Bridwell KH, Lenke LG, Baldus C, Blanke K: Major intraoperative neurologic deficits in pediatric and adult spinal deformity patients. *Spine* 1998; 23:324-31
 14. Mineiro J, Weinstein SL: Delayed postoperative paraparesis in scoliosis surgery. *Spine* 1997; 22:1668-72
 15. Taylor BA, Webb PJ, Hetreed M, Mulukutla RD, Farrell J: Delayed postoperative paraplegia with hypotension in adult revision scoliosis surgery. *Spine* 1994; 19:470-4
 16. Minto CF, Schnider TW, Egan TD, Youngs E, Lemmens HJ, Gambus PL, Billard V, Hoke JF, Moore KH, Hermann DJ, Muir KT, Mandema JW, Shafer SL: Influence of age and gender on the pharmacokinetics and pharmacodynamics of remifentanyl. I. Model development. *Anesthesiology* 1997; 86:10-23
 17. Hausmann O, Min K, Boni T, Erni T, Dietz V, Curt A: SSEP analysis in surgery of idiopathic scoliosis: the influence of spine deformity and surgical approach. *Eur Spine J* 2003; 12:117-23
 18. Bromage PR: A comparison of the hydrochloride and carbon dioxide salts of lidocaine and prilocaine in epidural analgesia. *Acta Anaesthesiol Scand Suppl* 1965; 16:55-69
 19. Gan TJ, Glass PS, Howell ST, Canada AT, Grant AP, Ginsberg B: Determination of plasma concentrations of propofol associated with 50% reduction in postoperative nausea. *ANESTHESIOLOGY* 1997; 87:779-84
 20. Cassady JF, Lederhaas G, Cancel DD, Cummings RJ, Loveless EA: A randomized comparison of the effects of continuous thoracic epidural analgesia and intravenous patient-controlled analgesia after posterior spinal fusion in adolescents. *Reg Anesth Pain Med* 2000; 25:246-53
 21. Zaric D, Nydahl PA, Philipson L, Samuelsson L, Heierson A, Axelsson K: The effect of continuous lumbar epidural infusion of ropivacaine (0.1%, 0.2% and 0.3%) and 0.25% bupivacaine on sensory and motor block in volunteers: A double-blind study. *Reg Anesth* 1996; 21:14-25
 22. Scott DA, Chamley DM, Mooney PH, Deam RK, Mark AH, Hagglof B: Epidural ropivacaine infusion for postoperative analgesia after major lower abdominal surgery: A dose finding study. *Anesth Analg* 1995; 81:982-6
 23. Gall O, Aubineau JV, Bernière J, Desjeux L, Murat I: Analgesic effect of low-dose intrathecal morphine after spinal fusion in children. *ANESTHESIOLOGY* 2001; 94:447-52
 24. Cucchiaro G, Dagher C, Baujard C, Dubouset AM, Benhamou D: Side effects of postoperative epidural analgesia in children: a randomized study comparing morphine and clonidine. *Paediatr Anaesth* 2003; 13:318-23
 25. Moriarty A: Postoperative extradural infusions in children: Preliminary data from a comparison of bupivacaine/diamorphine with plain ropivacaine. *Paediatr Anaesth* 1999; 9:423-7
 26. Jorgensen H, Fomsgaard JS, Dirks J, Wetterslev J, Andreasson B, Dahl JB: Effect of epidural bupivacaine vs combined epidural bupivacaine and morphine on gastrointestinal function and pain after major gynaecological surgery. *Br J Anaesth* 2001; 87:727-32
 27. Jorgensen H, Fomsgaard JS, Dirks J, Wetterslev J, Andreasson B, Dahl JB: Effect of peri- and postoperative epidural anaesthesia on pain and gastrointestinal function after abdominal hysterectomy. *Br J Anaesth* 2001; 87:577-83