

## Successful Use of Spinal Cord Stimulation in the Treatment of Severe Raynaud's Disease of the Hands

David M. Sibell, M.D., D.A.B.A., A.C.P.M.,\* Anthony J. Colantonio, M.D., D.A.B.A.,†  
Brett R. Stacey, M.D., D.A.B.A., A.C.P.M.\*

RAYNAUD'S Disease is a vasospastic disorder affecting primarily the distal resistance vessels. The disease is typically characterized by the abrupt onset of digital pallor or cyanosis in response to cold exposure or stress. Raynaud's Disease may occur independently or be associated with other conditions (systemic lupus erythematosus and scleroderma) and connective tissue diseases. Initial symptoms may include a burning sensation in the affected area accompanied by allodynia and painful paresthesias with vasomotor (cold, cyanotic) changes. Ultimately, as the ischemia becomes more chronic, this condition may progress to amputation of the affected digits.

The most common indication for spinal cord stimulation in the United States is for chronic painful neuropathies. However, in Europe, spinal cord stimulation is frequently used to treat ischemic conditions, such as peripheral vascular disease and coronary occlusive disease.<sup>1</sup> Although technically an off-label indication in the United States, this practice is supported by many published studies. There have also been case reports of its use in other diseases resulting in arterial insufficiency to the extremities, such as thromboangiitis obliterans (Buerger's Disease),<sup>2</sup> but its use in Raynaud's Disease is relatively underreported.<sup>3</sup>

This case describes the use of cervical spinal cord stimulation to treat refractory digital ischemia in a patient with advanced Raynaud's Disease.

### Case Report

The Vascular Surgery Service consulted the inpatient Acute Pain Service in April, 2003 to evaluate and treat a 51-yr-old female with a long history of Raynaud's Disease. She complained principally of bilateral hand pain (described as 8 of 10 on a verbal analog numeric rating scale) and symptoms of ischemia. Her disease had progressed to the point that she had already had an amputation at the distal phalanx of her left index finger. She had distal ulcerations of several of the digits and had dystrophic nails.

\* Assistant Professor, † Fellow in Pain Medicine, Oregon Health & Science University, Department of Anesthesiology and Perioperative Medicine, Portland, Oregon.

Received from the Oregon Health & Science University, Department of Anesthesiology and Perioperative Medicine, Portland, Oregon. Submitted for publication April 19, 2004. Accepted for publication August 11, 2004. Support was provided solely from institutional and/or departmental sources.

Address correspondence to Dr. Sibell: Oregon Health & Science University, Department of Anesthesiology, Pain Management Center, 3181 SW Sam Jackson Park Rd., UHS-2, Portland, Oregon 97201. Address electronic mail to: sibell@ohsu.edu. Individual article reprints may be purchased through the Journal Web site, www.anesthesiology.org.

She complained of cold intolerance, allodynia, and hyperalgesia of the fingers but also had similar symptoms, to a lesser extent, in the lower extremities. She had been a long-time smoker but had discontinued smoking several months before this consultation. Her pain was poorly controlled with high-dose opioids (methadone 80 mg by mouth every 8 h), as well as gabapentin. She had not responded to tricyclic antidepressants, nonsteroidal antiinflammatory drugs, anticoagulants, or antihypertensive agents. In addition, she had a history of scleroderma, fibromyalgia, and bilateral carpal tunnel syndrome.

Examination of the patient's hands revealed multiple nonhealing ulcers, dystrophic nails, and extreme pallor of all digits. She had severe allodynia, hyperalgesia, and hyperpathia of these digits without extension to the hand or arms. Radial artery pulses were normal (fig. 1).

Therapeutic considerations included recurrent amputation, sympathetic nerve block, surgical sympathectomy, and spinal cord stimulation. The goal of our consultation was to find a treatment plan that would avoid amputation. Sympathetic nerve blocks have a short duration of action and would not have addressed the long-term problem. Furthermore, both sympathetic nerve blocks and surgical sympathectomy lack long-term studies indicating positive long-term outcomes.<sup>4</sup> Therefore, we elected a trial of cervical spinal cord stimulation.

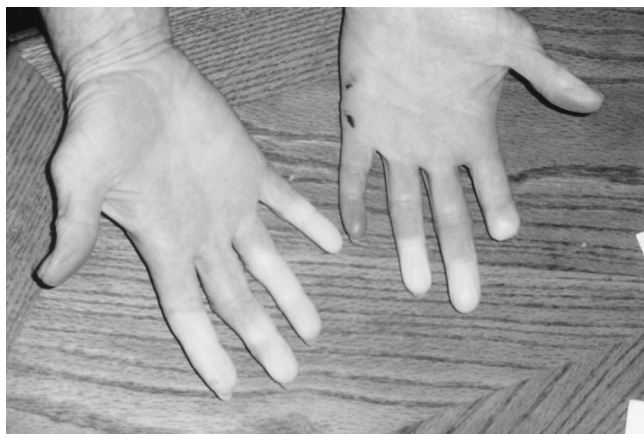This procedure was performed in two phases. In phase I, a single spinal cord stimulator lead (Pisces Quad; Medtronic®, Minneapolis, MN) was placed in the midline. Immediately, the patient noticed a dramatic improvement in circulation and pain in her hands along with paresthesia from the stimulator in the lateral aspects of both arms and forearms and in the entire hand bilaterally. Her allodynia was improved, and her pallor was eliminated.

Because of the substantial improvement in subjective pain, functional capacity, and objective signs of perfusion, bilateral spinal cord stimulator leads (Pisces Quad; Medtronic®) were placed in the posterior epidural space, with the zero electrodes positioned at the C4 level (fig. 2). This resulted in a larger area of paresthesia in both hands. The spinal cord stimulator implanted pulse generator (Synergy; Medtronic®) was subsequently placed in the abdominal subcutaneous tissue. The patient developed a mild cellulitis postoperatively, which responded well to oral antibiotic (cephalexin). She had an uneventful further recovery.

Six weeks after the completion of implantation the patient had a completion amputation of the two distal phalanges of the left index finger as a result of a nonhealing ulcer of the remnant of this digit. Aside from that preexisting ulcer, there was substantial improvement in the objective signs of perfusion and healing of other ulcers and nail dystrophy in the subsequent months.

Five months after the implantation, the patient rated her pain at 2 of 10 and was able to use her hands. She had had no subsequent surgical care or complications associated with her spinal cord stimulator. She was very satisfied with her pain control and functional ability with her hands (fig. 3). She continued on her other medications (with a slight reduction in methadone to 70 mg by mouth every 8 h) because of pain from her other conditions; however, she did not have further hospitalizations for this condition.

At 10 months after implantation, she had some recurrence of ischemia in the right distal index finger, which was previously her most serious area of ischemia. One year after implantation, this finger was amputated at the distal phalanx of this digit. She has had no subsequent digital ischemia, nor has she had recurrent pain outside of this area.

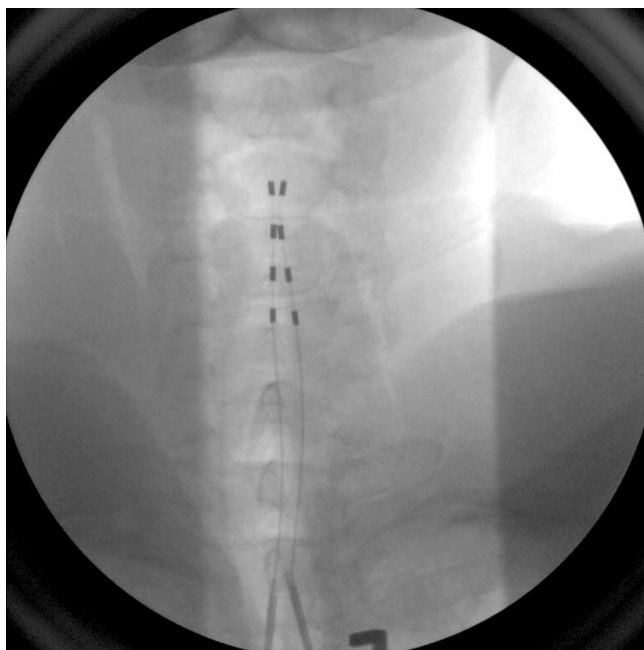

**Fig. 1. Photograph of patient's hands preoperatively.**

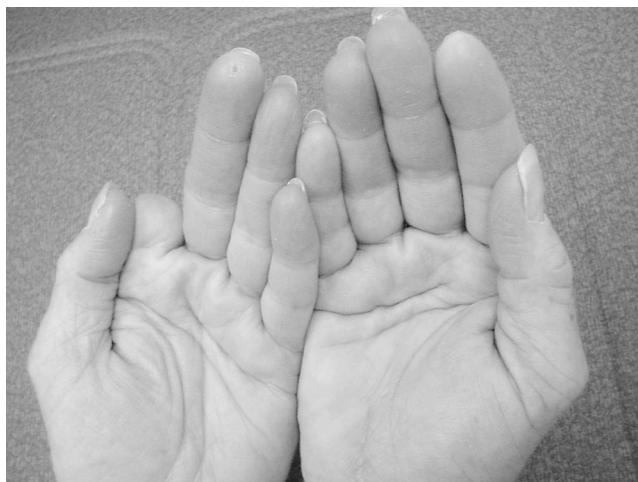Subsequent to this surgery, she has decreased her oral analgesic medications and continues to be active.

Before spinal cord stimulator implantation, this patient had increasingly severe pain and signs of ischemia for approximately 8 yr. Subsequent to implantation, with the exception of her most severely diseased digit, both the subjective complaints of pain and objective signs of ischemia have resolved and have maintained their resolution for more than 1 yr. She has had no other significant changes in medical therapy over that time aside from her surgical treatment.

Spinal cord stimulator settings from her most recent reprogramming session are available for review in the Appendix.



**Fig. 2. Cervical spinal cord stimulator electrode placement.**



**Fig. 3. Photograph of patient's hands 5 months postoperatively.**

## Discussion

The patient's previous history of her history of cigarette smoking predisposed her to vascular disease. However, treatment of the underlying scleroderma and smoking cessation had not improved her symptoms of digital pallor and pain. Her disease progressed to the point of having serial amputation. Introduction of spinal cord stimulation improved her pain control and objective signs of microvascular circulation to the extent that no further amputations have been required except for a completion amputation of a digit already beyond salvage.

There has been substantial controversy regarding the use of spinal cord stimulation in ischemic extremity disease. However, current information favors the use of this treatment in inoperable ischemic extremity disease. There have been a large number of prospective studies, as well as a systematic Cochrane Review, indicating the appropriateness of spinal cord stimulation in this scenario.<sup>5</sup> However, the studies focus primarily on atherosclerotic vascular disease. Although the exact mechanism of action of spinal cord stimulation in ischemic extremity disease is still uncertain, it most certainly affects peripheral vasoconstriction and therefore should be effective in vasospastic disease, such as Raynaud's Disease.

The present case demonstrates effective use of cervical spinal cord stimulation in a case of severe ischemic extremity disease and represents an opportunity for an area of further study.

## Appendix.

### Spinal Cord Stimulator Settings: Dual Lead Pisces Quad/Synergy System

Program 1	
Amp (V): 0.9	
PW ( $\mu$ s): 450	
Rate (Hz): 50	
Electrodes	
Designation	Polarity (N = Neutral)
0	N
1	+
2	+
3	-
4	N
5	N
6	+
7	-
Program 2	
Amp (V): 0.8	
PW ( $\mu$ s): 450	
Rate (Hz): 50	
Electrodes	
Designation	Polarity (N = Neutral)
0	N
1	N
2	+
3	-
4	N
5	+
6	+
7	-

## References

1. Amann W, Berg P, Gersbach P, Gamain J, Raphael JH, Ubbink DT: European Peripheral Vascular Disease Outcome Study SCS-EPOS. Spinal cord stimulation in the treatment of non-reconstructable stable critical leg ischaemia: results of the European Peripheral Vascular Disease Outcome Study (SCS-EPOS). *Eur J Vasc Endovasc Surg* 2003; 26:280-6
2. Swigris JJ, Olin JW, Mekhail NA: Implantable spinal cord stimulator to treat the ischemic manifestations of thromboangiitis obliterans (Buerger's disease). *J Vasc Surg* 1999; 29:928-35
3. Francaviglia N, Silvestro C, Maiello M, Bragazzi R, Bernucci C: Spinal cord stimulation for the treatment of progressive systemic sclerosis and Raynaud's syndrome. *Br J Neurosurg* 1994; 8:567-71
4. Mailis A, Furlan A: Sympathectomy for neuropathic pain. *Cochrane Pain, Palliative Care and Supportive Care Group Cochrane Database of Systematic Reviews*. 4, 2004, 1-24
5. Ubbink DT, Vermeulen H: Spinal cord stimulation for non-reconstructable chronic critical leg ischaemia. *Cochrane Peripheral Vascular Diseases Group Cochrane Database of Systematic Reviews*. 4, 2004, 1-25

Anesthesiology 2005; 102:227-9

© 2004 American Society of Anesthesiologists, Inc. Lippincott Williams & Wilkins, Inc.

## Tramadol and Vocal Cord Closure

Vincenzo Fodale, M.D.,\* Baldassare Mondello, M.D.,† Francesco Mirenda, M.D.,‡ Francesco Spinelli, M.D.,§ Letterio B. Santamaria, M.D.||

TRAMADOL is an analgesic acting as both a weak opioid agonist and an inhibitor of monoamine neurotransmitter reuptake. It also provides effective postoperative analgesia.<sup>1</sup> Unlike other opioids, it is well tolerated and has no clinically relevant effects on cardiovascular parameters; therefore, it is widely administered and may prove particularly useful in patients with poor cardiopulmonary function, including the elderly, and in patients with nonsteroidal antiinflammatory drug contraindications.<sup>2</sup>

The most common side-effects of tramadol (incidence 1.6% to 6.1%) are nausea, dizziness, drowsiness, sweating, vomiting, and dry mouth.<sup>2</sup>

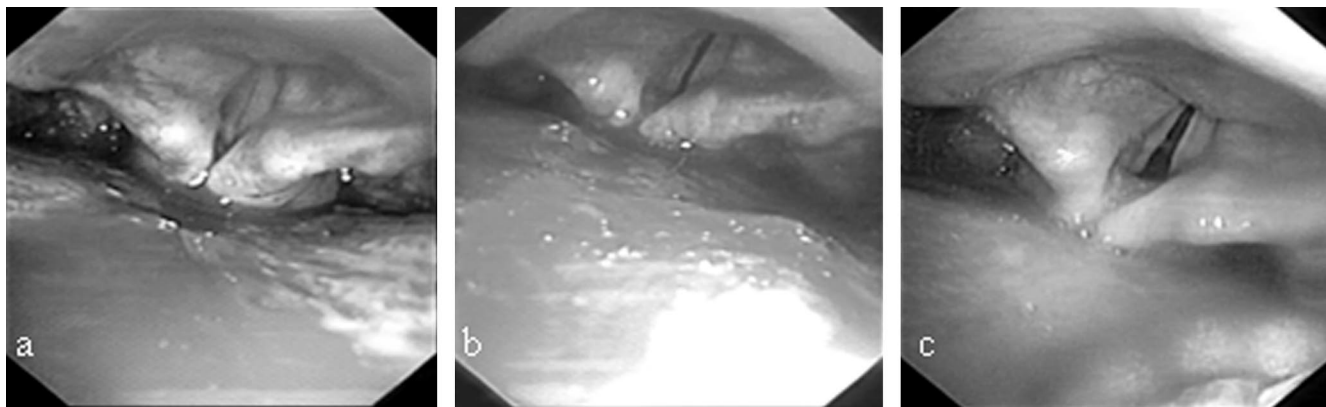
Effects of tramadol on control of breathing have been reported but with divergent points of view. Several clinical studies have reported the absence of a significant respiratory depression by an analgesic dose of tramadol.<sup>3-7</sup> The reputation of tramadol as an analgesic lacking respiratory depression has contributed to its increased clinical use in intraoperative and postoperative periods.<sup>8</sup> Other studies, however, indicate that under some circumstances, tramadol may cause respiratory depression.<sup>9-12</sup> Nieuwenhuijs *et al.*<sup>10</sup> reported that in healthy volunteers tramadol depresses respiration, probably mediated by an effect on  $\mu$ -opioid receptors. However, the affinity of tramadol at  $\mu$ -opioid receptors is much lower (>6,000 times) than that of morphine, and this makes it a potentially interesting analgesic with minimal respiratory depression.<sup>9</sup>

There are no reports of tramadol effects on vocal cords, such as closure or adduction. This is a report of a

\* Research Professor of Anesthesiology and Intensive Care, || Full Professor of Anesthesiology and Intensive Care, Department of Neuroscience, Psychiatric and Anesthesiological Sciences, † Thoracic Surgery Staff, ‡ Vascular Surgery Staff, § Full Professor of Vascular Surgery, Department of Thoracic and Cardiovascular Surgery.

Received from the Department of Neuroscience, Psychiatric and Anesthesiological Sciences and the Department of Thoracic and Cardiovascular Surgery, University of Messina, School of Medicine, Policlinico Universitario "G. Martino," Messina, Italy. Submitted for publication May 7, 2004. Accepted for publication August 12, 2004. Support was provided solely from institutional and/or departmental sources.

Address reprint requests to Dr. Fodale: Via Centonze 49, 98123 Messina, Italy. Address electronic mail to: vfodale@unime.it. Individual article reprints may be purchased through the Journal Web site, www.anesthesiology.org.



**Fig. 1. Fiberoptic bronchoscope vision. Vocal cord closure during inspiratory phase after administration of high doses of tramadol for postoperative pain control (a), progressive opening 4 min after giving naloxone (b), and ulterior improvement in opening 20 min later (c).**

hitherto unknown and potential life-threatening adverse event.

### Case Report

In January 2004, a 76-yr-old, 65 kg, male nonsmoker with a history of diabetes and ischemic heart disease, taking glibenclamide (an oral hypoglycemic medicine) and acenocoumarol (an oral anticoagulant), underwent open vascular surgery for open abdominal aneurysm with insertion of a Dacron prosthesis. After general anesthesia, postoperative pain control was managed administrating an induction dose of tramadol 2 mg/kg followed by a suggested continuous infusion of  $0.20 \text{ mg} \cdot \text{kg}^{-1} \cdot \text{h}^{-1}$  (plus supplementary bolus if required). The aim was to obtain a pain level of 3 or less as measured with the Verbal Pain Scale (ranging from 0 to 10). To obtain this goal, the infusion rate of tramadol was adjusted to  $0.4 \text{ mg} \cdot \text{kg}^{-1} \cdot \text{h}^{-1}$ . Other drugs administered were heparin for prophylaxis of thromboembolism, ondansetron to prevent nausea and vomiting, and antibiotics.

Twenty-eight hours after surgery the patient was calm, pain free (Verbal Pain Scale was 0), and responsive to verbal commands. Respiratory rate was 11 breaths/min, and peripheral oxygen saturation 98%. Approximately 720 mg of tramadol were administered *via* continuous infusion throughout the postoperative period. No other drugs had recently been given with the exception of the continuous heparin infusion. Hemodynamic parameters were well maintained, but the patient exhibited nausea, sweating, weariness, and chest wall rigidity. Mild dyspnea in association with stridor also occurred. Tramadol infusion was stopped, and corticosteroids and oxygen administration were ineffective. Nevertheless, dyspnea with stridor persisted, breathing effort increased, and peripheral oxygen saturation decreased from 98% to 73%. Clinically, the patient was awake with peripheral and mucosal cyanosis, and systolic blood pressure increased to 160 mmHg. A fiberoptic bronchoscope, positioned in the airway, photographed the glottis and documented vocal cord closure without signs of edema (fig. 1a). The ear, nose, and throat specialist diagnosed vocal cord closure and suggested an emergency tracheotomy. Nevertheless, before performing any invasive procedure in a patient with therapeutic reduction of coagulative parameters, the possibility that vocal cord closure could be iatrogenic as a result of opioid assumption was considered. Therefore, under fiberoptic bronchoscope vision, naloxone 1 mg was given intravenously to reverse opioid effects of tramadol. After giving naloxone, a progressive opening of the vocal cords was documented (fig. 1b). Clinically, dyspnea and stridor cessation was observed, with a dramatic improvement of peripheral oxygen saturation up to 95%. As is normally expected in such cases, the patient complained of severe

pain in the surgical wound. A third photograph was taken minutes later, showing further improvement in the vocal cord opening (fig. 1c). All these data suggested an involvement of the opioid effect of tramadol in the genesis of vocal cord closure. Therefore, neither tracheotomy nor endotracheal tube insertion were performed. Thereafter, the patient had an uncomplicated postoperative clinical course and was safely discharged after 7 days.

### Discussion

Vocal cord closure is a life-threatening adverse event causing difficulty in ventilation and hypoxemia.<sup>13</sup> Frequently, emergency intubation or tracheotomy is required.<sup>14</sup>

Opioid administration is related to vocal cord closure. Bennet *et al.*<sup>15</sup> documented progressing cord closure in 28 of 30 patients after administration of morphine, given intramuscularly to provide sedation, and induction with sufentanil, concluding that closure of vocal cords is the major cause of difficult ventilation after opioid-induced anesthesia. Vocal cord closure was also reported in patients receiving fentanyl.<sup>16,17</sup> Lalley *et al.*<sup>18</sup> suggested that low doses of fentanyl act on vagal postinspiratory (laryngeal adductor) motoneurons, whereas in vagal laryngeal adductor and pharyngeal constrictor motoneurons, depression of depolarizing synaptic drive potentials led to sparse, very low frequency discharges. Such effects on three types of vagal motoneurons might explain tonic vocal fold closure and pharyngeal obstruction of airflow.<sup>18</sup>

High-dose opiate administration may be accompanied by intense and generalized muscle rigidity. Studies in animal models suggested that opiate-induced muscle rigidity is primarily the result of activation of central  $\mu$ -opioid receptors.<sup>19</sup> A negative modulatory role of central  $\delta_1$ -opioid and  $\kappa_1$ -opioid receptors on systemic microagony-mediated muscle rigidity has also been demonstrated.<sup>19</sup> Muscle rigidity induced by tramadol administration has also been reported.<sup>20</sup>

It may be surprising that tramadol, a relatively weak

$\mu$ -agonist, produced fentanyl-like effects, as tramadol analgesia is thought to be mediated both through an action on  $\mu$ -opioid receptors and through the inhibition of the reuptake of monoamines or stimulation of their release.<sup>9,21,22</sup> Nevertheless, the opioid effect of tramadol is mediated *via*  $\mu$ -receptors because its affinity at  $\delta$ -receptors and  $\kappa$ -receptors is even lower than at the  $\mu$ -receptor.<sup>9,22,23</sup> Tramadol is a racemic mixture of two enantiomers, and the opioid action is exerted by the (+)-enantiomer and its metabolite O-desmethyltramadol, which has a greater affinity at the  $\mu$ -receptor than its parent compound.<sup>9,22</sup> Moreover, in elderly subjects older than 75 yr, tramadol serum concentrations are slightly increased and the elimination half-life is slightly prolonged. The aged can also be expected to vary more widely in their ability to tolerate adverse drug effects.

In our patient, treatment with the opioid antagonist naloxone led to complete recovery without consequences, confirming that this complication was related to opioid action of tramadol. It was of primary importance to correlate the symptoms experienced by the patient with the opioid drug given, and the consequent and prompt administration of the antagonist avoided emergency invasive treatments, such as endotracheal tube positioning or tracheotomy, high risk solutions in a patient with alterations in coagulation parameters and not free of potential complications *per se*. It is also of interest because the use of tramadol has recently expanded, and an increasing number of elderly patients are medicated with this drug for pain control, often outside the hospital or in the home. Approximately one quarter of the population older than 75 yr use analgesics regularly, and tramadol is one of the most frequently prescribed analgesics.<sup>24</sup>

The primary goal of this case report was to describe the occurrence of vocal cord closure in an aged patient as a result of a high dose administration of tramadol. But the more interesting aspect is that therapy with naloxone led to prompt and complete resolution of this adverse effect. However, the dose of naloxone required to reverse the  $\mu$ -receptor-mediated action of tramadol could be much higher than that usually needed for morphine.<sup>9</sup>

Therefore, this potential life-threatening adverse event, if recognized and related to administration of a high dose of tramadol, may also be promptly and easily managed outside the hospital or in the home by administering the

antagonist naloxone, similarly to other symptoms of opioid overdose.

## References

1. Lehmann KA: Tramadol in acute pain. *Drugs* 1997; 53(Suppl 2):25-33
2. Scott IJ, Perry CM: Tramadol: A review of its use in perioperative pain. *Drugs* 2000; 60:139-76
3. Mildh LH, Leino KH, Kirvela OA: Effects of tramadol and meperidine on respiration, plasma catecholamine concentrations, and hemodynamics. *J Clin Anaesth* 1999; 11:310-6
4. Tarkkila P, Tuominen M, Lingren L: Comparison of respiratory effects of tramadol and pethidine. *Eur J Anaesth* 1998; 15:64-8
5. Tarkkila P, Tuominen M, Lingren L: Comparison of respiratory effects of tramadol and oxycodone. *J Clin Anesth* 1997; 9:582-5
6. Vickers MD, O'Flaherty D, Szekeley SM, Read M, Yoshizumi J: Tramadol: Pain relief by an opioid without depression of respiration. *Anaesthesia* 1992; 47:291-6
7. Houmes RJ, Voets MA, Verkaaik A, Erdmann W, Lachmann B: Efficacy and safety of tramadol versus morphine for moderate and severe postoperative pain with special regard to respiratory depression. *Anesth Analg* 1992; 74:510-4
8. Bamigbade TA, Lanford RM: The clinical use of tramadol hydrochloride. *Pain Rev* 1998; 5:155-82
9. Teppema LJ, Nieuwenhuijs D, Olivier CN, Dahan A: Respiratory depression by tramadol in the cat: Involvement of opioid receptors. *ANESTHESIOLOGY* 2003; 98:420-7
10. Nieuwenhuijs D, Bruce J, Drummond GB, Warren PM, Dahan A: Influence of oral tramadol on the dynamic ventilatory response to carbon dioxide in healthy volunteers. *Br J Anaesth* 2001; 87:860-5
11. Barnung SK, Treschow M, Borgbjerg FM: Respiratory depression following oral tramadol in a patient with impaired renal function. *Pain* 1997; 71:111-2
12. Rothe KF, Brather R: Postoperative Atemdepressionen im Zusammenhang mit Tramadol-infusionsnarkose. *Anaesthesist* 1983; 32:88
13. Hillel AD, Benninger M, Blitzer A, Crumley R, Flint P, Kashima HK, Sanders I, Schaefer S: Evaluation and management of bilateral vocal cord immobility. *Otolaryngol Head Neck Surg* 1999; 121:760-5
14. Montiel GC, Quadrelli SA, Roncoroni AJ, Vidal R: Treatment of respiratory insufficiency secondary to vocal cord bilateral paralysis with continuous positive pressure. *Medicina* 1994; 54:241-4
15. Bennett JA, Abrams JT, Van Riper DF, Horrow JC: Difficult or impossible ventilation after sufentanil-induced anesthesia is caused primarily by vocal cord closure. *ANESTHESIOLOGY* 1997; 87:1070-4
16. Arandia HY, Patil VU: Glottic closure following large doses of fentanyl. *ANESTHESIOLOGY* 1987; 66:574-9
17. Scamman FL: Fentanyl-O<sub>2</sub>-N<sub>2</sub>O rigidity and pulmonary compliance. *Anesth Analg* 1983; 62:332-4
18. Lalley PM: Mu-opioid receptor agonist effects on medullary respiratory neurons in the cat: Evidence for involvement in certain types of ventilatory disturbances. *Am J Physiol Regul Integr Comp Physiol* 2003; 285:R1287-304
19. Vankova ME, Weinger MB, Chen DY, Bronson JB, Motis V, Koob GF: Role of central mu, delta-1, and kappa-1 opioid receptors in opioid-induced muscle rigidity in the rat. *ANESTHESIOLOGY* 1996; 85:574-83
20. Ossowska K, Wolfarth S: Muscle rigidity induced by the opioid analgesic tramadol, but not by the non-opioid flupirtine. *Pol J Pharmacol* 1994; 46:61-5
21. Driessen B, Reimann W, Giertz H: Effect of the central analgesic tramadol on the uptake and release of noradrenaline and dopamine *in vitro*. *Br J Pharmacol* 1993; 108:806-11
22. Raffa BB, Friderichs E, Reimann W, Shank RP, Codd EE, Vaught JL: Opioid and nonopioid components independently contribute to the mechanism of action of tramadol, an "atypical" opioid analgesic. *J Pharmacol Exp Ther* 1992; 260:276-85
23. Hennies HH, Friderichs E, Schneider J: Receptor binding, analgesic and antitussive potency of tramadol and other selected opioids. *Arzneim Forsch* 1988; 38:877-80
24. Kubsova H, Holik J, Bogrova I, Syslova D: Pain in elderly patients and aspects of its therapy. *Cas Lek Cesk* 2001; 140:291-4