

# Effects of Epidural Saline Injection on Cerebrospinal Fluid Volume and Velocity Waveform

## A Magnetic Resonance Imaging Study

Hideyuki Higuchi, M.D.,\* Yushi Adachi, M.D.,† Tomiei Kazama, M.D.‡

**Background:** The phenomenon of epidural “top-up” (increased spread of local anesthetic due to epidural fluid injection) is explained partly by an epidural volume effect. This study was designed to investigate the change in cerebrospinal fluid (CSF) volume and velocity waveform induced by epidural saline injection.

**Methods:** (1) Lumbar epidural catheters were placed in 28 patients. Magnetic resonance images were obtained for measurements of lumbosacral CSF volume and velocity waveform. Saline was injected into the epidural space through the catheter to three groups of randomly assigned patients: 5-ml saline (n = 10), 10-ml saline (n = 9), and 15-ml saline (n = 9) groups. A repeat image series was performed after epidural injection to compare CSF volume and velocity waveform before and after epidural injection. (2) We also examined the time course of dural sac compression after epidural saline injection in a separate series. Seven axial images at disk levels from T11–T12 to L5–S1 were obtained before injection and 1, 3, 5, 10, 15, 20, 25, and 30 min after 10-ml saline injection to compare each dural area before and after injection.

**Results:** (1) Saline injected through the epidural catheter compressed the dural sac with variability of the extent of compression, resulting in a significantly decreased CSF volume in all patients ( $P \leq 0.001$ ). The mean reductions in CSF volume were  $2.0 \pm 1.0$  ml in the 5-ml group,  $4.4 \pm 1.4$  in the 10-ml group, and  $7.2 \pm 2.6$  in the 15-ml group. There were significant differences among the three groups ( $P < 0.05$ – $0.001$ ). After the saline injection, the synchronization between the CSF velocity waveform and the cardiac cycle disappeared in significantly more patients in the 10-ml group (7 of 9 patients) than in the other groups ( $P < 0.05$ ). However, there was no significant relation between measures of CSF velocity waveform and dural area in any patient. (2) The maximum reduction of the sum of the total of seven disk areas occurred 5 min after epidural saline injection; thereafter, dural compression was gradually restored but did not return to the value before injection for 30 min.

**Conclusions:** These findings indicate that the reduction in CSF volume was injection-volume dependent, dural compression lasted at least 30 min after saline injection, and the changes of the CSF flow dynamics did not correlate with the degree of dural sac compression.

COMBINED spinal–epidural anesthesia (CSE) allows for a rapid onset of neuraxial blockade, which can be sub-

sequently modified.<sup>1</sup> Injecting local anesthetic or saline into the epidural space after spinal anesthesia speeds the onset, increases the sensory block level, or both.<sup>2–9</sup> Although the exact mechanism by which an epidural “top-up” reinforces anesthesia in CSE is not fully understood, this mechanism can be explained partly by the effect of the local anesthetic and partly by an epidural volume effect.<sup>1–9</sup> The volume effect occurs when the volume of the fluid injected into the epidural space compresses the dural sac, squeezes the cerebrospinal fluid (CSF) compartment, and displaces the CSF cephalad, thus raising the cephalad spread of spinal drugs.<sup>1</sup> Epidural saline injection compresses the dural sac.<sup>3</sup> The extent of the CSF volume reduction induced by epidural saline, however, is unclear. Lumbosacral CSF volume is a major factor governing the distribution of local anesthetic solutions in the subarachnoid space, because CSF is the diluent for local anesthetic solutions delivered by the subarachnoid route.<sup>10,11</sup> Carpenter *et al.*<sup>10</sup> and we<sup>11</sup> previously demonstrated significant correlations between lumbosacral CSF volume and peak sensory block level of hyperbaric lidocaine or plain bupivacaine using magnetic resonance (MR) imaging. On the other hand, Shibuya *et al.*<sup>12</sup> recently demonstrated a high correlation between CSF velocity amplitude and the severity of myelopathy, and concluded that measurements of CSF flow dynamics could quantify the degree of dural sac and spinal cord compression. Therefore, information about changes in CSF volume waveform and velocity by epidural saline injection should be useful to understand the mechanism of epidural top-up. The purpose of the current study was to investigate the effects of epidural saline injection with three different saline volumes (5, 10, and 15 ml) on CSF volume and velocity waveform using MR imaging.

## Materials and Methods

The current study was conducted at the Self Defense Force Hanshin Hospital in Hyogo, Japan, and was approved by the Hospital Ethics Committee. Forty patients with American Society of Anesthesiology physical status class I (study 1: 27 men, 3 women; study 2: 9 men) who provided written informed consent were enrolled in the study. They underwent orthopedic lower limb or urologic surgery during epidural anesthesia with ropivacaine, or lower abdominal surgery during epidural plus general anesthesia. Apart from the usual contraindica-

\* Chief of Anesthesiology, Department of Anesthesia, Self Defense Force Hanshin Hospital, Kawanishi, Hyogo, Japan. † Research Assistant, Department of Anesthesiology, National Defense Medical College, Tokorozawa, Saitama, Japan. ‡ Professor and Chair, Department of Anesthesiology, National Defense Medical College Tokorozawa, Saitama, Japan.

Received from the Department of Anesthesia, Self Defense Force Hanshin Hospital, Hyogo, Japan. Submitted for publication May 11, 2004. Accepted for publication September 27, 2004. Support was provided solely from institutional and/or departmental sources.

Address reprint requests to Dr. Higuchi: Department of Anesthesiology, Tokyo Women's Medical University, 8-1 Kawadacho, Shinjuku, Tokyo 162-8666, Japan. Address electronic mail to: higu-chi@ka2.so-net.ne.jp. Individual article reprints may be purchased through the Journal Web site, www.anesthesiology.org.

tions for epidural anesthesia, patients with obvious spinal postural abnormalities (kyphosis) or neurologic disturbances were excluded from the study.

A few hours before surgery, an epidural puncture was performed using an 18-gauge Tuohy needle at the L3-L4 level, using the loss-of-resistance technique with saline, taking care not to inject more than 1 ml saline. A medial approach with the patient in the lateral decubitus position was used. Counting the spines of the vertebrae and palpation of the iliac crest was used to identify the L3-L4 level interspace. After confirmation of the epidural space, an epidural catheter (Prefix; B. Braun, Tokyo, Japan), which has lateral side ports 14 mm, 10 mm, and 6 mm from the closed tip, was advanced 3-5 cm into the epidural space. Before insertion, the catheter and bacterial filter were primed with physiologic saline to ensure an air-free column of fluid from the connector to the catheter tip. Patients were then transferred to the MR imaging room.

### Study 1

Low thoracic and lumbosacral axial MR images for the measurement of CSF volume and velocity waveform were obtained using an MR imaging system (Excel Art; Toshiba, Tokyo, Japan) operating at 1.5 T using a method similar to that previously described.<sup>11,13</sup> First, sagittal MR images of the lower thoracic lumbosacral column were obtained. Then, the level of the disk between the 11th and 12th thoracic vertebrae was determined and low thoracic, lumbar, and spinal axial MR images caudal from this site were obtained at 8-mm increments with a fast-spin echo sequence for the CSF volume measurements. Finally, phase-contrast MR imaging at the L3-L4 disk levels was performed for the measurement of CSF velocities (CSFVs). Peak systolic (CSFV<sub>systolic</sub>), peak diastolic, and average CSFV values at the L3-L4 levels were measured from these phase-contrast images, tracing the outlines of the entire CSF, similar to a method reported previously.<sup>13</sup> These measurements required 51 s, 8.5 min, and 6.8 min, respectively. After obtaining these MR images, saline was injected into the epidural space through the epidural catheter at a rate of 0.5 ml/s using a 10-ml syringe. Patients were randomly assigned to one of three groups: 5 ml saline (n = 10), 10 ml saline (n = 10), and 15 ml saline (n = 10). Five minutes after completion of the injection, MR images were obtained in an order similar to that before epidural saline injection: Sagittal, axial, and phase-contrast MR images were acquired over approximately 5-6, 6-14, and 14-21 min after injection. The timing for beginning the MR images was determined based on a preliminary study that indicated that approximately 5 min was required for saline to spread up to the lower thoracic level in sagittal MR images.

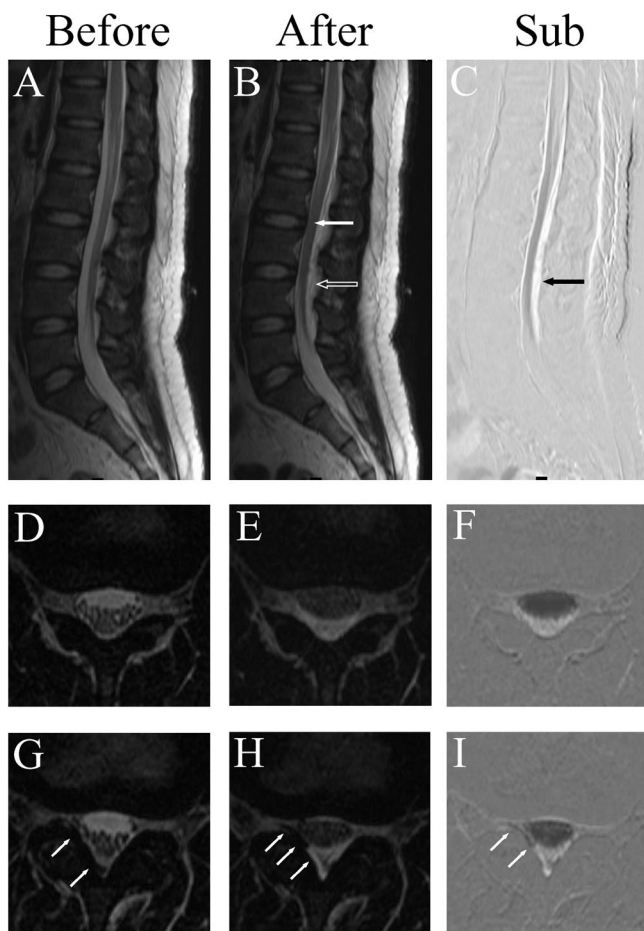
One of the authors (Y. A.) determined the dural sac and spinal cord areas for each axial MR image using the

public domain NIH Image 1.63 program (developed at the Research Services Branch of the National Institutes of Mental Health, Bethesda, MD). During quantification, the images were encoded and randomized to blind the investigator to the source of the image with regard to saline volume and the presence or absence of epidural injection. Because it is sometimes difficult to distinguish epidural saline from CSF in MR images, in which CSF appears as bright as saline, the sagittal and axial MR images after epidural saline injection were subtracted from those before injection (Fig. 1). In these subtracted images, only epidural saline appears as bright (figs. 1C, F, and I, black arrow). The dural sac areas for these subtracted images (axial) were also determined and compared with those after epidural saline injection. Simultaneously, the blinded investigator classified the CSF velocity waveform after saline injection into three types: (1) saw type (a sawlike waveform caused by the disappearance of waveform synchronization with the cardiac cycle), (2) decreased type (waveform synchronization with the cardiac cycle was maintained and CSFV<sub>systolic</sub> was decreased), and (3) increased type (synchronized waveform was maintained and CSFV<sub>systolic</sub> was increased) (fig. 2).

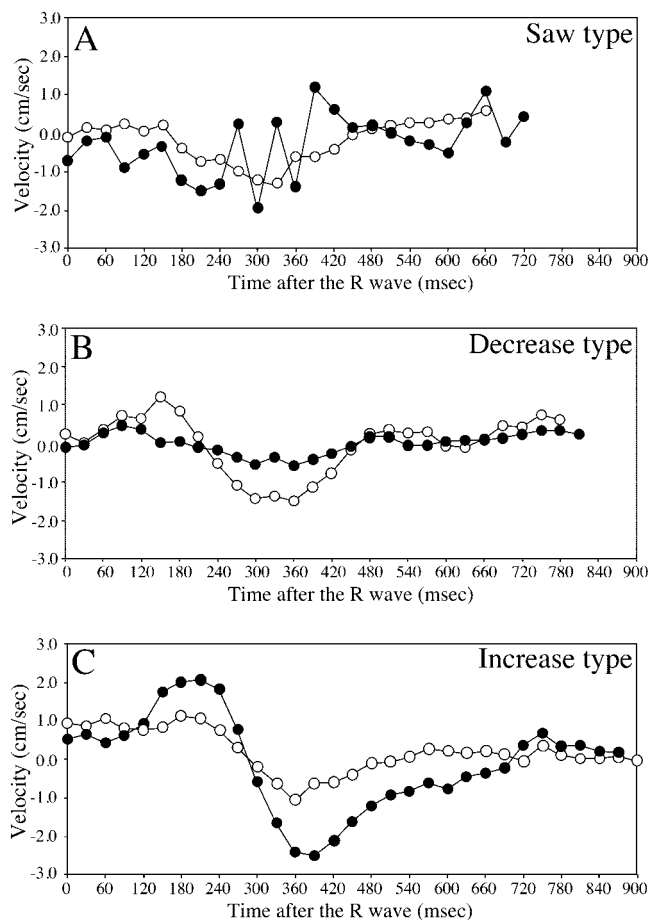
### Study 2

We examined the time course of dural sac compression after epidural saline injection in a separate series because of time required for the measurements of CSF volume. To complete axial MR measurements within 1 min, fewer than 10 slices and changes in the technical specifications, such as a short repetition time, resulting in reduced resolution, were required. Accordingly, we limited the study to seven axial images at disk levels from T11-T12 to L5-S1 with modified specifications (2,900-ms repetition time, 120-ms echo time). This MR measurement was completed in 56 s. Axial MR images were obtained before injection and 1, 3, 5, 10, 15, 20, 25, and 30 min after completion of 10 ml epidural saline injection. Similar to study 1, we determined the dural sac areas for each axial MR image and compared the sum of the seven areas before with after epidural saline injection.

The patient sample size in the current study was determined by power analysis ( $\alpha = 0.05$ ,  $\beta = 0.20$ ) to reveal a significant difference in the reduced CSF volume (study 1). Power analysis indicated that nine patients from each group were required to obtain a significant difference between two groups, assuming that the difference in the reduced CSF volume between the 5-ml and 10-ml groups was 2.0 ml with a 1.5 SD, which was based on a preliminary study. Data were expressed as mean  $\pm$  SD and analyzed using one-way analysis of variance or two-way repeated-measures analysis of variance followed *post hoc* by Scheffé F test or paired *t* test, where appropriate. Chi-square analysis was used to de-



**Fig. 1.** (A–I) Magnetic resonance images before (left; A, D, and G) and after (center; B, E, and H) epidural saline (15 ml) injection in a 40-yr-old man, whose cerebrospinal fluid volume decreased from 40.4 ml to 31.2 ml. Images taken before the epidural saline injection were subtracted from those taken afterward (center-left) are also presented (right; C, F, and I). In these axial images, anterior is toward the top of the figure and anatomic right is to the left in the figure. (A) Sagittal magnetic resonance image of lower thoracic lumbosacral column before epidural saline injection. (B) After injection, saline accumulated posteriorly in the epidural space, compressing the dura (outlined arrow). Conus medullaris and cauda equina dislocated anteriorly (solid arrow). (C) Subtracting the image taken before injection from that after injection, both anterior and posterior epidural saline is represented as a bright signal (black arrow). (D) Axial magnetic resonance image at the L2–L3 disk level. The dural area at this level was 1.88 cm<sup>2</sup>. (E) After injection, saline accumulated posteriorly in the epidural space, significantly compressing the dura, as indicated by the dark appearance of the cerebrospinal fluid. Dural area at this level decreased to 1.12 cm<sup>2</sup>. (F) The observations in E were verified in this subtracted image. (G–I) The epidural catheter can be seen (solid arrows) between the right ligamentum flavum and posterolateral dura. (G) Axial magnetic resonance image at the L3–L4 disk level. Dural area at this level was 1.55 cm<sup>2</sup>. (H) After injection, saline accumulated posteriorly in the epidural space, compressing the dura. Saline passed predominantly to the left of the dura, which was the opposite side of the catheter, and accumulated anterior to the dura. The dural area at this level decreased to 0.91 cm<sup>2</sup>. (I) The observations in H were verified in this subtracted image.



**Fig. 2.** Three types of the cerebrospinal fluid velocity (CSFV) waveforms before (open circles) and after epidural saline injection (closed circles). (A: saw type) CSFV profiles in a 45-yr-old man whose cerebrospinal fluid volume decreased from 43.3 ml to 39.3 ml after injection of 10 ml saline. Although there was a smooth waveform, which synchronized with the cardiac cycle, in the CSFV profile before saline injection, the waveform became sawlike after epidural saline injection. (B: decrease type) CSFV profiles in a 31-yr-old man whose cerebrospinal fluid volume decreased from 35.7 ml to 23.1 ml after injection of 15 ml saline. After epidural saline injection, the synchronized waveform was maintained and peak systolic (CSFV<sub>systolic</sub>) was decreased. (C: increase type) CSFV profiles in a 19-yr-old man whose cerebrospinal fluid volume decreased from 28.6 ml to 26.0 ml after injection of 5 ml saline. After epidural saline injection, the synchronized waveform was maintained and CSFV<sub>systolic</sub> was increased.

termine differences in the incidence of the dark appearance of CSF and the types of CSF velocity profiles.

**Results**

*Study 1*

Magnetic resonance images of one woman were obtained 1 day after surgery because the MR imaging room was not available on the day of surgery. Two female patients were excluded from the analysis because their epidural catheters were not in the epidural space. After injecting 15 ml saline, the saline was observed in the

Downloaded from http://esa2.silverchair.com/anesthesiology/article-pdf/102/2/285/357935/000542-20050200-00008.pdf by guest on 01 October 2022

**Table 1. Patient Characteristics**

	5 ml	10 ml	15 ml
Male/Female	10/0	8/1	9/0
Age, yr	32 ± 12	31 ± 6	31 ± 8
Height, cm	170 ± 6	171 ± 6	171 ± 6
Weight, kg	68 ± 8	68 ± 7	68 ± 7

Data are presented as mean ± SD where appropriate.

paraspinal muscle and subcutaneous tissue in one woman (age, 23 yr) whose MR images were obtained after anesthesia. Her epidural catheter might have withdrawn from the epidural space during the night because her knee surgery was performed during epidural anesthesia induced by local anesthetics injected through the catheter. In another woman (age, 42 yr) in the 10-ml group, saline was observed only in the left psoas muscle, not in the epidural space. After confirmation of this finding, her epidural catheter was withdrawn 2 cm before surgery. Good epidural anesthesia by local anesthetics injected through the catheter was then obtained, and her knee surgery was performed during epidural anesthesia. There was resistance to the injection in one male patient (age, 26 yr) of the 15-ml group. His MR images revealed that part of the saline was seen in the paraspinal muscle, although almost all of the saline encircled the dura. He was included in the analysis. Patient characteristics of the 28 patients included in the study are presented in table 1. The CSF volume and velocity before and after saline injection are presented in table 2. There was no significant difference among the three groups regarding demographics and characteristics of variables measured by MR imaging before saline injection.

The findings of MR images before and after saline injection are summarized in table 3. The catheter was identified in 26 of 28 patients (table 3 and figs. 1G-I, solid arrows). The exact position of the catheter tip, however, was unclear because of the limited resolution in this MR imaging study. Saline injected into the epidural space usually spreads freely through the epidural space and coats the cylindrical dural sac while partly passing out the foramina. However, there was no single pattern of saline spread, but rather marked differences

**Table 3. Findings of Magnetic Resonance Imaging before and after Saline Injection**

	5 ml (n = 10)	10 ml (n = 9)	15 ml (n = 9)
Before injection			
Air*	9	5	6
Catheter*	9	9	7
After injection			
Air*	9	9	8
Velocity†‡			
Saw type	2	7	3
Decrease type	0	0	3
Increase type	8	2	3

\* Data are presented as number of patients in whom air or catheter was identified by magnetic resonance imaging. † Data are presented as number of patients who belonged to one of the three types. See text for details. ‡ There was a significant difference among the three groups in the number of patients.

among patients regarding the sites of accumulation and the amount exiting through the intervertebral foramina. Similarly, saline injected through the epidural catheter compressed the dural sac with a variable pattern. The dural sac was dislocated anteriorly with accumulation of saline in the posterior areas, which resulted in great compression and was a common finding (fig. 1). On the other hand, the dural sac was occasionally dislocated posteriorly or laterally with preferential accumulation of saline in the anterior or posterolateral areas, resulting in less compression. In a longitudinal distribution, the maximum reduction occurred near the L2-L3 disk level and gradually decreased toward the cephalad and caudal directions (fig. 3). As the volume of saline injected increased, the magnitude of the area reduction and the number of slices with a reduced area increased. Individual CSF volume was compared before and after saline injection, and decreased in all subjects after saline injection with great variability in the extent (fig. 4). As a result, the mean CSF volume in each group after saline injection decreased significantly from that before injection (table 2 and fig. 4;  $P = 0.001$ , 5-ml group;  $P < 0.001$ , 10-ml and 15-ml groups). The mean reduction in CSF volume of the 5-ml group was  $2.0 \pm 1.0$  ml, whereas the corresponding values in the 10-ml and 15-ml groups were  $4.4 \pm 1.4$  and  $7.2 \pm 2.6$  ml, respectively (fig. 5).

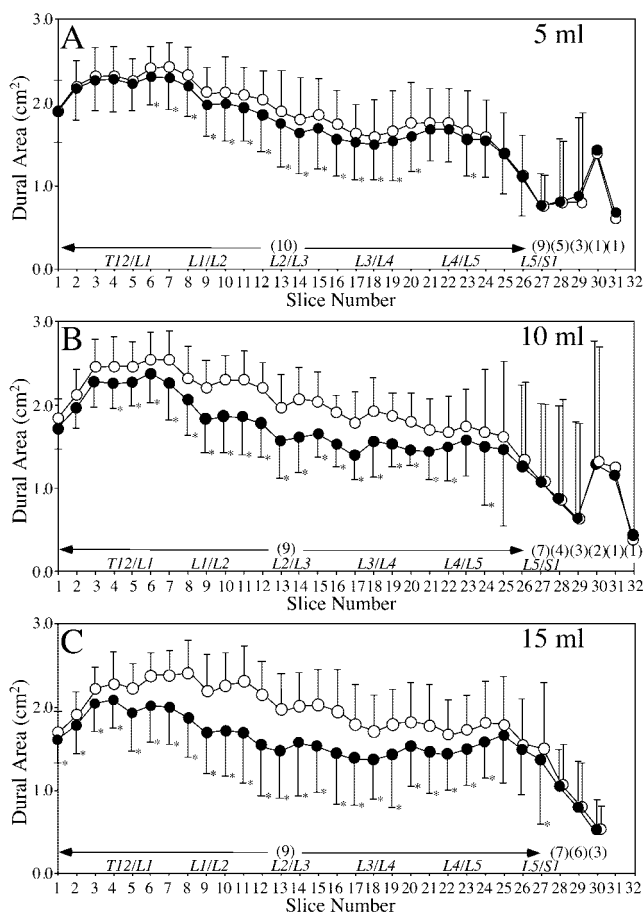
**Table 2. Measures of Magnetic Resonance Images before and after Saline Injection**

	5 ml (n = 10)		10 ml (n = 9)		15 ml (n = 9)	
	Before	After	Before	After	Before	After
CSF volume, ml	39.0 ± 7.4	37.0 ± 7.8*	41.7 ± 8.7	37.4 ± 8.2*	41.1 ± 8.0	33.9 ± 8.6*
CSF velocity, cm/st						
Peak systolic	-0.8 ± 0.3	-1.3 ± 0.5*	-1.0 ± 0.5	-1.2 ± 0.8	-1.1 ± 0.4	-1.1 ± 0.5
Peak diastolic	0.8 ± 0.3	0.8 ± 0.5	0.6 ± 0.3	0.7 ± 0.4	0.6 ± 0.2	0.6 ± 0.2
Average	0.0 ± 0.2	-0.1 ± 0.1	-0.1 ± 0.1	-0.1 ± 0.2	-0.1 ± 0.1	-0.1 ± 0.1

Data are presented as mean ± SD.

\*  $P < 0.01$  compared with corresponding value before saline injection. † The negative values represent caudal flow, whereas the positive represent cephalad flow.

CSF = cerebrospinal fluid.

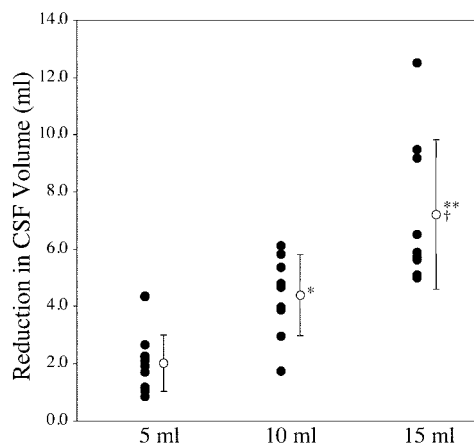
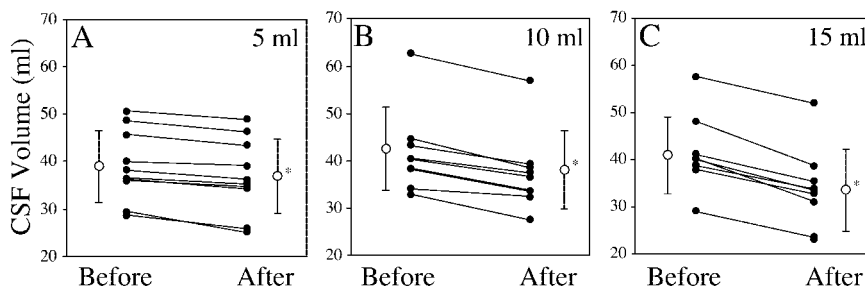


**Fig. 3.** Changes in the dural area below the T11–T12 disk before (open circles) and after (closed circles) epidural saline injection in the three groups (A: 5 ml, n = 10; B: 10 ml, n = 9; C: 15 ml, n = 9). The number of slices (3-mm thickness at 5-mm intervals) is indicated in the x-axis. Although slices in different subjects would not necessarily fall at the same level, approximate disk levels are presented in italic letters for reference points. The numbers of patients are shown in parentheses. \*  $P < 0.05$  compared with each value before saline injection at that level. Data are presented as mean  $\pm$  SD.

There were significant differences in the reduction of CSF volume between the 5-ml and 10-ml groups ( $P < 0.05$ ), between the 5-ml and 15-ml groups ( $P < 0.001$ ), and between the 10-ml and 15-ml groups ( $P < 0.01$ ).

There was a significant difference among the three groups in the pattern of the CSF velocity waveform ( $P < 0.01$ ; table 3). In 8 of 10 patients in the 5-ml group, the waveform was maintained and CSFV<sub>systemic</sub> increased (ta-

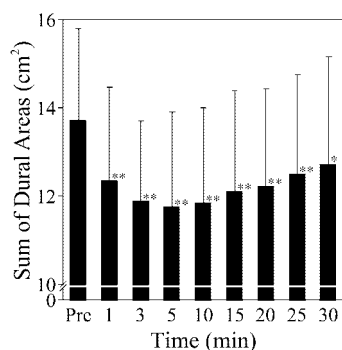
**Fig. 4.** Changes in cerebrospinal fluid (CSF) volume before and after epidural saline injection in the three groups (A: 5 ml, n = 10; B: 10 ml, n = 9; C: 15 ml, n = 9). Individual (closed circles) and mean  $\pm$  SD values (open circles) of each group are shown. Cerebrospinal fluid volumes of all subjects decreased with variability in the three groups. \*  $P \leq 0.001$  compared with each value before saline injection.



**Fig. 5.** The reductions in cerebrospinal fluid (CSF) volume produced by saline injection. Individual (closed circles) and mean  $\pm$  SD values (open circles) of each group are shown. There were significant differences in the reduction of CSF volume among the three groups (\*  $P < 0.05$ , 5 ml vs. 10 ml; †  $P < 0.01$ , 10 ml vs. 15 ml; \*\*  $P < 0.001$ , 5 ml vs. 15 ml).

ble 3 and fig. 2). The overall mean CSFV<sub>systemic</sub> after saline injection significantly increased in the 5-ml group ( $P < 0.01$ ; table 2). Synchronization of the CSF velocity waveform with the cardiac cycle disappeared in 7 of 9 patients in the 10-ml group after saline injection, a significantly greater proportion than in the other groups ( $P < 0.05$ ). In contrast, the waveform was maintained and CSFV<sub>systemic</sub> was decreased in 3 patients, and synchronization of the CSF velocity waveform with the cardiac cycle disappeared in 3 patients in the 15-ml group. There was no significant relation in any patient between measures of velocity and those of CSF volume or the dural area, such as between the change in CSFV<sub>systemic</sub> and the reduction in CSF volume after saline injection.

Of 789 subtracted images, it was possible to determine the dural area in 659 images. In the remaining 130 images, there was no saline observed in the epidural space, such as the sacral segments, or there were discrepancies in the dural sac position in MR images between before and after saline injection. The correlation coefficient of the dural area between axial MR images after saline injection and the corresponding subtracted images was 0.991. The relative error, defined as (axial – subtracted images)/subtracted images, was  $3.82 \pm 3.84\%$ .



**Fig. 6.** Changes over time in the sum of the dural areas of disk levels from T11–T12 to L5–S1 before injection and 1, 3, 5, 10, 15, 20, 25, and 30 min after completion of 10-ml epidural saline injection ( $n = 9$ ). There were significant differences in the sum of seven disk areas between before and 1, 3, 5, 10, 15, 20, 25, and 30 min after injection. \*  $P < 0.05$ , \*\*  $P < 0.01$  compared with each value before saline injection at that level. Data are presented as mean  $\pm$  SD.

### Study 2

No patients were excluded from the analysis in the study 2. Patient age, height, and weight were  $32 \pm 10$  yr,  $172 \pm 5$  cm, and  $71 \pm 9$  kg, respectively. Figure 6 shows the changes over time in the sum of seven dural areas of disk levels from T11–T12 to L5–S1. Dural compression was observed immediately after epidural saline injection and persisted for at least 30 min. In general, the maximum dural compression at the L1–L2 and L2–L3 disk levels was observed earlier than at the other disk levels. The maximum reduction of the sum of seven disk areas from T11–T12 to L5–S1 occurred 5 min after injection.

### Discussion

The principal findings of the current study were the variability of saline distribution and dural sac compression, and more uniform spread and greater compression of the dural sac with increased saline volume, resulting in an injection-volume-dependent mean reduction in CSF volume in the three groups. Although dural sac compression or a reduction in the diameter of the dural sac by epidurally injected solution was previously reported,<sup>3,14,15</sup> these studies did not examine the change in CSF volume by epidural injection. We measured the reduction in CSF volume after epidural saline injection using an MR imaging technique to investigate whether the reduction in CSF volume is relevant to the reinforcement of spinal anesthesia in CSE, because the lumbosacral CSF volume is the major determinant of the sensory block spread of spinal anesthesia.<sup>10,11</sup> In addition, the results of the current study demonstrate that dural compression was not restored in a short time but persisted for at least 30 min after epidural saline injection. The persistent dural compression is consistent with the findings of a previous study<sup>15</sup> and contrasts with the quick

return to baseline values of epidural and CSF pressure in parallel only a few minutes after epidural injection.<sup>16–18</sup>

There are several limitations to the methods using MR imaging in the current study. First, the MR images had limited resolution. In contrast to the previous studies using computed tomography, contrast medium, or both,<sup>13,19,20</sup> the catheter tip position could not be located in the current study. In addition, because the boundaries of the adjacent structures are not clear, there are many sources of error in MR imaging. Especially when CSF does not appear dark after saline injection, a large error is introduced because it is difficult to distinguish saline from CSF, both of which appear bright. Although the investigator carefully distinguished saline from CSF for each image, there are potential inaccuracies in the determination of the area after epidural saline injection in the current study. Second, basic anatomy changes before and after the epidural injection influence the subtraction method used in the current study. For example, in the standard subtraction technique used to enhance an angiogram, the basic anatomy does not change and only the blood/contrast medium signal changes. An epidural saline injection, however, distorts the thecal sac and changes the signal intensity. We do not know the validity of this subtraction method. However, we did not want to use contrast medium, because the effect of the viscosity on the contrast medium distribution and dural sac compression is not clear. We also wanted to examine the effect of epidural saline injection on CSF volume, using conditions identical to the clinical situation. Finally, CSF volume and velocity waveform observed in the current study are time-averaged values, because it takes times to obtain axial MR and phase-contrast images for the measurements of CSF volume and velocity waveform. Axial MR images were obtained very close to when the maximum reduction of the dural sac area was observed, and dural compression was gradually restored until all the axial MR images were obtained (fig. 6). On the other hand, velocity measurements were performed during the restoration of dural compression. Therefore, the results of the current study should be interpreted carefully because the values were not measured at the peak change of dural compression. Comparison of the sum of the dural areas 15 min after injection with that 5 min after injection indicated that the CSF volume measured after injection in the current study might be approximately 3% lower than the maximum reduced CSF ( $12.10$  vs.  $11.75$  cm<sup>2</sup>). Improved resolution and time with new MR imaging technology will increase the accuracy and precision of determination of the area after saline injection.

Patterns of distribution exhibited great variability. A large-saline volume injection, however, improved the uniformity of distribution. These findings are in agreement with those of Hogan,<sup>14</sup> who examined the spread of contrast material in the epidural space using com-

puted tomographic imaging. Accompanying the findings of distribution, the patterns and magnitude of dural sac compression exhibited great variability. Although it was difficult to identify the exact position of the catheter tips in the current study, the variations in distribution and compression might be related to catheter tip position. Hogan<sup>14</sup> examined catheter tip position; catheter tips were rarely in the posterior midline, and approximately half of the catheters were in the intervertebral foramina.

Hogan *et al.*<sup>21</sup> reported that the CSF volume of obese subjects (42.9 ml) is significantly less than that of non-obese subjects (53.5 ml). They also reported that abdominal compression decreased CSF volume by 3.6 ml. Lee *et al.*<sup>22</sup> found that hyperventilation, abdominal compression, and hyperventilation with abdominal compression caused enlargement of the epidural venous plexus, decreasing CSF volume by 3.7, 10.1, and 14.9 ml, respectively. The extent of the CSF volume reduction in these two studies was comparable to that in the current study, although there were differences in the patterns of dural sac compression between the previous studies and the current study.

Although there are many studies of the effect of epidural saline injection on reinforcement of spinal anesthesia in CSE, there is great variability in the results regarding the extent of epidural saline injection-induced spinal anesthesia because of methodologic differences among the studies, such as the use of local anesthetics for spinal anesthesia and the timing of the saline injection.<sup>2-9</sup> Generalizing the results of these studies, the ability to increase dermatomal spread by increasing epidural volume seems to be time dependent.<sup>1-9</sup> Beyond 20 min or after two-segment regression has begun, epidural top-up with saline does not affect sensory block extension.<sup>6,7</sup> With regard to the increased sensory block level in CSE anesthesia, what are the implications of the saline injection-induced reduction in CSF volume in the current study? Previous studies indicated that there is a significant correlation between the lumbosacral CSF volume and sensory block spread of spinal anesthesia.<sup>10,11</sup> Calculation of the slopes of linear regression in the correlation between CSF volume and peak sensory block level revealed that an approximately 5-ml difference in CSF volume results in a one-segment difference after spinal anesthesia.<sup>10,11</sup> Using this calculation with the results in the current study suggests that the reduction in CSF volume in 4 patients in the 10-ml group does not explain the one-segment increase in sensory block level, because their CSF volume reduction was less than 5 ml, even after a 3% increase was used to compensate for the potential underestimation, although the precise CSF volume required to produce a one-segment difference after spinal anesthesia and the maximum CSF volume reduction are unclear. Such variations in the CSF volume reduction in the patients of the 10-ml group might partly explain the results of previous studies.<sup>4,5,7,8</sup> In the stud-

ies by Stienstra *et al.*,<sup>4,5</sup> there were 2 or 3 of 10 patients in whom the epidural catheter functioned properly based on clinical assessment after surgery who did not respond to epidural top-up of 10 ml saline during a plateau of plain bupivacaine spinal anesthesia. In addition, the lack of a significant difference in the peak sensory block level between patients who received 10 ml saline epidurally and the control patients, who received nothing in some studies,<sup>4,8</sup> and the failure to increase the block level of spinal anesthesia even when it was assumed that saline was injected before cephalad extension of spinal anesthesia reached its peak<sup>7,8</sup> might be explained in part by an insufficient CSF volume reduction in 4 of 9 patients. On the other hand, the overall mean reduction in CSF volume in the 5-ml group was half of that in the 10-ml group, and the CSF volume reduction of all patients in the 5-ml group was less than 5 ml. Stienstra *et al.*,<sup>5</sup> however, reported that 5 ml saline produced an approximately two-segment increase in CSE, similar to 10 ml saline. It is difficult to explain this injection-volume-independent increase of the peak sensory block level by CSF volume reduction. One possible explanation is that epidural saline was injected within 20 min after plain bupivacaine spinal anesthesia, which was administered in the sitting position.<sup>5</sup> We previously reported that a greater hypobaricity of plain bupivacaine is associated with a higher peak sensory block, extending past 20 min.<sup>11</sup> Accordingly, the increased epidural pressure due to epidural saline injection might effectively raise the "unfixed" hypobaric local anesthetic within the CSF cephalad, despite the insufficient CSF volume reduction.

In the current study, the CSF pulsatile waveform was maintained and CSFV<sub>systolic</sub> was increased in 8 of 10 patients in the 5-ml group, whereas the CSF pulsatile waveform disappeared in 7 of 9 patients in the 10-ml group. This finding is partly consistent with that in the study by Shibuya *et al.*,<sup>12</sup> who investigated the relation between the severity of myelopathy and the degree of CSF flow disturbance. They reported that in patients whose dural sac and spinal cord were mildly compressed, the CSF waveform synchronized with the cardiac cycle, whereas the CSF pulsatile waveform disappeared in patients whose dural sac and cord were severely compressed. Interestingly, however, the CSF waveform of 6 patients in the 15-ml group was synchronized with the cardiac cycle, and the CSFV<sub>systolic</sub> in half of these patients was decreased. Further, there was no relation between the magnitude of dural sac compression and the CSFV measures. Accordingly, the current study indicated that measurements of CSF flow dynamics could not necessarily quantify the degree of dural sac compression, contrary to the conclusion by Shibuya *et al.*<sup>12</sup> The CSF flow dynamics at the L3-L4 disk level, however, were measured during the restoration of dural sac compression in healthy patients in the current study,

whereas Shibuya *et al.* measured them at the cervical region in patients with cervical spine pathology. On the other hand, we previously demonstrated that CSF velocity might influence the duration of motor block in plain bupivacaine spinal anesthesia.<sup>11</sup> Ten milliliters epidural saline might decrease the duration of spinal anesthesia in CSE.<sup>6,8</sup> Therefore, the change in CSF flow dynamics is a possible factor in the distribution and clearance of spinal agents in CSE.

Other potential study limitations include the following. The study was performed in a limited situation, such as the use of a multiorifice epidural catheter. Different catheter designs and injection speeds or pressures might produce different patterns of solution distribution and dural compression.<sup>23</sup> In addition, only one woman was included in the analysis of the current study. Although it is unclear whether sex differences affect dural compression, Leeda *et al.*<sup>24</sup> reported that women have a smaller increase in peak sensory block level than men after an epidural loading dose following an epidural top-up with ropivacaine. Similarly, the current study did not include patients with increased abdominal pressure, which occurs with obesity or pregnancy, although CSE is frequently used in obstetric surgery. The dural sac in these patients is compressed by inward movement of soft tissue in the intervertebral foramen<sup>16</sup> or enlargement of epidural venous plexus.<sup>25</sup> Therefore, it is possible that there would be different results in different populations, such as pregnant women.

In summary, the reduction in CSF volume was volume-dependent in the three groups; 5, 10, and 15 ml epidural saline decreased CSF volume by 2.0, 4.4, and 7.2 ml, respectively. Dural compression persisted for at least 30 min after epidural saline injection. In addition, 10 ml epidural saline disturbed the synchronization of the waveform with the cardiac cycle. The disturbance in CSF flow, however, did not correlate with the extent of the dural sac compression.

The authors thank the surgeons and nurses in the operating room and orthopedic wards and the workers in the Department of Radiology of the Self Defense Force Hanshin Hospital (Kawanishi, Hyogo, Japan) for their cooperation.

## References

- Liu SS, McDonald SB: Current issues in spinal anesthesia. *ANESTHESIOLOGY* 2001; 94:888-906
- Blumgart CH, Ryall D, Dennison B, Thompson-Hill LM: Mechanism of extension of spinal anaesthesia by extradural injection of local anaesthetic. *Br J Anaesth* 1992; 69:457-60
- Takiguchi T, Okano T, Egawa H, Okubo Y, Saito K, Kitajima T: The effect of epidural saline injection on analgesic level during combined spinal and epidural anesthesia assessed clinically and myelographically. *Anesth Analg* 1997; 85:1097-100
- Stienstra R, Dahan A, Alhadi BZ, van Kleef JW, Burm AG: Mechanism of action of an epidural top-up in combined spinal epidural anesthesia. *Anesth Analg* 1996; 83:382-6
- Stienstra R, Dilrosun-Alhadi BZ, Dahan A, van Kleef JW, Veering BT, Burm AG: The epidural "top-up" in combined spinal-epidural anesthesia: The effect of volume versus dose. *Anesth Analg* 1999; 88:810-4
- Trautman WJ III, Liu SS, Kopacz DJ: Comparison of lidocaine and saline for epidural top-up during combined spinal-epidural anesthesia in volunteers. *Anesth Analg* 1997; 84:574-7
- Mardirossoff C, Dumont L, Lemedioni P, Pauwels P, Massaut J: Sensory block extension during combined spinal and epidural. *Reg Anesth Pain Med* 1998; 23:92-5
- Choi DH, Park NK, Cho HS, Hahn TS, Chung IS: Effects of epidural injection on spinal block during combined spinal and epidural anesthesia for cesarean delivery. *Reg Anesth Pain Med* 2000; 25:591-5
- Lew E, Yeo SW, Thomas E: Combined spinal-epidural anesthesia using epidural volume extension leads to faster motor recovery after elective cesarean delivery: A prospective, randomized, double-blind study. *Anesth Analg* 2004; 98:810-4
- Carpenter RL, Hogan QH, Liu SS, Crane B, Moore J: Lumbosacral cerebrospinal fluid volume is the primary determinant of sensory block extent and duration during spinal anesthesia. *ANESTHESIOLOGY* 1998; 89:24-9
- Higuchi H, Hirata J, Adachi Y, Kazama T: Influence of lumbosacral cerebrospinal fluid density, velocity, and volume on extent and duration of plain bupivacaine spinal anesthesia. *ANESTHESIOLOGY* 2004; 100:106-14
- Shibuya R, Yonenobu K, Koizumi T, Kato Y, Mitta M, Yoshikawa H: Pulsatile cerebrospinal fluid flow measurement using phase-contrast magnetic resonance imaging in patients with cervical myelopathy. *Spine* 2002; 27:1087-93
- Higuchi H, Adachi Y, Kazama T: Factors affecting the spread and duration of epidural anesthesia with ropivacaine. *ANESTHESIOLOGY* 2004; 101:451-60
- Hogan Q: Epidural catheter tip position and distribution of injectate evaluated by computed tomography. *ANESTHESIOLOGY* 1999; 90:964-70
- Fukushige T, Kano T, Sano T, Irie M: Computed tomographic epidurography: an aid to understanding deformation of the lumbar dural sac by epidural injections. *Eur J Anaesthesiol* 1999; 16:628-33
- Usubiaga JE, Usubiaga LE, Brea LM, Goyena R: Effect of saline injections on epidural and subarachnoid space pressures and relation to postspinal anesthesia headache. *Anesth Analg* 1967; 46:293-6
- Ramsay M, Roberts C: Epidural injection does cause an increase in CSF pressure (letter). *Anesth Analg* 1991; 73:668
- Nystrom EU, Blomberg SG, Buffington CW: Transmural pressure of epidural veins in the thoracic and lumbar spine of pigs. *ANESTHESIOLOGY* 1998; 89:449-55
- Hsin ST, Yeow KM, Tsou CH, Liu HP, Luk HN, Ren HZ: The use of three-dimensional computed tomography to visualize thoracic epidural catheters. *ANESTHESIOLOGY* 2003; 98:1031-2
- Yokoyama M, Hanazaki M, Fujii H, Mizobuchi S, Nakatsuka H, Takahashi T, Matsumi M, Takeuchi M, Morita K: Correlation between the distribution of contrast medium and the extent of blockade during epidural anesthesia. *ANESTHESIOLOGY* 2004; 100:1504-10
- Hogan QH, Prost R, Kulier A, Taylor ML, Liu S, Mark L: Magnetic resonance imaging of cerebrospinal fluid volume and the influence of body habitus and abdominal pressure. *ANESTHESIOLOGY* 1996; 84:1341-9
- Lee RR, Abraham RA, Quinn CB: Dynamic physiologic changes in lumbar CSF volume quantitatively measured by three-dimensional fast spin-echo MRI. *Spine* 2001; 26:1172-8
- Magides AD, Sprigg A, Richmond MN: Lumbar epidurography with multi-orifice and single orifice epidural catheters. *Anaesthesia* 1996; 51:757-63
- Leeda M, Stienstra R, Arbous MS, Verschure MJ, Dahan A, Veering BT, Van Kleef JW, Burm AG: The epidural "top-up": Predictors of increase of sensory blockade. *ANESTHESIOLOGY* 2002; 96:1310-4
- Hirabayashi Y, Shimizu R, Fukuda H, Saitoh K, Igarashi T: Soft tissue anatomy within the vertebral canal in pregnant women. *Br J Anaesth* 1996; 77:153-6