

Continuous Infusion of Ropivacaine for Pain Relief after Iliac Crest Bone Grafting for Shoulder Surgery

Stephan Blumenthal, M.D.,* Alexander Dullenkopf, M.D.,† Katharina Rentsch, M.D.,‡ Alain Borgeat, M.D.§

Background: The aim of the study was to compare the efficacy of either ropivacaine or placebo through an iliac crest (IC) catheter after Bankart repair with IC bone grafting.

Methods: With approval of the local ethics committee and after written informed consent was obtained, 36 patients had an interscalene catheter placed preoperatively. Intraoperatively, the surgeon placed a catheter at the IC donor site. At the end of surgery, 30 ml ropivacaine, 0.5% (ropivacaine group), or 30 ml NaCl, 0.9% (placebo group), was administered. Ropivacaine, 0.2%, was started 6 h after the initial block through the interscalene catheter for 48 h (t_{48}) in all patients. At t_0 , the patient received either 5 ml/h ropivacaine, 0.2% (ropivacaine group), or 5 ml/h NaCl, 0.9% (placebo group), for 48 h through the IC catheter. All patients received an intravenous morphine patient-controlled analgesia device. Pain scores at the shoulder and at the IC donor site were assessed at rest and during motion every 8 h for 48 h and after 3 months. Plasma concentrations of total and unbound ropivacaine, morphine consumption, and patient satisfaction were assessed.

Results: At the IC donor site, pain was significantly lower in the ropivacaine group compared with the placebo group at rest and during motion at any time. Total and unbound plasma concentrations of ropivacaine were below the toxic threshold in both groups. Morphine consumption was significantly lower in the ropivacaine group after 24 and 48 h. Patient satisfaction was significantly higher in the ropivacaine group. At 3 months, pain at the IC during motion was significantly lower in the ropivacaine group.

Conclusions: Continuous application of 0.2% ropivacaine through an IC catheter after Bankart repair with IC bone grafting is an effective method for pain relief for the first 48 h, with few adverse effects and high patient satisfaction. The benefit of this technique is still present after 3 months.

SHOULDER surgery and iliac bone graft harvest are both procedures that are associated with considerable postoperative pain and discomfort.¹⁻³ Bankart repair for instability of the shoulder frequently requires autogenous bone graft from the ilium, resulting in two painful sites for the patient. The continuous application of local anesthetic through an interscalene catheter is an established technique for the control of postoperative pain after shoulder surgery.^{4,5} The pain at the donor site usually resolves within the first postoperative weeks, but it may persist and represent a significant source of postoperative morbidity.^{1,6} Studies have reported incidences

of relevant pain of 29, 38, and 19% at 3 months, 6 months, and 2 yr after bone graft harvesting from the iliac crest (IC), respectively.^{2,3} Local administration of morphine⁷ or wound infiltration with bupivacaine⁸ has been performed to control the pain at the donor site.

The aim of this study was to evaluate the analgesic efficacy of continuous application of ropivacaine through an IC catheter for 48 h administered to the site of bone graft harvesting in patients undergoing Bankart repair for shoulder instability. In addition, the incidence of donor site pain was evaluated 3 months after surgery.

Materials and Methods

After obtaining institutional ethics committee approval (University Clinic Balgrist, Zurich, Switzerland) and written informed consent, 36 adult patients scheduled to undergo elective Bankart repair for shoulder instability using autogenous bone grafts were enrolled in this prospective, randomized, double-blind study. Patients (American Society of Anesthesiologists physical status I or II; age, 18-75 yr; weight, 50-100 kg; height, 155-195 cm) were eligible for participation if they could operate a patient-controlled analgesia device, had no contraindications for interscalene brachial plexus block, had no known allergy to amino amid local anesthetics or morphine, did not receive application of ropivacaine fewer than 7 days before surgery, did not have intake of opioid or nonsteroidal antiinflammatory drugs, and were not pregnant. Failure of successful placement of the interscalene catheter was considered an exclusion criterion during the study.

Patients were given a number between 1 and 36 by choosing a sealed envelope containing a number. Each patient's number was passed on to a pharmacist, who prepared the anesthetic set (bolus and maintenance package) of either ropivacaine or placebo, according to a randomization list. On the day of surgery, all patients were premedicated with 0.1 mg/kg midazolam given orally 1 h before arrival in the induction room. The interscalene brachial plexus was identified using a nerve stimulator (Stimuplex[®] HNS 11; B. Braun Melsungen AG, Melsungen, Germany) connected to the proximal end of the metal inner needle (Stimuplex[®] A, 21-gauge stimulation needle; B. Braun Melsungen AG). Placement of the needle was considered successful when a contraction of the triceps muscle was obtained with a current output of less than 0.5 mA and an impulse duration of 0.1 ms. For the placement of the perineural catheter, the cannula-over-needle technique was used with a plastic cannula

* Consultant, † Resident, § Professor and Chief-of-Staff, Department of Anesthesiology, Orthopedic University Clinic Balgrist. ‡ Assistant Professor, Department of Clinical Chemistry, University Hospital Zurich, Zurich, Switzerland.

Received from the Department of Anesthesiology and Intensive Care, Orthopedic University Clinic Balgrist, Zurich, Switzerland. Submitted for publication June 14, 2004. Accepted for publication September 6, 2004. Support was provided solely from institutional and/or departmental sources. Drs. Blumenthal and Dullenkopf contributed equally to this work.

Address reprint requests to Prof. Borgeat: Orthopedic University Clinic Balgrist/Zurich, Forchstrasse 340, CH-8008 Zurich, Switzerland. Address electronic mail to: aborgeat@balgrist.unizh.ch. Individual article reprints may be purchased through the Journal Web site, www.anesthesiology.org.

(Polymedic[®], polyplex N50-T, 20-gauge external diameter; Te me na, Bondy, France). The catheter (Polymedic[®], polyplex N50, 23-gauge with stylet; Te me na) was introduced distally and advanced between the anterior and middle scalene muscle up to 2–3 cm past the tip of the stimulating needle. The catheter was subcutaneously tunneled over 4–5 cm through an 18-gauge intravenous cannula and fixed to the skin with adhesive tape. Interscalene block was performed in all patients with 30 ml ropivacaine, 0.5% (200 mg), given through the catheter. An interscalene block was considered successful when a sensory block (inability to recognize cold temperature; pins-and-needles-type of paresthesia at the tip of the first and third finger) and a motor block (inability to extend or flex the arm involving the radial and musculocutaneous nerve) were present within 20 min after the administration of the local anesthetic. When the interscalene block was complete, general anesthesia was induced and maintained with propofol using the target-controlled infusion technique (target-controlled infusion pump, Graseby; SIMS Graseby Limited Watford, Herts, United Kingdom). Tracheal intubation was facilitated with use of 0.8 mg/kg rocuronium and 0.1 mg fentanyl.

The autogenous bone was harvested through a lateral oblique incision just cephalad to the anterior IC using a classic surgical technique. After obtaining adequate exposure, an osteotome was used to cut through the crest in a sagittal direction exposing the bone marrow cavity. Before closing the wounds, a self-resorbing foam pad dressing (Spongostan[®]; Johnson and Johnson Ltd., Skipton, United Kingdom) measuring 3.5 × 2.5 cm was placed in direct contact with the bone. Using an 18-gauge Tuohy needle (Perifix[®]; B. Braun Melsungen AG), the skin was tunneled laterally to the surgical incision so that a 20-gauge catheter could be placed in direct contact with the dressing. After the surgical procedure was completed, the catheter was then secured to the skin with use of sutures and adhesive dressing. At the end of surgery, patients received through the iliac bone catheter a bolus of either 30 ml ropivacaine, 0.5%, or 30 ml saline (placebo).

After extubation, patients were transferred to the postoperative care unit. In all patients, continuous interscalene analgesia was started 6 h after the initial block with 0.2% ropivacaine, at a rate of 10 ml/h. A continuous infusion of either 0.2% ropivacaine or saline at a rate of 5 ml/h was administered through the IC catheter, corresponding to t_0 of the study. All patients were connected to a patient-controlled analgesia pump (Abbott Provider; Abbott Laboratories, North Chicago, IL) containing 1 mg/ml morphine. The settings were a dose of 2 mg, a lockout interval of 15 without baseline infusion, or 4-h limit. All patients received 2 g intravenous propacetamol four times a day. The first dose was given at t_0 . The patients were allocated to the postoperative care unit for the first 12 postoperative hours and could receive a 2-mg

top-up of intravenous morphine given by a nurse if the visual analog scale score was greater than 30. After discharge home, all patients received 25 mg oral rofecoxib per day and 2 g oral paracetamol per day for the treatment of pain during 3 weeks if pain persisted.

Data Assessment

A research nurse not involved in the protocol was responsible for assessing pain every 8 h at the operated IC and operated shoulder (from t_0 to t_{48} , end of the study) by means of a visual analog scale (from 0 mm = no pain to 100 mm = worst pain imaginable) at rest and during motion (patient sitting, flexion of the thigh toward the thorax for the IC donor site—the test was considered adequate as soon as the patient's thigh was in contact with the abdomen, and passive abduction of the arm for the shoulder) and recording all episodes of nausea, vomiting, and pruritus. The amount of morphine consumption was recorded at t_{24} and t_{48} . The interscalene and IC catheters were observed daily for signs of inflammation or infection. Patients were asked to rate their satisfaction from 0 = completely dissatisfied to 10 = completely satisfied, the day after completion of the study. All the patients were observed independently by a surgeon and an anesthesiologist 3 months after surgery to assess the pain (anesthesiologist) at rest and during motion at the operated IC and operated shoulder, using the visual analog scale (0–100 mm). Neurologic assessment (numbness, dysesthesias, paresthesias) for damage of the lateral femoral cutaneous, ilioinguinal, and superior cluneal nerves was performed at the same time (surgeon).

Ropivacaine Blood Sampling

Ropivacaine blood concentrations were determined at t_0 , t_{24} , and t_{48} . Blood samples of 8 ml were taken for determination of total and unbound plasma concentrations of ropivacaine as well as α_1 -acid glycoprotein. The samples were taken in heparinized tubes (Venoject[®]; Terumo, Leuven, Belgium), and plasma was separated by centrifugation (10 min at 3,000 rotations/min) at room temperature within 60 min after collection. The plasma was stored at -20°C until drug assay. The total ropivacaine plasma concentration was determined by gas chromatography using a nitrogen-sensitive detector; the unbound plasma ropivacaine fraction was determined by coupled-column liquid chromatography with mass spectrometric detection using electrospray ionization after ultrafiltration of the sample. Concentrations of α_1 -acid glycoprotein were measured by immunoturbidimetry.

Statistical Analysis

Based on our experience, pain severity at rest in this surgical context was unacceptable in 20% of the patients receiving morphine through a patient-controlled analgesia device during the first 48 postoperative hours. A

Table 1. Patient Characteristics

	Ropivacaine Group (n = 18)	Saline Group (n = 18)
Sex, male/female	14/4	13/5
Age, yr*	25 (\pm 5)	26 (\pm 4)
Weight, kg*	80 (\pm 13)	75 (\pm 11)
Height, cm*	172 (\pm 7)	172 (\pm 8)
Operated side, left/right	12/6	7/11
Operation time, min*	89 (\pm 20)	88 (\pm 17)
Patient Satisfaction*†	9 (\pm 1)	6 (\pm 1)

* Values are expressed as mean \pm SD. † Patient satisfaction was scored from 0 = completely dissatisfied to 10 = completely satisfied.

clinical improvement of the pain scores in the IC catheter group should include a 25% reduction in pain during the first 48 postoperative hours to be considered significant. Based on this data, a power analysis indicated that a sample size of 18 patients per group was sufficient to have 80% power at the 95% significance level.

Data are reported as mean \pm SD unless otherwise stated. Demographic data, procedure duration, doses of morphine required, and patient satisfaction were assessed using the Mann-Whitney U test. Pain scores were analyzed with use of the Mann-Whitney U test with Bonferroni correction for multiple comparisons. Side effects were assessed using the Fisher exact test. For all determinations, a *P* value less than 0.05 was considered significant.

Results

All patients completed the study. Both groups were comparable with respect to age, sex, height, weight, and duration of surgery (table 1). All interscalene catheters were successfully placed, and no disconnection or other technical problems were encountered during the course of the study. Pain was significantly lower at the donor site at rest (except at t_{40}) and during motion (except at t_{48}) in the ropivacaine group (figs. 1A and B). At 3 months, pain at the donor site during motion (aching type) was significantly lower in the ropivacaine group. At rest, pain was similar in the two groups (figs. 2A and B). There was no significant difference among the groups regarding pain in the operated shoulder at rest or during motion, either during the first 48 postoperative hours or after 3 months (table 2). In the placebo group, the consumption of morphine was significantly increased compared to the ropivacaine group at 24 and 48 h (fig. 3). There was no significant difference in the incidence of nausea and vomiting, which occurred in 17 and 12% in the placebo and ropivacaine groups, respectively. Pruritus was observed in 7% of patients in the placebo group and 5% of patients in the ropivacaine group (not significant). No sign of inflammation or infection at the IC catheter skin puncture point was observed in any patient. Patient satisfaction was signifi-

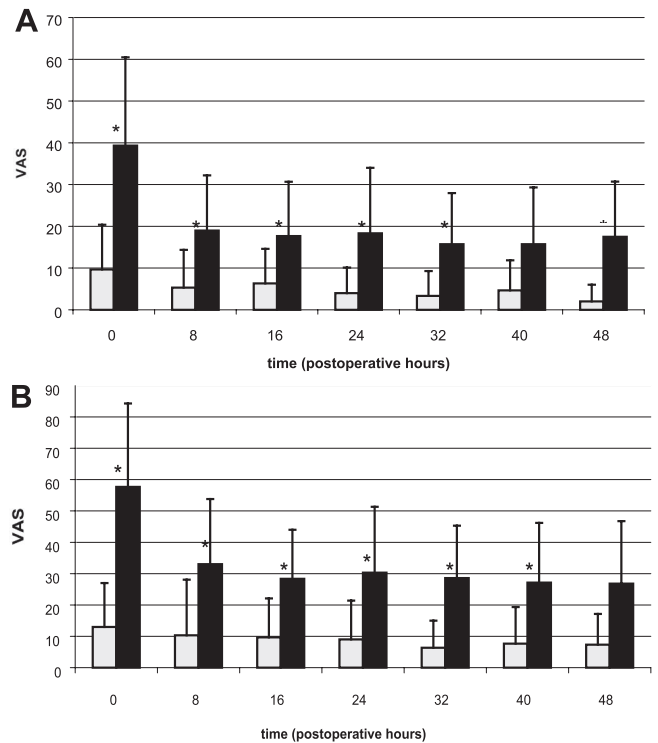


Fig. 1. Pain at the iliac crest at rest (A) and during motion (B) in patients receiving 0.2% ropivacaine (open bars) or saline (closed bars) through the iliac crest catheter. Measurements were made postoperatively (= t_0) and then every 8 h until t_{48} . VAS = visual analog scale from 0 = no pain to 100 = worst pain imaginable. Values are presented as mean \pm SD. * Significant differences between the two groups ($P < 0.05$).

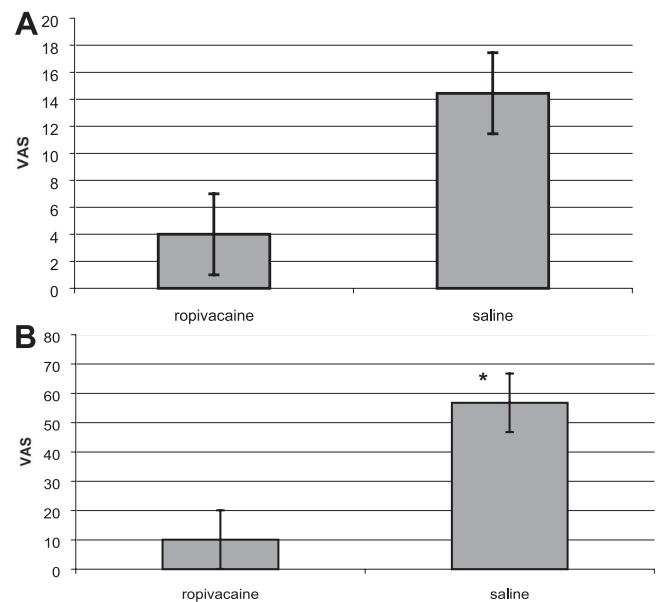


Fig. 2. Pain at the iliac crest at rest (A) and during motion (B) after 3 months in patients who received 0.2% ropivacaine or saline through the iliac crest catheter. VAS = visual analog scale from 0 = no pain to 100 = worst pain imaginable. Values are presented as mean \pm SD. * Significant difference between the two groups ($P < 0.05$).

Table 2. Postoperative Pain at the Shoulder

	0 h	8 h	16 h	24 h	32 h	40 h	48 h	3 months
At rest								
R group	1 (\pm 3)	1 (\pm 2)	2 (\pm 4)	6 (\pm 6)	3 (\pm 6)	4 (\pm 5)	2 (\pm 3)	7 (\pm 4)
P group	1 (\pm 2)	2 (\pm 4)	3 (\pm 4)	3 (\pm 4)	4 (\pm 5)	3 (\pm 5)	5 (\pm 6)	12 (\pm 4)
In motion								
R group	4 (\pm 6)	1 (\pm 5)	5 (\pm 9)	13 (\pm 12)	5 (\pm 6)	8 (\pm 10)	5 (\pm 5)	16 (\pm 6)
P group	2 (\pm 4)	4 (\pm 9)	6 (\pm 10)	6 (\pm 9)	10 (\pm 13)	7 (\pm 10)	8 (\pm 11)	22 (\pm 6)

Values are expressed as mean \pm SD. Pain, measured on a visual analog scale, is scored from 0 = no pain to 100 = worst pain imaginable.

cantly greater in the ropivacaine group than in the placebo group (table 1). The plasma concentrations of total ropivacaine were comparable in the two groups at all times (fig. 4A). The unbound fraction of ropivacaine was higher in the ropivacaine group at t_0 , t_{24} , and t_{48} , but only significantly higher at t_{24} (fig. 4B). There was no difference in the plasma concentrations of α_1 -acid glycoprotein at any time between the two groups. α_1 -Acid glycoprotein increased from 0.6 *versus* 0.55 to 0.8 *versus* 1.1 and 1.1 *versus* 1.2 g/l in the placebo group *versus* the ropivacaine group at t_0 , t_{24} , and t_{48} , respectively. Three months after surgery, no patient had signs of neurologic damage of the lateral cutaneous, ilioinguinal, or superior cluneal nerves. No patient had numbness, dysesthesias, or paresthesias.

Discussion

This study shows that, compared with placebo, continuous infusion of 0.2% ropivacaine through an IC catheter provides significantly better control of postoperative pain both at rest and during motion at the donor site, significant reduction of morphine consumption, and significantly higher patient satisfaction. The beneficial effect on pain was still present during motion 3 months after surgery.

Ropivacaine was chosen because, among the long last-

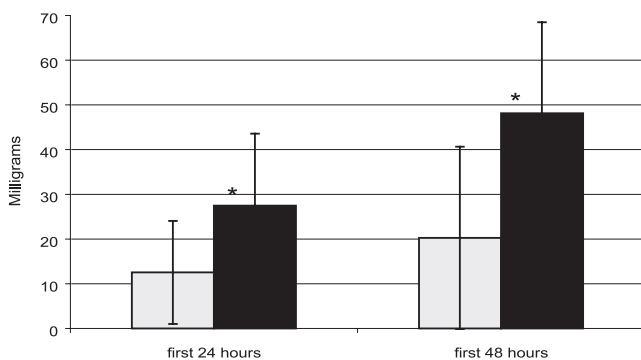


Fig. 3. Mean postoperative morphine consumption (in milligrams) in patients receiving 0.2% ropivacaine (open bars) or saline (closed bars) through the iliac crest catheter. Measurements were made 24 and 48 h postoperatively. Values are presented as mean \pm SD. * Significant differences between the two groups ($P < 0.05$).

ing amino acid local anesthetics, it provides the greatest margin of safety^{9,10} and the lowest potential for neurotoxicity.^{11,12} The concentration of 0.2% was used because a preliminary pilot study demonstrated good control of postoperative pain at the donor site.

To our knowledge, this study is the first to observe the efficacy of a continuous infusion of ropivacaine at the iliac donor site in patients undergoing Bankart repair for shoulder instability. The advantages of this model include a well-standardized surgical procedure requiring a similar amount of iliac bone and the fact that both surgical sites receive the same drug for the pain treatment. Ropivacaine through an interscalene catheter has been shown to be very efficient for pain relief after shoulder surgery. This has the advantage in this context of almost completely abolishing the influence of other pain than that resulting from the donor site. The beneficial effects of local anesthetics in this condition have

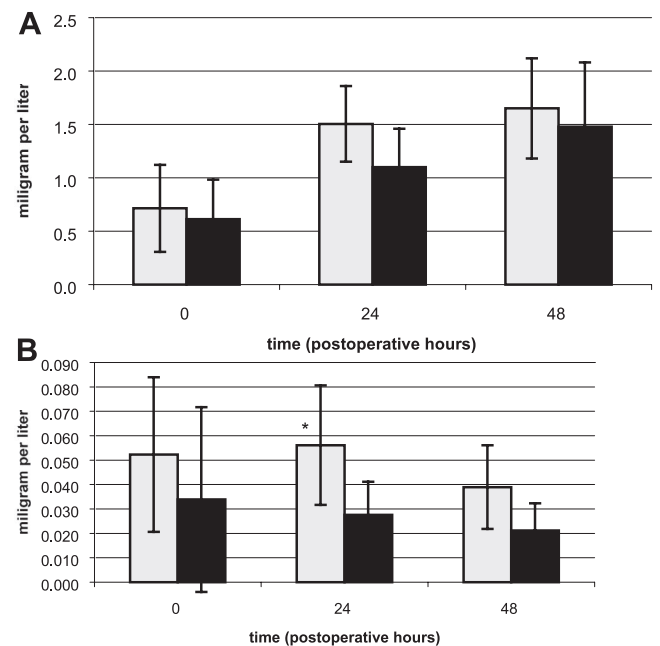


Fig. 4. Plasma concentration of total (A) and unbound (B) ropivacaine in patients receiving 0.2% ropivacaine (open bars) or saline (closed bars) through the iliac crest catheter. Measurements were made 24 and 48 h postoperatively. Values are presented as mean \pm SD. * Significant differences between the two groups ($P < 0.05$).

been demonstrated by different studies.^{13,14} Todd and Reed¹⁵ showed a reduction of pain intensity at the donor site for 4 h after infiltration of IC with 20 ml bupivacaine, 0.5%. Cowan *et al.*¹⁶ made the same observation after repeated administration of boluses of 0.25% bupivacaine. Our results are in accordance with those of Brull *et al.*⁸ In this study, the authors demonstrated a significant decrease of immediate and residual postoperative pain by administering through an 20-gauge catheter at least one injection of 0.25% bupivacaine with 1:200,000 epinephrine in patients who underwent spinal fusion surgery compared with a retrospective control group. At 6 months, the incidence of chronic donor site pain was still lower in the group that received bupivacaine. Gundes *et al.*¹⁷ demonstrated that adding morphine to bupivacaine resulted in a better pain control as compared with bupivacaine alone. The beneficial effect of this treatment was still significant at 12 weeks. Reuben *et al.*⁷ infiltrated the harvest site with 5 mg morphine in patients undergoing cervical spine fusion surgery and compared this group of patients to a group that received the same amount of morphine in the deltoid muscle. The authors found significantly better pain control in the former group in the early postoperative phase as well as 1 yr later. In this investigation, no data regarding motion are reported. This would have been informative because opioids, contrary to local anesthetics, are weak blockers of the A- δ fibers, which are closely linked to movement.¹⁸ The mechanism of the pain at the IC site remains unknown. It has been postulated to be muscular or periosteal in nature, secondary to stripping of the abductors from the ilium.⁶ This is in accordance with the large increase in pain intensity observed in the placebo group at 3 months during flexion of the thigh toward the thorax. The development of neuropathic pain has been advocated because damage of the lateral femoral cutaneous, ilioinguinal, or superior cluneal nerves has been reported.¹ In our study, no patient had clinical characteristics of neuropathic pain, and no sensory disturbance involving the territory of one of the above-mentioned nerves was evidenced. The placement of the catheter in a "swab" on the wounded periost seems to be appropriate because neurosensory pain fibers are highly concentrated in the periosteum, whereas fine myelinated and nonmyelinated fibers accompany vessels into bone.^{19,20}

The beneficial effect of the reduced lower incidence of chronic donor site pain observed in this investigation and others^{7,17} are suggestive of a preemptive analgesic effect in which a reduction in spinal cord hyperexcitability is attained by a prompt reduction in noxious afferent input.²¹ However, this topic is controversial,²² and, as shown by Kelly *et al.*,²³ the variable patient characteristics and timing of preemptive analgesia in relation to surgical noxious input required individualization of the technique chosen. Moreover, multimodal

analgesic techniques seem more effective than a single-drug treatment.²⁴

In the ropivacaine group, patients received a continuous infusion of 0.2% ropivacaine at 15 ml/h (10 and 5 ml through the interscalene and IC catheters, respectively). The mean unbound blood concentrations of ropivacaine were 0.051, 0.056, and 0.039 mg/l at t_0 , t_{24} , and t_{48} , respectively. These values remain well below the concentrations for early signs of central nervous toxicity of 0.15 mg/l found by Knudsen *et al.*²⁵ These results are comparable to those found after a continuous infusion of 0.2% ropivacaine at 9 ml/h (0.03 mg/l at 48 h). The decrease of the unbound fraction of ropivacaine observed at t_{48} may be explained by the increase of α_1 -acid glycoprotein, which acts as a buffer for the unbound fraction of the local anesthetic.²⁶

The incidences of nausea and vomiting and pruritus were comparable in the two groups despite the reduced morphine consumption and the better pain control in the ropivacaine group. The main endpoint of the current investigation was the pain score, and therefore, the study was most likely underpowered to disclose a difference regarding the adverse effects between the two groups.

The current study shows evidence that a continuous infusion of 0.2% ropivacaine through an IC catheter to the harvest side can reduce the incidence and severity of both early and chronic donor site pain after Bankart repair for shoulder instability. This was associated with a lower pain score in the immediate postoperative period, reduced morphine consumption, higher patient satisfaction, and a lower pain score during motion 3 months after surgery.

The authors thank Paul Harpes, M.D. (Institute of Biostatistics, Department of Psychosocial Medicine, University Hospital, Zurich, Switzerland), for his help in performing the statistics.

References

1. Kurz LT, Garfin SR, Booth RE Jr: Harvesting autogenous iliac bone grafts: A review of complications and techniques. *Spine* 1989; 14:1324-31
2. Fernyhough JC, Schimandle JJ, Weigel MC, Edwards CC, Levine AM: Chronic donor site pain complicating bone graft harvesting from the posterior iliac crest for spinal fusion. *Spine* 1992; 17:1474-80
3. Goulet JA, Senunas LE, DeSilva GL, Greenfield ML: Autogenous iliac crest bone graft: Complications and functional assessment. *Clin Orthop* 1997; 339:76-81
4. Borgeat A, Schappi B, Biasca N, Gerber C: Patient-controlled analgesia after major shoulder surgery: Patient-controlled interscalene analgesia *versus* patient-controlled analgesia. *ANESTHESIOLOGY* 1997; 87:1343-7
5. Singelyn FJ, Seguy S, Gouverneur JM: Interscalene brachial plexus analgesia after open shoulder surgery: Continuous versus patient-controlled infusion. *Anesth Analg* 1999; 89:1216-20
6. Summers BN, Eisenstein SM: Donor site pain from the ilium: A complication of lumbar spine fusion. *J Bone Joint Surg Br* 1989; 71:677-80
7. Reuben SS, Vieira P, Faruqi S, Verghis A, Kilaru PA, Maciolek H: Local administration of morphine for analgesia after iliac bone graft harvest. *ANESTHESIOLOGY* 2001; 95:390-4
8. Brull SJ, Lieponis JV, Murphy MJ, Garcia R, Silverman DG: Acute and long-term benefits of iliac crest donor site perfusion with local anesthetics. *Anesth Analg* 1992; 74:145-7
9. Radwan IA, Saito S, Goto F: The neurotoxicity of local anesthetics on growing neurons: A comparative study of lidocaine, bupivacaine, mepivacaine, and ropivacaine. *Anesth Analg* 2002; 94:319-24

10. Ohtake K, Matsumoto M, Wakamatsu H, Kawai K, Nakakimura K, Sakabe T: Glutamate release and neuronal injury after intrathecal injection of local anesthetics. *Neuroreport* 2000; 11:1105-9
11. Graf BM, Abraham I, Eberbach N, Kunst G, Stowe DF, Martin E: Differences in cardiotoxicity of bupivacaine and ropivacaine are the result of physicochemical and stereoselective properties. *ANESTHESIOLOGY* 2002; 96:1427-34
12. Groban L, Deal DD, Vernon JC, James RL, Butterworth J: Does local anesthetic stereoselectivity or structure predict myocardial depression in anesthetized canines? *Reg Anesth Pain Med* 2002; 27:460-8
13. Borgeat A, Tewes E, Biasca N, Gerber C: Patient-controlled interscalene analgesia with ropivacaine after major shoulder surgery: PCIA vs PCA. *Br J Anaesth* 1998; 81:603-5
14. Borgeat A, Perschak H, Bird P, Hodler J, Gerber C: Patient-controlled interscalene analgesia with ropivacaine 0.2% *versus* patient-controlled intravenous analgesia after major shoulder surgery: Effects on diaphragmatic and respiratory function. *ANESTHESIOLOGY* 2000; 92:102-8
15. Todd BD, Reed SC: The use of bupivacaine to relieve pain at iliac graft donor sites. *Int Orthop* 1991; 15:53-5
16. Cowan N, Young J, Murphy D, Bladen C: Double-blind, randomized, controlled trial of local anesthetic use for iliac crest donor site pain. *J Neurosci Nurs* 2002; 34:205-10
17. Gundes H, Kilickan L, Gurkan Y, Sarlak A, Toker K: Short- and long-term effects of regional application of morphine and bupivacaine on the iliac crest donor site. *Acta Orthop Belg* 2000; 66:341-4
18. Pirec V, Laurito CE, Lu Y, Yeomans DC: The combined effects of N-type calcium channel blockers and morphine on A delta versus C fiber mediated nociception. *Anesth Analg* 2001; 92:239-43
19. Williams PL, Warwick R, Dyson M: *Gray's Anatomy*, 37th edition. Edinburgh, Churchill Livingstone, 1989, p 300
20. Woodburne RT: *Essentials of Human Anatomy*. New York, Oxford University, 1983, p 42
21. Woolf CJ, Chong MS: Preemptive analgesia: Treating postoperative pain by preventing the establishment of central sensitization. *Anesth Analg* 1993; 77:362-79
22. Kissin I: Preemptive analgesia: Why its effect is not always obvious. *ANESTHESIOLOGY* 1996; 84:1015-9
23. Kelly DJ, Ahmad M, Brull SJ: Preemptive analgesia: I. Physiological pathways and pharmacological modalities. *Can J Anaesth* 2001; 48:1000-10
24. Kelly DJ, Ahmad M, Brull SJ: Preemptive analgesia: II. Recent advances and current trends. *Can J Anaesth* 2001; 48:1091-101
25. Knudsen K, Beckman Suurkula M, Blomberg S, Sjoval J, Edvardsson N: Central nervous and cardiovascular effects of i.v. infusions of ropivacaine, bupivacaine and placebo in volunteers. *Br J Anaesth* 1997; 78:507-14
26. Ekatodramis G, Borgeat A, Huledal G, Jeppsson L, Westman L, Sjoval J: Continuous interscalene analgesia with ropivacaine 2 mg/ml after major shoulder surgery. *ANESTHESIOLOGY* 2003; 98:143-50