

GW280430A

To the Editor:—We appreciate the three articles in the April 2004 issue of ANESTHESIOLOGY regarding GW280430A.¹⁻³ Although remarkable advances in developing intermediate and short-acting muscle relaxants were realized, anesthetists have not yet been provided with a substance comparable to succinylcholine in terms of its rapid onset and ultrashort-acting pharmacodynamic profile.

However, this aim should not be lost. A survey in Germany⁴ revealed that, despite its undesirable side effects, succinylcholine is still the most used drug for both rapid sequence inductions⁵ and for elective case induction.⁶ An overwhelming majority (76.6%) of respondents answered that they would appreciate a nondepolarizing substitute for succinylcholine if a similar pharmacodynamic profile was preserved. Assuming that this is not an isolated German viewpoint, a substance replacing succinylcholine would be highly desirable.

The developers and the researchers have a great responsibility when introducing a new drug into clinical practice, particularly in neuromuscular blocking drugs.⁷ Dr. Caldwell addresses this issue in his editorial when he compares the side effects of rapacuronium and GW280430A.⁸ Because we were involved in the clinical evaluation of rapacuronium,⁹⁻¹¹ we would like to comment on some relevant aspects of the side effect profiles of both drugs and on the drug approval processes. First, in clinically relevant concentrations, rapacuronium potentiates bronchoconstriction most probably by destabilization of the balance between M2 and M3 muscarinic receptors.¹² In contrast, GW280430A seems to release histamine³ and therefore may possibly induce bronchoconstriction. Second, although many antihistaminic drugs and prophylactic strategies are available, an effective treatment to rebalance the muscarinic effects of rapacuronium was and is still missing. Third, because rapacuronium did not release histamine,¹³ because different M2 versus M3 muscarinic effects of muscle relaxants were unknown at that time, and because clinical symptoms of the pulmonary side effects differed from those seen during typical bronchoconstriction,¹² the clearly described dose-dependent pulmonary side effects (from 10.7% with 1.5 mg/kg rapacuronium to 18.5% with 2.5 mg/kg rapacuronium)^{9,10} may have been questioned—unfortunately until patients were badly harmed. Therefore, we agree with Dr. Caldwell that the recent experience with rapacuronium must be considered during the trials with GW280430A, e.g., by in addition investigating its effects on M2 and M3 receptors. The fiasco with rapacuronium, however, must not induce pessimism if new drugs and especially GW280430A may have the potency to improve anesthesia practice.

GW280430A was, of course, not compared with rapacuronium, but it was also not compared to succinylcholine.¹⁻³ Regardless, the hope that GW280430A will be a substitute for succinylcholine has been advanced⁸ with this first presentation. Expectations that this new drug will approximate the rapid onset of succinylcholine may in high doses, high injection speeds, and, therefore, the risk for high incidences of side effects. The presentations¹⁻³ primarily suggest that GW280430A may be an ultrashort-acting rather than a rapid-onset muscle relaxant.

Unfortunately, preclinical and clinical trials to approve new drugs

are expensive, and, in this context, the substance to be replaced is already very cheap. Nevertheless, we (and many other anesthetists⁴⁻⁶) would like to encourage the recent attempts to develop better muscle relaxants (or reversal drugs, e.g., Org 25969¹⁴) to improve safety and efficiency of neuromuscular treatment during anesthesia.

Goetz F. Geldner, D.E.A.A., M.D., Ph.D.,* Manfred Blobner, M.D., Ph.D. * Klinik für Anästhesie und Intensivtherapie der Philipps-Universität, Marburg, Germany. geldner@mail.uni-marburg.de

References

1. Savarese JJ, Belmont MR, Hashim MA, Mook RA Jr, Boros EE, Samano V, Patel SS, Feldman PL, Schultz J-AI, McNulty M, Spitzer T, Cohn DL, Morgan P, Wastila WB: Preclinical pharmacology of GW280430A (AV430A) in the rhesus monkey and in the cat: A comparison with mivacurium. ANESTHESIOLOGY 2004; 100:835-45
2. Heerdt PM, Kang R, The' A, Hashim M, Mook RJ Jr, Savarese JJ: Cardiopulmonary effects of the novel neuromuscular blocking drug GW280430A (AV430A) in dogs. ANESTHESIOLOGY 2004; 100:846-51
3. Belmont M, Lien C, Tjan J, Bradley E, Stein B, Patel S, Savarese J: Clinical pharmacology of GW280430A in humans. ANESTHESIOLOGY 2004; 100:768-73
4. Blobner M, Sohnel AM, van de Roemer A, Bachmann H, Geldner G, Hofmockel R, Fuchs-Buder T, Diefenbach C, Ulm K: Anwendung von Muskelrelaxanzien in Deutschland. Eine Umfrage an Deutschen Anästhesieeinrichtungen. Anaesthesist 2003; 52:427-34
5. Hofmockel R, Geldner G, Diefenbach C, Fuchs-Buder T, Ulm K, Blobner M: Die Anwendung von Muskelrelaxanzien zur Blitzintubation in Deutschland. Anaesthesist 2003; 52:516-21
6. Geldner G, Fuchs-Buder T, Hofmockel R, Diefenbach C, Ulm K, Blobner M: Anwendung von Muskelrelaxanzien zur Routineeinleitung in Deutschland. Anaesthesist 2003; 52:435-41
7. Goudsouzian NG: Rapacuronium and bronchospasm. ANESTHESIOLOGY 2001; 94:727-8
8. Caldwell J: The continuing search for a succinylcholine replacement. ANESTHESIOLOGY 2004; 100:763-4
9. Blobner M, Mirakhor RK, Wierda JM, Wright PM, Olkkola KT, Debaene B, Pendeville P, Engbaek J, Rietbergen H, Sparr HJ: Rapacuronium 2.0 or 2.5 mg kg⁻¹ for rapid-sequence induction: comparison with succinylcholine 1.0 mg kg⁻¹. Br J Anaesth 2000; 85:724-31
10. Sparr HJ, Mellinshoff H, Blobner M, Nöldge-Schomburg G: Comparison of intubating conditions after rapacuronium (Org 9487) and succinylcholine following rapid sequence induction in adult patients. Br J Anaesth 1999; 82:537-41
11. Geldner G, Lang C, Hoffmann W, Hossfeld A, Weinberger J, Eble M, Blobner M: Spontane und induzierte neuromuskuläre Erholung nach gleich langer Relaxierung mit Rapacuronium und Mivacurium. Anaesthesiol Intensivmed Notfallmed Schmerzther 2003; 38:594-9
12. Jooste E, Klaffer F, Hirshman CA, Emala CW: A mechanism for rapacuronium-induced bronchospasm: M2 muscarinic receptor antagonism. ANESTHESIOLOGY 2003; 98:906-11
13. Levy JH, Pitts M, Thanopoulos A, Szlam F, Bastian R, Kim J: The effects of rapacuronium on histamine release and hemodynamics in adult patients undergoing general anesthesia. Anesth Analg 1999; 89:290-5
14. Epemolu O, Bom A, Hope F, Mason R: Reversal of neuromuscular blockade and simultaneous increase in plasma rocuronium concentration after the intravenous infusion of the novel reversal agent Org 25969. ANESTHESIOLOGY 2003; 99:632-7

(Accepted for publication November 17, 2004.)

GW280430A: Pharmacodynamics and Potential Adverse Effects

To the Editor:—We read with interest Dr. Caldwell's recent editorial¹ accompanying the articles published on GW280430A.²⁻⁴ Although we agree with his assessment of its potential advantages, we have several concerns with respect to his comments regarding its adverse effects.

GW280430A is a potent, nondepolarizing neuromuscular blocking agent with a fast onset of effect and a duration of action similar to that of succinylcholine.²⁻⁴ When administered as a rapid intravenous bolus to volunteers in doses greater than or equal to 2.8 times the ED₉₅, it

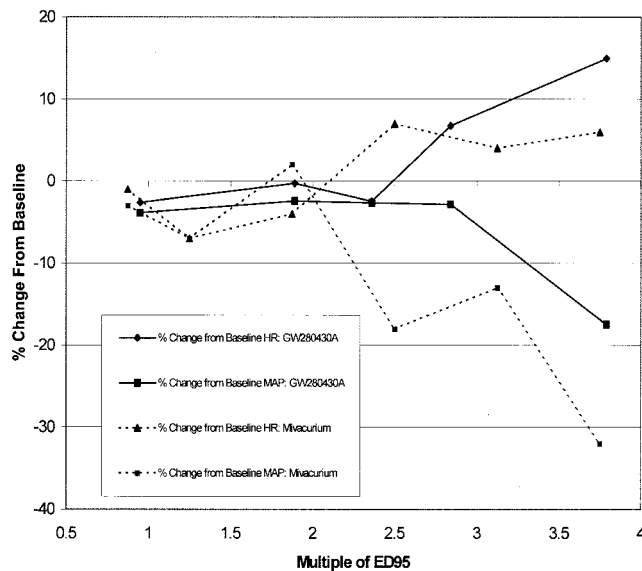


Fig. 1. The mean maximal heart rate (HR) and blood pressure changes after bolus administration of GW280430A² and mivacurium.⁵ Decreases in mean arterial pressure (MAP) and increases in HR occur at doses of 2.5 times the ED₉₅ of mivacurium. An average increase in HR of 7% occurs with administration of 2.8 times the ED₉₅ of GW280430A, and an average increase of 14% occurs after administration of 3.8 times the ED₉₅ of GW280430A. Decreases in MAP occurred at a dose of 3.8 times the ED₉₅. The average maximal decrease at this dose of GW280430A was 18%. At all doses, GW280430A was administered as a bolus (5 s) into a rapidly flowing intravenous line. In the study of mivacurium,⁵ the neuromuscular blocking agent was injected three times more slowly (15 s).

may cause histamine release and subsequent hemodynamic changes, a decrease in blood pressure, and an increase in heart rate.² As reported by Belmont *et al.*,² such changes were observed in 25% of volunteers receiving a dose of 2.8 times the ED₉₅ and 75% of volunteers receiving a dose of 3.8 times the ED₉₅. As is typical of cardiovascular effects due to histamine release, these hemodynamic changes were all self-limited and required no pharmacologic treatment. As anticipated, observed symptoms of histamine release increased in frequency as the dose of GW280430A was increased. No attempt was made to decrease histamine release in that all doses were administered as a rapid intravenous bolus (5 s) into a rapidly flowing intravenous line. To put this further into perspective, as demonstrated in figure 1, the average maximal heart rate and blood pressure changes after administration of GW280430A are less than those observed after administration of mivacurium, when mivacurium is injected slowly (over 15 s).⁵ Doses of 2.5 times the ED₉₅ of GW280430A do not cause histamine release even when administered over 5 s. Furthermore, because 90% suppression of T₁ occurs within 1.3 min after administration of 0.36 mg/kg GW280430A, tracheal intubation may likely be accomplished in 60 s with doses lower than those recommended for mivacurium.

We did not enroll volunteers with a history of cigarette smoking or

pulmonary disease. Bronchospasm or any other difficulty with ventilation was not encountered over the course of the volunteer trial. This problem has been encountered rarely in the thousands of patients who have received mivacurium, which has a greater propensity to release histamine than GW280430A.

The bronchospasm noted after administration of rapacuronium is likely not due to histamine release. Bronchospasm has occurred in patients receiving rapacuronium with no evidence of histamine release.⁶ The bronchospasm after administration of rapacuronium is likely caused by its antagonism of the muscarinic M2 receptor.⁷ Nondepolarizing neuromuscular blocking agents can interact with two of the three muscarinic receptors that exist in the airways (M1, M2, and M3). Their antagonism of the M3 receptor causes bronchodilation by inhibiting vagally induced bronchoconstriction. Antagonism of the M2 receptors, which are located presynaptically at postganglionic parasympathetic nerve endings, results in an increased release of acetylcholine that subsequently binds to M3 receptors, causing bronchoconstriction. The affinity of rapacuronium for the M2 receptor is 15 times its affinity for the M3 receptor.⁷

As shown in experiments in cats,⁴ GW280430A is a very weak inhibitor of muscarinic receptors in general, with nearly the same safety ratio for this side effect as mivacurium. In cats, the muscarinic blocking dose (ED₅₀) of GW280430A is more than 25 times its ED₉₅ for neuromuscular block.⁴ A closer look at the data in the study of Heerd *et al.*³ in dogs shows a complete lack of effect of GW280430A on airway pressures in the dog, even at doses of 50 times the ED₉₅. Nevertheless, GW280430A will have to be further tested for its relative affinity for the muscarinic receptors of the airways, as will all other nondepolarizing relaxants that may be introduced into clinical practice. Based on the data published to date,²⁻⁴ there is no reason to anticipate that GW280430A may even rarely cause life-threatening bronchospasm.

Cynthia A. Lien, M.D.,* Matthew R. Belmont, M.D., Paul M. Heerd, M.D., Ph.D. * Weill Medical College of Cornell University, New York, New York. calien@med.cornell.edu

References

1. Caldwell JE: The continuing search for a succinylcholine replacement. *ANESTHESIOLOGY* 2004; 100:763-4
2. Belmont MR, Lien CA, Tjan J, Bradley E, Stein B, Patel SS, Savarese JJ: Clinical pharmacology of GW280430A in humans. *ANESTHESIOLOGY* 2004; 100:768-773
3. Heerd PM, Kang R, The' A, Hashim M, Mook RJ Jr, Savarese JJ: Cardiopulmonary effects of the novel neuromuscular blocking drug GW280430A (AV430A) in dogs. *ANESTHESIOLOGY* 2004; 100:846-51
4. Savarese JJ, Belmont MR, Hashim MA, Mook RA Jr, Boros EE, Samano V, Patel SS, Feldman PL, Schultz J-AI, McNulty M, Spitzer T, Cohn DL, Morgan P, Wastila WB: Preclinical pharmacology of GW280430A (AV430A) in the rhesus monkey and in the cat: A comparison with mivacurium. *ANESTHESIOLOGY* 2004; 100:835-45
5. Savarese JJ, Ali HH, Basta SJ, Scott RP, Embree PB, Wastila WB, Abou-Donia MM, Gelb C: The cardiovascular effects of mivacurium chloride (BW B1090U) in patients receiving nitrous oxide-opiate-barbiturate anesthesia. *ANESTHESIOLOGY* 1989; 70:368-94
6. Levy JH, Pitts M, Thanopoulos A, Szlam F, Bastian R, Kim J: The effects of rapacuronium on histamine release and hemodynamics in adult patients undergoing general anesthesia. *Anesth Analg* 1999; 89:290-5
7. Jooste E, Klafter F, Hirshman CA, Emala C: A mechanism for rapacuronium-induced bronchospasm: M2 muscarinic receptor antagonism. *ANESTHESIOLOGY* 2003; 98:906-11

(Accepted for publication November 17, 2004.)

In Reply:—I am grateful to Drs. Geldner and Blobner and Dr. Lien *et al.* for their responses to my editorial.¹ I agree with Drs. Geldner and Blobner that succinylcholine still has a significant clinical role, and that anesthesia providers would like to see it replaced by a nondepolarizing drug with a similar time course of action. I agree also that we should not be pessimistic about prospects for new drugs, but history and

recent experience (the withdrawal of rapacuronium) amply demonstrate that it is prudent to exercise caution when evaluating the clinical potential of experimental drugs.

Before proceeding, I must make an apology for and clarify confusing language in my editorial. The text as written, "Is there evidence of such a potential problem with GW280403A?" is clearly open to misinter-

pretation. I did not intend to suggest that GW280403A produced bronchospasm; there is no evidence for that. Rather, my intent was to emphasize that any adverse effect observed during clinical trials may assume far greater significance when the drug goes into general use. The experience with rapacuronium was a dramatic illustration of this point. In the case of GW280403A, the adverse effects raising concern are its propensity to release histamine and to produce hypotension.²

I differ with Dr. Lien *et al.* in the interpretation of the significance of the adverse hemodynamic effects of GW280403A. For example, take their statement "As is typical of cardiovascular effects due to histamine release, these hemodynamic changes were all self-limited and required no pharmacologic treatment." I do not believe that the word *typical* can be used to characterize histamine-related effects. These effects can vary from trivial, localized, cutaneous flushing to life-threatening cardiovascular collapse. The fact that in a small sample of healthy young volunteers, who can increase heart rate to compensate for histamine-mediated vasodilatation, a blood pressure decrease of nearly 40% was observed is a matter for concern.² The obvious question is how severely might this degree of histamine release manifest in patients with much less cardiovascular reserve.

In addition, the fact that the blood pressure changes required no pharmacologic treatment in this limited subject population cannot be used to predict safety in the general population of patients. The subjects studied were all healthy young volunteers in whom a period of hypotension might be tolerable. Allowing the persistence of hypotension without treatment would not be an option for many patients undergoing anesthesia.

Will the doses of GW280403A causing histamine release and hypotension overlap with the doses that might be used in clinical practice? Dr. Lien *et al.* suggest not by speculating that GW280403A in dose of 0.36 mg/kg ($2 \times ED_{95}$) will provide good intubating conditions in 60 s. Because the onset time of 0.36 mg/kg GW280403A ranged up to 2 min in this small, healthy, and homogeneous group of subjects, it is difficult to believe that intubation within 60 s could be reliably achieved in the general patient population with this dose. It is likely that larger doses will be required to facilitate rapid tracheal intubation. As I described in my editorial, there is ample evidence that clinicians tend to increase

Anesthesiology 2005; 102:863-5

In Reply:—The three reports by our group in the April (2004) issue of ANESTHESIOLOGY¹⁻³ on the new ultrashort-acting nondepolarizing relaxant GW280430A (AV430A) have evoked invited commentary by Caldwell⁴ and observations by Geldner and Blobner. Both anticipation and caution were expressed by these commentators regarding the possible future clinical performance of AV430A.

To add to the discussion, I would offer a rather optimistic viewpoint based on additional data in preparation for publication. I am certainly biased because of my closeness to the development of AV430A. Nevertheless, I do believe that future results will strengthen the candidacy of AV430A as a replacement for succinylcholine or as an excellent alternative.

AV430A is a representative of the new class of nondepolarizing relaxants, which we have called asymmetrical mixed-onium chlorofumarates.⁵ These compounds are inactivated by two entirely chemical (nonenzymatic) mechanisms both *in vivo* and *in vitro*: cysteine adduction and pH-sensitive hydrolysis.^{1,5,6} The cysteine adduction reaction is notably manipulatable.^{5,6} In AV430A, both reactions are fast (combined $T_{1/2\beta}$ approximately 1-2 min) such that the duration of block is ultrashort, similar in duration to or even shorter than succinylcholine in cats, dogs, and three different primate species.^{1,3}

Dr. Savarese has been a consultant to Glaxo Wellcome, Research Triangle Park, North Carolina, and is one of the inventors and patent holders of GW280430A and related compounds on behalf of Cornell University, New York, New York.

doses of neuromuscular blocking drugs to achieve better and faster intubating conditions.³⁻⁵ Therefore, it is feasible that clinicians might use GW280403A in the dose range $3-4 \times ED_{95}$, and the work by Dr. Lien *et al.* shows that at these doses, histamine release and hypotension can occur.²

Finally, it is not justified to infer the cardiovascular safety of GW280403A by using 15-yr-old historic comparisons with mivacurium.⁶ There is no way to ensure the comparability of the study procedures or subjects. The weakness of this comparison is further compounded by the use of "average maximal changes" as the variables for comparison. This averaging masks larger changes in individual subjects, and it is these that have the most clinical significance.

In summary, I do not believe that bronchospasm is a significant clinical issue with GW280403A, but histamine release and hypotension most assuredly are.

James E. Caldwell, M.B.Ch.B., University of California, San Francisco, California. caldwell@anesthesia.ucsf.edu

References

1. Caldwell JE: The continuing search for a succinylcholine replacement. ANESTHESIOLOGY 2004; 100:763-4
2. Belmont MR, Lien CA, Tjan J, Bradley E, Stein B, Patel SS, Savarese JJ: Clinical pharmacology of GW280430A in humans. ANESTHESIOLOGY 2004; 100:768-73
3. Pino RM, Ali HH, Denman WT, Barrett PS, Schwartz A: A comparison of the intubation conditions between mivacurium and rocuronium during balanced anesthesia. ANESTHESIOLOGY 1998; 88:673-8
4. Motamed C, Donati F: Intubating conditions and blockade after mivacurium, rocuronium and their combination in young and elderly adults. Can J Anaesth 2000; 47:225-31
5. Doenicke AW, Czeslick E, Moss J, Hoerneck R: Onset time, endotracheal intubating conditions, and plasma histamine after cisatracurium and vecuronium administration. Anesth Analg 1998; 87:434-8
6. Savarese JJ, Ali HH, Basta SJ, Scott RP, Embree PB, Wastila WB, Abou-Donia MM, Gelb C: The cardiovascular effects of mivacurium chloride (BW B1090U) in patients receiving nitrous oxide-opiate-barbiturate anesthesia. ANESTHESIOLOGY 1989; 70:386-94

(Accepted for publication November 17, 2004.)

© 2005 American Society of Anesthesiologists, Inc. Lippincott Williams & Wilkins, Inc.

Notable characteristics of this series include high potency, easy antagonism by anticholinesterases, and rapid antagonism by cysteine (see last paragraph). AV430A is particularly nonvagolytic,¹ an important contrast *vis-à-vis* rapacuronium, and does not block sympathetic ganglia.¹ AV430A is approximately four times weaker than mivacurium with respect to release of histamine in the rhesus monkey.¹ These autonomic data suggest that the only possible side effect of AV430A that might appear in the clinical dose range is a rather mild tendency to cause minor symptoms and signs suggestive of slight degrees of histamine release, exemplified by facial erythema, brief decrease in blood pressure, and increase in heart rate.

AV430A and its related series were first studied in 1997. Despite encouraging results in human volunteers,² the development process has been delayed. First, a corporate decision by Glaxo Wellcome (Research Triangle Park, NC) to discontinue the development of products for the field of anesthesia, and then the merger of Glaxo Wellcome and Smith Kline, halted the project for 4 yr until the AV430A series was acquired by Avera Pharmaceuticals (San Diego, CA) in 2002. In 2003, a second study of a new formulation of AV430A in volunteers was completed and reported in 2004. The kinetic and safety data are encouraging.^{7,8}

The failure of rapacuronium and its removal from the market, as a result of the side effect of bronchospasm, will place greater scrutiny on the possible airway effects of all new relaxants. An ultrashort-acting agent such as AV430A, which will no doubt be given for tracheal intubation, will bear the greatest scrutiny. Bronchospasm after rapacuronium, although noted in clinical trials, was far more serious in

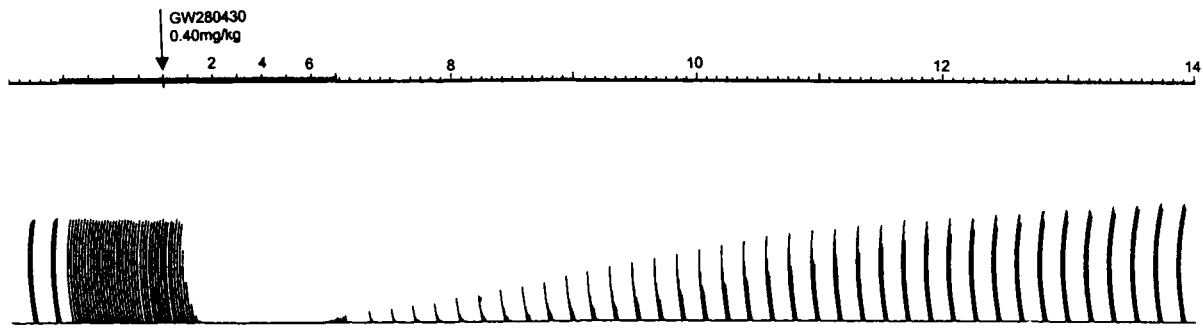


Fig. 1. A recording of evoked twitch (at 0.15 Hz) and train-of-four (2 Hz for 2 s every 10 s) of the adductor pollicis in an anesthetized human volunteer. AV430A (0.4 mg/kg) was given intravenously at the arrow. Time scale (minutes) at top. Note change of time scale and change of evoked response from single twitch to train-of-four at minute 7. Onset of block is 80 s. Recovery to train-of-four of 95% is 13.5 min.

clinical practice with rapacuronium than foreseen before its release. This is the crux of the problem: Minimal effects of AV430A on the airway must be shown to provide convincing data regarding the safety of AV430A. Caldwell⁴ and Geldner and Blobner both allude to this.

Following is a discussion of some of the data regarding AV430A that are already published, which suggest that AV430A should be safe as far as airway effects are concerned. Minimal airway effects have already been found in dogs in doses up to $50 \times \text{ED}_{95}$.³ The nonvagolytic properties of AV430A found in cats¹ mean that it is unlikely to have any blocking effects on M2 or M3 receptors in the human airway. This indicates minimal possibility of bronchospasm on this basis, in contrast with the severe responses noted after rapacuronium. Jooste *et al.*¹⁰ have shown that mivacurium has minimal interactions with M2 and M3 receptors⁹ where the actions of rapacuronium are clearly demonstrable. Because mivacurium, which is a predecessor of AV430A, has approximately the same large safety ratio (> 25) as does AV430A regarding lack of interaction with muscarinic receptors in cats,¹ the imbalanced blocking property on muscarinic receptors in the human airway, which is the likely mechanism of rapacuronium-induced bronchospasm,¹⁰ is a most unlikely clinical scenario in the case of AV430A.

What about histamine release? Both Caldwell⁴ and Geldner and Blobner express concern about this, but in the rhesus monkey, the safety ratio of AV430A for this side effect is approximately four times greater than that of mivacurium.¹ This results in the following comparison in humans: mivacurium, at $2.5\text{--}3 \times \text{ED}_{95}$ (0.20–0.25 mg/kg), causes greater symptomatology of histamine release when injected over 15 s¹¹ than does AV430A when injected over only 5 s at $3\text{--}4 \times \text{ED}_{95}$ (0.5 mg/kg).² Since the original study in human volunteers by Belmont *et al.*² in 1998, AV430A has been reformulated. This reformulation has further improved the safety ratio for histamine release to approximately $4 \times \text{ED}_{95}$ in humans.⁷ As a reminder, this “safety ratio” is defined as the dose required to cause an average decrease in blood pressure of 10%, divided by the ED_{95} for neuromuscular blockade: $\text{ED}_{\text{Hist}}/\text{ED}_{95}$.¹

Both Caldwell⁴ and Geldner and Blobner caution that anesthesiologists might increase dosage to cause faster onset and thereby increase the possibility of histamine release by AV430A. We have already compared the onset and duration of AV430A in the human larynx and the thumb *vis-a-vis* succinylcholine, rapacuronium, rocuronium, mivacurium, and cisatracurium. The data are not yet published but suggest that the onset of AV430A is as fast as that of succinylcholine and faster than those of the others. So why administer AV430A at a dosage higher than 0.4–0.5 mg/kg? Onset of block after AV430A does not get any faster at dosages higher than this and is probably circulation limited, as pointed out by Caldwell.⁴ The onset is fast in all species—dogs, cats, monkeys, and humans.^{1–3} Consequently, Geldner and Blobner, who believe that “GW280430A may be an ultrashort-acting rather than a rapid-onset muscle relaxant” are most likely incorrect. AV430A is clearly ultrashort and very rapid in onset in all studies.^{1–3} figure 1

shows a mechanomyograph recording of the response to AV430A (0.4 mg/kg) in the adductor pollicis in a healthy human volunteer during nitrous oxide–oxygen–fentanyl–propofol anesthesia. The pattern of block seen in figure 1 was noted in every volunteer subject of the more than 100 humans treated so far. The dose of 0.4 mg/kg is approximately $3 \times \text{ED}_{95}$.⁷

Doses up to $5 \times \text{ED}_{95}$ caused minimal side effects.⁷ A 5-s bolus dose of AV430A (0.4 mg/kg) was given at the arrow. Two control train-of-four (TOF) responses are followed by the elicited twitch in the thumb at 0.15 Hz. Twitch is abolished within approximately 80 s. Recovery begins at approximately +6 min (time scale at top). The time scale changes at and after this point. At +8 min, TOF shows appearance of T_4 , and T_1 is at approximately 25% of control. At +10 min, TOF is 45% and T_1 is 75% of control. At +12 min, TOF is 85% and T_1 is 95% of control. At +13.5 min, TOF is 95% of control (control TOF is at the far left). The time from 5% T_1 to a TOF of 90% is 6 min. Heart rate (upper record) and blood pressure (lower record) show no change.

Time and experience will tell, as clinical studies in patients are undertaken, whether early data from volunteers accurately predict the performance of AV430A in practice. The dosage recommended to achieve certain clinical endpoints, *e.g.*, intubation of the trachea within 60 s, among others, must be defined by these future studies.

In volunteer studies thus far, at dosages as high as 0.8–0.9 mg/kg (approximately $6 \times \text{ED}_{95}$ or $2 \times$ intubating dosage) where AV430A is given as a rapid (5 s) bolus, the manifestations of histamine release after AV430A are rather mild (facial flushing and brief decrease in blood pressure, not requiring treatment).⁷ There has been no bronchospasm. This suggests that clinicians could give these very large dosages safely, particularly by injecting them a little more slowly (such as over 15 s). The side effect of histamine release as caused by AV430A, because it is four times weaker than it is in mivacurium,¹ may constitute a minor concern in future clinical practice. Time again will tell. Only after a couple of years of experience in thousands of administrations will the pattern be fully defined.

Nevertheless, we can be reassured by this data. If, as Kopman *et al.*¹² have suggested, a dose of 2.0 or $2.5 \times \text{ED}_{95}$ of AV430A is enough for good to excellent intubating conditions within 60 s (this dose would be in the range 0.3 ± 0.05 mg/kg), there may very well be minimal side effects.

The chemical pathways of inactivation of AV430A are, in my opinion, its most promising feature. The chemical breakdown will ensure no prolonged neuromuscular blockade. Problems with atypical pseudocholinesterase will not be an issue. Cysteine, given intravenously as a “reversal drug” or “rescue agent,” will rapidly inactivate AV430A. Complete recovery from 100% twitch inhibition can be induced in monkeys with exogenous cysteine within 1–2 min.¹³ In the future, anesthesiologists may have the choice of spontaneous recovery (12–14 min) from AV430A *via* endogenous cysteine or induced recovery by giving additional cysteine, *e.g.*, in case of an airway emergency.

Cysteine, given within 2–3 min after injection of AV430A, should abolish complete paralysis within 1–2 min.¹⁵ The latter treatment with cysteine may shorten the total duration of action in humans to an estimated 5 min to return of full neuromuscular function such as cough, normal vital capacity, and head lift.

John J. Savarese, M.D., Weill Medical College of Cornell University/New York Presbyterian Hospital, New York, New York. jjsavare@med.cornell.edu

References

- Savarese John J, Belmont MR, Hashim MA, Mook RA Jr, Boros EE, Samano V, Patel SS, Feldman PL, Schultz JI, McNulty M, Spitzer T, Cohn DL, Morgan P, Wastila WB: Preclinical pharmacology of GW280430A (AV430A) in the rhesus monkey and in the cat. *ANESTHESIOLOGY* 2004; 100:835–45
- Belmont MR, Lien CA, Tjan J, Bradley E, Stein B, Patel SS, Savarese JJ: Clinical pharmacology of GW280430A in humans. *ANESTHESIOLOGY* 2004; 100:768–73
- Heerdt PM, Kang R, The' A, Hashimi MA, Mook RA Jr, Savarese JJ: Cardiopulmonary effects of the novel neuromuscular blocking drug GW 280430A (AV430A) in dogs. *ANESTHESIOLOGY* 2004; 100:846–51
- Caldwell JE: The continuing research for a succinylcholine replacement. *ANESTHESIOLOGY* 2004; 100:763–4
- Boros EE, Bigham EC, Boswell GE, Mook RA Jr, Patel SS, Savarese JJ, Ray JA, Thompson JB, Hashim MA, Wisowaty JC, Feldman PL, Samano V: Bis- and mixed-tetrahydroisoquinolinium chlorofumarates: New ultra-short acting nondepolarizing neuromuscular blockers. *J Med Chem* 1999; 42:206–9
- Boros EE, Samano V, Ray JA, Thompson JB, Jung DK, Kaldor I, Koble CS, Martin MT, Styles VL, Mook RA Jr, Feldman PL, Savarese JJ, Belmont MR, Bigham ED, Boswell GE, Hashim MA, Patel SS, Wisowaty JC, Bowers GD, Mosely CL, Walsh JS, Reese MJ, Rutkowske RD, Seffler AM, Spitzer TD: Neuromuscular blocking activity and therapeutic potential of mixed-tetrahydroisoquinolinium halofumarates and halosuccinates in rhesus monkeys. *J Med Chem* 2003; 46:2502–15
- Belmont MR, Tjan J, Lien CA, Patel SS: The preliminary cardiovascular profile of AV430A in humans (abstract). *ANESTHESIOLOGY* 2004; 101:A1145
- Belmont MR, Lien CA, Tjan J, Patel SS: Preliminary pharmacokinetic profile of AV430A in humans (abstract). *ANESTHESIOLOGY* 2004; 101:A1146
- Jooste E, Zhang Y, Emala CW: Rapacuronium preferentially antagonizes the function of M2 versus M3 muscarinic receptors in guinea pig airway smooth muscle. *ANESTHESIOLOGY* 2005; 102:117–24
- Jooste E, Klaffer F, Hirshman CA, Emala CW: A mechanism for rapacuronium-induced bronchospasm: M2 muscarinic receptor antagonism. *ANESTHESIOLOGY* 2003; 98:906–11
- Savarese JJ, Ali HH, Basta SJ, Scott RPF, Embree PB, Wastila WB, Abou-Donia MM, Gelb C: The cardiovascular effects of mivacurium chloride (BW B1090U) in patients receiving nitrous oxide-opiate-barbiturate anesthesia. *ANESTHESIOLOGY* 1989; 70:386–94
- Kopman AF, Klewicka MM, Neuman GG: Reexamined: The recommended "intubating dose" for nondepolarizing blockers of rapid-onset. *Anesth Analg* 2001; 93:954–9
- Belmont MR, Horochiwsky Z, Eliazio RF, Savarese JJ: Reversal of AV430A with cysteine in rhesus monkeys (abstract). *ANESTHESIOLOGY* 2004; 101:A1180

(Accepted for publication November 17, 2004.)

Anesthesiology 2005; 102:865

© 2005 American Society of Anesthesiologists, Inc. Lippincott Williams & Wilkins, Inc.

The Right Thing in the Right Place: Lumbar Plexus Block in Children

To the Editor:—I read with interest the article "Lumbar Plexus in Children" by Lukas Kirchmair *et al.*¹ published in the August 2004 issue of *ANESTHESIOLOGY*. The authors have nicely shown that sonography of the lumbar plexus in children is feasible, they have clarified the anatomical understanding, and they have given additional information on the depth of the lumbar plexus in pediatric patients.

In addition, they applied their technique to five children scheduled to undergo inguinal hernia repair and concluded that all lumbar plexus blocks provided effective anesthesia and analgesia of the inguinal region during surgery and for postoperative pain relief. Although I am unable to check the clinical effects in these five individual patients, I have considerable doubt that lumbar plexus block is a suitable anesthetic technique for inguinal hernia repair and would not recommend it for the following reasons:

First, the iliohypogastric nerve arises from the roots T12 and L1, and the ilioinguinal nerve arises from L1. These two nerves are usually not densely blocked by injections made at an L4–L5 level. Even the genitofemoral nerve, arising from L1 and L2, is often missed.

Second, a successful lumbar plexus block is followed by a profound motor blockade of all knee extensor and most hip adductor muscles. This is clearly an undesirable side effect after inguinal hernia repair. Avoiding this by using a small volume and a low concentration of the

local anesthetic does not seem to be a valuable strategy, especially when nerves far away from the injection site must be blocked.

Third, clinically, in awake adolescents, using the posterior lumbar plexus block with an injection at the L4–L5 level in combination with a sciatic nerve block, incisions coming high up, close to the inguinal ligament, are often troublesome. The ilioinguinal and genitofemoral nerves are often not sufficiently blocked.

In summary, lumbar plexus block can be used in children. However, its use should be restricted to indications where this technique is clearly effective, *e.g.*, for lower limb procedures involving parts of the hip or extensive knee surgery, and where no other less invasive alternative exists.

Martin Jöhr, M.D., Kantonsspital, Luzern, Switzerland. joehrmartin@bluewin.ch

Reference

- Kirchmair L, Enna B, Mitterschiffthaler G, Moriggl B, Greher M, Marhofer P, Kapral S, Gassner I: Lumbar plexus in children: A sonographic study and its relevance to pediatric regional anesthesia. *ANESTHESIOLOGY* 2004; 101:445–50

(Accepted for publication November 30, 2004.)

Anesthesiology 2005; 102:865–6

© 2005 American Society of Anesthesiologists, Inc. Lippincott Williams & Wilkins, Inc.

In Reply:—We thank Dr. Jöhr for his comments on our article published in the August 2004 issue of *ANESTHESIOLOGY*.¹ He pointed out important anatomical features regarding lumbar plexus anatomy that might raise concerns about the indications of ultrasound-guided posterior lumbar plexus blocks in our series of pediatric patients.

The lumbar plexus is derived from the ventral rami of the roots L1–L5. The latter and its branches are arranged in a potential space within the substance of the psoas major muscle, the so-called psoas compartment. The iliohypogastric, ilioinguinal, and genitofemoral nerves are the most cranial branches and provide innervation of the

inguinal region. They arise from the ventral rami of the roots T12–L1, L1, and L1–L2, respectively. Therefore, a posterior lumbar plexus block by means of an approach at the level L4–L5 would probably result in an incomplete or missing block of these nerves, as mentioned by Dr. Jöhr.

In adults, the iliohypogastric and ilioinguinal nerves approximately exit the psoas major muscle at L1–L2,² and the genitofemoral nerve usually exits at L4.² Nevertheless, the detailed topographic anatomy and arrangement of these nerves within the psoas major muscle in children is unknown.

In the current cases, the local anesthetic solution must have reached the cranial parts of the lumbar plexus because sufficient anesthesia and analgesia of the inguinal region was observed in all five patients. Recent investigations of ultrasound-guided posterior lumbar plexus block in pediatric patients revealed a greater extent of anesthesia and analgesia compared with adults.

It was not the aim of our study to investigate posterior lumbar plexus block for inguinal hernia repair in children, and we agree with Dr. Jöhr that it should not be the first choice for this surgical procedure. However, in our opinion, it might be a useful alternative and still represents a peripheral nerve block.

Dr. Jöhr also had concerns about the strategy of applying small volumes in the current setting. Nevertheless, one of the proven benefits of ultrasound-guided techniques is the decreased need of local anesthetics³ compared with traditional approaches.

Lukas Kirchmair, M.D.,* Birgit Enna, M.D., Peter Marhofer, M.D., Stephan Kapral, M.D. * Community Hospital Hall in Tyrol, Hall in Tyrol, Austria. l.kirchmair@chello.at

References

1. Kirchmair L, Enna B, Mitterschiffthaler G, Moriggl B, Greher M, Marhofer P, Kapral S, Gassner I: Lumbar plexus in children: A sonographic study and its relevance to pediatric regional anesthesia. *ANESTHESIOLOGY*. 2004; 101:445-50
2. Pernkopf E: Atlas der topographischen und angewandten Anatomie des Menschen. Vol 2, 3rd edition. Edited by Platzer W. Munich, Vienna, Baltimore, Urban & Schwarzenberg, 1989, pp 186-7
3. Greher M, Kapral S: Is regional anesthesia simply an exercise in applied sonoanatomy? *ANESTHESIOLOGY* 2003; 99:1-2

(Accepted for publication November 30, 2004.)

Anesthesiology 2005; 102:866-8

© 2005 American Society of Anesthesiologists, Inc. Lippincott Williams & Wilkins, Inc.

Of Mice and Men: Should We Extrapolate Rodent Experimental Data to the Care of Human Neonates?

To the Editor:—Over the years, Dr. Olney *et al.*¹ have enlightened the scientific community with their research on the *N*-methyl-D-aspartate receptor and its role in human disease. Recently, Dr. Olney's group has examined the effects of commonly used anesthetics and anticonvulsants on the developing brain. In several high-profile scientific journals, they reported that the administration of these drugs, including ketamine, ethanol, phencyclidine, nitrous oxide, isoflurane, propofol, barbiturates, diazepam, and other anticonvulsants all increase apoptotic neurodegeneration in developing rat brain.²⁻⁵ We and others have replicated some of the studies with ketamine, and there is no doubt regarding the scientific validity of their findings.^{6,7}

The direct applicability of these experimental findings to the clinical practice of pediatric anesthesia and critical care, however, should be questioned. Likewise, the implication that all types of anesthetic and sedative agents may have similar potentially deleterious effects on neuronal development in neonates is premature and inappropriate. Multiple lines of evidence cast doubt on the clinical relevance of these experimental paradigms, as recently reviewed in our Special Article published in the August 2004 issue of *ANESTHESIOLOGY*.⁸ Dr. Olney *et al.*⁹ eloquently provided a counterpoint editorial in the same issue of *ANESTHESIOLOGY*, which mainly questioned our assertion that repeated large doses of ketamine were responsible for mediating the neurodegenerative changes noted in neonatal rat brains. Similar doses and durations of administration, particularly in the absence of surgical stimulation, are never used in pediatric anesthesia.

Recent data from the Neurotoxicology division at the National Center for Toxicological Research (Jefferson, Arkansas) further confirm our findings that the single- or smaller-dose regimens of ketamine do not increase neuronal apoptosis in the brains of 7-day-old (P7) rat pups.⁷ Scallet *et al.*⁷ examined the effect of various dosing regimens on the different assays for neuroapoptosis in P7 rat pup brains. They reported no differences in the appearance of apoptotic neurons in rat pups receiving saline, seven doses of ketamine (10 mg/kg) over 9 h, and a single dose of ketamine (20 mg/kg), whereas rat pups receiving higher doses, seven doses of ketamine (20 mg/kg) over 9 h, had significant increases in neuronal apoptosis. Scallet *et al.* found that the magnitude and pattern of neuronal changes were similar to those reported earlier.^{2,6} Unlike Olney *et al.*, these investigators also measured blood concentrations of ketamine to show that the repeated low-dose (10 mg/kg) and single-dose regimens resulted in the blood concentrations achieved in clinical practice, whereas the repeated high-dose regimen (20 mg/kg) resulted in sevenfold higher ketamine concentrations. Furthermore, Scallet *et al.* verified the presence of neurodegeneration with several histochemical methods, including cu-

pric silver and Fluoro-Jade-B staining for nonspecific neurodegeneration, 4',6-diamido-2-phenylindole for nuclear DNA, and caspase-3 immunohistochemistry as a marker for neuronal apoptosis. These findings confirmed that ketamine doses and duration both play important roles in ketamine-induced neurodegeneration.^{2,6,7}

In their editorial, Olney *et al.*⁹ disagree with our concern that neurodegenerative changes after repeated high doses of ketamine may result from hypoxic/ischemic damage because of the hemodynamic effects of high-dose ketamine. "It is excitotoxic, and ultrastructurally does not resemble apoptosis," they state. The neuronal cell death that occurs soon after exposure to hypoxia/ischemia does result from excitotoxicity, but rat brains were not sampled at this time period in the studies by Olney *et al.*^{2,4} A voluminous literature shows a delayed neuronal cell death after hypoxia/ischemia that results from neuronal apoptosis in the immature rat brain and also occurs at the same time periods (4-24 h) as those sampled by Olney *et al.*¹⁰⁻¹³ Excitotoxicity cannot account for hypoxia-induced injury in immature neurons but may explain the effects of hypoxia on more mature neurons,¹⁴ and even the excitotoxic damage of immature neurons leads to apoptosis at 6-24 h,¹⁵ at the time periods studied by Olney *et al.*^{2,4}

In their editorial, Olney *et al.*⁹ state that arterial blood gases showed oxygen saturations of 97-99% (contained in the legend for their fig. 2). To our knowledge, the complete data from arterial blood gases obtained at 0, 15, 30, 60, 120, 180, or 240 min in neonatal rats given high-dose ketamine have not been reported in the literature and cannot guarantee the absence of significant hypoxia occurring between these sampling times. In contrast, pediatric anesthesiologists routinely and continuously monitor oxygenation (oximetry), ventilation (capnography), and other hemodynamic variables during neonatal anesthesia and respond to these monitors within seconds after noting a clinically important change.

Similarly, our concern for nutritional deprivation was also dismissed by Olney *et al.*⁹ because of the lack of "a robust pattern of neuroapoptosis" in the controls from their experiments, stating that "all animals are sacrificed 4 to 8 h later for histologic evaluation of the brains." Their experiments, however, showed that rat pups were killed at 4, 8, 12, 16, 24, or 48 h after ketamine and that apoptosis was most prominent in the brains sampled at 12, 16, and 24 h.² If newborn rat pups were exposed to nutritional deprivation for these periods of time, increasing patterns of neuronal apoptosis would be expected.^{16,17}

Last, we must restate our concern that neonatal rats or humans exposed to anesthetic agents in the presence *versus* the absence of surgically induced pain or stress would manifest drastically different effects and that the observations that the neuronal effects of all anes-

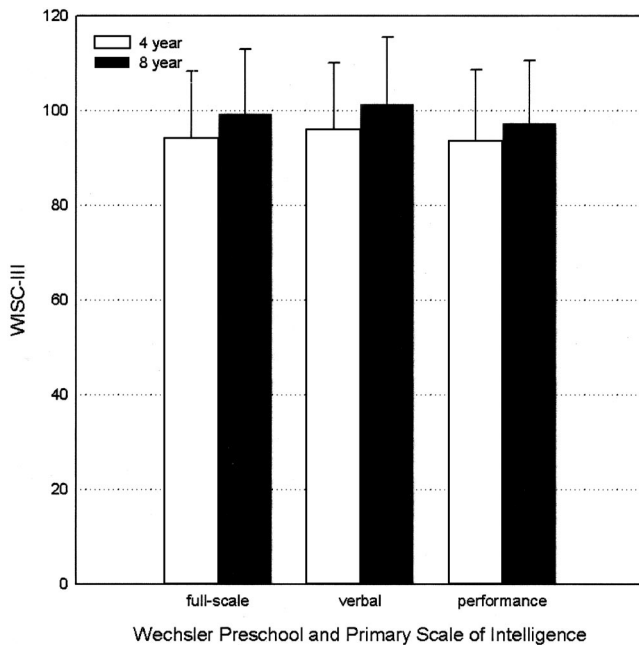


Fig. 1. Wechsler Preschool and Primary Scale of Intelligence score measures at 4 and 8 yr after surgical repair of complex congenital heart defects. Population norms are 100 ± 10 . There were no significant differences between the study groups and the population norms. Data compiled from Bellinger *et al.*^{21,22} and de Ferranti *et al.*²³ WISC-III = Wechsler Intelligence Scale for Children-III.

thetic agents and ketamine in particular are dose dependent.⁸ At the Society for Neuroscience annual meeting on November 8–12, 2003 (New Orleans, Louisiana), Olney *et al.* reported that a single sedating dose of ketamine increases neurodegeneration, but this finding was noted from neonatal mice, highlighting the importance of species-dependent variations in the response to pharmacologic agents.^{18,19}

We agree with Drs. Olney and Todd that human clinical studies are needed to truly examine the potential neurotoxic effect of anesthetic drugs in the developing human brain.^{9,19,20} Given the ethical and societal constraints, randomized controlled trials mirroring the experimental designs used in rodent models are not possible. We examined children at 4 and 8 yr after the surgical repair of congenital heart defects as neonates using a standardized anesthetic regimen including high-dose barbiturates and opiates.^{21–23} Despite the known neurologic sequelae of cardiopulmonary bypass and deep hypothermic circulatory arrest,²⁴ their performance IQ scores were not significantly different from the population norms (fig. 1). Certainly their neurologic outcome was no worse than that of peer groups with similar congenital heart defects repaired later in life and exposed to anesthetic agents after the “vulnerable” neonatal and infant periods of brain development at issue in the study of Newburger *et al.*²⁵ The longer operative repair (and anesthetic exposure) was postponed after infancy in this study population, the greater the cognitive impairment was. These findings suggest that even under extreme conditions encountered in the conduct of pediatric anesthesia, neonatal exposure to anesthetic agents does not necessarily confer substantial neurologic deficits and is, at worst, only one factor among many potentially influencing brain development.

Regardless of this interpretation of such data, the controversy initiated by the studies of Olney and others should provoke clinical investigators to examine the long-term neurocognitive effects of prolonged exposure to anesthetic drugs in pediatric patients, to help sort out the differences between mice and men. Further knowledge in these areas is required before changes in clinical practices in neonatal and pediatric anesthesia can be recommended; such changes may not be

necessary or may even be deleterious to long-term neurologic outcome. We are all indebted to Olney *et al.* for their contribution in raising these issues.

Sulpicio G. Soriano, M.D.,* Kanwaljeet J. S. Anand, M.B.B.S., D.Phil., Cynthia R. Rovnaghi, M.S., Paul R. Hickey, M.D.
* Children’s Hospital Boston and Harvard Medical School, Boston, Massachusetts. sulpicio.soriano@childrens.harvard.edu

References

1. Olney JW, Labruyere J, Wang G, Wozniak DF, Price MT, Sesma MA: NMDA antagonist neurotoxicity: Mechanism and prevention. *Science* 1991; 254:1515–8
2. Ikonomidou C, Bosch F, Miksa M, Bittigau P, Voekler J, Dikranian K, Tenkova TI, Stefovskva V, Turski L, Olney JW: Blockade of NMDA receptors and apoptotic neurodegeneration in the developing brain. *Science* 1999; 283:70–4
3. Ikonomidou C, Bittigau P, Ishimaru MJ, Wozniak DF, Koch C, Genz K, Price MT, Stefovskva V, Horster F, Tenkova T, Dikranian K, Olney JW: Ethanol-induced apoptotic neurodegeneration and fetal alcohol syndrome. *Science* 2000; 287:1056–60
4. Jevtovic-Todorovic V, Hartman RE, Izumi Y, Benshoff ND, Dikranian K, Zorumski CF, Olney JW, Wozniak DF: Early exposure to common anesthetic agents causes widespread neurodegeneration in the developing rat brain and persistent learning deficits. *J Neurosci* 2003; 23:876–82
5. Bittigau P, Sifringer M, Genz K, Reith E, Pospischil D, Govindarajulu S, Dziecko M, Pesditschek S, Mai I, Dikranian K, Olney JW, Ikonomidou C: Antiepileptic drugs and apoptotic neurodegeneration in the developing brain. *Proc Natl Acad Sci U S A* 2002; 99:15089–94
6. Hayashi H, Dikkes P, Soriano SG: Repeated administration of ketamine may lead to neuronal degeneration in the developing rat brain. *Paediatr Anaesth* 2002; 12:770–4
7. Scallet AC, Schmued LC, Slikker W Jr, Grunberg N, Faustino PJ, Davis H, Lester D, Pine PS, Sistare F, Hanig JP: Developmental neurotoxicity of ketamine: Morphometric confirmation, exposure parameters, and multiple fluorescent labeling of apoptotic neurons. *Toxicol Sci* 2004; 81:364–70
8. Anand KJS, Soriano SG: Anesthetic agents and the immature brain: Are these toxic or therapeutic agents? *ANESTHESIOLOGY* 2004; 101:527–30
9. Olney JW, Young C, Wozniak DF, Ikonomidou C, Jevtovic-Todorovic V: Anesthesia-induced developmental neuroapoptosis: Does it happen in humans? *ANESTHESIOLOGY* 2004; 101:530–3
10. Beilharz EJ, Williams CE, Dragunow M, Sirimanne ES, Gluckman PD: Mechanisms of delayed cell death following hypoxic-ischemic injury in the immature rat: Evidence for apoptosis during selective neuronal loss. *Brain Res Mol Brain Res* 1995; 29:1–14
11. Benjelloun N, Joly LM, Palmier B, Plotkine M, Charriat-Marlangue C: Apoptotic mitochondrial pathway in neurones and astrocytes after neonatal hypoxia-ischaemia in the rat brain. *Neuropathol Appl Neurobiol* 2003; 29:350–60
12. Turkyilmaz C, Turkyilmaz Z, Atalay Y, Soylemezoglu F, Celasun B: Magnesium pre-treatment reduces neuronal apoptosis in newborn rats in hypoxia-ischemia. *Brain Res* 2002; 955:133–7
13. Zhu C, Qiu L, Wang X, Hallin U, Cande C, Kroemer G, Hagberg H, Blomgren K: Involvement of apoptosis-inducing factor in neuronal death after hypoxia-ischemia in the neonatal rat brain. *J Neurochem* 2003; 86:306–17
14. Chihab R, Bossenmeyer C, Oillet J, Daval JL: Lack of correlation between the effects of transient exposure to glutamate and those of hypoxia/reoxygenation in immature neurons in vitro. *J Neurochem* 1998; 71:1177–86
15. Lok J, Martin LJ: Rapid subcellular redistribution of Bax precedes caspase-3 and endonuclease activation during excitotoxic neuronal apoptosis in rat brain. *J Neurotrauma* 2002; 19:815–28
16. Ferrand-Drake M, Zhu C, Gido G, Hansen AJ, Karlsson JO, Bahr A, Zamzani N, Kroemer G, Chan PH, Wieloch T, Blomgren K: Cyclosporin A prevents calpain activation despite increased intracellular calcium concentrations, as well as translocation of apoptosis-inducing factor, cytochrome c and caspase-3 activation in neurons exposed to transient hypoglycemia. *J Neurochem* 2003; 85:1431–42
17. Tkacs NC, Dunn-Meynell AA, Levin BE: Presumed apoptosis and reduced arcuate nucleus neuropeptide Y and pro-opiomelanocortin mRNA in non-coma hypoglycemia. *Diabetes* 2000; 49:820–6
18. Berde C, Cairns B: Developmental pharmacology across species: Promise and problems. *Anesth Analg* 2000; 91:1–5
19. Haberny KA, Paule MG, Scallet AC, Sistare F, Lester DS, Hanig JP, Slikker W Jr: Ontogeny of the N-methyl-D-aspartate (NMDA) receptor system and susceptibility to neurotoxicity. *Toxicol Sci* 2002; 68:9–17
20. Todd MM: Anesthetic neurotoxicity: The collision between laboratory neuroscience and clinical medicine. *ANESTHESIOLOGY* 2004; 101:533–4
21. Bellinger DC, Wypij D, Kuban KC, Rappaport LA, Hickey PR, Wernovsky G, Jonas RA, Newburger JW: Developmental and neurological status of children at 4 years of age after heart surgery with hypothermic circulatory arrest or low-flow cardiopulmonary bypass. *Circulation* 1999; 100:526–32
22. Bellinger DC, Wypij D, duDupleiss AJ, Rappaport LA, Jonas RA, Wernovsky G, Newburger JW: Neurodevelopmental status at eight years in children

with dextro-transposition of the great arteries: The Boston Circulatory Arrest Trial. *J Thorac Cardiovasc Surg* 2003; 126:1385-96

23. de Ferranti S, Gauvreau K, Hickey PR, Jonas RA, Wypij D, du PA, Bellinger DC, Kuban K, Newburger JW, Laussen PC: Intraoperative hyperglycemia during infant cardiac surgery is not associated with adverse neurodevelopmental outcomes at 1, 4, and 8 years. *ANESTHESIOLOGY* 2004; 100:1345-52

24. du Plessis AJ, Bellinger DC, Gauvreau K, Plumb C, Newburger JW, Jonas

RA, Wessel DL: Neurologic outcome of choreoathetoid encephalopathy after cardiac surgery. *Pediatr Neurol* 2002; 27:9-17

25. Newburger JW, Silbert AR, Buckley LP, Fyler DC: Cognitive function and age at repair of transposition of the great arteries in children. *N Engl J Med* 1984; 310:1495-9

(Accepted for publication November 30, 2004.)

Anesthesiology 2005; 102:868-9

© 2005 American Society of Anesthesiologists, Inc. Lippincott Williams & Wilkins, Inc.

In Reply:—In their letter to the editor, Soriano *et al.* state that in our recent counterpoint editorial,¹ we “mainly questioned [their] assertion that repeated large doses of ketamine were responsible for mediating the neurodegenerative changes noted in neonatal rat brains.” This is not what we questioned; we know that repeated large doses of ketamine can cause extensive neuroapoptosis. What we mainly questioned was whether repeated large doses are necessary, or whether neuroapoptosis can be triggered by a single low dose of ketamine. We then presented evidence that a single subcutaneous dose of ketamine (20, 30, or 40 mg/kg)—one that does not fully immobilize, anesthetize, or abolish pain responses in infant mice—does trigger a significant increase in the rate of neuroapoptosis. The scientifically appropriate response would be for Soriano *et al.* to administer these single subanesthetic doses of ketamine to infant mice and, using the same methods we used, to see whether they could reproduce our findings. Instead, Soriano *et al.* imply that it requires “repeated large doses” to trigger neuroapoptosis and argue that ketamine is safe for pediatric anesthesia because such large “doses and durations . . . are never used in pediatric anesthesia.”

To bolster their claim that a single dose is ineffective, they cite a recent report of Scallet *et al.*² in which a single dose of ketamine at 20 mg/kg did not trigger apoptosis in infant rats, although repeated 20-mg/kg doses did. Because, in our single-dose experiments, 20 mg/kg was the threshold dose for triggering apoptosis, it is not surprising or very meaningful that one laboratory would report a barely significant effect and another would report a barely insignificant effect at this dose. What is surprising is that instead of directly acknowledging and discussing the implications of our finding that a single dose of ketamine at 20, 30, or 40 mg/kg does trigger apoptosis in a dose-dependent manner, Soriano *et al.* continue to promote their original position that ketamine is safe because, in their hands, a single dose as high as 75 mg/kg does not trigger neuroapoptosis. It is difficult to reconcile this position with their introductory statement that “there is no doubt regarding the scientific validity” of our findings.

Soriano *et al.* suggest that we should have measured blood ketamine concentrations in our mouse experiments. However, Soriano *et al.* did not measure ketamine blood concentrations in their rodent experiments, and anesthesiologists do not routinely measure, much less rely on, ketamine blood concentrations to determine depth of anesthesia. We reported that a single dose of ketamine, in the range of 20–40 mg/kg, that does not fully immobilize, anesthetize, or render an infant mouse insentient to pain does trigger neuroapoptosis in the infant mouse brain. This is a message that is not difficult to understand. Presumably, we can all agree that regardless of ketamine blood concentrations, it would be unacceptable to perform surgery on an infant mouse, or infant human, whose depth of anesthesia is such that the infant is squirming around, flailing the extremities, and responding to skin pinch by vigorous antalgic movements.

Soriano *et al.* continue to argue that the neuroapoptosis response to anesthetic drugs is due to hypoxia/ischemia. How is this possible in light of our demonstration¹ that arterial oxygen saturation remains in the 97–99% range over a 4-h period after a dose of ketamine that triggers neuroapoptosis within this same time interval? Soriano *et al.* postulate that the oxygen saturation fleetingly decreased to brain-damaging levels during intervals between our sampling time points but abruptly resumed normal levels at each time point (15, 30, 60, 120, 180, 240 min) just before we drew blood. We doubt that the readership of *ANESTHESIOLOGY* will be persuaded by this argument, especially

because we are talking about a subanesthetic dose of ketamine, a drug that reputedly, even at anesthetic doses, does not compromise cardiorespiratory function.

Even if severe hypoxia/ischemia did occur, it could not account for the neuroapoptosis response to ketamine because 4–6 h after ketamine administration, an increase in apoptotic profiles is evident both as a caspase-3 activation response and as ultrastructurally confirmed apoptotic morphology. However, when one intentionally induces hypoxia/ischemia and examines the developing brain 4–6 h later, there is no increase in apoptotic profiles, either by caspase-3 activation or ultrastructural criteria. It is illogical to argue that anesthesia-induced apoptosis is caused by hypoxia/ischemia if one cannot demonstrate that intentionally induced hypoxia/ischemia reproduces the anesthesia-induced apoptosis phenomenon. What one does find in the brain 4–6 h after hypoxia/ischemia, as we have demonstrated previously,³ and also very recently,⁴ is excitotoxic neurodegeneration. (See Young *et al.*⁴ for a detailed presentation of evidence directly addressing and clarifying this issue.) Soriano *et al.* challenge our position by citing works from other laboratories that they believe contradict our observations. We have examined the cited works, some of which are *in vitro* studies, and find that these works either support our position or are irrelevant to the issue in contention. We stand by our own observations, which are based on a three-decade-long direct investigation of the specific issue in contention: *in vivo* excitotoxic versus apoptotic neurodegeneration in the developing brain.^{3–10}

Regarding the nutritional deprivation issue, we stated¹ that in a “typical” experiment, we expose infant rodents to a single dose of saline or an apoptogenic anesthetic drug and, without returning the pups to the maternal nest, kill them 4–8 h later. Because both the control and experimental pups are exposed to the same degree of maternal/nutritional deprivation during this 4- to 8-h period, nutritional deprivation cannot explain the higher rate of neuroapoptosis in the experimental pups. In an apparent effort to refute this interpretation, Soriano *et al.* note that in one study we killed animals not only at 4 and 8 h but also at 12, 16, 24, and 48 h, and determined, using a staining procedure that detects cumulative neuronal degeneration, that apoptosis became increasingly more prominent at 12, 16, and 24 h. We do not understand how this reference to our earlier comprehensive evaluation of the apoptotic response to large doses of MK801¹¹ refutes our current interpretations pertaining to “typical” experiments focusing on the very early response to low subanesthetic doses of ketamine.

Soriano *et al.* point out that our most recent findings¹ pertaining to threshold conditions for inducing developmental neuroapoptosis were conducted in mice and suggest that species differences between rats and mice and between rodents and humans may be of paramount importance. We have tested rats and mice and find no appreciable differences between these species, but we agree that differences between rodents and primates may be very important. Of course, species differences can go in either direction—humans may be less vulnerable or they may be more vulnerable than rodents.

Soriano *et al.* conclude that only human studies can provide the final answer. We do not contest the importance of human experiments, but such experiments will require many years to complete and, because of design limitations, may provide equivocal results that defy interpretation. Therefore, we recommend that the issue be addressed in nonhuman primate studies designed to test the sensitivity of the primate brain to anesthesia-induced developmental neuroapoptosis. If the pri-

mate brain proves sensitive, additional studies designed to evaluate the neurobehavioral consequences of graded degrees and controlled patterns of apoptotic neurodegeneration in the developing nonhuman primate brain would be informative. Such studies would provide the anesthesiology community with reliable information and guidance in the conduct of much-needed human studies.

John W. Olney, M.D.,* Chainllie Young, M.D., Ph.D., David F. Wozniak, Ph.D., Chrysanthy Ikonomidou, M.D., Ph.D., Vesna Jevtovic-Todorovic, M.D., Ph.D. * Washington University School of Medicine, St. Louis, Missouri. olneyj@wustl.edu

References

1. Olney JW, Young C, Wozniak DF, Ikonomidou C, Jevtovic-Todorovic V: Anesthesia-induced developmental neuroapoptosis: Does it happen in humans? *ANESTHESIOLOGY* 2004; 101:273-5
2. Scallet AC, Schmued LC, Slikker W Jr, Grunberg N, Faustino PJ, Davis H, Lester P, Pine PS, Sistare F, Hanig JP: Developmental neurotoxicity of ketamine: morphometric confirmation, exposure parameters, and multiple fluorescent labeling of apoptotic neurons. *Toxicol Sci* 2004; 81:364-70
3. Ikonomidou C, Price MT, Mosinger JL, Friedrich G, Labruyere J, Shahid Salles K, Olney JW: Hypobaric-ischemic conditions produce glutamate-like cytopathology in infant rat brain. *J Neurosci* 1989; 9:1693-700

4. Young C, Tenkova T, Dikranian K, Labruyere J, Olney JW: Excitotoxic versus apoptotic mechanisms of neuronal cell death in perinatal hypoxia/ischemia. *Curr Molecular Med* 2004; 4:73-81

5. Olney JW: Glutamate-induced retinal degeneration in neonatal mice: Electron microscopy of the acutely evolving lesion. *J Neuropathol Exp Neurol* 1969; 28:455-74

6. Olney JW: Glutamate-induced neuronal necrosis in the infant mouse hypothalamus: An electron microscopic study. *J Neuropathol Exp Neurol* 1971; 30:75-90

7. Olney JW, Ho OL, Rhee V: Cytotoxic effects of acidic and sulphur-containing amino acids on the infant mouse central nervous system. *Exp Brain Res* 1971; 14:61-76

8. Olney JW, Sharpe LG, Feigin RD: Glutamate-induced brain damage in infant primates. *J Neuropathol Exp Neurol* 1972; 31:464-88

9. Ishimaru MJ, Ikonomidou C, Tenkova TI, Der TC, Dikranian K, Sesma MA, Olney JW: Distinguishing excitotoxic from apoptotic neurodegeneration in the developing rat brain. *J Comp Neurol* 1999; 408:461-76

10. Dikranian K, Ishimaru MJ, Tenkova T, Labruyere J, Qin YQ, Ikonomidou C, Olney JW: Apoptosis in the in vivo mammalian forebrain. *Neurobiol Dis* 2001; 8:359-79

11. Ikonomidou C, Bosch F, Miksa M, Bittigau P, Vöckler J, Dikranian K, Tenkova T, Stevoska V, Turski L, Olney JW: Blockade of NMDA receptors and apoptotic neurodegeneration in the developing brain. *Science* 1999; 283:70-4

(Accepted for publication November 30, 2004.)

Anesthesiology 2005; 102:869

© 2005 American Society of Anesthesiologists, Inc. Lippincott Williams & Wilkins, Inc.

Avoid Excessive Sedation during Cervical Injections

To the Editor:—I read with interest the article by Rathmell *et al.*¹ regarding cervical transforaminal injection of steroids. An important safety issue not addressed was the need to minimize complications by avoiding excessive sedation. Hodges *et al.*² reported two cases of nerve injury after cervical epidural steroid injections, both performed in heavily sedated patients using fluoroscopy. Excessive sedation may result in the inability of the patient to experience and report pain and paresthesias at the time of spinal cord or nerve root contact. In addition, some recommend that cervical injections should only be performed by experienced and well-trained practitioners.³

Richard B. Weiskopf, M.D., served as Handling Editor for this letter, the following letter by Willis and Martin, and the reply by Rathmell *et al.*

Anesthesiology 2005; 102:869

© 2005 American Society of Anesthesiologists, Inc. Lippincott Williams & Wilkins, Inc.

A Safer and More Effective Intervention for Radiculopathic Pain

To the Editor:—We thank Dr. Rathmell *et al.* for emphasizing the potential hazards of transforaminal injections.¹ It is clear that these injections should be performed by individuals who are fully trained in advanced imaging and interventional techniques. Moreover, the practitioner must be capable of managing any adverse sequelae.

Although the treatment of radiculopathic pain with the local injection of corticosteroid is appreciated, we believe that the best treatment of radiculopathic pain is by the application of pulsed radiofrequency current to the involved dorsal root ganglion. In our extensive experience with pulsed radiofrequency, we have found the results of treatment to be superior to those of conventional corticosteroid injections in both effectiveness and duration.^{2,3} Furthermore, pulsed radiofrequency application exposes patients to less risk for the following reasons: (1) Cannula placement can be performed based solely on osseous anatomy and electrophysiologic stimulation results. Therefore, no injection of any material is requisite. (2) The patient is exposed to no systemic sequelae of medication or radiocontrast administration. (3) Unlike injection therapies, pulsed radiofrequency can be repeated as indicated, without fear of accumulating medicinal toxicity.

Noor M. Gajraj, M.D., F.R.C.A., U.T. Southwestern Medical Center, Dallas, Texas. noorgajraj@aol.com

References

1. Rathmell J, Aprill C, Bogduk N: Cervical transforaminal injection of steroids. *ANESTHESIOLOGY* 2004; 100:1595-600
2. Hodges S, Castleberg R, Miller T, Ward R, Thornburg C: Cervical epidural steroid injection with intrinsic spinal cord damage: Two case reports. *Spine* 1998; 23:2137-42
3. De Cordoba J, Bernal J: Cervical transforaminal blocks should not be attempted by anyone without extensive documented experience in fluoroscopically guided injections. *ANESTHESIOLOGY* 2004; 100:1323-4

(Accepted for publication December 20, 2004.)

The only potential disadvantage to the use of pulsed radiofrequency *versus* injection therapy is the requirement of a larger cannula (20-22 vs. 26 gauge) that could cause more tissue trauma. Regardless, the take-home message is well elucidated by the authors. Spinal interventional techniques should only be performed by practitioners who have demonstrated expertise in neuraxial imaging for interventional treatment modalities.

Mark L. Willis, M.D., Dan C. Martin, M.D.* Medical College of Georgia, Augusta, Georgia. damartin@mail.mcg.edu

References

1. Rathmell JP, Aprill C, Bogduk N: Cervical transforaminal injection of steroids. *ANESTHESIOLOGY* 2004; 100:1595-600
2. Sluijter ME, Cosman ER, Rittman WB, Van Kleef M: The effects of pulsed radiofrequency fields applied to dorsal root ganglion: A preliminary report. *Pain Clin* 1998; 2:109-17
3. Mikeladze G, Espinal R, Finnegan R, Routon J, Martin D: Pulsed radiofrequency application in treatment of chronic zygapophyseal joint pain. *Spine J* 2003; 3:360-2

(Accepted for publication December 20, 2004.)

Anesthesiology 2005; 102:870

© 2005 American Society of Anesthesiologists, Inc. Lippincott Williams & Wilkins, Inc.

In Reply:—Critical to the safety of cervical transforaminal injection of steroids is an understanding of the anatomy of the cervical intervertebral foramina and their contents, coupled with disciplined and accurate imaging. We thank both Dr. Gajraj and Drs. Willis and Martin for emphasizing that cervical transforaminal injection should be performed by experienced and well-trained practitioners. Indeed, the radiographic anatomy of the cervical spine is difficult to master. We have all watched talented physicians-in-training get confused by small changes in alignment on the x-ray image caused by positioning or rotation of the neck and stray dangerously off-course during needle placement. Image-guided injection in the cervical spine requires advanced and extended training under the guidance of an experienced practitioner; as we have emphasized before, this is not something that can be mastered through a weekend cadaver course.¹

Even with the best technique in skilled hands, minimal changes in needle direction and depth can lead the tip into contact with neural structures. After the needle is in proper position, the volume of the injectate itself can cause painful neural compression. We have emphasized the need to maintain an awake and responsive patient when performing cervical epidural steroid injection *via* a translaminar route as the only safe means to avoid injury,² and we thank Dr. Gajraj for raising this point because it is equally relevant to any type of neural blockade.

As for Drs. Willis and Martin's advocating pulsed radiofrequency treatment of the dorsal root ganglion as a superior technique for treating cervical radicular pain, we point out that there is little evidence to support their assertion. Small, randomized trials of conventional radiofrequency treatment (*i.e.*, resulting in a thermal lesion) of the dorsal root ganglion for the treatment of cervical radicular pain suggest time-limited efficacy.^{3,4} Results from similar trials in patients with lumbosacral radicular pain have been less promising: An initial large observational study suggested significant pain reduction,⁵ but a subsequent randomized trial by the same investigators showed no benefit over placebo.⁶ Pulsed radiofrequency treatment has evolved from the notion that the pain relief that ensues after radiofrequency treatment does not result from actual tissue destruction caused by conventional thermal lesions; rather, it is brought about by the large

voltage fluctuations in the area of treatment that induce long-term changes in the dorsal horn of the spinal cord.⁷ The appeal of pulsed radiofrequency treatment is immediately clear: a simple treatment that imparts long-term pain relief without tissue destruction. However, we do not have even a single randomized trial that compares the efficacy of pulsed radiofrequency to any type of control treatment or to conventional radiofrequency treatment. We hope that the evidence will soon appear to support the unbridled zeal of practitioners for this new treatment. We urge those like Drs. Willis and Martin who have extensive experience with these techniques to conduct the randomized trials we need to demonstrate the effectiveness (or lack thereof) of pulsed radiofrequency treatment.

James Rathmell, M.D.,* Charles Aprill, M.D., Nikolai Bogduk, M.D., Ph.D., D.Sc. * University of Vermont, Burlington, Vermont. james.rathmell@vtmednet.org

References

- Rathmell JP: The injectionists. *Reg Anesth Pain Med* 2004; 29:305-6
- Field J, Rathmell JP, Stephenson JH, Katz NP: Neuropathic pain following cervical epidural steroid injection. *ANESTHESIOLOGY* 2000; 93:885-8
- Slappendal R, Crul BJ, Braak GJ, Guerts JW, Booij LH, Voerman VF, de Boer T: The efficacy of radiofrequency lesioning of the cervical spinal dorsal root ganglion in a double blinded randomized study: No difference between 40 degrees C and 67 degrees C treatments. *Pain* 1997; 73:158-63
- van Kleef M, Liem L, Lousberg R, Barendse G, Kessels F, Sluiter M: Radiofrequency lesion adjacent to the dorsal root ganglion for cervicobrachial pain: A prospective double blind randomized trial. *Neurosurgery* 1996; 38:1127-31
- van Wijk RM, Guerts JW, Wynne HJ: Long-lasting analgesic effect of radiofrequency treatment of the lumbosacral dorsal root ganglion. *J Neurosurg Spine* 2001; 94:227-31
- Guerts JW, van Wijk RM, Wynne HJ, Hammink E, Buskens E, Lousberg R, Knape JT, Groen GJ: Radiofrequency lesioning of the dorsal root ganglion for chronic lumbosacral radicular pain: A randomized, double-blind, controlled trial. *Lancet* 2003; 361:21-6
- Higuchi Y, Nashold BS Jr, Sluiter M, Cosman E, Pearlstein RD: Exposure of the dorsal root ganglion in rats to pulsed radiofrequency currents activates dorsal horn lamina I and II neurons. *Neurosurgery* 2002; 50:850-5

(Accepted for publication December 20, 2004.)

Anesthesiology 2005; 102:870-1

© 2005 American Society of Anesthesiologists, Inc. Lippincott Williams & Wilkins, Inc.

Endotracheal Tube Damage during Head and Neck Surgeries as a Result of Harmonic Scalpel® Use

To the Editor:—The Harmonic Scalpel® (Ethicon, Somerville, NJ) and laser are precise cutting and coagulating surgical devices. These devices are widely used worldwide for endoscopic and open surgical procedures. We describe our experience with the Harmonic Scalpel® during the anesthetic management of head and neck oncology.

A 58-yr-old male with postradiation recurrence of tongue and soft palate carcinoma was scheduled for wide excision and functional neck dissection with the Harmonic Scalpel® under general anesthesia. After induction of general anesthetic, direct laryngoscopy was performed and an 8 mm cuffed endotracheal tube (ETT) was introduced nasotracheally under vision. Maintenance of anesthetic was achieved with opioids, muscle relaxants, and positive pressure ventilation with 66% nitrous oxide, 34% oxygen, and 0.8% halothane delivered by anesthesia ventilator. The patient remained stable and was closely monitored while the surgeons proceeded with dissection using the Harmonic Scalpel®. While the soft palate lesion was being dissected, the venti-

lator suddenly emitted the low airway pressure alarm and stopped functioning. The surgical team also noticed bubbling of blood inside the oral cavity. Damage to the ETT was suspected and the head end of the operating table was immediately lowered to prevent aspiration of blood that had pooled in the oropharynx. The fraction of inspired oxygen was increased to 60% and manual ventilation was attempted after thorough suctioning of the oral cavity. However, this was unsuccessful due to the leak (fig. 1), and a fresh ETT of the same size was introduced with the aid of a tube exchanger. The patient was reversed at the end of surgery and the ETT was retained overnight. The postoperative period was uneventful.

The blade of the Harmonic Scalpel® vibrates at 55,000 Hz. It cuts and coagulates tissue at temperatures much lower than either lasers or traditional electrocautery. As a result, the risk of airway fires should be reduced. However, as shown here, it is clear that the Harmonic Scalpel®—like a laser—can cause accidental damage to the ETT when used in the pharynx.

The existing literature abounds with techniques to protect the air-

Support was provided solely from institutional and/or departmental sources.

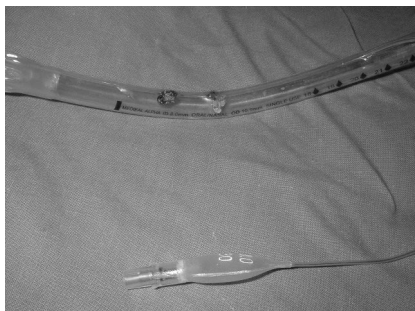


Fig. 1. Polyvinyl chloride endotracheal tube damaged by the Harmonic Scalpel® during surgery on the soft palate.

way and the ETT from lasers and to manage fires when they occur.¹⁻⁶ Substitution of the Harmonic Scalpel® can eliminate the risk of fire (and does not dictate the use of lower concentrations of oxygen), but ETT damage may still occur.

Mallika Balakrishnan, M.D.,* Renju Kuriakose, M.D. * Regional Cancer Centre, Trivandrum, Kerala, India. mallikarcc@yahoo.co.in

References

1. Patil V, Stehling LC, Zauder HL: A modified endotracheal tube for laser microsurgery. *ANESTHESIOLOGY* 1979; 51:571
2. A Practice of Anesthesia for Infants and Children, 3rd edition. Edited by Cote CJ, Todres ID, Goudsouzian NG, Ryan JF. Philadelphia, WB Saunders, 2001, p. 471
3. Anesthesia, 5th edition. Edited by Miller RD. New York, Churchill Livingstone, 2000, p. 2208
4. Sosis M: Anesthesia for laser surgery. *Int Anesthesiol Clin* 1990; 28:119-31
5. Kuo CH, Tan PH, Chen JJ, Peng CH, Lee CC, Chung HC, Tseng CK: Endotracheal tube fires during carbon dioxide laser surgery on the larynx: A case report. *Acta Anaesthesiol Sin* 2001; 39:53-6
6. Meyers A: Complications of CO₂ laser surgery of the larynx. *Ann Otol Rhinol Laryngol* 1981; 90:132-4

(Accepted for publication October 12, 2004.)

Anesthesiology 2005; 102:871

© 2005 American Society of Anesthesiologists, Inc. Lippincott Williams & Wilkins, Inc.

Interference between Extraneal® Peritoneal Dialysis and the Accu-Chek® Blood Glucose Monitor

To the Editor:—I wish to report a little-known and potentially dangerous mechanism of interference between Extraneal® (Baxter Healthcare Corporation, Deerfield, IL) peritoneal dialysis solution and the Accu-Chek® (Roche Diagnostics, Basel, Switzerland) blood glucose test strip monitor. Extraneal® is being integrated into continuous ambulatory peritoneal dialysis regimens because of its increased ultrafiltration and its extralong dwell (time a solution resides in the abdomen). Unfortunately, this new solution interferes with most modern capillary glucose strip-based measuring devices, including the Accu-Chek® brand. The test strip devices can dangerously overestimate the true blood glucose, potentially leading to erroneous treatment and hypoglycemia. A full year before the Food and Drug Administration approved Extraneal® in the United States in December 2002, a case series in a British diabetes journal highlighted this concern.¹ Several patients in that report experienced symptomatic hypoglycemia although their glucose strip machine reported a normal or even increased blood sugar. This year, a case report published in *Diabetes Care*, the journal of the American Diabetes Association, described a patient on Extraneal® who fell into a hypoglycemic coma secondary to this interference in capillary blood glucose measurement.² As anesthesiologists, we must be aware of this potentially lethal monitoring malfunction, especially because during anesthesia, there may be no other clinical warnings of hypoglycemia.

The mechanism behind this interference is quite interesting.³ Icodextrin, a starch-derived, water-soluble glucose polymer, is the osmotically active colloid in the Extraneal® formulation. Up to 40% of indwelling icodextrin is systemically absorbed and then metabolized

by α -amylase into several oligosaccharides, including maltose, maltotriose, and maltotetraose. Although the serum metabolite concentration peaks at the end of the long dwell (approximately 12 h after infusion into the peritoneum), metabolites remain in the circulation for a full 7 days after the last dwell. Many handheld blood glucose monitors use a glucose dehydrogenase-based method to determine glucose concentration, and both maltose and maltotriose interfere with this test, leading to a falsely increased reported value. In contrast, laboratory-based blood glucose-quantifying machines typically use the glucose oxidase-based method, which does not interfere with icodextrin metabolites, thus providing an accurate measurement. In conclusion, before relying on handheld glucose monitors, we must be sure that the specific monitor is compatible with icodextrin-based peritoneal dialysis.

Nir Hoftman, M.D., UCLA Medical Center, Los Angeles, California. nhoftman@mednet.ucla.edu

References

1. Mehmet S, Quan G, Thomas S, Goldsmith D: Important causes of hypoglycemia in patients with diabetes on peritoneal dialysis. *Diabet Med* 2001; 18: 679-82
2. Disse E, Thivolet C: Hypoglycemic coma in a diabetic patient on peritoneal dialysis due to interference of icodextrin metabolites with capillary blood glucose measurements. *Diabetes Care* 2004; 27:2279
3. Moberly JB, Mujais S, Gehr T, Hamburger R, Sprague S, Kucharski A, Reynolds R, Ogrinc F, Martis L, Wolfson M: Pharmacokinetics of icodextrin in peritoneal dialysis patients. *Kidney Int Suppl* 2002; 81:S23-33

(Accepted for publication November 11, 2004.)

Support was provided solely from institutional and/or departmental sources.

Nitroglycerin to Facilitate Insertion of a Labor Epidural

To the Editor:—Placement of a labor epidural or combined spinal-epidural in advanced labor is technically challenging. Regular painful contractions often make it difficult for the parturient to remain still during epidural placement, and this may increase the chance of an accidental dural tap or nerve injury. Decreasing the intensity and frequency of uterine contractions during neuraxial placement in this setting may be advantageous. Previous reports show that nitroglycerin produces rapid effective uterine relaxation.¹⁻⁵ Nitroglycerin to facilitate the placement of a labor epidural has not previously been reported. This case describes the use of nitroglycerin in the setting of advanced labor to facilitate the placement of a labor epidural.

A 35-yr-old, healthy, 90-kg, gravida 3, para 2 parturient admitted to labor and delivery in advanced labor requested an epidural for pain relief. She had two previous uncomplicated normal vaginal deliveries without the use of a labor epidural. A recent cervical examination showed her cervix to be dilated 8 cm, with the fetal head at +1 station. She was moving and uncooperative during contractions, which occurred every 45–60 s. She had not responded to 100 μ g intravenous fentanyl given 5 min previously. With difficulty, we managed to position her in a sitting position to administer the epidural. After a sterile preparation of her back with a 10% povidone-iodine solution and 1% lidocaine skin infiltration, we attempted to insert the epidural catheter using a 17-gauge Tuohy needle. However, she kept moving and was uncooperative during and between uterine contractions. After informing the obstetrician and the patient that we were going to administer medication to help ease the painful contractions, we administered three sprays (400 μ g per spray dose) of sublingual nitroglycerin (Nitrolingual[®] Pumpspray; First Horizon Pharmaceutical Corporation, Alpharetta, GA). This produced a temporary decrease in her uterine contractions (reduction in peak uterine pressures and an increased between-contraction interval as measured by external tocodynamometer) and resulted in some transient pain relief. It was then possible to perform the combined spinal-epidural during the interval between contractions. The patient experienced no hypotension or cardiovascular disturbances after administration of the nitroglycerin and resumed her normal uterine contraction pattern within a few minutes. The patient was delivered of a healthy baby vaginally 2 h later, with 1- and 5-min Apgar scores of 8 and 9, respectively.

Reducing contraction pain during placement of a labor epidural is potentially beneficial. However, the risks of uterine tocolysis must be balanced with the potential benefit of safer epidural placement and labor analgesia. Although there have been no studies demonstrating increased dural puncture or neural damage after epidural placement in an uncooperative and moving parturient, most clinical anesthesiologists believe that a relation must exist. Decreasing the intensity and frequency of uterine contractions during neuraxial placement in this setting should be potentially advantageous. Remifentanyl has been described in this setting to improve analgesia and facilitate the insertion of a labor epidural.⁶ However, potent narcotics have potential adverse effects, in particular maternal apnea, dysphoria, and emesis. Nitroglycerin is a safe, effective uterine tocolytic commonly used in labor, with a rapid onset and brief half-life.^{2,7} Nitroglycerin has minimal, short-lived cardiovascular effects compared with β -adrenergic tocolytics. Although the safety of nitroglycerin during obstetric emer-

gencies seems high, with no adverse maternal or neonatal outcomes,² maternal hypotension and hemodynamics changes are possible, especially if high doses are given.⁸ No more than three metered sprays are recommended within a 15-min period.⁹

A number of studies and case reports describe the use of nitroglycerin in achieving rapid uterine relaxation.^{2,3,5} Nitroglycerin has been used as a tocolytic to reduce uterine hyperactivity,¹⁰ assist reduction of an inverted uterus,¹¹ facilitate intrapartum external cephalic version,¹² and manage preterm labor contractions.¹³ Nitroglycerin can be administered *via* a number of routes (intravenous, sublingual, or ointment); however, bioavailability is highly variable between subjects because of a pronounced first-pass metabolism. After sublingual administration, bioavailability is approximately 38%.¹⁴

Nitroglycerin may be useful in a setting where advanced labor and parturient movement during uterine contractions makes the placement of an epidural difficult and potentially dangerous. It exposes the mother and fetus to minimal risk and, in selected patients, may offer potential benefits justifying its use in this setting. However, physicians should remember that this is “off-label” use of nitroglycerin.⁹ Both the risks and the benefits must be considered, and the patient and her obstetrician must be consulted before uterine tocolytics are administered in this setting.

Brendan Carvalho, M.B.B.Ch., F.R.C.A., Stanford University School of Medicine, Stanford, California. bcarvalho@stanford.edu

References

1. Axemo P, Fu X, Lindberg B, Ulmsten U, Wessen A: Intravenous nitroglycerin for rapid uterine relaxation. *Acta Obstet Gynecol Scand* 1998; 77:50–3
2. Caponas G: Glyceryl trinitrate and acute uterine relaxation: A literature review. *Anaesth Intensive Care* 2001; 29:163–77
3. Dufour P, Vinatier D, Puech F: The use of intravenous nitroglycerin for cervico-uterine relaxation: A review of the literature. *Arch Gynecol Obstet* 1997; 261:1–7
4. Redick LF, Livingston E, Bell E: Sublingual aerosol nitroglycerin for uterine relaxation in attempted external version. *Am J Obstet Gynecol* 1997; 176:496–7
5. Riley ET, Flanagan B, Cohen SE, Chitkarat U: Intravenous nitroglycerin: A potent uterine relaxant for emergency obstetric procedures. Review of literature and report of three cases. *Int J Obstet Anesth* 1996; 5:264–8
6. Brada SA, Egan TD, Viscomi CM: The use of remifentanyl infusion to facilitate epidural catheter placement in a parturient: A case report with pharmacokinetic simulations. *Int J Obstet Anesth* 1998; 7:124–7
7. O'Grady JP, Parker RK, Patel SS: Nitroglycerin for rapid tocolysis: Development of a protocol and a literature review. *J Perinatol* 2000; 20:27–33
8. Buhimschi CS, Buhimschi IA, Malinow AM, Weiner CP: Effects of sublingual nitroglycerin on human uterine contractility during the active phase of labor. *Am J Obstet Gynecol* 2002; 187:235–8
9. Nitrolingual[®] Pumpspray [package insert]. First Horizon Pharmaceutical Corporation, Alpharetta, Georgia, 2003
10. Mercier FJ, Dounas M, Bouaziz H, Lhuissier C, Benhamou D: Intravenous nitroglycerin to relieve intrapartum fetal distress related to uterine hyperactivity: A prospective observational study. *Anesth Analg* 1997; 84:1117–20
11. Dayan SS, Schwalbe SS: The use of small-dose intravenous nitroglycerin in a case of uterine inversion. *Anesth Analg* 1996; 82:1091–3
12. Abouleish AE, Corn SB: Intravenous nitroglycerin for intrapartum external version of the second twin. *Anesth Analg* 1994; 78:808–9
13. El-Sayed YY, Riley ET, Holbrook RH Jr, Cohen SE, Chitkara U, Druzin ML: Randomized comparison of intravenous nitroglycerin and magnesium sulfate for treatment of preterm labor. *Obstet Gynecol* 1999; 93:79–83
14. Noonan P, Benet L: Incomplete and delayed bioavailability of sublingual nitroglycerin. *Am J Cardiol* 1985; 55:184–7

Support was provided solely from institutional and/or departmental sources.

(Accepted for publication November 24, 2004.)

Anesthesiology 2005; 102:873-4

© 2005 American Society of Anesthesiologists, Inc. Lippincott Williams & Wilkins, Inc.

Transpharyngeal Ultrasonography for Cannulation of the Internal Jugular Vein

To the Editor:—Complications due to internal jugular vein (IJV) cannulation are infrequent and rarely life threatening. However, inadvertent carotid artery puncture can lead to serious problems in patients who have atheromas or bleeding disorders or who are undergoing full anticoagulation therapy, as for cardiopulmonary bypass. An external vascular ultrasound technique, using a vascular probe positioned on the neck, has previously been described as an aid for IJV cannulation.¹ We have found useful in our practice an alternative method, using a transesophageal probe.

During the past year, we selected 50 cardiac patients for whom jugular vein cannulation could present a risk. Patients who required monitoring with a transesophageal probe and who had carotid artery disease, previous carotid artery surgery, and difficult anatomy, such as unclear landmarks or no palpable venous pulse, were selected. The mean age of the patients was 72.3 ± 8.8 yr (median, 74 yr).

Transesophageal echocardiographic monitoring is performed with use of a multiplane transducer and a Sonos 5500 imaging system (Hewlett Packard, Andover, MA). Induction of anesthesia and tracheal intubation are performed before insertion of the echo probe. A small towel is placed under the patient's shoulders. The head is then extended and turned slightly to the side opposite the cannulation, and the patient's arms are placed by his or her sides. The patient is positioned in a 25° head-down position. The ultrasound monitor is placed in front of the operator.

The transesophageal echo probe is inserted 12-20 cm from the teeth. The tip is directed along the pharyngeal lateral wall, which is why we call this method *transpharyngeal*. The probe is then rotated laterally 15-20° until the cervical vascular bundle is seen. The view is a mirror image of that obtained from conventional vascular ultrasonography (fig. 1).

A needle covered with a plastic hood is used to search the skin

surface of the neck for the best site of cutaneous insertion to find the IJV, which is not pulsating and does not compress. The ultrasound probe is kept stable on a trolley. The operating field, the operator, and the devices are then prepared as usual under sterile conditions.

The skin puncture site is that nearest the IJV, and the puncturing needle is directed away from the carotid artery. The needle is inserted at a 60° angle to the neck axis and directed to the middle of the vein while it is observed on the monitor. Insertion of the needle through the vein may be seen directly, or it may be seen indirectly as movement of the vein wall (fig. 1). Aspiration of blood in the syringe confirms the proper needle position. As the probe is left in place, no adjustment is needed to maintain the correct view.

The IJV puncture was successful in 100% of the patients studied. No carotid punctures or other immediate complications occurred.

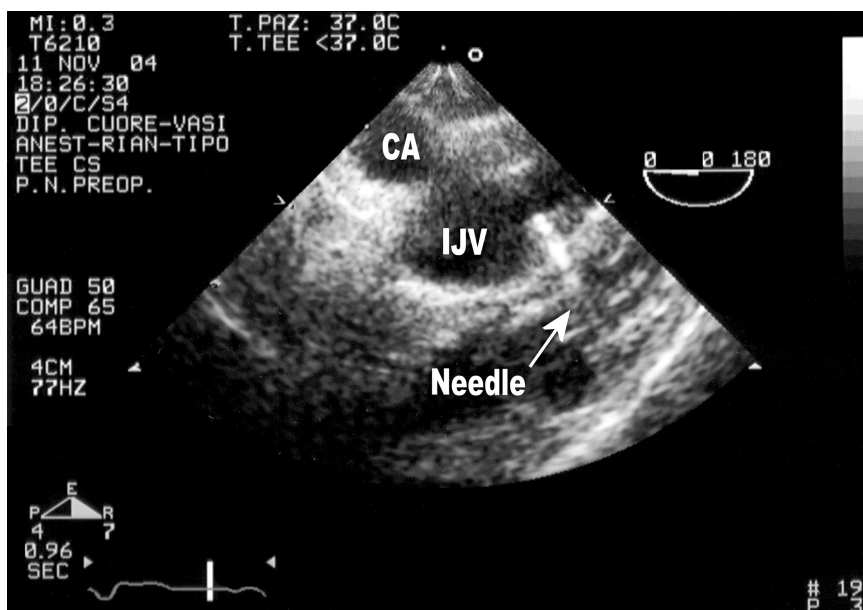
Conventional ultrasound-guided cannulation of the IJV significantly improves the success rate, decreases the access time, and reduces the complication rate of cannulation.²⁻⁴ Meta-analyses and a systematic review of control data from literature⁵⁻⁷ were performed and suggested an advantage of ultrasonography in complicated cases and when access problems were anticipated.^{1,8} At our institution, the widespread use of transesophageal echocardiography, with its ability to provide a view of the vascular bundle of the neck, offers the anesthesiologist a simple way to aid in central venous cannulation, without any additive cost.

Potential advantages of transpharyngeal ultrasonography in comparison with conventional ultrasonography in intubated patients undergoing transesophageal echocardiographic monitoring are as follows: Direct compression on the IJV by the external probe is not needed; other professionals do not need to be involved in the procedure; the operator's hands are free; and the ultrasound probe, still working in the patient, can be used for other purposes.

Further studies are needed to assess the reliability of this procedure for IJV cannulation, to determine its proper indications, and to compare this technique with other methods.

Support was provided solely from institutional and/or departmental sources.

Fig. 1. Transpharyngeal, short-axis view of the neck vessels. The direction of the needle is away from the carotid artery (CA), and the tip of the needle is inside the internal jugular vein (IJV).



Sergio Bevilacqua, M.D.,* Stefano Romagnoli, M.D., Francesco Ciappi, M.D., Nicoletta Ridolfi, M.D., Riccardo Codecasa, M.D., Carlo Rostagno, M.D., Carlo Sorbara, M.D. * Azienda Ospedaliera Universitaria Careggi, Firenze, Italy. sebevi@tin.it

References

1. Denys BG, Uretsky BF, Reddy PS: Ultrasound-assisted cannulation of the internal jugular vein: A prospective comparison to the external landmark-guided technique. *Circulation* 1993; 87:1557-62
2. Koski EM, Suhonen M, Mattila MA: Ultrasound-facilitated central venous cannulation. *Crit Care Med* 1992; 20:424-6
3. Gann M Jr, Sardi A: Improved results using ultrasound guidance for central venous access. *Am Surg* 2003; 69:1104-7
4. Armstrong PJ, Cullen M, Scott DH: The "SiteRite" ultrasound machine: An aid to internal jugular vein cannulation. *Anaesthesia* 1993; 48:319-23
5. Randolph AG, Cook DJ, Gonzales CA, Pribble CG: Ultrasound guidance for placement of central venous catheters: A meta-analysis of the literature. *Crit Care Med* 1996; 24:2053-8
6. Hind D, Calvert N, McWilliams R, Davidson A, Paisley S, Beverley C, Thomas S: Ultrasonic locating devices for central venous cannulation: Meta-analysis. *BMJ* 2003; 327:361-4
7. Keenan SP: Use of ultrasound to place central lines. *J Crit Care* 2002; 17:126-37
8. Mallory DL, McGee WT, Shawker TH, Brenner M, Bailey KR, Evans RG, Parker MM, Farmer JC, Parillo JE: Ultrasound guidance improves the success rate of internal jugular vein cannulation: A prospective, randomized trial. *Chest* 1990; 98:157-60

(Accepted for publication December 2, 2004.)