

## Extramedullary Intrathecal Catheter Granuloma Adherent to the Conus Medullaris Presenting as Cauda Equina Syndrome

Donald C. Shields, M.D., Ph.D.,\* Claudio Palma, M.D.,† Larry T. Khoo, M.D.,‡ F. Michael Ferrante, M.D.§

EXTRAMEDULLARY intrathecal granuloma formation is a rare complication of morphine administration *via* implanted drug delivery systems.<sup>1-5</sup> We present a unique case of a granuloma adherent to the conus medullaris presenting as cauda equina syndrome. Practitioners should not assume that implantation of intrathecal catheters with their tips located at or below the conus medullaris will eliminate all risk of neurologic sequelae associated with inflammatory granulomas.

### Case Report

Over the course of 15 yr, a 47-yr-old male with a history of traumatic L1 compression fracture underwent five lumbar and thoracic surgeries with instrumentation. He subsequently underwent intrathecal morphine pump (SynchroMed®, Medtronic, Minneapolis, MN) placement in 1999 to control his pain. He presented after 5 yr of adequate pain relief at an intrathecal dose of 25 mg of morphine per day (stable over the previous 12-18 months). Beginning 4 months before admission, the patient noted new onset and increasing numbness and sharp burning pain in his left lower extremity. During this time, his physician had liberally increased the patient's oral opioid administration and administered neuropathic pain medication, but no improvement of his symptoms occurred. The patient was admitted with severe unremitting neuropathic pain in his left lower extremity. He was afebrile with a normal leukocyte count. Neurologic examination revealed hypesthesia (without allodynia) from L2-S1 in the left lower extremity. Motor strength and reflexes were preserved bilaterally. The patient had no complaints of bowel or bladder incontinence or sexual dysfunction. Lumbar spine magnetic resonance imaging revealed a T2 hypointense, T1 hyperintense, intrathecal, extramedullary, ovoid 7-mm mass to the left and lateral to the conus medullaris with displacement of the conus to the right. The conus itself demonstrated a central abnormal T2 hyperintensity signal extending craniocaudally for one vertebral level, suggesting cord edema (fig. 1, A and B). This lesion was consistent with a catheter tip granuloma.

After surgical consent, the patient was taken to the operating room for exploration and removal of the granuloma. The catheter entered the dura at approximately L3 with a cranial course to L1. A midline durotomy at the level of L1 revealed the catheter tip to be located within the cauda equina along the left side (fig. 1C). A brownish

extramedullary mass adherent to the conus medullaris surrounded the catheter at its proximal port (fig. 1D). Several of the nerve roots of the cauda equina were adherent to the granuloma (fig. 1D) and were carefully dissected away. On further inspection, the center of the mass contained a thick, purulent-appearing substance that was sent for culture. Solid components of the necrotic mass were plugging the more distal catheter tip openings, requiring blunt dissection for removal of the tip. The necrotic mass was removed *via* sharp dissection (fig. 1, C, D, E). Microscopic examination of the lesion revealed a chronic inflammatory process with necrotic neural tissue. Because bacterial contamination of the entire catheter and pump could not be ruled out, both were removed.

The patient was placed on broad-spectrum antibiotics because of the presence of purulent-appearing material within the center of the granuloma. Consultation with infectious disease specialists suggested the need for repetitive lumbar puncture to determine the presence of occult cerebrospinal fluid (CSF) infection before any consideration of reimplantation, although signs and symptoms of infection never occurred. None of the cultures from the granuloma, catheter tip, pump pocket, or fluid from the pump reservoir revealed bacterial growth.

Postoperatively, the patient's pain was very difficult to manage (average hourly verbal numerical pain score was 9 on a 1-10 scale) despite using 450-550 mg of hydromorphone on a daily basis *via* intravenous patient-controlled analgesia. Because of poor pain control despite access to these extraordinary amounts of intravenous opioids, consideration was given to reservoir implant for intracerebroventricular administration of opioids.<sup>6</sup> This was abandoned because of the substantive risk of infection.<sup>6</sup> Despite the patient's increased risk for recurrent granuloma, an intrathecal drug delivery system was surgically placed such that the catheter pierced the dura at L3 with a caudal course to the level of L5. The patient recovered well from this procedure and was weaned off intravenous opioids without withdrawal. All neurologic symptoms and signs resolved completely, and the patient was discharged home receiving 12.5 mg of intrathecal morphine per day.

Several weeks after discharge, the patient developed new and sudden onset left S1 radicular pain. Repeat magnetic resonance imaging demonstrated that the catheter tip had migrated into the left lateral recess at S1 (fig. 2). With the patient awake, the catheter was repositioned by percutaneous withdrawal under fluoroscopy. The left S1 radicular pain immediately and completely resolved.

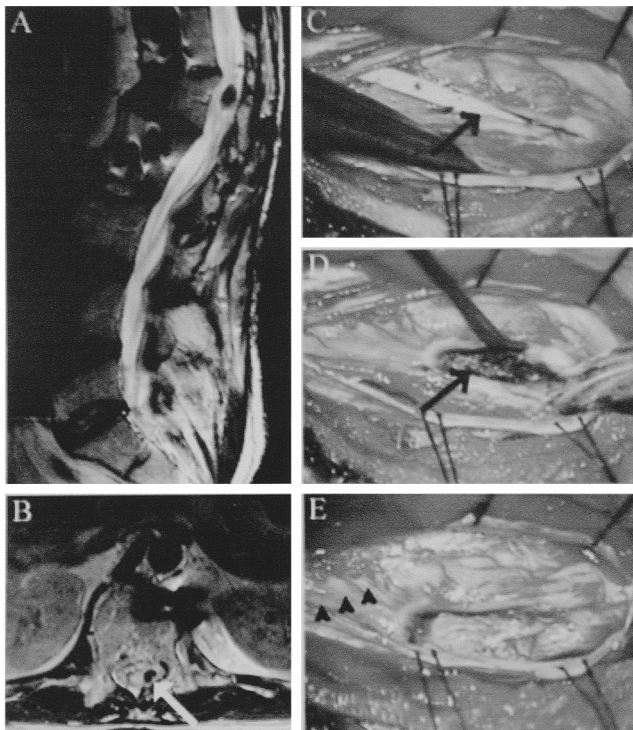
### Discussion

Before the identification of catheter-associated granulomas, it had been customary to place catheter tips at thoracic levels. A shift in practice to catheter placement within the lumbar cistern has now occurred in an attempt to eliminate the risk of neurologic sequelae associated with the development of granulomas. The significance of this case report is that neurologic dysfunction may still occur with catheter tip placement at or below the level of the conus medullaris and the presentation described in this case report will likely become more common, given the shift in practice to lumbar catheter tip placement.

\* Resident, Division of Neurosurgery, Department of Surgery, University of California, Los Angeles. † Fellow, Pain Medicine Center, Department of Anesthesiology, University of California, Los Angeles. ‡ Assistant Professor of Neurosurgery Co-Director, UCLA Spine Center, University of California, Los Angeles. § Professor of Clinical Anesthesiology and Medicine, Pain Medicine Center, Department of Anesthesiology, Co-Director, UCLA Spine Center, University of California, Los Angeles.

Received from the Departments of Anesthesiology and Surgery and the Division of Neurosurgery, UCLA Spine Center, David Geffen School of Medicine at UCLA, Los Angeles, California. Submitted for publication October 1, 2004. Accepted for publication February 3, 2005. Support was provided solely from institutional and/or departmental sources.

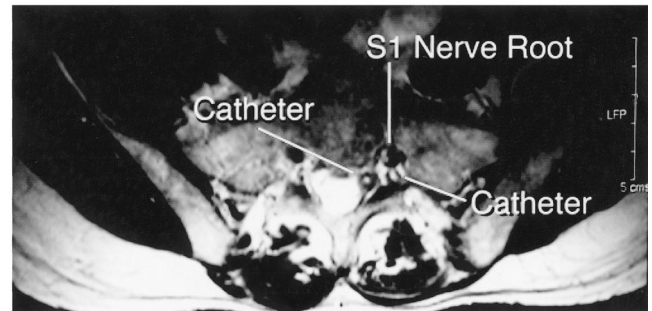
Address reprint requests to Dr. Ferrante: 1245 16th Street, Suite 309, Santa Monica, California 90404. Address electronic mail to: mferrante@mednet.ucla.edu. Individual article reprints may be purchased through the Journal Web site, www.anesthesiology.org.



**Fig. 1.** (A) Sagittal T2-weighted magnetic resonance imaging scan showing the intradural hypointense lesion at the level of L1. (B) Axial T2-weighted magnetic resonance imaging scan at the level of the lesion demonstrating the hypointensity (arrow). (C) Intraoperative photograph (left side = caudal; right side = cephalad) taken after durotomy showing the catheter tip (arrow) encased by the inflammatory mass. (D) After catheter removal, photo shows brownish inflammatory mass (arrow) that was enmeshed in the catheter tip ports. (E) Neural elements remain after sharp dissection of inflammatory mass. Nerve roots of the cauda equina are marked by arrowheads.

Despite the atypical location of the granuloma, the patient had a typical presentation for intrathecal catheter-associated granuloma: sensory changes and increasing pain that was refractory to escalating doses of analgesics. Sensory abnormalities and increased pain are very common presentations of granulomas that can occur with granulomas affecting any part of the spinal neuraxis.<sup>3</sup> Vigilance, with strict attention to symptoms (e.g., increasing pain or new pain) and neurologic signs, is still warranted despite lumbar catheter tip placement to allow early detection of granulomas. Motor deficits typically occur later in the natural history of the progression of granulomas after prodromal symptoms have been overlooked.<sup>1,3</sup> Motor dysfunction may still occur with lumbar catheter tip placement.

Purely anatomic considerations would suggest that catheter placement below the conus medullaris could prevent paresis or paralysis from cord compression. However, motor dysfunction is still possible. Typically, lesions of the conus medullaris (in this case, compression) spare motor and reflex function in the lower extremities but are associated with dense perineal anesthesia (S3-S5) and prominent bowel, bladder, and sexual dysfunction. Lesions of the cauda equina are character-



**Fig. 2.** The catheter is curled within the lateral recess at S1.

ized by neurologic signs and symptoms referable to the involved nerve roots, manifesting as radicular pain, asymmetric lower extremity hypesthesia, anesthesia, motor dysfunction, and variable areflexia. There is relative preservation of bowel and bladder function. Mass lesions in the lower spinal canal can produce a clinical presentation that is a mixture of conus medullaris and cauda equina syndromes. The patient in this report did not present with conus medullaris syndrome despite compression and adherence of the granuloma to the conus. The patient did present with cauda equina syndrome without a motor deficit, although motor abnormalities are possible.

Current hypotheses as to the etiology of catheter granulomas involve the combined contributions of high drug concentration, duration of high concentration infusion, catheter tip location, and poor CSF flow patterns.<sup>1-3</sup> Indeed, this patient had been receiving a high concentration of morphine for at least 2 to 3 yr. In a review of 41 patients with intrathecal granulomas, Coffey and Burchiel reported that 39% of the patients received  $\geq 10$  mg per day and another 39% of patients received  $\geq 25$  mg per day.<sup>1</sup> Magnetic resonance imaging models of pulsatile CSF flow predict the ventral cervical, dorsal thoracic, and ventral lumbar spinal canal to have maximal CSF flow velocities.<sup>7,8</sup> Such areas of high flow would promote good mixing of drug with CSF. Although there is a larger area of CSF in juxtaposition to neural tissue within the lumbar canal in comparison with the thoracic spinal canal, regions of low flow, pooling, and poor mixing of drug do exist.<sup>1</sup>

It is important to comment on the rationale for surgical intervention in this patient. Once a granuloma has been identified, the physician must decide whether to remove the granuloma and all or part of the drug infusion system. Treatment options include cessation of the infusion with shrinkage or disappearance of the granulomas within 2-5 months,<sup>1,3</sup> percutaneous withdrawal of the catheter, and partial or complete surgical removal of the granuloma and infusion system.

Discontinuation of drug infusion is usually reserved for patients with minimal signs and symptoms and small granulomas. In the present situation, the patient was in extremely severe pain that was refractory to neuropathic pain medications and opioids. Cessation of drug admin-

istration would have mandated an intrathecal "drug holiday." Over the 12-18 months before surgery, the patient had received a stable dose of 25 mg of morphine per day. It was anticipated that the patient's pain would be exceedingly difficult to assuage without intrathecal drug administration, and in retrospect, this was true.

In cases where motor dysfunction is not present, percutaneous revision, repositioning or replacement of the catheter have been advocated.<sup>3</sup> Such procedures are to be performed in awake patients with fluoroscopic guidance, continuous lower extremity monitoring of motor and sensory function, the utilization of only gentle traction, and abandonment of the procedure if "force beyond gentle traction is required and/or if the patient reports intraoperative symptoms that indicate displacement of the mass."<sup>3</sup> Percutaneous withdrawal of the catheter was considered but not pursued during the patient's initial presentation because of the exceedingly severe and unremitting neuropathic pain.

In retrospect, percutaneous catheter withdrawal might have initially failed in this patient because of the extension of the granuloma into the catheter's fenestrations, although this is speculation. Similarly, because of its anatomic location, simply pulling the catheter back without durotomy and inspection might have resulted in neurologic deficit resulting from adhesions between the catheter, granuloma, conus medullaris, and several of the nerve roots of the cauda equina. However, this is speculation also. As was demonstrated subsequently with resolution of the S1 radicular pain, percutaneous catheter withdrawal can be effective and safe.

In summary, we present a case of catheter-associated granuloma adherent to the conus medullaris presenting with cauda equina syndrome. Despite the shift in current practice away from thoracic catheter tip placement and its hypothesized benefits on an anatomic basis, this case study demonstrates two complications arising from catheter tip placement within the lumbar cistern. Practitioners must not assume that lumbar catheter tip placement for intrathecal drug infusion is devoid of neurologic sequelae. Regular attention to symptoms and neurologic signs is still warranted despite lumbar catheter tip placement to allow early detection of granulomas.

## References

1. Coffey RJ, Burchiel K: Inflammatory mass lesions associated with intrathecal drug infusion catheters: Report and observations on 41 patients. *Neurosurgery* 2002; 50:78-87
2. Yaksh TL, Hassenbusch S, Burchiel K, Hildebrand KR, Page LM, Coffey RJ: Inflammatory masses associated with intrathecal drug infusion: A review of preclinical evidence and human data. *Pain Med* 2002; 3:300-12
3. Hassenbusch S, Burchiel K, Coffey RJ, Cousins MJ, Deer T, Hahn MB, DuPen S, Follett KA, Krames E, Rogers JN, Sagher O, Staats PS, Wallace M, Willis KD: Management of intrathecal catheter-tip inflammatory masses: A consensus statement. *Pain Med* 2002; 3:313-23
4. McMillan MR, Doud T, Nugent W: Catheter-associated masses in patients receiving intrathecal analgesic therapy. *Anesth Analg* 2003; 96:186-90
5. Follett KA, Naumann CP: A prospective study of catheter-related complications of intrathecal drug delivery systems. *J Pain Symptom Manage* 2000; 19:209-15
6. Lazorthes YR, Sallerin BA-M, Verdier JCP: Intracerebroventricular administration of morphine for control of irreducible cancer pain. *Neurosurgery* 1995; 37:422-9
7. Grietz D, Franck A, Nordell B: On the pulsatile nature of intracranial and spinal CSF circulation demonstrated by MR imaging. *Acta Radiol* 1993; 34:312-28
8. Thomsen C, Stahlberg F, Stubgaard M, Nordell B: Fourier analysis of cerebrospinal fluid flow velocities: MR imaging study. The Scandinavian Flow Group. *Radiology* 1990; 177:659-65

*Anesthesiology* 2005; 102:1061-2

© 2005 American Society of Anesthesiologists, Inc. Lippincott Williams & Wilkins, Inc.

## Retrograde Intubation around an In Situ Combitube: A Difficult Airway Management Strategy

William L. Harrison, M.D.,\* Marc L. Bertrand, M.D.,† Steven K. Andeweg, M.D.,† Jeffrey A. Clark, M.D.†

WE describe a unique airway management experience involving the Combitube and intubation over a retrograde-placed wire.

### Case Report

We responded to a trauma alert at our institution for a 62 yr-old (113 kg, 192 cm) man who was involved in a motorcycle accident and

sustained a closed-head injury. During transport his level of consciousness deteriorated, and the paramedic crew attempted a rapid sequence induction and tracheal intubation to secure the airway. An experienced flight nurse was unable to visualize vocal cords. After two attempts at direct laryngoscopy the patient began to experience oxygen desaturation and the crew placed a Combitube 37-French SA as a rescue airway (Tyco Healthcare Group, Mansfield, MA).<sup>1,2</sup> The patient was successfully ventilated *via* the blue (pharyngeal) lumen, confirming placement of the tip of the Combitube in the proximal esophagus.

On arrival in the emergency department the patient was obtunded and on a backboard. His cervical spine was immobilized with a collar, and he had an oxygen saturation of 100%. Breath sounds were auscultated bilaterally, and the initial end-tidal carbon dioxide measured 30 mmHg with ventilation by Ambu-bag. He was placed on a mechanical ventilator and noted to have a large air leak. Although the pilot balloons on the Combitube remained inflated and firm, gas could be heard escaping from the patient's mouth during ventilation. This did not resolve with insufflation of more air into the pharyngeal cuff. A resident physician and staff anesthesiologist attempted direct laryngoscopy using a Macintosh #4 blade with inline stabilization of the cervical

\* Anesthesiology Resident, † Assistant Professor, Department of Anesthesiology, Dartmouth-Hitchcock Medical Center.

Received from the Department of Anesthesiology, Dartmouth-Hitchcock Medical Center, Lebanon, New Hampshire. Submitted for publication November 2, 2004. Accepted for publication February 3, 2005. Support was provided solely from institutional and/or departmental sources.

Address reprint requests to Dr. Harrison: Department of Anesthesiology, Dartmouth-Hitchcock Medical Center, One Medical Center Drive, Lebanon, New Hampshire 03756. Address electronic mail to: william.l.harrison@hitchcock.org. Individual article reprints may be purchased through the Journal Web site, www.anesthesiology.org.

spine, cricoid pressure, and deflation of the pharyngeal cuff. They were unable to visualize recognizable structures, including the epiglottis. A moderate amount of blood was noted in the pharynx, but suctioning it did not improve the view.

Although oxygen saturation remained at 100%, a more definitive airway was required to provide adequate ventilation. It was thought to be inappropriate to remove the Combitube given multiple failed attempts at direct laryngoscopy. An attempt at fiberoptic intubation was dismissed given the findings of blood in the pharynx. In discussion with the trauma surgical team, we decided to attempt placement of a retrograde wire to achieve tracheal intubation. Surgical staff was present and prepared to intervene with a surgical airway if needed.

The pharyngeal balloon on the Combitube was deflated and ventilation held. A retrograde wire was placed through the cricothyroid membrane using the direct Seldinger technique (Cook Retrograde Intubation Set; Cook Critical Care, Bloomington, Indiana). The wire was advanced until it exited the left naris. A semirigid intubation catheter from the retrograde kit was passed over the wire. A lubricated 7.0-mm ID endotracheal tube was advanced over the wire/catheter assembly and into the trachea. The wire and catheter were removed, the endotracheal tube cuff was inflated, and the patient's lungs were ventilated. Bilateral breath sounds and positive end-tidal carbon dioxide confirmed correct placement of the endotracheal tube. The Combitube was subsequently removed. It appeared grossly normal and without any obvious defects. The patient subsequently received a tracheostomy to manage his airway and required a prolonged stay in the intensive care unit.

## Discussion

This case underscores several important points. The Combitube is well described as an aid in securing the airway when attempts at conventional intubation and ventilation have failed.<sup>3</sup> Experience has shown that removing a rescue airway, even if it is not providing optimal ventilation, can lead to a "can't ventilate, can't intubate" scenario. However, airway exchange with a Combitube may be difficult. During placement, the Combitube is inserted into the esophagus 95% of the time.<sup>3</sup> This precludes airway exchange over a wire, bronchoscope, or catheter without special preplacement modifications to the Combitube.<sup>4</sup> In the minority of cases in which the Combitube is placed in the trachea, airway exchange for an endotracheal tube can proceed using a wire or small diameter airway exchange catheter.

Despite this limitation, techniques for airway exchange with a Combitube in the esophageal location have been described. Gaitini *et al.* described transnasal passage of an armored endotracheal tube over a fiberoptic bronchoscope with a Combitube in place.<sup>5</sup> Although similar to our approach of not removing the Combitube, this technique may be limited by the availability of the fiberoptic scope and the presence of blood or mucus in the pharynx that may make visualization difficult. At least two reports demonstrate retrograde intubation *via* the laryngeal mask airway.<sup>6,7</sup> Again, this is a similar

approach of not removing the rescue device while securing the airway with an endotracheal tube.

The retrograde technique is an accepted method for securing the airway.<sup>8,9</sup> It may be especially useful in patients with facial trauma or hemorrhage or when manipulation of the cervical spine is either impossible or contraindicated. Many trauma patients have facial or neck injuries and oral blood and some may have prehospital placement of a Combitube. Retrograde intubation and the use of a Combitube may be complimentary in these situations, although further experience with this technique is certainly necessary. Nasotracheal intubation is contraindicated in patients with certain facial injuries or basilar skull fractures, neither of which was suspected in our patient. The inability to intubate the trachea is an indication for a surgical airway,<sup>10</sup> but in discussion with the surgical trauma team, it was thought that the Combitube was serving both as an airway and a means to decrease the risk of aspiration. Therefore it was thought appropriate to attempt retrograde intubation with a surgical airway as a backup.

We do not know whether advancing the wire into the mouth with a Combitube in place is possible or if it would subsequently pose difficulties with antegrade passage of either the catheter or endotracheal tube. One could hypothesize that the nasal route of the wire may have allowed better alignment and ease of passage of the endotracheal tube. In summary, we have demonstrated that it is possible to perform retrograde intubation without removing an *in situ* Combitube.

## References

1. Blostein PA, Koestner AJ, Hoak S: Failed rapid sequence intubation in trauma patients: esophageal tracheal Combitube is a useful adjunct. *J Trauma* 1998; 44:534-7
2. Davis DP, Valentine C, Ochs M, Vilke GM, Hoyt DB: The Combitube as a salvage airway device for paramedic rapid sequence intubation. *Ann Emerg Med* 2003; 42:697-704
3. Agro F, Frass M, Benumof JL, Krafft P: Current status of the Combitube: A review of the literature. *J Clin Anesth* 2002; 14:307-14
4. Krafft P, Roggla M, Fidirich P, Locker GJ, Frass M, Benumof JL: Bronchoscopy via a redesigned Combitube in the esophageal position: A clinical evaluation. *ANESTHESIOLOGY* 1997; 86:1041-5
5. Gaitini LA, Vaida SJ, Somri M, Fradis M, Ben-David B: Fiberoptic-guided airway exchange of the esophageal-tracheal Combitube in spontaneously breathing versus mechanically ventilated patients. *Anesth Analg* 1999; 88:193-6
6. Arndt GA, Topp J, Hannah J, McDowell TS, Lesko A: Intubation via the LMA using a Cook retrograde intubation kit. *Can J Anaesth* 1998; 45:257-60
7. Harvey SC, Fishman RL, Edwards SM: Retrograde intubation through a laryngeal mask airway. *ANESTHESIOLOGY* 1996; 85:1503-4
8. Weksler N, Klein M, Weksler D, Sidelnick C, Chorni I, Rozentsveig V, Brill S, Gurman GM, Ovadia L: Retrograde tracheal intubation: Beyond fiberoptic endotracheal intubation. *Acta Anaesthesiol Scand* 2004; 48:412-6
9. An updated report by the American Society of Anesthesiologists Task Force on Management of the Difficult Airway: Practice guidelines for management of the difficult airway. *ANESTHESIOLOGY*. 2003;98: 1269-77
10. American College of Surgeons Committee on Trauma: *Advanced Trauma Life Support for Doctors*, 6th edition. Chicago, American College of Surgeons, 1997, pp 61-72