

## Air Embolism during Intraoperative Endoscopic Localization and Surgical Resection for Blue Rubber Bleb Nevus Syndrome

Robert S. Holzman, M.D.,\* Lisa Yoo, M.D.,† Victor L. Fox, M.D.,‡ Steven J. Fishman, M.D.§

BLUE rubber bleb nevus syndrome, a rare vascular malformation involving the gastrointestinal tract, may result in clinically significant acute and chronic bleeding. The bleeding is generally chronic and unremitting, with continual melena necessitating transfusion or surgical management. Definitive surgical management is frustrating because the lesions are usually multiple (often numbering in the hundreds) and may be found anywhere in gut derivatives from the mouth to the anus, most often in the small intestine. The length of the instruments available and the risks of incomplete removal and perforation limit endoscopic treatment such as sclerotherapy or laser photocoagulation as an alternative. Combined approaches using transoral and transrectal endoscopic examination and endoscopic examination *via* laparotomy/enterotomy permit visualization of the entire gastrointestinal tract.<sup>1-6</sup>

### Case Report

An 11-yr-old, 29.6-kg girl with blue rubber bleb nevus syndrome underwent simultaneous upper and lower endoscopy and exploratory laparotomy for resection of multiple vascular lesions. She had experienced gastrointestinal bleeding 2 weeks before admission.

After intravenous premedication with midazolam, anesthesia was induced with propofol, fentanyl, and pancuronium. The trachea was intubated with a 6.0-mm cuffed orotracheal tube, and anesthesia was maintained with an air-oxygen mixture and 0.5-1.2% end-tidal isoflurane. Ventilation at a tidal volume of 320 ml and a rate of 9 breaths/min was controlled by a rising-bellows pneumatic anesthesia ventilator. Standard noninvasive monitors were used, and in addition, a radial artery line was placed. An infrared spectrometer was used (Datex Capnomac Ultima; Datex Medical Instrumentation, Tewksbury, MA), and end-tidal carbon dioxide and isoflurane concentrations were recorded.

Approximately 3 h into the procedure, after laparotomy, esophago-gastroduodenoscopy, and transoral proximal enteroscopy with manual assistance to advance the telescope and while undergoing colonoscopy (Olympus PCF-160-AL video colonoscope; Olympus America Inc., Melville, NY), the patient had a decrease in oxygen saturation to 88-94%, a decrease in end-tidal carbon dioxide to 22 mmHg, and hypotension (51/31 mmHg; baseline, 93/43 mmHg). Simultaneously,

there was an increase in the peak inspiratory pressure (33 cm H<sub>2</sub>O; baseline, 22 cm H<sub>2</sub>O) and mean airway pressure (17 cm H<sub>2</sub>O; baseline, 5 cm H<sub>2</sub>O). The small bowel was distended approximately 6 cm and attenuated. The insufflation was stopped, the bowel was allowed to decompress, the isoflurane and air in the inspired gas were discontinued, and the oxygen saturation improved to 99-100%. A bolus of lactated Ringer's solution (19 ml/kg) was given. After the patient became hemodynamically stable, the surgeon examined the bowel and found small air bubbles with a "Rice Krispies<sup>®</sup>" appearance in the mesentery (fig. 1).

Gas delivery system dysfunction accounting for a sudden decrease in end-tidal carbon dioxide was quickly checked for and ruled out: There was no leak in the endotracheal tube cuff, the patient did not show evidence of spontaneous breathing either by physical examination or notching of the capnographic waveform, and there were no disconnects or ventilation system obstructions. No further treatment was required, and the case proceeded uneventfully to the conclusion of surgery, emergence, and the perioperative period.

### Discussion

Venous air embolism (VAE), now commonly reported with many surgical procedures, has rarely been reported with gastrointestinal endoscopy. This case offered a unique opportunity to examine the external surface of the bowel and mesentery during upper and lower gastrointestinal endoscopy. The most likely cause of the VAE was direct transmucosal to intravascular introduction of enteric air under high pressure, with additional entrapment in the mesentery.

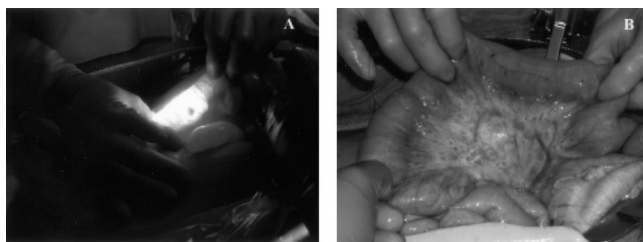
The pathophysiology of VAE has been well described<sup>7</sup>; typical intraoperative signs include hypotension, a decrease in end-tidal carbon dioxide, and alterations in airway pressure. The biochemistry of these multisystem findings may result from the release of vasoactive mediators, complement, and cytokines.<sup>8-10</sup> However, early detection remains the basis for monitoring in higher risk cases. Although not usually employed during lower risk cases, transesophageal echocardiography, precordial Doppler ultrasonography, or a pulmonary artery catheter, in descending level of sensitivity, reveal evidence of VAE.<sup>11</sup> The pneumomesentery with crunchy "Rice Krispies<sup>®</sup>"-like pockets of air and the rapid resolution of the signs of VAE after decompression of the bowel and removal of the colonoscope serve to further support the intraoperative diagnosis of VAE.

The choice of insufflation gas has been a matter of considerable investigation. Almost all surgical endoscopy at this point is conducted with carbon dioxide as the insufflation gas, whereas the gastrointestinal endoscopy insufflation gas most commonly used continues to be air. Other gases less frequently used include nitrous

\* Associate Professor of Anesthesia, ‡ Assistant Professor of Pediatrics, § Assistant Professor of Surgery, Harvard Medical School. † Clinical Fellow in Anesthesia, Beth Israel Deaconess Medical Center, Boston, Massachusetts.

Received from Harvard Medical School, Boston, Massachusetts. Submitted for publication November 9, 2004. Accepted for publication February 3, 2005. Support was provided solely from institutional and/or departmental resources.

Address reprint requests to Dr. Holzman: Department of Anesthesiology, Perioperative and Pain Medicine, Children's Hospital Boston, 300 Longwood Avenue, Boston, Massachusetts 02115. Address electronic mail to: robert.holzman@childrens.harvard.edu. Individual article reprints may be purchased through the Journal Web site, www.anesthesiology.org.



**Fig. 1.** (A) Intraoperative enteroscopy demonstrating nevous location by transillumination. (B) Pneumomesentery.

oxide, helium, argon, nitrogen, and oxygen. Although nitrous oxide is somewhat less soluble than carbon dioxide (130 *vs.* 170 ml/100 ml water), it supports combustion. Even the use of nitrous oxide as part of the anesthetic technique is less frequently chosen because of its possible contribution to expanding any entrained or insufflated air.<sup>12</sup> The choice of carbon dioxide as an insufflation gas is based on its high aqueous solubility and lack of support of combustion. The magnitude of physiologic derangement attributable to carbon dioxide is 6.5 times less than that of air.<sup>13</sup> Neither helium nor argon support combustion, but argon has been associated with myocardial depression, and helium has been associated with subcutaneous emphysema.

This intraoperative endoscopic approach to the multifocal vascular malformations of blue rubber bleb nevus syndrome has rarely been described,<sup>3,14,15</sup> although in 10 previous cases at our institution by the same surgeon and gastroenterologist, VAE did not occur. However, this case raises an intriguing question. Because transoral and transrectal flexible endoscopy is so commonly performed and intraoperative enteroscopy is rarely used, it is likely that technical aspects of the latter technique contributed to the occurrence of VAE. Continuous insufflation through the endoscope while maintaining manual compression of the distal bowel optimizes visualization and the likelihood of identifying small lesions. However, this technique may increase the intraluminal pressure beyond that caused by standard closed-abdomen endoscopy. As collaborations in the operating room continue to develop between surgeons and procedurally trained

medical colleagues, consideration should be given to how techniques developed outside the operating room should be modified, such as conversion to carbon dioxide rather than air for gastrointestinal insufflation. VAE is rare in current clinical practice,<sup>16,17</sup> but as practice and new collaborations evolve, previous practices should be a cause for reflection if not active, prospective study.

## References

1. Domini M, Aquino A, Fakhro A, Tursini S, Marino N, Di Matteo S, Lelli Chiesa P: Blue rubber bleb nevus syndrome and gastrointestinal haemorrhage: Which treatment? *Eur J Pediatr Surg* 2002; 12:129-33
2. Dwivedi M, Misra S: Blue rubber bleb nevus syndrome causing upper GI hemorrhage: A novel management approach and review. *Gastrointest Endosc* 2002; 55:943-6
3. Fishman S, Smithers C, Folkman J, Lund D, Burrows P, Mulliken J, Fox V: Blue rubber bleb nevus syndrome: Surgical eradication of gastrointestinal bleeding. *Ann Surg* 2005; 241:523-8
4. Jain A, Kar P, Chander R, Khandpur S, Jain S, Prabhaskar K, Gangwal P: Blue rubber bleb nevus syndrome: A cause of gastrointestinal hemorrhage. *Indian J Gastroenterol* 1998; 17:153-4
5. Oksuzoglu B, Oksuzoglu G, Cakir U, Bayir T, Esen M: Blue rubber bleb nevus syndrome. *Am J Gastroenterol* 1996; 91:780-2
6. Place R: Blue rubber bleb nevus syndrome: A case report with long-term follow-up. *Mil Med* 2001; 166:728-30
7. Muth C, Shank E: Gas embolism. *N Engl J Med* 2000; 342:476-82
8. Nossum V, Hjelde A, Brubakk A: Small amounts of venous gas embolism cause delayed impairment of endothelial function and increase polymorphonuclear neutrophil infiltration. *Eur J Appl Physiol* 2002; 86:209-14
9. Nossum V, Hjelde A, Bergh K, Ustad A, Brubakk A: Anti-C5a monoclonal antibodies and pulmonary polymorphonuclear leukocyte infiltration: Endothelial dysfunction by venous gas embolism. *Eur J Appl Physiol* 2003; 89:243-8
10. Wang D, Li M, Hsu K, Shen C, Chen H, Lin Y: Air embolism-induced lung injury in isolated rat lungs. *J Appl Physiol* 1992; 72:1235-42
11. Glenski J, Cucchiara R, Michenfelder J: Transesophageal echocardiography and transcutaneous O<sub>2</sub> and CO<sub>2</sub> monitoring for detection of venous air embolism. *ANESTHESIOLOGY* 1986; 64:541-5
12. Kytta J, Tanskanen P, Randell T: Comparison of the effects of controlled ventilation with 100% oxygen, 50% oxygen in nitrogen, and 50% oxygen in nitrous oxide on responses to venous air embolism in pigs. *Br J Anaesth* 1996; 77:658-61
13. Steffy E, Johnson B, Eger E: Nitrous oxide intensifies the pulmonary arterial pressure response to venous injection of carbon dioxide in the dog. *ANESTHESIOLOGY* 1980; 52:52-5
14. Shimada S, Namikawa K, Maeda K, Obata S, Ikei S, Mizutani J, Ogawa M: Endoscopic polypectomy under laparotomy throughout the alimentary tract for a patient with blue rubber bleb nevus syndrome. *Gastrointest Endosc* 1997; 45:423-7
15. Watanabe Y, Sato M, Tokui K, Yukumi S, Koga S, Nezu K, Matsui H, Murakami H, Kawachi K: Multiendoscope-assisted treatment for blue rubber bleb nevus syndrome (case report). *Surg Endosc* 2000; 14:595
16. Herron D, Vernon J, Gryska P, Reines H: Venous gas embolism during endoscopy. *Surg Endosc* 1999; 13:276-9
17. Katzgraber F, Glenewinkel F, Fischler S, Rittner C: Mechanism of fatal air embolism after gastrointestinal endoscopy. *Int J Legal Med* 1998; 111:154-6

## Remifentanyl in the Intensive Care Unit: Tolerance and Acute Withdrawal Syndrome after Prolonged Sedation

Bernard Delvaux, M.D.,\* Yves Ryckwaert, M.D.,† Michel Van Boven, M.D.,‡ Marc De Kock, Ph.D.,§  
Xavier Capdevila, Ph.D.||

SEDATION in the intensive care unit should be minimized to reduce the duration of mechanical ventilation and its related complications.<sup>1</sup> The drug regimen would ideally allow rapid awakening, to perform neurologic and respiratory evaluation on a daily basis.<sup>2,3</sup> In this context, remifentanyl, with its unique pharmacokinetic profile, should be considered an agent of choice.<sup>4,5</sup> However, acute tolerance and even hyperalgesic response have been observed after opioid administration.<sup>6-8</sup> In addition, withdrawal syndrome after cessation of opioid-based sedation has been seen in the intensive care unit setting.<sup>9-11</sup> We report three cases of severe and fast-onset withdrawal syndrome, with signs of acute tolerance, after remifentanyl-based sedation of between 2 and 30 days' duration, requiring reintroduction of remifentanyl and then tapering over 24-48 h.

### Case Reports

#### Case 1

A 69-yr-old man was admitted to the hospital for facial and hip trauma after a bike accident. He underwent intubation on day 3 for respiratory failure. He was sedated with propofol at 200 mg/h and remifentanyl at  $0.1 \mu\text{g} \cdot \text{kg}^{-1} \cdot \text{min}^{-1}$  and then  $0.16 \mu\text{g} \cdot \text{kg}^{-1} \cdot \text{min}^{-1}$  to maintain a Ramsay score of 3. On day 5, the propofol was stopped, and the remifentanyl infusion was decreased to  $0.08 \mu\text{g} \cdot \text{kg}^{-1} \cdot \text{min}^{-1}$  for 1 h. The patient then safely underwent extubation, and the remifentanyl was stopped 1 h later. Within 10 min, the patient became very anxious, reporting vague discomfort but no pain. He had myoclonus and uncontrollable shaking of all four limbs, and was noted to be sweating, hypertensive, and tachycardic. We suspected an opioid withdrawal syndrome, which was treated with 20 mg intravenous morphine, 150  $\mu\text{g}$  clonidine, and 10 mg haloperidol. Despite this treatment, the symptomatology persisted. We restarted remifentanyl at  $0.1 \mu\text{g} \cdot \text{kg}^{-1} \cdot \text{min}^{-1}$ , and the symptoms disappeared within 5 min. Subsequently, we started a morphine infusion at 40 mg/day and then progressively tapered remifentanyl over the next 48 h.

\* Resident, ‡ Staff Anesthesiologist, § Professor and Head, Anesthesiology Department, University Hospital Saint-Luc, Catholic University of Louvain, Brussels, Belgium. † Staff Anesthesiologist, || Professor and Head, Anesthesia and Intensive Care Department, Lapeyronie University Hospital, Montpellier, Montpellier, France.

Received from the Anesthesia and Intensive Care Department, Lapeyronie University Hospital, Montpellier, France. Submitted for publication December 1, 2004. Accepted for publication February 23, 2005. Support was provided solely from institutional and/or departmental sources.

Address reprint requests to Dr. Delvaux: Service d'Anesthésiologie, Cliniques Universitaires Saint-Luc, Avenue Hippocrate 10, B-1200 Brussels, Belgium. Address electronic mail to: delvauxbernard@yahoo.fr. Individual article reprints may be purchased through the Journal Web site, www.anesthesiology.org.

#### Case 2

A 52-yr-old man was admitted to the hospital for head trauma after a motorbike accident. He underwent intubation and received remifentanyl at  $0.1 \mu\text{g} \cdot \text{kg}^{-1} \cdot \text{min}^{-1}$  and midazolam at 15 mg/h. After 24 h, the midazolam was stopped. During the ensuing 30 days, we had to increase the infusion rate of remifentanyl to  $0.725 \mu\text{g} \cdot \text{kg}^{-1} \cdot \text{min}^{-1}$  to maintain a Ramsay score of 3. On day 33, after neurologic improvement, we were able to decrease the infusion rate to  $0.325 \mu\text{g} \cdot \text{kg}^{-1} \cdot \text{min}^{-1}$ , and the patient underwent extubation after further tapering over a 2-h period. Ten minutes after discontinuation, we observed severe agitation with tachycardia, hypertension, tachypnea, mydriasis, sweating, and myoclonus. The patient was given 10 mg morphine and 150  $\mu\text{g}$  clonidine intravenously, without any change. We restarted remifentanyl infusion at a rate of  $0.1 \mu\text{g} \cdot \text{kg}^{-1} \cdot \text{min}^{-1}$ , and the symptoms improved dramatically. An intravenous infusion of morphine was started, followed by tapering of the remifentanyl over 24 h.

#### Case 3

A 32-yr-old woman was admitted to the hospital after an automobile accident with head trauma, myocardial contusion, and fracture of the wrist and ankle. She underwent intubation and was sedated for the next 4 days to maintain a Ramsay score of 4, with propofol at 120 mg/h and remifentanyl at  $0.12 \mu\text{g} \cdot \text{kg}^{-1} \cdot \text{min}^{-1}$ . The remifentanyl infusion rate had to be increased to  $0.72 \mu\text{g} \cdot \text{kg}^{-1} \cdot \text{min}^{-1}$  and the propofol rate had to be increased to 200 mg/h because of pneumonia. After resolution of the pneumonia, the remifentanyl infusion rate was decreased to  $0.48 \mu\text{g} \cdot \text{kg}^{-1} \cdot \text{min}^{-1}$ , and propofol was stopped and replaced by midazolam at 10 mg/h because of signs of major anxiety. On day 15, midazolam and remifentanyl were discontinued, and 10 mg morphine was injected intravenously. The patient became extremely agitated, although not confused, with associated tachycardia, hypertension, tachypnea, and mydriasis. She received 150  $\mu\text{g}$  intravenous clonidine and 20 mg ketamine, without any improvement. She improved immediately after reintroduction of remifentanyl. The patient underwent extubation 2 days later, after remifentanyl was tapered in conjunction with an intravenous infusion of morphine and clonidine.

### Discussion

We use remifentanyl-based sedation to facilitate frequent awakening for neurologic and respiratory evaluation of our patients.<sup>4,5,12,13</sup> During a 6-month period, 4 of 40 patients receiving a similar sedation regimen in our department presented the same acute-onset withdrawal syndrome, in addition to development of acute tolerance to remifentanyl.

Initial infusion rates complied with the manufacturer's recommendations ( $0.10-0.15 \mu\text{g} \cdot \text{kg}^{-1} \cdot \text{min}^{-1}$ ). Subsequently, they were adjusted, following an established protocol, to maintain a predefined Ramsay score. When sedation was no longer needed, the infusions were ta-



pered and stopped over a 2-h period. This protocol was similar to protocols in place in other intensive care units in France.

We think that the observed symptoms are those of withdrawal syndrome because, first, the clinical presentation was typical of an opioid withdrawal syndrome, and the onset was approximately 10 min after discontinuation of remifentanyl; second, the patients were not in pain at the time of symptoms; third, the patients had regained consciousness and did not show any confusion; and finally, the patients did not have any significant preexisting medical conditions or history of substance abuse (e.g., alcohol) that could explain the symptoms.

We did not find any similar cases of acute-onset withdrawal syndrome in studies with adult patients<sup>9,10</sup> or children.<sup>14-17</sup> In adult studies, withdrawal syndrome occurs when there is a sudden discontinuation of an opioid drug (usually fentanyl).<sup>9,10</sup> We postulate that in our series of patients, the same phenomenon occurred after discontinuation of the short-acting remifentanyl over a short period of time (2 h).

Acute tolerance to the analgesic effects of opioids has been shown to occur within a few hours after commencing administration of opioids,<sup>6,7</sup> including remifentanyl,<sup>6,8</sup> but acute tolerance to their sedative properties has been studied little.<sup>16,17</sup>

Our patients had no history of alcohol or substance abuse. However, other patients who received the same drug regimen, including some who were alcohol abusers, did not present such a withdrawal syndrome. We believe there may be a genetic component to these observations.<sup>18,19</sup> Pharmacogenetics is a gene-by-gene approach, and pharmacogenomics is an approach to the genome focusing on its expression.<sup>20</sup> The latter approach seems more appropriate in evaluating a genetic basis for tolerance and withdrawal, because these processes are complex and likely involve many pathways (e.g., the cyclic adenosine monophosphate signal transduction pathway and its distal effectors).<sup>20</sup> However, much research remains to be done in this field before we can accurately evaluate the potential importance of these various mechanisms.<sup>21</sup>

In conclusion, we hypothesize that remifentanyl-based sedation may result in acute tolerance and a unique withdrawal syndrome, in that it can only be treated by remifentanyl. The obvious precipitating factor seems to be the rate of infusion discontinuation. Because there were no medical risk factors identified, we postulate that this difference could be due to yet unknown genetic factors. Current guidelines recommend a systematic prevention of opioid withdrawal syndrome by gradually tapering the infusion rate.<sup>22</sup> However, further studies are necessary to prospectively evaluate the clinical importance of this phenomenon in relation to remifentanyl. In the meantime, we recommend tapering a remifentanyl-

based sedation over 24–48 h, in conjunction with a concurrently running morphine infusion (evidence-based recommendation grade C).

The authors thank Francis Veyckemans, M.D. (Professor of Anesthesiology, Anesthesiology Department, Chairman of Acute Medicine Department, University Hospital Saint-Luc, Catholic University of Louvain, Brussels, Belgium), and Scott Nordstrom, M.D. (Staff Anesthesiologist, Montreal General Hospital, McGill University Health Center, Montreal, Canada).

## References

- Schweickert WD, Gehlbach BK, Pohlman AS, Hall JB, Kress JP: Daily interruptions of sedative infusions and complications of critical illness in mechanically ventilated patients. *Crit Care Med* 2004; 32:1272-6
- Kress JP, Pohlman AS, O'Connor MF, Hall JB: Daily interruption of sedative infusions in critically ill patients undergoing mechanical ventilation. *N Engl J Med* 2000; 342:1471-7
- Kollef MH, Levy NT, Ahrens TS, Schaiff R, Prentice D, Sherman G: The use of continuous IV sedation is associated with prolongation of mechanical ventilation. *Chest* 1998; 114:541-8
- Dahaba AA, Grabner T, Rehak PH, List WF, Metzler H: Remifentanyl versus morphine analgesia and sedation for mechanically ventilated critically ill patients. *ANESTHESIOLOGY* 2004; 101:640-6
- Kuhlen R, Putensen C: Remifentanyl for analgesia-based sedation in the intensive care unit. *Crit Care* 2004; 8:13-4
- Guignard B, Bossard AE, Coste C, Sessler DI, Lebrault C, Alfonsi P, Fletcher D, Chauvin M: Acute opioid tolerance: Intraoperative remifentanyl increases postoperative pain and morphine requirement. *ANESTHESIOLOGY* 2000; 93:409-17
- Chia YY, Liu K, Wang JJ, Kuo MC, Ho ST: Intraoperative high dose fentanyl induces postoperative fentanyl tolerance. *Can J Anesth* 1999; 46:872-7
- Angst MS, Koppert W, Pahl I, Clark DJ, Schmelz M: Short-term infusion of the mu-opioid agonist remifentanyl in humans causes hyperalgesia during withdrawal. *Pain* 2003; 106:49-57
- Cammarano WB, Pittet JF, Weitz S, Schlobohm RM, Marks JD: Acute withdrawal syndrome related to the administration of analgesic and sedative medications in adult intensive care unit patients. *Crit Care Med* 1998; 26:676-84
- Brown C, Albrecht R, Pettit H, McFadden T, Schermer C: Opioid and benzodiazepine withdrawal syndrome in adult burn patients. *Am Surg* 2000; 66:367-70
- Tobias JD: Tolerance, withdrawal and physical dependency after long-term sedation and analgesia of children in the pediatric intensive care unit. *Crit Care Med* 2000; 28:2122-32
- Muellejans B, Lopez A, Cross MH, Bonome C, Morrison L, Kirkham AJ: Remifentanyl versus fentanyl for analgesia based sedation to provide patient comfort in the intensive care unit: A randomized, double-blind controlled trial. *Crit Care* 2004; 8:R1-11
- Karabinis A, Mandragos K, Stergiopoulos S, Komnos A, Soukup J, Speelberg B, Kirkham AJ: Safety and efficacy of analgesia-based sedation with remifentanyl versus standard hypnotic-based regimens in intensive care unit patients with brain injuries: A randomised, controlled trial. *Crit Care* 2004; 8:R268-80
- Katz R, Kelly HW, Hsi A: Prospective study on the occurrence of withdrawal in critically ill children who receive fentanyl by continuous infusion. *Crit Care Med* 1994; 22:763-7
- Dominguez KD, Lomako DM, Katz RW, Kelly HW: Opioid withdrawal in critically ill neonates. *Ann Pharmacother* 2003; 37:473-7
- Arnold JH, Truog RD, Orav EJ, Scavone JM, Hershenson MB: Tolerance and dependence in neonates sedated with fentanyl during extracorporeal membrane oxygenation. *ANESTHESIOLOGY* 1990; 73:1136-40
- Arnold JH, Truog RD, Scavone JM, Fenton T: Changes in the pharmacodynamic response to fentanyl in neonates during continuous infusion. *J Pediatr* 1991; 119:639-43
- Hoffmann O, Plesan A, Wiesenfeld-Hallin Z: Genetic differences in morphine sensitivity, tolerance and withdrawal in rats. *Brain Res* 1998; 806:232-7
- Nestler EJ, Landsman D: Learning about addiction from the genome. *Nature* 2001; 409:834-5
- Lichteremann D, Franke P, Maier W, Rao ML: Pharmacogenomics and addiction to opiates. *Eur J Pharmacol* 2000; 410:269-79
- Lötsch J, Skarke C, Liefhold J, Geisslinger G: Genetic predictors of the clinical response to opioid analgesics. *Clin Pharmacokinet* 2004; 43:983-1013
- Jacobi J, Fraser GL, Coursin DB, Riker RR, Fontaine D, Wittbrodt ET, Chalfin DB, Masica MF, Bjerke HS, Coplin WM, Crippen DW, Fuchs BD, Kelleher RM, Marik PE, Nasraway SA Jr, Murray MJ, Peruzzi WT, Lumb PD, Task Force of the American College of Critical Care Medicine (ACCM) of the Society of Critical Care Medicine (SCCM), American Society of Health-System Pharmacists (ASHP), American College of Chest Physicians: Clinical practice guidelines for the sustained use of sedatives and analgesics in the critically ill adult. *Crit Care Med* 2002; 30:119-41