

## Intraneural Injection during Anterior Approach for Sciatic Nerve Block: What Have We Learned and Where to Go from Here?

*To the Editor:*—We read with interest the case report by Sala-Blanch *et al.*<sup>1</sup> The authors describe an unorthodox but interesting treatment for patients undergoing continuous sciatic nerve block that raises several concerns. In short, using computed tomographic imaging without clear clinical indication, the authors documented that nerve stimulator-guided needle placement during sciatic nerve block through the anterior approach resulted in an intraneural needle placement. The authors then inserted the catheter and administered local anesthetics. Conventional wisdom suggests that intraneural needle placement and catheter insertion should be avoided because intraneural application of local anesthetics has been shown to result in neurologic injury in animal models.<sup>2–6</sup> However, despite the documented intraneural needle and catheter placement—although it is not clear whether the stimulating needle lies between fascia and epineurium or between epineurium and perineurium—the patients did not have neurologic injury. Therefore, this case report suggests that not all intraneural injections lead to neurologic injury. It also suggests that nerve stimulators may not be reliable in avoiding intraneural needle or catheter placement. Finally, a better definition of what constitutes an intraneural *versus* an intraepineural sheath injection during blockade of peripheral nerves and plexuses is needed for more meaningful discussion of this matter. Some experts may view the patient treatment in report by Sala-Blanch *et al.* unusual or even potentially hazardous. However, their findings should be welcomed because they clearly pose some important questions. At the least, they suggest that future research should continue to focus on developing more reliable and objective tools of nerve localization and injection monitoring techniques to help avoid intraneural injection and reduce the risk of consequent neuro-

logic injury.<sup>7</sup> In any case, it is recommended to withdraw the needle or the catheter if one has any doubt that its position is too close to the nerve, for the safety of regional anesthesia.

**Stephan Blumenthal, M.D., Maud Lambert, M.D., Alain Borgeat, M.D.\*** \* Balgrist University Hospital, Zurich, Switzerland.  
aborgeat@balgrist.unizh.ch

### References

1. Sala-Blanch X, Pomes J, Matute P, Valls-Sole J, Carrera A, Tomas X, Garcia-Diez AI: Intraneural injection during anterior approach for sciatic nerve block. *ANESTHESIOLOGY* 2004; 101:1027–30
2. Selander D: Neurotoxicity of local anesthetics: Animal data. *Reg Anesth* 1993; 18:461–8
3. Radwan IA, Saito S, Goto F: The neurotoxicity of local anesthetics on growing neurons: A comparative study of lidocaine, bupivacaine, mepivacaine, and ropivacaine. *Anesth Analg* 2002;94: 319–24, table of contents
4. Zapata-Sudo G, Trachez MM, Sudo RT, Nelson TE: Is comparative cardiotoxicity of S(–) and R(+) bupivacaine related to enantiomer-selective inhibition of L-type Ca(2+) channels? *Anesth Analg* 2001; 92:496–501
5. Kishimoto T, Bollen AW, Drasner K: Comparative spinal neurotoxicity of prilocaine and lidocaine. *ANESTHESIOLOGY* 2002; 97:1250–3
6. Kirihara Y, Saito Y, Sakura S, Hashimoto K, Kishimoto T, Yasui Y: Comparative neurotoxicity of intrathecal and epidural lidocaine in rats. *ANESTHESIOLOGY* 2003; 99:961–8
7. Hadzic A, Dilberovic F, Shah S, Kulenovic A, Kapur E, Zaciragic A, Cosovic E, Vuckovic I, Divanovic KA, Mornjakovic Z, Thys DM, Santos AC: Combination of intraneural injection and high injection pressure leads to fascicular injury and neurologic deficits in dogs. *Reg Anesth Pain Med* 2004; 29:417–23

(Accepted for publication February 17, 2005.)

Anesthesiology 2005; 102:1283–4

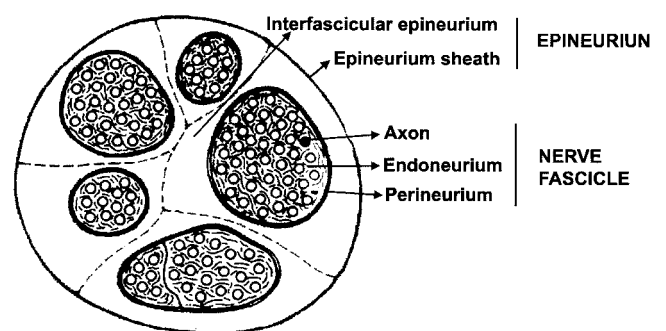
© 2005 American Society of Anesthesiologists, Inc. Lippincott Williams & Wilkins, Inc.

*In Reply:*—We appreciate the interest of Dr. Blumenthal *et al.* in our case report on intraneural administration of local anesthetic during an anterior approach of the sciatic nerve.<sup>1</sup> We agree completely with these authors but would like to clarify a few details.

Our patients had been included in a study intended to evaluate the accessibility of the sciatic nerve using the anterior approach. We aimed at determining the reliability and stability of the catheter for postoperative analgesia in this approach. Despite this explanation of why we conducted these blocks in the computerized tomographic radiologic room, we believe that the near future will see an increasing participation of neuroimaging techniques in helping with anesthetic block procedures.<sup>2</sup> Moreover, the sciatic nerve is hidden behind the minor trochanter in a nonnegligible proportion of patients (> 10%) when we effect an anterior approach, independently of the rotation of the hip, and the risk of puncture of the femoral vessels exists.<sup>3,4</sup> The computerized tomography-guided approach should help to avoid risks.

We agree with Blumenthal *et al.* in that, with the current state of our knowledge, the best praxis would have been to withdraw the catheter. This was what we did in the second patient reported. In the first patient, however, we were not aware of the intraneural puncture and anesthetic administration because the images were analyzed off-line.

The structure of the nerve trunk is complex (fig. 1). Basically, the nerves run along different body compartments surrounded by tissues with their own fascia. These fascias, which are not part of the nerve, are the “recommended points” for injection to avoid nerve damage—or, that is what we thought. Inside the nerve trunk, the axons, en-



**Fig. 1.** Schematic drawing of the peripheral nerve sheaths. The nerve fibers are arranged in bundles (fascicles) that are embedded in loose connective tissue, the epineurium. The perineurium is the dense, lamellated, fibrous sheath that surrounds the fascicles containing the nerve fibers. Although injection into the perineurium could lead to neurologic damage,<sup>12</sup> this is less likely with injection into the epineurium sheath.<sup>1,11</sup>

wrapped by the endoneurium, are grouped in fascicles surrounded by the perineurium, a relatively resistant membrane that is difficult to puncture because of its elasticity, mobility, and adaptability to external forces. The fascicles are embedded within the epineurium, which is surrounded by a thicker membrane, the epineurium sheath. The

epineurium is a slack collagen and fatty tissue, which contains the vasa and nervi nervorum.<sup>5-8</sup> Most of the nerve section (between 30–75%) is occupied by nonneural structures.<sup>5,9</sup> The sciatic nerve produces abundant epineurium, which covers between 72 and 78% of the nervous section.<sup>10</sup>

Intraepineural injection of anesthetic would not necessarily lead to nerve damage.<sup>11</sup> On the contrary, intrafascicular injection is more likely to induce nerve lesions.<sup>12</sup> However, because of their elastic properties, the fascicles probably separate from each other and get out of the way if a needle penetrates the nerve trunk. Although direct neural tissue lesion is unlikely, it should be taken into account that intraepineural injection of a substance can cause an increase in neural pressure and secondary damage because of compression or a vascular lesion.

Clinical experience supports neurostimulation as a safe and effective technique with minimal incidence of nerve lesions. However, a large number of unresolved questions stemming out from our observations remain: How often does intraepineural injection occur in routine practice? Does it occur preferentially in certain nerves? What are the clinical and radiologic signs suggesting intraneural puncture? What is the safe threshold for electrical near-nerve stimulation?

**Xavier Sala-Blanch, M.D.,\* Jaume Pomés, M.D., Purificación Matute, M.D., Josep Valls-Solé, M.D., Anna Carrera, M.D., Xavier Tomás, M.D., Anna I. García-Diez, M.D.** \* Hospital Clínic, Barcelona, Spain. xsala@clinic.ub.es

## References

1. Sala-Blanch X, Pomes J, Matute P, Valls-Sole J, Carrera A, Tomas X, Garcia-Diez AI: Intraneural injection during anterior approach for sciatic nerve block. *ANESTHESIOLOGY* 2004; 101:1027-30

2. Sala-Blanch X, De Andrés J: Image-guided techniques for peripheral nerve blocks. *Curr Opin Anesthesiol* 2004; 17:409-15
3. Moore CS, Sheppard D, Wildsmith JA: Thigh rotation and the anterior approach to the sciatic nerve: A magnetic resonance imaging study. *Reg Anesth Pain Med* 2004; 29:32-5
4. Vloka JD, Hadzic A, April E, Thys DM: Anterior approach to the sciatic nerve block: The effects of leg rotation. *Anesth Analg* 2001; 92:460-2
5. Reina MA, Lopez A, De Andres JA: Adipose tissue within peripheral nerves: Study of the human sciatic nerve [in Spanish]. *Rev Esp Anesthesiol Reanim* 2002; 49:397-402
6. Reina MA, Lopez A, De Andres JA, Maches F: Possibility of nerve lesions related to peripheral nerve blocks: A study of the human sciatic nerve using different needles [in Spanish]. *Rev Esp Anesthesiol Reanim* 2003; 50:274-83
7. Reina MA, Lopez A, Villanueva MC, De Andres JA, Maches F: The blood-nerve barrier in peripheral nerves [in Spanish]. *Rev Esp Anesthesiol Reanim* 2003; 50:80-6
8. Reina MA, Lopez A, Villanueva MC, De Andres JA, León GI: Morfología de los nervios periféricos, de sus cubiertas y de su vascularización. *Rev Esp Anesthesiol Reanim* 2000; 47:464-75
9. Sunderland S: The connective tissues of peripheral nerves. *Brain* 1965; 88:841-54
10. Sunderland S, Bradley KC: The cross-sectional area of peripheral nerve trunks devoted to nerve fibres. *Brain* 1949; 72:428-49
11. Vloka JD, Hadzic A, Lesser JB, Kitain E, Geatz H, April EW, Thys DM: A common epineural sheath for the nerves in the popliteal fossa and its possible implications for sciatic nerve block. *Anesth Analg* 1997; 84:387-90
12. Hadzic A, Dilberovic F, Shah S, Kulenovic A, Kapur E, Zacicragic A, Cosovic E, Vuckovic I, Divanovic KA, Mornjakovic Z, Thys DM, Santos AC: Combination of intraneural injection and high injection pressure leads to fascicular injury and neurologic deficits in dogs. *Reg Anesth Pain Med* 2004; 29:417-23

(Accepted for publication February 17, 2005.)

Anesthesiology 2005; 102:1284

© 2005 American Society of Anesthesiologists, Inc. Lippincott Williams & Wilkins, Inc.

## Management of Anaphylactic Shock

*To the Editor:*—It was interesting to read the recent case report by Schummer *et al.*<sup>1</sup> regarding management of anaphylactic shock. The use of vasopressin in anaphylactic shock is commendable.

However, before the use of vasopressin, two steps in the management of anaphylactic shock must be addressed. First, the simple measure of elevating the lower limbs could have helped to increase the venous return with vasodilatation, thereby contributing to an increase in blood pressure. This measure is well recommended in the management of anaphylactic shock.<sup>2-4</sup>

Second, all colloids have been shown to produce clinical anaphylaxis. The overall incidence has been estimated to range between 0.033 and 0.22%.<sup>3</sup> The last French survey of anaphylaxis during anesthesia demonstrated that 2.95% of anaphylactic cases were due to colloids.<sup>3,5</sup> The incidence of anaphylaxis with succinylated gelatin solution (Gela-fusal®; Serumwerk Bernburg AG, Bernburg, Germany) is 0.34%, whereas with hydroxyethyl starch (HES), it is one sixth of this, *i.e.*, 0.06%.<sup>5</sup> HES seems to be the safest colloid, and the incidence of immunoglobulin G antibodies against HES is rare in the general population.<sup>6</sup> However, this does not betoken the absolute safety of HES. Isotonic crystalloids are the recommended fluids during anaphylaxis, and rapid infusion of 1-4 l may be required to compensate for the peripheral vasodilatation that often accompanies anaphylaxis. The American Heart Association (Dallas, Texas), in collaboration with the International Liaison Committee on Resuscitation (Antwerp, Belgium), has endorsed the use of isotonic crystalloids in anaphylactic shock.<sup>3,4</sup>

Although immediate discontinuation of the offending drug, Gela-fusal®, was justified,<sup>2,3</sup> we are skeptical of its replacement with other colloids with the potential, albeit low, for anaphylaxis. Patients might have developed anaphylaxis to HES, thereby obtunding the response to the conventional drugs, *via* epinephrine and steroids. Although the authors performed skin testing for gelatin, no skin or immunologic test

such as enzyme-linked immunosorbent assay for reactive antibodies to HES was performed to rule out its allergy.<sup>7</sup>

Last but not least, minimal invasive direct coronary artery bypass grafting does not preclude the possible use of cardiopulmonary bypass. Considering the recent warning by the US Food and Drug Administration (Rockville, Maryland) regarding use of HES for cardiopulmonary bypass, its use over crystalloids does not seem to be justified in this case.<sup>8</sup>

**Rajesh Mahajan, M.D.,\* Rahul Gupta, M.B.B.S.** \* Acharya Shri Chander College of Medical Sciences, Jammu, India. drmahajan@rediffmail.com, drmahajan@yahoo.com

## References

1. Schummer W, Schummer C, Wipermann J, Juergan F: Anaphylactic shock: Is vasopressin the drug of choice? *ANESTHESIOLOGY* 2004; 101:1025-7
2. Mertes PM, Laxenaire MC: Allergic reactions occurring during anaesthesia. *Eur J ANESTHESIOLOGY* 2002; 19:240-62
3. Hepner DL, Castells MC: Anaphylaxis during the perioperative period. *Anesth Analg* 2003; 97:1381-5
4. Guidelines 2000 for cardiopulmonary resuscitation and emergency cardiovascular care: An international consensus on science. *Circulation (supplement)* 2000; 102:1-241-3
5. Laxenaire MC, Mertes PM, Groupe d'Etudes des Reactions Anaphylactoides Peranesthesiques: Anaphylaxis during anaesthesia: Results of two year survey in France. *Br J Anaesth* 2001; 87:549-58
6. Kreimeier U, Christ F, Kraft D, Lauterjung I, Niklas M, Peter K, Messmer K: Anaphylaxis due to hydroxyethyl starch-reactive antibodies. *Lancet* 1995; 346: 49-50
7. Dieterich HJ, Kraft D, Sirtl C, Laubenthal H, Schimetta W, Polz W, Gerlach E, Peter K: Hydroxyethyl starch antibodies in humans: Incidence and clinical relevance. *Anesth Analg* 1998; 86:1123-6
8. Haynes GR, Havidich JE, Payne KJ: Why the food and drug administration changed the warning label of Hetastarch. *ANESTHESIOLOGY* 2004; 101:560-1

(Accepted for publication February 17, 2005.)

Anesthesiology 2005; 102:1285

© 2005 American Society of Anesthesiologists, Inc. Lippincott Williams &amp; Wilkins, Inc.

*In Reply:*—We thank Drs. Mahajan and Gupta for their interest in our case report and appreciate the opportunity to reply.

Drs. Mahajan and Gupta obviously believe in algorithms. However, the complexity and severity of anaphylaxis is such that no single algorithm can adequately treat all cases. Anaphylaxis is generally an unanticipated severe allergic reaction, often rapid in onset, and starts within seconds to minutes after exposure to the allergen. Symptoms progress rapidly, can affect most organ systems, and can lead to cardiovascular collapse and death, even when appropriately treated. The management of anaphylaxis consists of withdrawing the offending drug, interrupting the effects of the preformed mediators that were released in response to the antigen, and preventing more mediator release.

The intention of our case report was to adjoin a practicable method to the management of anaphylaxis by considering the application of vasopressin to standard therapy as an approach for mediator-induced vasodilatory shock and not to add on a discussion about the right colloid.<sup>1</sup>

Yes, effective fluid therapy is a mainstay of treating critically ill patients. The ideal kind of volume replacement in this situation remains a matter of debate. Despite an immense number of contributions to this problem, there is no answer yet. This topic is often discussed emotionally rather than scientifically. The ideal solution should not only maintain gross hemodynamics, but organ perfusion and microcirculation should also be guaranteed or even improved. To treat hypovolemia, in Germany, colloids are used more often than crystalloids. The lack of acceptance of synthetic colloids such as hydroxyethyl starch (HES) as a solution for volume replacement is most likely due to reports on abnormal coagulation function. This cannot be used as an argument when new, modern HES preparations with low molecular weights (70,000 or 200,000 Da) and a low degree of substitution (0.5) are used. This is the commonly used priming solution of the cardiopulmonary bypass machine at our institution.<sup>2,3</sup>

In clinical practice, with the given situation of a high-risk patient with cardiovascular disease, being placed on the operation table for minimally invasive direct coronary artery bypass grafting, elevation of the legs and head-down tilt is not a suitable therapeutic option. Infusion of up to 4 l of a crystalloid is time-consuming and might end in fluid overload.

There was no need for skin testing of HES because further infusions did not provoke anaphylactic reactions. Furthermore, the cause of adverse reactions due to HES is not yet clear. Major histamine release is not known to occur.<sup>4</sup> In a multicenter, prospective trial, 200,906 infusions of colloid volume substitutes have been examined. The frequency of severe reactions (shock, cardiac and/or respiratory arrest)

was 0.006% for HES.<sup>5</sup> HES-reactive antibodies are extremely rare, and they do not necessarily induce anaphylaxis.<sup>6</sup> Also, there is no known cross-reactivity between the different colloids, so a particular allergy to one should not preclude the use of a different colloid.<sup>7</sup>

Tachycardia, a common symptom in anaphylaxis, may have devastating consequences, especially in patients with cardiovascular disease, and should be terminated as soon as possible. High-dose epinephrine, administered with the intention to stabilize hemodynamics, may cause cardiac fibrillation, whereas vasopressin increases perfusion pressures and has an antitachycardic effect.<sup>8</sup>

Since the publication of our case report, we have gained more experience with the use of vasopressin in the management of anaphylactic shock beyond standard therapy. Administration of vasopressin, regardless of the causing agent (*e.g.*, antibiotics, nonsteroidal anti-inflammatory drugs), always stabilized hemodynamics quickly: The need for epinephrine reduced dramatically, and the heart rate normalized.

The management of anaphylactic shock must be immediate because time is running against the patient. Restoring cerebral and coronary perfusion quickly plays a pivotal role; therefore, one should consider the early addition of vasopressin complementary to standard therapy.

**Wolfram Schummer, M.D., D.E.A.A., E.D.I.C.,\* Claudia Schummer, M.D., Jens Wippermann, M.D., Juergen Fuchs, M.D.** \* Friedrich-Schiller-University Jena, Jena, Germany. cwschummer@gmx.de

## References

- Schummer W, Schummer C, Wippermann J, Fuchs J: Anaphylactic shock: Is vasopressin the drug of choice? *ANESTHESIOLOGY* 2004; 101:1025-7
- Kuitunen AH, Hynynen MJ, Vahtera E, Salmenperä MT: Hydroxyethyl starch as a priming solution for cardiopulmonary bypass impairs hemostasis after cardiac surgery. *Anesth Analg* 2004; 98:291-7
- Boldt J: New light on intravascular volume replacement regimens: What did we learn from the past three years? *Anesth Analg* 2003; 97:1595-604
- Bothner U, Georgieff M, Vogt NH: Assessment of the safety and tolerance of 6% hydroxyethyl starch (200/0.5) solution: A randomized, controlled epidemiology study. *Anesth Analg* 1998; 86:850-5
- Ring J, Messmer K: Incidence and severity of anaphylactoid reactions to colloid volume substitutes. *Lancet* 1977; 1:466-9
- Dieterich HJ, Kraft D, Sirtl C, Laubenthal H, Schimetta W, Polz W, Gerlach E, Peter K: Hydroxyethyl starch antibodies in humans: Incidence and clinical relevance. *Anesth Analg* 1998; 86:1123-6
- Hepner DL, Castells MC: Anaphylaxis during the perioperative period. *Anesth Analg* 2003; 97:1381-95
- Duffy BL, Harding JN, Fuller WR, Peake SL: Cardiac arrest following Haemaccel. *Anaesth Intensive Care* 1994; 22:90-2

(Accepted for publication February 17, 2005.)

Anesthesiology 2005; 102:1285-6

© 2005 American Society of Anesthesiologists, Inc. Lippincott Williams &amp; Wilkins, Inc.

## Bupivacaine Spinal Block Cauda Equina Syndrome: Why Did It Happen?

*To the Editor:*—I was excited when I read the title “Severe Neurological Complications after Central Neuraxial Blockades in Sweden 1990–1999.”<sup>1</sup> I expected that the article would broaden my knowledge in this important aspect of anesthesiology. Although the article was very good and I commend the authors for their work, I was disappointed in one respect. The most surprising and new observation was that the authors uncovered 11 cases of cauda equina syndrome (CES) associ-

ated with bupivacaine spinal anesthesia. This finding is both eye opening and discouraging. It is discouraging because of all the local anesthetics used for spinal anesthesia, bupivacaine seems to be the safest. This is supported by the fact that a literature search of the terms *cauda equina syndrome* and *bupivacaine* turned up only four case reports. Furthermore, *in vivo* and *in vitro* studies show limited bupivacaine neuronal toxicity. However, in the report by Moen *et al.*,<sup>1</sup> bupivacaine caused the greatest number of cases of CES associated with spinal anesthesia. This could be due to the fact that bupivacaine is indeed neurotoxic in certain clinical situations and surfaces as neurotoxic in this report by Moen *et al.*<sup>1</sup> because bupivacaine is more widely used for spinal anesthesia than are any of the other local

The above letter was sent to the author of the referenced Editorial View. The authors did not feel that a response was required.—Michael M. Todd, Editor-in-Chief



anesthetics. Alternatively, it was not the bupivacaine *per se* that caused the CES, but something associated with the performance of the spinal anesthesia or with patient selection.

Moen *et al.* report the following large groups of complications (in addition to other but fewer complications): 33 spinal hematomas, 32 cases of CES, and 29 cases of purulent meningitis. Although the authors allot approximately 1,200 words to spinal hematoma, they expend only 272 words on CES. Furthermore, the authors mention the cases of CES only in the results section and provide no insight in the discussion regarding the "process of care" that resulted in the 11 cases of bupivacaine CES or a possible etiology. It is easy to assume that CES in this study resulted from local anesthetic toxicity, but as the authors point out in their conclusion, "Spinal stenosis can by itself cause spontaneous paraplegia, but if preceded by [central neuraxial blockade], the blockade will most probably be blamed." My complaint is in keeping with the editorial that accompanied the article of Moen *et al.*, which states, "Behind the outcome is the process of care, and we must move from the question 'What happened?' to 'Why did it happen?'"<sup>2</sup> Thus, the authors missed an opportunity to report on the "process of care" that

resulted in previously unreported or underreported cases of bupivacaine CES of which they now hold the largest database.

It is not too late, however, and I would be pleased to have the authors provide more detail regarding the serious complication of the so-called bupivacaine CES. By informing us of the "process of care" or "what happened" in these cases, we may be able to prevent future occurrences.

**Donald H. Lambert, Ph.D., M.D.,** Boston Medical Center, Boston, Massachusetts. donlam@fastmail.us

## References

1. Moen V, Dahlgren N, Irestedt L: Severe neurological complications after central neuraxial blockades in Sweden 1990-1999. *ANESTHESIOLOGY* 2004; 101:950-9
2. Auroy Y, Benhamou D, Amaberti R: Risk assessment and control require analysis of both outcomes and process of care. *ANESTHESIOLOGY* 2004; 101:815-7

(Accepted for publication February 17, 2005.)

Anesthesiology 2005; 102:1286

© 2005 American Society of Anesthesiologists, Inc. Lippincott Williams & Wilkins, Inc.

## Why Do Orthopedic Patients Have a Higher Incidence of Serious Complications after Central Neuraxial Blockade?

*To the Editor:*—The authors should be congratulated on their comprehensive work "Severe Neurological Complications after Central Neuraxial Blockades in Sweden 1990-1999."<sup>1</sup> A variety of biases, which usually are inherent in such study designs, were successfully controlled. Considering previous data from the 1990s,<sup>2,3</sup> the current incidence of complications is alarmingly high, but it stands in line with most recent retrospective surveys.<sup>4,5</sup>

One question, however, deserves discussion. The authors described significantly higher incidence of spinal hematomas in the population of orthopedic patients, but the underlying causes remain partially unexplained. The authors presume that the high incidence may be related to low-molecular-weight heparin administration, which was introduced to thromboembolism prophylaxis during the study period.

In an 8-yr survey regarding serious complications after regional anesthesia at our institution,<sup>6</sup> we observed three spinal epidural hematomas in 28,933 central neuraxial blocks, of which two occurred in the subgroup of orthopedic patients (n = 4,205), indicating similar incidences and risk factors as reported by Moen *et al.*<sup>1</sup> One of the hematomas was previously reported elsewhere,<sup>7</sup> and the second one occurred after spinal anesthesia in a patient treated with unfractionated heparin. Both patients were concomitantly treated with nonsteroidal antiinflammatory drugs (NSAIDs), which were not considered a risk factor at that time. The third hematoma developed in a patient with heparin-induced thrombocytopenia during postoperative epidural pain therapy after hemihepatectomy. No hematoma occurred in urologic (n = 10,817) or obstetric (n = 4,250) patients.

The discussion about the risk of spinal hematoma in patients with NSAID (antiplatelet) therapy remains controversial. In orthopedic patients treated with aspirin, Horlocker *et al.*<sup>8</sup> did not observe an increased risk of spinal hematoma during spinal anesthesia. However, in 1984, Cronberg *et al.*<sup>9</sup> reported on the effects of NSAIDs on the second wave of aggregation, which was considered a key issue in our patient.<sup>7</sup> In urologic patients (no hematoma in 10,817 neuraxial blocks), the risk profile regarding comorbidity and comedication is comparable to that of orthopedic patients, with the exception of concomitant therapy with NSAIDs.

We believe that the combination of heparin and NSAIDs in orthopedic patients is responsible for the higher risk of spinal hematoma in this group as compared with obstetric patients.<sup>1</sup> Because pain therapy with NSAIDs is widespread in patients in need of (orthopedic) hip or knee joint replacement surgery, it would be of interest if the authors could provide any information regarding the concomitant use of NSAIDs in their cohort of orthopedic patients.

**Axel R. Heller, M.D., Ph.D. D.E.A.A.,\* Rainer J. Litz, M.D.**  
\* University Hospital Carl Gustav Carus, Dresden, Germany.  
heller-a@rcs.urz.tu-dresden.de

## References

1. Moen V, Dahlgren N, Irestedt L: Severe neurological complications after central neuraxial blockades in Sweden 1990-1999. *ANESTHESIOLOGY* 2004; 101:950-9
2. Wulf H: Epidural anaesthesia and spinal haematoma. *Can J Anaesth* 1996; 43:1260-71
3. Vandermeulen EP, Van Aken H, Vermeylen J: Anticoagulants and spinal-epidural anesthesia. *Anesth Analg* 1994; 79:1165-77
4. Horlocker TT, Wedel DJ: Spinal and epidural blockade and perioperative low molecular weight heparin: Smooth sailing on the Titanic. *Anesth Analg* 1998; 86:1153-6
5. Auroy Y, Narchi P, Messiah A, Litt L, Rouvier B, Samii K: Serious complications related to regional anesthesia: Results of a prospective survey in France. *ANESTHESIOLOGY* 1997; 87:479-86
6. Litz RJ, Groessle R, Wiessner D, Heller AR, Koch T: Incidence of cardiac arrests during regional anesthesia: An 8-year survey (abstract). *ANESTHESIOLOGY* 2004; 101(suppl):A-902
7. Litz RJ, Hubler M, Koch T, Albrecht DM: Spinal-epidural hematoma following epidural anesthesia in the presence of antiplatelet and heparin therapy. *ANESTHESIOLOGY* 2001; 95:1031-3
8. Horlocker TT, Wedel DJ, Schroeder DR, Rose SH, Elliott BA, McGregor DG, Wong GY: Preoperative antiplatelet therapy does not increase the risk of spinal hematoma associated with regional anesthesia. *Anesth Analg* 1995; 80:303-9
9. Cronberg S, Wallmark E, Soderberg I: Effect on platelet aggregation of oral administration of 10 non-steroidal analgesics to humans. *Scand J Haematol* 1984; 33:155-9

(Accepted for publication February 17, 2005.)

## Learning from Incidents and Near-misses Reports

*To the Editor:*—We strongly support reporting systems and therefore read with interest the Editorial View by Auroy *et al.*<sup>1</sup> However, before these methods become a standard audit or educational tool, some of their limitations must be considered further.

Clinicians can often select the type of adverse incident or outcome they will record. These tend to be those that are more severe, or those in accordance with individual perspectives of safety.<sup>2,3</sup> For example, prolonged paralysis after a regional block is more likely to be reported than transitory paresthesia. Temporary complications are often ignored, despite their potential educational value. Sometimes, reporters select those incidents most likely to carry a message to the organization's management.<sup>4</sup> Incidents over inappropriate waiting times for patients or surgeons are not exceptional in anesthetic incident-reporting systems. Such selection and reporting biases may seriously distort perception of safety problems in anesthesia.

When reporting systems focus on near misses (prevented or mitigated adverse events), another difficulty arises, one familiar to aviation safety experts: information overload.<sup>4</sup> A progressively larger amount of data is collected and stored to be further analyzed. It can become increasingly difficult and costly to classify and retrieve meaningful events in such an extensive system analysis.<sup>5</sup> Gradually limited by resources and complexity, experts may end up fixing near misses instead of addressing system errors concealed behind the data overload. This may jeopardize the didactic value of such events.

Finally, anesthetic and medical practices in general are largely controlled by a professional body of knowledge.<sup>6</sup> Organizational guidelines and standards are much less the norm than, for example, in

chemical or nuclear industries.<sup>7</sup> Variability in local practices, professional culture, and political context seriously challenge the generalizability of organizational analysis.

To address these problems, suggested approaches could include the use of international standardized definitions of incidents and the development of guided reporting through generic adverse event indicators. The specificities of the healthcare organization analyzed could also be more systematically described and addressed.

If limitations such as these are not well understood and properly addressed, case reports and root cause analyses of adverse incidents and near misses are likely to remain largely narrative and of limited educational value within the broader anesthetic community.

**Guy Haller, M.D.,\* Paul S. Myles, M.B., B.S., M.P.H., M.D., F.C.A.R.C.S.I., F.A.N.Z.C.A.** \* Alfred Hospital, Melbourne, Australia. [guy.haller@med.monash.edu.au](mailto:guy.haller@med.monash.edu.au)

### References

1. Auroy Y, Benhamou D, Amalberti R: Risk assessment and control require analysis of both outcomes and process of care. *ANESTHESIOLOGY* 2004; 101:815–7
2. Stanhope N, Crowley-Murphy M, Vincent C, O'Connor AM, Taylor-Adams SE: An evaluation of adverse incident reporting. *J Eval Clin Pract* 1999; 5:5–12
3. Vincent C, Stanhope N, Crowley-Murphy M: Reasons for not reporting adverse incidents: An empirical study. *J Eval Clin Pract* 1999; 5:13–21
4. Amalberti R: Revisiting safety paradigms to meet the safety challenges of ultra complex and safety systems, *System Safety: Challenges and Pitfalls of Intervention*, 1st edition. Edited by Wilpert B, Fahlbruch B. Amsterdam, Pergamon Publishers, 2002, pp 265–76
5. Johnson CW: How will we get the data and what will we do with it then? Issues in the reporting of adverse healthcare events. *Qual Saf Health Care* 2003; 12 (suppl 2):ii64–7
6. Shortell SM, Kaluzny AD: *Health Care Management: Organization, Design, and Behavior*, 4th edition. Albany, New York, Delmar Publishers, 2000, pp 12–3
7. Glouberman S, Mintzberg H: Managing the care of health and the cure of disease: II. Integration. *Health Care Manage Rev* 2001; 26:70–84

(Accepted for publication February 17, 2005.)

The above letter was sent to the author of the referenced Editorial View. The authors did not feel that a response was required.—Michael M. Todd, Editor-in-Chief

Supported by the Swiss National Science Foundation, the Count Eugenio Litta Foundation, a Monash University Postgraduate Research Scholarship (to Dr. Haller), and an Australian National Health and Medical Research Council Practitioner's Fellowship (to Dr. Myles).

*In Reply:*—We thank Dr. Lambert for his interest in our study, which was performed primarily to investigate the incidence of severe complications after central neuraxial blockades.<sup>1</sup> The strength of our study is the comprehensive study design and the large number of cases recorded. The limitation, common to most retrospective studies, is the relative lack of detail. Before attempting to answer the ultimate question of “why does it happen,” we set out to answer the question of “does it happen,” because the causal relation between central blockades and complications has been questioned, even recently.<sup>2</sup> Our data were subsequently analyzed to answer the question “to whom does it happen.” This is a straightforward epidemiologic approach that can produce some but not all of the answers.

We share Dr. Lambert's preoccupation regarding the high number of patients with cauda equina syndrome.

This patient group is heterogenous, regarding both type of blockade and patient characteristics and, most importantly, probably also regarding pathophysiology of the complication. To attempt a better understanding of the different pathogenetic processes, we grouped nine of the patients with cauda equina syndrome and the four patients with paraparesis, because they were all found to have spinal stenosis (table 5 in the article).<sup>1</sup> Most of these patients were older than 70 yr, and nine

had received epidural blockade or combined spinal epidural blockade. Compression was thought to have an important role in the development of the complication in these patients. The proposed pathogenetic process is demonstrated by a recent case report of transient paraplegia during epidural infusion in an elderly woman with severe kyphosis.<sup>3</sup> This case report included a magnetic resonance image showing cord compression caused by epidural infusion: Remarkably, the neurologic deficit spontaneously receded shortly after the infusion was stopped, thus illustrating the possibility of creating high epidural pressure with epidural pump infusion in subjects with restriction of the spinal canal and with outflow obstruction. Also, during spinal anesthesia in a patient with spinal stenosis, maldistribution of local anesthetic in the subarachnoid space could cause higher concentration, thus favoring neurotoxic processes.

In our study, a remaining 23 patients experienced cauda equina syndrome in the absence of spinal stenosis. Single-shot spinal blockade had been given to 15 of these patients, and in 1 additional patient, a spinal catheter was placed. These patients were younger, half of them being younger than 55 yr. Lidocaine had been used in seven cases, bupivacaine had been used in five cases, and a combination of both drugs had been used in one case. No information was obtained in three

cases. Roughly twice as many ampoules of bupivacaine were sold during the study period, indicating a higher incidence of cauda equina syndrome after spinal anesthesia with lidocaine. The fact that half of the spinal blockades were reported as technically difficult or resulting in unsatisfactory anesthesia could indicate uneven distribution of local anesthetic within the spinal canal, causing localized high concentrations resulting in neurotoxicity. The pathogenetic processes, however, might vary: The diagnosis of arachnoiditis was made in two patients, and in one further patient, an elderly man, severe hypotension during surgery was believed to be at least partially responsible for the complication.

Cauda equina syndrome occurred after spinal blockade in roughly 1:100,000 of our patients. This is unpleasant information, because our data do not permit us to provide a better understanding of the pathophysiologic processes. However, we would like to point out that although case reports may yield important information, they should not be used as indication of incidence. One of our main results is in fact the demonstration of discrepancy between calculations of incidence based on case reports or research in larger but still limited sources and the incidences in our study, obtained with a more comprehensive research.

Drs. Heller and Litz raise the question of the role of nonsteroidal antiinflammatory drug (NSAIDs) in the development of spinal hematoma. In our study, only 4 of the 13 orthopedic patients with spinal hematoma were reported to have received NSAIDs, and a further 2 patients received low-dose acetyl salicylic acid, including one patient receiving steroid therapy. However, underreporting can be presumed. The respondents in the enquiry were asked to provide as much information as possible regarding the patients' pathology and medication. Because the association of low-molecular-weight heparin and spinal hematoma was much debated, we can assume that the information regarding these drugs is more reliable than is the case with NSAIDs.

Drs. Heller and Litz partially misinterpret our conclusions regarding the higher incidence of spinal hematoma among the orthopedic patients. We do not propose that this is exclusively related to the administration of low-molecular-weight heparin; on the contrary, we propose that spinal pathology is also an important factor, as well as bleeding disorders and medications interfering with coagulation. Also, in the aged spine, any space occupying mass causes cord compression at an earlier stage as compared with the younger spine.

The development of a symptomatic spinal hematoma is probably a multifactorial event, and NSAIDs, alone or in combination with throm-

boprophylaxis, might be one of these factors. Patients with spinal and vascular pathology might be more susceptible to alterations of platelet function. However, the opinion that NSAIDs are mainly responsible for the development of spinal hematoma in these patients could induce an ungrounded belief that epidural blockades are safe in orthopedic patients, permitted they refrain from taking NSAIDs. This solution seems too simplistic. Many data now indicate a high risk among orthopedic patients for spinal hematoma, particularly after epidural blockade. The use of epidural blockade for hip or knee replacement should be questioned because the risk seems out of proportion to the benefit.<sup>4</sup>

Drs. Heller and Litz interestingly refer to three cases of spinal hematomas in their institution. However large and impressive, the total of 28,933 central neuraxial blockades does not permit reliable calculation of incidences, because spinal and obstetric anesthesia are included. The urologic patients, although of similar age to the orthopedic patients, include fewer females and usually, at least at our institutions, more often receive spinal blockade. These facts alone prevent any physiopathologic comparison between the two patient groups.<sup>5,6</sup>

**Vibeke Moen, M.D.,\* Nils Dahlgren, M.D., Ph.D., Lars Irestedt, M.D., Ph.D.** \* County Hospital, Kalmar, Sweden.  
vibekem@ltkalmars.se

## References

1. Moen V, Dahlgren N, Irestedt L: Severe neurological complications after central neuraxial blockades in Sweden 1990–1999. *ANESTHESIOLOGY* 2004; 101: 950–9
2. Wheatley RG, Schug SA, Watson D: Safety and efficacy of postoperative epidural analgesia. *Br J Anaesth* 2001; 87:47–61
3. Jacob A, Borowiec J, Long TR, Brown MJ, Rydberg CH, Wass CT: Transient profound neurologic deficit associated with thoracic epidural analgesia in an elderly patient. *ANESTHESIOLOGY* 2004; 101:1470–1
4. Choi PT, Bhandari M, Scott J, Douketis J: Epidural analgesia for pain relief following hip or knee replacement. *Cochrane Pain, Palliative Care and Supportive Care Group Cochrane Database of Systematic Reviews* 2004; 4
5. Lee LA, Posner KL, Domino KB, Caplan RA, Cheney FW: Injuries associated with regional anesthesia in the 1980s and 1990s: A closed claims analysis. *ANESTHESIOLOGY* 2004; 101:143–52
6. Auroy Y, Benhamou D, Bargues L, Ecoffey C, Falissard B, Mercier FJ, Bouaziz H, Saamii K, Mercier F: Major complications of regional anesthesia in France: The SOS Regional Anesthesia Hotline Service. *ANESTHESIOLOGY* 2002; 97:1274–80

(Accepted for publication February 17, 2005.)

## Stellate Ganglion Blockade for Acute Postoperative Upper Extremity Pain

*To the Editor:*—We read with interest the review article by Dr. Reuben entitled “Preventing the Development of Complex Regional Pain Syndrome after Surgery.”<sup>1</sup> The author mentioned that in his practice, he administers a stellate ganglion block to patients with a history of complex regional pain syndrome (CRPS) undergoing upper extremity surgical procedures in an effort to prevent its recurrence. Although the literature supports this practice, the efficacy of a stellate ganglion block has broader applications to patients *without* a history of CRPS. No study has examined its use in the acute postoperative setting. Nevertheless, we report the first case using a stellate ganglion block to treat acute postoperative pain successfully in a patient without a history of CRPS who underwent an open reduction and internal fixation of his left humerus.

A 46-yr-old, 70-kg male with a medical history significant for recent cocaine abuse underwent general anesthesia for an open reduction and

internal fixation of a left humerus fracture. The 3-h intraoperative course was uneventful during a 3% desflurane in 50% nitrous and oxygen anesthetic. Fentanyl, 500 µg, and 5 mg morphine were also given intraoperatively. In the postanesthesia care unit, an additional 20 mg morphine was titrated for pain relief, although to no avail: The patient's pain score remained 10 out of 10. On further evaluation, his left upper extremity appeared cold, clammy, and edematous, whereas the pain characteristic was described as burning.

After informed consent, a left stellate ganglion block was performed using 10 ml bupivacaine, 0.25%, with a sterile technique. Pain relief (0 out of 10) was achieved 5 min after injection. Evidence of successful blockade included ptosis and miosis, temperature increase in the ipsilateral extremity, and an increase in perfusion index.

Numerous publications in the literature support the use of a stellate ganglion block for chronic sympathetically mediated pain; however, to the best of our knowledge, we report the first case in which a stellate ganglion block was used in the acute postoperative setting. Furthermore, the success of the block in absence of a history of CRPS illustrates primary prevention—interventions to prevent a disease from

David C. Warltier, M.D., Ph.D., acted as Handling Editor for this Correspondence.



occurring. Activation of the sympathetic pain pathways could have taken place before the patient's operating room visit or even intraoperatively. Nevertheless, the challenge is to recognize the clinical symptoms that differentiate acute CRPS from postsurgical pain, despite the close resemblance.<sup>2</sup> Further review of the case revealed that the patient's fracture was a week old, which may have contributed to an alteration of central nociceptive processing pathways, thus increasing his risk for development of postsurgical CRPS.<sup>3</sup> Overall, we share the same enthusiasm of Dr. Ruben on regional anesthetic techniques to prevent the occurrence of CRPS. In our clinical practice, it is not only important to focus on CRPS prevention, but also to understand the pathophysiology so that we know which patients are at greatest risk.

Anesthesiology 2005; 102:1289

*In Reply:*—I appreciate the comments by Drs. Kakazu and Julka. Although the role of the sympathetic nervous system in certain chronic pain states, including complex regional pain syndrome (CRPS), has been well documented,<sup>1,2</sup> its role in acute pain and inflammation is still controversial.<sup>3,4</sup> A coupling between the sensory afferent and sympathetic efferent system after peripheral nerve lesions has been previously described as a causative mechanism for neuropathic pain, including CRPS.<sup>1,2</sup> However, the role of the sympathetic nervous system in acute pain still must be elucidated. The sympathetic nervous system may influence the nociceptive response to acute tissue injury in two ways.<sup>4</sup> First, there is a potentiation of the chemical mediator cascade after trauma as well as augmentation of sensitization to substance P. Second, norepinephrine and  $\alpha_2$  agonism in the dorsal horn neurons and in the locus ceruleus in the medulla play a major role in the descending medullospinal inhibition of nociception. Experimental studies in rats indicate that sympathetic postganglionic neurons may be involved in the generation of pain, hyperalgesia, and inflammation after tissue damage or trauma.<sup>5,6</sup> Sensitization of nociceptive afferent fibers in the knee joints of rats involves a cascade of events in which the mast cell and the sympathetic terminal are sequentially activated, resulting in plasma extravasation in the synovium.<sup>5,6</sup> Further, adrenal medullary-derived epinephrine can exacerbate and surgical or pharmacologic sympathectomy can decrease the severity of experimental arthritis.<sup>5</sup> Although these behavioral studies in rats point to a potential role of the sympathetic nervous system in acute inflammatory pain, neurophysiologic studies of nociceptors in rats and psychophysical studies in humans have failed to provide confirmatory evidence for the role of sympathetic efferents in inflammatory pain and hyperalgesia.<sup>3</sup>

The use of a stellate ganglion block for acute postoperative pain as described by Drs. Kakazu and Julka is intriguing. I agree with the authors that because this patient sustained his fracture 1 week before surgical correction, prolonged sensitization and alteration of nociceptive afferent pathways may have increased the risk for the development of postsurgical CRPS. However, the authors did not report whether this patient had any clinical symptoms consistent with CRPS before surgical intervention. Perhaps the surgical intervention exacerbated an underlying disease process that may have been initiated before surgery. Interestingly, since the success of our original report on the efficacy of stellate ganglion blocks for CRPS patients undergoing surgery,<sup>7</sup> many of our surgeons now request that we routinely perform this sympathetic block for non-CRPS patients who are undergoing

David C. Wartier, M.D., Ph.D., acted as Handling Editor for this Correspondence.

Clinton Z. Kakazu, M.D.,\* Inderjeet Julka, M.D. \* Harbor-UCLA Medical Center, Torrance, California. ckakazu@hotmail.com

## References

1. Reuben SS: Preventing the development of complex regional pain syndrome after surgery. *ANESTHESIOLOGY* 2004; 101:1215-24
2. Birklein F, Kunzel W, Sieweke N: Despite clinical similarities there are significant differences between acute limb trauma and complex regional pain syndrome I (CRPS I). *Pain* 2001; 93:165-71
3. Gracely RH, Lynch SA, Bennett GJ: Painful neuropathy: Altered central processing maintained dynamically by peripheral input. *Pain* 1992; 51:175-94

(Accepted for publication February 23, 2005.)

© 2005 American Society of Anesthesiologists, Inc. Lippincott Williams & Wilkins, Inc.

surgical procedures and are at increased risk for development of this disease. Although stellate ganglion block may be effective for treating acute postoperative neuropathic pain, it may also be useful in the management of acute nociceptive pain. Matsuura *et al.*<sup>8</sup> describe the efficacy of stellate ganglion block in 29 patients undergoing ocular surgery. These authors report a significant reduction in postoperative pain and nonsteroidal antiinflammatory drugs with the use of stellate ganglion block. These case studies highlight the importance of moving from symptom control toward a mechanism-specific pharmacologic management of postoperative pain.<sup>9</sup> We have only begun to identify the multiple neurobiologic mechanisms responsible for different pain states. We hope to be able to develop diagnostic tools that will allow us to identify these mechanisms in individual patients and target them with appropriate analgesic interventions. Future research is needed in defining the clinical significance of the interaction of the sympathetic nervous system and the somatic afferent system in the development of postoperative pain. At that time, we may have available not only the resources for eliminating acute pain but also the tools necessary for preventing the occurrence of chronic postsurgical pain.

Scott S. Reuben, M.D., Baystate Medical Center and the Tufts University School of Medicine, Springfield, Massachusetts. scott.reuben@bhs.org

## References

1. Jänig W: The puzzle of "reflex sympathetic dystrophy": Mechanisms, hypotheses, open questions, Reflex Sympathetic Dystrophy: A Reappraisal. Edited by Stanton-Hicks M, Jänig W. Seattle, IASP Press, 1997, pp 1-24
2. Baron R: Peripheral neuropathic pain: From mechanisms to symptoms. *Clin J Pain* 2000; 16:S12-20
3. Raja SN: Role of the sympathetic nervous system in acute pain and inflammation. *Ann Med* 1995; 27:241-6
4. Forrest JB: Sympathetic mechanisms in postoperative pain. *Can J Anaesth* 1992; 39:523-7
5. Basbaum AI, Levine JD: The contribution of the nervous system to inflammatory and inflammatory disease. *Can J Physiol Pharmacol* 1991; 69:647-51
6. Jänig W, Levine JD, Michaelis M: Interactions of sympathetic and primary afferent neurons following nerve injury and tissue trauma. *Prog Brain Res* 1996; 113:161-84
7. Reuben SS, Rosenthal EA, Steinberg RB: Surgery on the affected upper extremity of patients with a history of complex regional pain syndrome: A retrospective study of 100 patients. *J Hand Surg* 2000; 25:1147-51
8. Matsuura M, Matsuura M, Ando F, Sahashi K, Torii Y, Hirose H: The effect of stellate ganglion block on prolonged post-operative ocular pain. *Nippon Ganka Gakkai Zasshi* 2003; 107:607-12
9. Woolf CJ: Pain: Moving from symptom control toward mechanism-specific pharmacologic management. *Ann Intern Med* 2004; 140:441-51

(Accepted for publication February 23, 2005.)

## Air Venting and In-line Intravenous Fluid Warming for Pediatrics

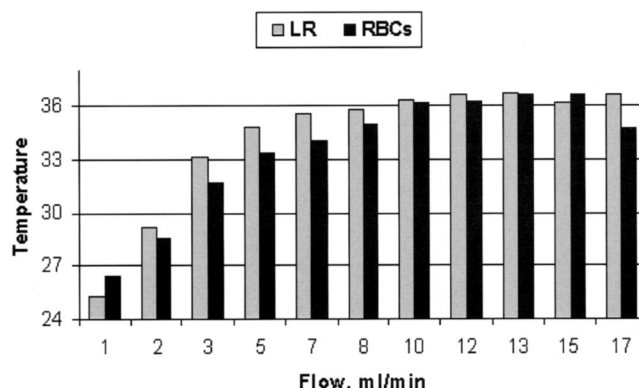
*To the Editor:*—It is important to have suitable fluid warmers for pediatric anesthesia, especially in hypovolemic neonates and infants who require boluses of isotonic crystalloid, packed erythrocytes, or both given over 5–20 min. The purpose of this study was to evaluate the fluid warming and air venting capability of a new device (buddy fluid warmer; Belmont Instrument Corp., Billerica, MA) designed for use in pediatrics. With this device, fluids are heated to 38°C as they pass through a disposable set containing microporous membranes able to vent air. Air is released through the side vents of the set. The small heating unit and disposable set are placed in-line near the patient at the intravenous infusion site and can be used easily with volumetric infusion pumps.

Fluids tested were lactated Ringer's solution, 1 l, at room temperature, and refrigerated, outdated erythrocytes diluted with 100 ml saline, 0.9%. The estimated hematocrit was 50%. Standard or Y-type blood solution sets were attached proximal to the commercial microheater disposable set (priming volume, 4 ml), which was connected to a 12.7 cm T connector (total volume, 0.4 ml). A rapid response thermocouple (Fluke 51 II; Fluke Corp., Everett, WA; accuracy,  $\pm 0.05\%$ ) was used to measure distal temperature at the point at which the T connector would be attached to the intravenous line. Temperature data were collected at 5-ml intervals for flows of 8 ml/min or greater and at 10-s intervals for slower flows. A volumetric infusion pump was used to regulate flow between 50 and 1,000 ml/h. For gravity-free flow, lactated Ringer's solution was infused from a height of 1.8 m into a cylindrical scored beaker, and measurements were made every 50 ml. Pressure-driven flow was not used, per manufacturer guidelines.

A three-way stopcock with a 0.8 m extension was inserted proximal to the microheater, and a 22-gauge Angiocath (Becton Dickinson, Sandy, UT) was attached to the T connector distally. The Angiocath was submerged in a liquid-filled beaker for crystalloid infusion and attached to a cell salvage waste system for erythrocytes. Without the fluid warmer disposable set, injection of as little as 1 ml of air was readily visible in the liquid-filled beaker with submerged Angiocath. Aliquots of 5, 10, 20, 30, 40, 50, and 60 ml of air were rapidly injected into the stopcock toward the patient infusion site, followed by resumption of fluid flow. Visual inspection for air bubbles distal to the warmer was performed by two observers. Tests were repeated twice for each condition and fluid.

Distal temperatures are summarized in figure 1. Air bubbles were not

Supported by the Department of Anesthesiology, MetroHealth Medical Center, Cleveland, Ohio. Belmont Instrument Corporation, Billerica, Massachusetts, loaned the buddy fluid warmer and donated the microheater disposables.



**Fig. 1.** Distal temperature ( $^{\circ}\text{C}$ ) of lactated Ringer's solution (LR) and erythrocytes (RBC) at the point where fluid would enter the patient. Proximal erythrocyte temperature was (mean  $\pm$  SD)  $16.5 \pm 2^{\circ}\text{C}$ . Proximal crystalloid temperature was  $19.2 \pm 1.2^{\circ}\text{C}$ . Gravity flow from a height of 6 feet was  $68 \pm 10$  ml/min, and distal temperature was  $37.8^{\circ}\text{C}$ . A minimum of 40 measurements were made for each flow (total of 1,216 measures).

seen in the T connector or in the liquid-filled beaker for any value of injected air.

The buddy fluid warmer was effective in delivering warm intravenous fluids at flows of 7 ml/min or greater. At the slowest flows, infusate temperature decreased, likely resulting from significant heat loss distal to the warmer. Venting of air by the fluid warmer is of great advantage to pediatric patients with congenital heart disease. Moreover, use of this warming device might theoretically reduce the risk of accidental infusion of air during crystalloid and blood resuscitation of children with hypovolemic shock. The manufacturer's list price for the buddy fluid warmer is \$1,599.00; the disposable set is \$14.99.

The authors thank Jeanne Javor, M.T. (A.S.C.P.), S.B.B. (Blood Bank Supervisor, MetroHealth Medical Center, Cleveland, Ohio), for providing outdated erythrocytes and hematocrit estimates; Richard Kramer, C.P.P. (Division of Cardiothoracic Surgery, MetroHealth Medical Center), for useful suggestions; and Denise Kosty Sweeney, R.N., M.S.N. (Administrative Nurse Manager, General Clinical Research Center, MetroHealth Medical Center), for the loan of a stopwatch and beaker.

**Ramachandra R. Avula, M.D., Charles E. Smith, M.D., F.R.C.P.C.\*** \* MetroHealth Medical Center, Case Western Reserve University, Cleveland, Ohio. csmith@metrohealth.org

(Accepted for publication January 11, 2005.)

## Using the Bonfils Intubation Fiberscope with a Double-lumen Tracheal Tube

*To the Editor:*—Several surgical procedures require single-lung ventilation. Because a double-lumen tube (DLT) allows for independent ventilation therapy (e.g., continuous positive airway pressure), suctioning, and bronchoscopy of each lung, the DLT is the accepted standard for the treatment of patients undergoing thoracic surgery.<sup>1</sup> A difficult

intubation in this subset of patients is particularly challenging because tube insertion is impeded by the special shape of the DLT and the two separate cuffs, which can be damaged by the patient's teeth and during repeated insertion maneuvers using intubation tools with sharp surfaces.

Recently, in two patients scheduled to undergo a minimally invasive direct coronary artery bypass procedure requiring DLT insertion, direct laryngoscopy failed. Because at our institution the Bonfils intubation fiberscope (Karl Storz GmbH, Tuttlingen, Germany), a rigid fiber-

Support was provided solely from institutional and/or departmental sources. The Bonfils intubation fiberscope was supplied by Karl Storz GmbH, Tuttlingen, Germany.

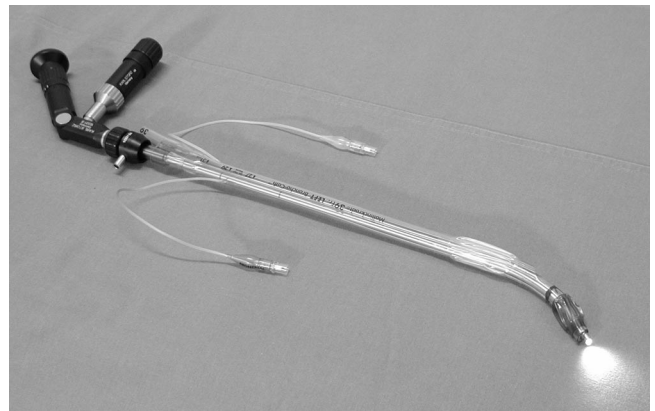


scope with a curved tip, is routinely used for managing unexpected as well as anticipated difficult airways,<sup>2,3</sup> we decided to use the device to aid in DLT placement. The Bonfils intubation fiberscope has a length of approximately 40 cm and an OD of 5 mm. According to the manufacturer, tracheal tubes with an ID of 5.5 mm or greater and a length of 39 cm or less may be used. The length of the DLTs (including tube connector) used in our cases is approximately 42 cm, and the largest ID of the bronchial lumen is approximately 5.1 mm (37 French) and 5.3 mm (39 French), respectively. Usually, the tube is too long for insertion of a Bonfils intubation fiberscope. After shortening both the tracheal and the bronchial connectors to a complete length of 38.5 cm and after ensuring adequate lubrication of the scope with silicone spray, however, the tube's bronchial lumen was mounted on the scope easily (fig. 1). Shortening of the proximal connectors did not prevent connecting them to the endotracheal tube adapter and subsequently to the right angle adapter attached to the breathing circuit.

Using the Bonfils intubation fiberscope, the patient's mouth is opened, and the scope inserted from the right side of the mouth along the molars after the patient's head is adjusted in a neutral position. With the insertion of the device, the anesthesiologist performs a jaw-thrust maneuver with his or her left hand to enhance the retropharyngeal space. After this, guided by the right hand, the Bonfils intubation fiberscope is advanced in the glottic aperture. The tube is then released from the scope with the left hand (or by an assistant) and inserted into the trachea under direct visualization. Sometimes, performing simultaneous laryngoscopy with a conventional Macintosh blade by a second anesthesiologist may be helpful to lift up a large tongue impeding advancement of the fiberscope. Finally, the correct position of the tube must be verified with a fiberoptic bronchoscope, because the rigid Bonfils intubation fiberscope should not be advanced in the trachea.

In the two cases denoted, the Bonfils intubation fiberscope was an effective tool for placing a DLT. The time to intubation was clinically acceptable, and no damage occurred with respect to the patient's teeth or soft tissues. Importantly, the cuffs were intact after placement despite a very desolate set of teeth in one patient. The right-sided insertion approach of the scope along the molars may be advantageous in such cases, because touching the front teeth is avoided, and molars are not as sharp-edged as the anterior and canine teeth.

Few intubation tools are suitable for DLT placement. The fiberoptic bronchoscope, which has evolved as an accepted standard for management of the difficult airway,<sup>4</sup> may not be suitable for oral DLT insertion. The limited ID of the bronchial lumen of the DLT only allows use of a relatively small fiberoptic bronchoscope, and elastic orpha-



**Fig. 1.** Bonfils intubation fiberscope mounted with a 39-French left-sided double-lumen tube (Bronchocath; Mallinckrodt Medical, Athlone, Ireland). The tube connectors have been shortened to the appropriate length. Light source is powered by a battery handle.

ryngeal soft tissues, especially a large tongue, may prevent successful passage through the mouth. In conclusion, the Bonfils intubation fiberscope may be used with DLTs of 37 French or greater after appropriate tube shortening in patients with a difficult airway anatomy.

**Berthold Bein, M.D.,\* Dorothee Caliebe, M.D., Thomas Römer, M.D., Jens Scholz, M.D., Volker Dörge, M.D.** \* University Hospital Schleswig-Holstein, Campus Kiel, Germany. [bein@anaesthesie.uni-kiel.de](mailto:bein@anaesthesie.uni-kiel.de)

## References

1. Lewis JW Jr, Serwin JP, Gabriel FS, Bastanfar M, Jacobsen G: The utility of a double-lumen tube for one-lung ventilation in a variety of noncardiac thoracic surgical procedures. *J Cardiothorac Vasc Anesth* 1992; 6:705-10
2. Bein B, Yan M, Tonner PH, Scholz J, Steinfath M, Dörge V: Tracheal intubation using the Bonfils intubation fiberscope after failed direct laryngoscopy. *Anaesthesia* 2004; 59:1207-9
3. Bein B, Worthmann F, Scholz J, Brinkmann F, Tonner PH, Steinfath M, Dörge V: A comparison of the intubating laryngeal mask airway and the Bonfils intubation fibrescope in patients with predicted difficult airways. *Anaesthesia* 2004; 59:668-74
4. Benumof JL: Management of the difficult adult airway: With special emphasis on awake tracheal intubation. *ANESTHESIOLOGY* 1991; 75:1087-110

(Accepted for publication January 11, 2005.)

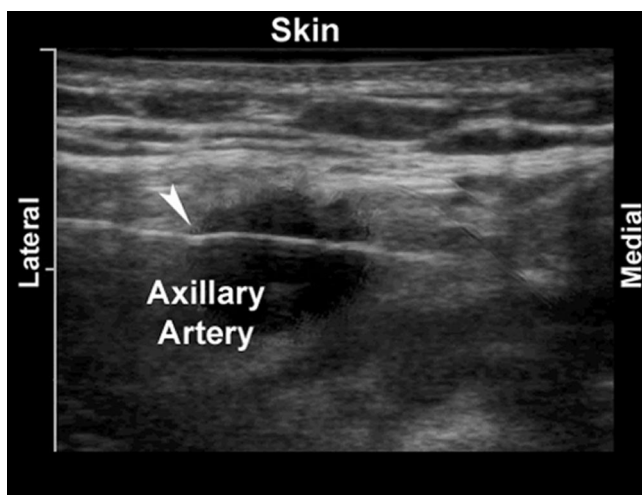## “Bayonet Artifact” during Ultrasound-guided Transarterial Axillary Block

*To the Editor:*—Ultrasound-guided regional anesthesia is an emerging field that potentially provides better block efficacy than other current techniques.<sup>1-3</sup> In particular, ultrasound-guided axillary block had been described as an excellent technique for brachial plexus anesthesia.<sup>4,5</sup> With this method, a short axis (transverse cross-sectional) view of the axillary artery and surrounding nerves is obtained with the block needle approaching from the lateral aspect of the arm in the plane of imaging. Although V-shaped redirection of the block needle can be used to place local anesthetic on the superficial and deep sides of the axillary artery, transarterial placement of the needle may occur during the procedure.

During an ultrasound-guided axillary block, we observed a bent echo of the 25-gauge 3.8-cm Quincke tip needle (Becton Dickinson and Company, Franklin Lakes, NJ). The needle shaft echo was bent toward the skin surface when the needle crossed the axillary artery (fig. 1). When examined after the procedure, the injection needle was perfectly straight.

Described as a “bayonet artifact,” this ultrasound artifact causes apparent needle deformity and has been reported during breast biopsy in which a needle traverses a tumor surrounded by fat tissue.<sup>6</sup> Bayonet artifact occurs when the ultrasound beam passes through tissues with different speeds of sound. Similar speed of sound artifacts have been described in the soft tissues of the kidney.<sup>7-9</sup> Because all commercial ultrasound machines assume a uniform speed of sound of 1,540 m/s,<sup>10</sup> actual differences among speeds of sound in tissue change the appar-

Support was provided solely from institutional and/or departmental sources.



**Fig. 1.** “Bayonet” bending of the needle shaft echo as the block needle passes through soft tissue and the axillary artery during an ultrasound-guided axillary nerve block. The arrowhead indicates the part of the needle echo that bends toward the ultrasound probe on the skin surface. Tick marks are 10 mm apart.

ent depth of received echoes. The speeds of sound among soft tissues may actually range from 1,450 m/s in fat to more than 1,600 m/s in muscle.<sup>10</sup> Thus, clinical scanning can routinely produce speed of sound errors of approximately 5%.

This letter describes a bayonet artifact observed during regional anesthesia. The artifact occurred when the block needle passed through the axillary artery with the ultrasound beam nearly perpendicular to the needle. The speed of sound in whole blood (1,580 m/s) is higher than the average speed of sound in soft tissue (1,540 m/s).<sup>11</sup> Therefore, bending of the needle echo toward the transducer was seen when the needle passed through the axillary artery.

Ultrasound guidance likely reduces the incidence of vascular puncture during regional block.<sup>12</sup> However, inadvertent vascular puncture has been reported during peripheral nerve blocks despite use of ultrasound guidance.<sup>13,14</sup> Therefore, bayonet artifacts from transarterial needle placement may occur during regional block even if vascular puncture was not intended.

The basic premise of the in-plane approach for ultrasound-guided regional blockade is that precise placement of the block needle tip near nerves is possible in real time. However, there are circumstances under which the actual needle position and perceived image do not agree. Here, we describe one of those circumstances that occurred during transarterial axillary block.

**Andrew T. Gray, M.D., Ph.D.,\* Ingeborg Schaffhalter-Zoppoth, M.D. \*** San Francisco General Hospital, University of California, San Francisco, California. graya@anesthesia.ucsf.edu

## References

1. Marhofer P, Schrogendorfer K, Koinig H: Ultrasonographic guidance improves sensory block and onset time of three-in-one blocks. *Anesth Analg* 1997; 85:854-7
2. Williams SR, Chouinard P, Arcand G, Harris P, Ruel M, Boudreault D, Girard F: Ultrasound guidance speeds execution and improves the quality of supraclavicular block. *Anesth Analg* 2003; 97:1518-23
3. Marhofer P, Sitzwohl C, Greher M, Kapral S: Ultrasound guidance for infraclavicular brachial plexus anaesthesia in children. *Anaesthesia* 2004; 59: 642-6
4. Peer S, Bodner G: High-Resolution Sonography of the Peripheral Nervous System. Berlin, Springer Verlag, 2003
5. Perlas A, Chan VW, Simons M: Brachial plexus examination and localization using ultrasound and electrical stimulation: A volunteer study. *ANESTHESIOLOGY* 2003; 99:429-35
6. Fornage BD: Sonographically guided core-needle biopsy of breast masses: the “bayonet artifact.” *Am J Roentgenol* 1995; 164:1022-3
7. Sommer FG, Filly RA, Minton MJ: Acoustic shadowing due to refractive and reflective effects. *AJR* 1979; 132:973-9
8. Pedersen JF, Larsen VA, Rosenkilde M: Renal duplication artefacts in ultrasound imaging. *Br J Radiol* 1999; 72:1040-5
9. Richman TS, Taylor KJW, Kremkau FW: Propagation speed artifact in a fatty tumor (myelolipoma): Significance for tissue differential diagnosis. *J Ultrasound Med* 1983; 2:45-47
10. Anderson ME, McKeag MS, Trahey GE: The impact of sound speed errors on medical ultrasound imaging. *J Acoust Soc Am* 2000; 107:3540-8
11. Pierce G, Golding RH, Cooperberg PL: The effects of tissue velocity changes on acoustical interfaces. *J Ultrasound Med* 1982; 1:185-7
12. Marhofer P, Schrogendorfer K, Wallner T: Ultrasonographic guidance reduces the amount of local anesthetic for 3-in-1 blocks. *Reg Anesth Pain Med* 1998; 23:584-8
13. Sandhu NS, Capan LM: Ultrasound-guided infraclavicular brachial plexus block. *Br J Anaesth* 2002; 89:254-9
14. Chan VW, Perlas A, Rawson R, Odukoya O: Ultrasound-guided supraclavicular brachial plexus block. *Anesth Analg* 2003; 97:1514-7

(Accepted for publication February 9, 2005.)