

Successful Resuscitation after Cardiovascular Collapse following Accidental Intravenous Infusion of Levobupivacaine during General Anesthesia

Timo E. Salomäki, M.D., Ph.D.,* Päivi A. Laurila, M.D., Ph.D.,† Jäntti Ville, M.D., Ph.D.‡

LOCAL anesthetics, when injected intravascularly, result in serious cardiac complications. We report the first clinical case in which cardiovascular collapse occurred after intravenous administration of levobupivacaine (125 mg).

Case Report

A 63-yr-old, 77-kg man with localized prostate cancer but no other medical history presented for brachytherapy. The patient was premedicated with 10 mg oral diazepam and 1 g oral paracetamol 60 min before anesthesia. At the time of arrival in the operating room, saline infusion was started, and the monitors were connected: five-lead electrocardiogram, end-tidal carbon dioxide, end-tidal sevoflurane concentration, noninvasive arterial blood pressure, pulse oximetry, Entropy index (GE Health Care Finland, Helsinki, Finland), and peripheral nerve stimulator. For prophylaxis, infusion of 200 mg ciprofloxacin (100 ml) was started 5 min before the induction of anesthesia. General anesthesia was induced with thiopental (425 mg), fentanyl (0.1 mg), and rocuronium (50 mg). Tracheal intubation was performed, and controlled ventilation was started (40% oxygen in air with 1.1-1.7% sevoflurane). The patient's arterial blood pressure and heart rate were 152/95 mmHg and 75 beats/min, respectively, initially, and 125/85 mmHg and 70 beats/min 5 min after induction. Ten minutes after induction (15 min after the initiation of antibiotic infusion), arterial blood pressure was 85/60 mmHg, heart rate was 60 beats/min, and end-tidal carbon dioxide was 32 mmHg. To increase arterial blood pressure, the patient was given 1 mg intravenous etilefrine. Five minutes later, when the infusion of the prescribed antibiotic dose (100 ml) was completed (during the past 20 min), it was noticed that the administered infusion was not antibiotic but 125 mg levobupivacaine (Chirocain[®]; Abbot, Espoo, Finland). The levobupivacaine, which was intended for epidural infusion, was packed in a similar 100-ml plastic infusion bag as the antibiotic. At the same time, arterial blood pressure was not measurable noninvasively, and there was no pulse in the left radial artery. Electrocardiogram showed a heart rate of 55 beats/min, and there were no changes in ST level or rhythm. There were no changes in the Entropy indexes or end-tidal carbon dioxide (32 mmHg), either. The patient was immediately given 0.2 mg intravenous epinephrine, and his arterial blood pressure increased to 85/65 mmHg. His left radial artery was cannulated, blood gas analysis was performed, and the oxygen fraction in the ventilator was increased to 100%. His blood gas values were as follows: pH, 7.37; partial pressure of carbon dioxide, 45 mmHg; base excess, -0.9 mmHg; partial pressure of oxygen, 187 mmHg. Seven min-

utes later, arterial blood pressure decreased again, to 62/45 mmHg, and 0.1 mg epinephrine was given intravenously. Arterial blood pressure then increased to 95/55 mmHg, and the infusion of norepinephrine was started. Norepinephrine was infused during the first 5 min at a dose of 0.17 $\mu\text{g} \cdot \text{kg}^{-1} \cdot \text{min}^{-1}$ and thereafter at 0.09 $\mu\text{g} \cdot \text{kg}^{-1} \cdot \text{min}^{-1}$ over the next 70 min until the end of anesthesia. When systolic blood pressure stabilized at the level of 95-100 mmHg after starting the norepinephrine infusion, the surgical procedure was performed. During this period, there were numerous extra supraventricular beats, multiple transitory changes in ST levels, and short periods of nodal rhythm. After the operation, the patient awakened normally, and he was kept in the recovery room overnight for monitoring. There were no changes in his postoperative electrocardiogram, and his glucose, electrolyte, and troponin plasma concentrations were normal. The arterial levobupivacaine concentrations were 1.74 mg/l at 40 min (after starting the infusion of levobupivacaine), 0.81 mg/l at 100 min, and 0.60 mg/l at 160 min. The patient had no sequelae, and he was informed about the accidental infusion. A thorough investigation was performed in the department to find out how this accident had been possible and how a similar instance could be prevented in the future. The pharmaceutical company (Abbot) was also informed of the fact that their epidural 0.125% levobupivacaine (100 ml) was packaged similarly to some intravenous antibiotics.

Discussion

Levobupivacaine, which is a pure S(-)-enantiomer, was developed to improve the safety profile of racemic bupivacaine.¹⁻³ There are several case reports of convulsions after peripheral nerve blockade with a total dose of 142-150 mg levobupivacaine, but no cardiovascular complications have been reported.⁴⁻⁸ All of the patients in these reports had toxic central nervous system symptoms immediately after the peripheral nerve blockade, but it is not clear how large a percentage of the total injected dose was intravascular. In one of these cases, in which the total dose of levobupivacaine was 142 mg, the venous serum concentrations were 2.7 and 1.1 mg/l at 14 and 120 min after the cessation of the intended epidural injection, respectively.⁴ The patient had transient central nervous system agitation but no arrhythmias or other severe cardiovascular disorders.⁴ In our case, the concentration of levobupivacaine was 1.74 mg/l at 40 min after the start of the infusion of 125 mg levobupivacaine (20 min after the total dose had been infused). In studies of healthy volunteers, levobupivacaine was infused at a dose of 10 mg/min until central nervous system symptoms occurred or when a total dose of 150 mg had been given.^{9,10} In these studies, the first central nervous system symptoms occurred after a mean dose of 36.9-56.1 mg, and the maximum mean concentration was 1.93 mg/l.⁹ These patients had no change in cardiac

* Deputy Chief Anesthesiologist, † Chief Anesthesiologist, Department of Anesthesiology, Oulu University Hospital, Oulu, Finland. ‡ Professor of Physiology, University of Tampere, Department of Clinical Neurophysiology, Tampere University Hospital, Tampere, Finland.

Received from the Department of Anesthesiology, Oulu University Hospital, Oulu, Finland. Submitted for publication April 27, 2005. Accepted for publication June 23, 2005. Support was provided solely from institutional and/or departmental sources.

Address reprint requests to Dr. Salomäki: Department of Anesthesiology, Oulu University Hospital, PL 21, Oulu 90029 OYS, Finland. Address electronic mail to: timo.salomaki@ppshp.fi or timo.salomaki@oulu.fi. Individual article reprints may be purchased through the Journal Web site, www.anesthesiology.org.

values,⁵ or only their systolic and diastolic pressures and pulse rate increased.⁹ In our case (infusion 6.2 mg/min), the patient had been anesthetized with diazepam, thio-pental, and sevoflurane, and he was given rocuronium, which probably prevented convulsions. In this case, where cardiovascular collapse occurred after the infusion of intravenous levobupivacaine, simultaneous induction of general anesthesia probably had some depressive effects on cardiovascular function. Because arterial blood pressure was very low but heart rate and end-tidal partial pressure of carbon dioxide tension were normal and there was no metabolic acidosis, the intravenous levobupivacaine possibly caused more vasodilatation than direct cardiac depression.

Levobupivacaine has been given during general anesthesia to induce caudal¹¹⁻¹³ and ilioinguinal-iliohypogastric nerve block in children.¹⁴ In one of those studies, the patients received a total levobupivacaine dose of 2 mg/kg for an ilioinguinal-iliohypogastric nerve block.¹⁴ Although maximum total plasma concentrations more than 2 mg/l were achieved in 40% of the patients, no adverse effects were detected.¹⁴ The time to the maximum measured concentration was 28 ± 16 min. The doses and mean plasma concentrations of levobupivacaine in that study were close to those of our adult patient, who had cardiovascular collapse. Accordingly, one could debate the width of the safety margins for the practice of inducing nerve blockade with levobupivacaine by giving 2 mg/kg to anesthetized children, although no adverse effects have been reported so far.¹²⁻¹⁴ In our case, although the administered dose of intravenous levobupivacaine induced cardiovascular collapse, it was possible to restore circulation with moderate doses of epinephrine and norepinephrine without any sequelae. However, levobupivacaine is a potent

drug, and a strict policy is needed to avoid intravenous administration.

References

1. Benhamou D, Ghosh C, Mercier FJ: A randomized sequential allocation study to determine the minimum effective analgesic concentration of levobupivacaine and ropivacaine in patients receiving epidural analgesia for labor. *ANESTHESIOLOGY* 2003; 99:1383-6
2. Polley LS, Columb MO, Naughton NN, Wagner DS, van de Ven CJM, Goralski KH: Relative analgesic potencies of levobupivacaine and ropivacaine for epidural analgesia in labor. *ANESTHESIOLOGY* 2003; 99:1354-8
3. Lerman J, Nolan J, Eyres R, Schily M, Stoddart P, Bolton CM, Grad D, Mazzeo F, Wolf AR: Efficacy, safety, and pharmacokinetics of levobupivacaine with and without fentanyl after continuous epidural infusion in children: A multicenter trial. *ANESTHESIOLOGY* 2003; 99:1166-74
4. Kopacz DJ, Allen HW: Accidental intravenous levobupivacaine. *Anesth Analg* 1999; 89:1027-9
5. Khan H, Atanassoff P: Accidental intravascular injection of levobupivacaine and lidocaine during the transarterial approach to the axillary brachial plexus (letter). *Can J Anaesth* 2003; 50:95
6. Crews J, Rothman T: Seizure after levobupivacaine for interscalene brachial plexus block. *Anesth Analg* 2003; 96:1188-90
7. Breslin DS, Martin G, MacLeod D, D'Ercole F, Grant SA: Central nervous system toxicity following the administration of levobupivacaine for lumbar plexus block: A report of two cases. *Reg Anesth Pain Med* 2003; 28:144-7
8. Pirotta D, Sprigge J: Convulsions following axillary brachial plexus blockade with levobupivacaine. *Anaesthesia* 2002; 57:1187-9
9. Bardsley H, Gristwood R, Baker H, Watson N, Nimmo W: A comparison of the cardiovascular effects of levobupivacaine and rac-bupivacaine following intravenous administration to healthy volunteers. *Br J Clin Pharmacol* 1998; 46:245-9
10. Stewart J, Kellet N, Castro D: The central nervous system and cardiovascular effects of levobupivacaine and ropivacaine in healthy volunteers. *Anesth Analg* 2003; 412-6
11. Astuto M, Disma N, Arena C: Levobupivacaine 0.25% compared with ropivacaine 0.25% by the caudal route in children. *Eur J Anaesthesiol* 2003; 20:826-30
12. Taylor R, Eyres R, Chalkiadis GA, Austin S: Efficacy and safety of caudal injection of levobupivacaine 0.25% in children under 2 years of age undergoing inguinal hernia repair, circumcision or orchidopexy. *Pediatr Anaesth* 2003; 13:114-21
13. Chalkiadis GA, Eyres RL, Cranswick N, Taylor RH, Austin S: Pharmacokinetics of levobupivacaine 0.25% following caudal administration in children under 2 years of age. *Br J Anaesth* 2004; 92:218-22
14. Alakokko TI, Riih a E, Karinen J, Kiviluoma K, Alahuhta S: Pharmacokinetics of 0.5% levobupivacaine following ilioinguinal-iliohypogastric nerve blockade in children. *Acta Anaesthesiol Scand* 2005; 49:397-400

Anesthesiology 2005; 103:1096-8

© 2005 American Society of Anesthesiologists, Inc. Lippincott Williams & Wilkins, Inc.

Massive Inhalation of Desflurane due to Vaporizer Dysfunction

Jean-Christophe Geffroy, M.D., M.B.A.,* Marc E. Gentili, M.D., Ph.D.,* Ren  Le Poll s, M.D.,* Philippe Triclot, M.D.†

HALOGENATED anesthetics are safely used worldwide for induction and maintenance of general anesthesia.¹ Fatal cases related to administration of halogenated anesthetics have been rarely reported, mainly in children.^{2,3} Routine monitoring of end-tidal halogenated an-

esthetic concentrations is likely to have improved the safety of their administration. We report a case of sudden and transient cardiac arrest due to a very high concentration of desflurane delivered inadvertently because of a vaporizer malfunction.

*Staff Anesthesiologist. † Staff Orthopedic Surgeon.

Received from the Department of Anesthesiology and Intensive Care A and the Orthopedic Surgery Unit, Centre Hospitalier Priv  Saint-Gr goire, Saint-Gr goire, France. Submitted for publication December 16, 2004. Accepted for publication July 2, 2005. Support was provided solely from institutional and/or departmental sources.

Address reprint requests to Dr. Gentili: Department of Anesthesiology and Intensive Care A, Centre Hospitalier Priv  Saint-Gr goire, 35760 Saint-Gr goire, France. Address electronic mail to: marc.gentili@wananadoo.fr. Individual article reprints may be purchased through the Journal Web site, www.anesthesiology.org.

Case Report

A healthy 36-yr-old woman (height, 1.65 m; weight, 68 kg) was scheduled to undergo surgery because of Dupuytren disease of the left upper limb. During the preoperative visit, she declined regional block and asked for general anesthesia. Hydroxyzine, 100 mg, was given orally 1 h before surgery. Induction of anesthesia was performed with propofol (2.5 mg/kg), sufentanil (3 µg), and atracurium (0.5 mg/kg). A laryngeal

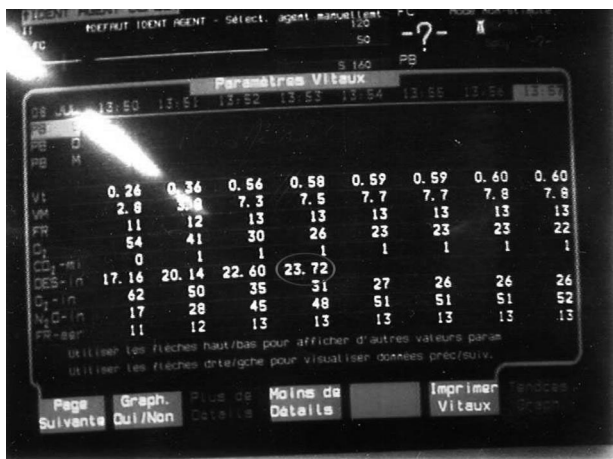


Fig. 1. Evolution of desflurane concentration during the initial period of anesthesia.

mask was inserted, and the lungs were mechanically ventilated with a mixture of oxygen-nitrous oxide (50/50%). Anesthesia was maintained with desflurane delivered at 3.5% using a Tec 6 Plus Vaporizer (Datex Ohmeda, Steeton, England) via a partially closed circuit with a low flow of fresh gases (1 l/min). Partial pressure of end-tidal carbon dioxide was maintained within 30–35 mmHg. Five minutes after induction, hypoxia and bradycardia occurred, rapidly followed by cardiac arrest. Cardiopulmonary resuscitation was initiated while nitrous oxide and desflurane administration were stopped, ventilation being performed manually with 100% oxygen. The continuous electrocardiogram showed an asystole. Epinephrine, 1 mg, was administered intravenously. Ventricular fibrillation was then observed and treated by external countershock (250 J), which enabled a return to spontaneous circulation with sinus rhythm (arterial pressure 90/50 mmHg, oxygen peripheral saturation 100%). Ectopic ventricular extrasystoles were noted and treated with intravenous lidocaine (70 mg). The patient was then sedated with midazolam (10 mg/h) and admitted to the postanesthesia care unit. Chest x-ray showed a pulmonary edema. Except for transient lactic acidosis (blood lactates 3.8 mm), biologic analysis results of the blood remained within the reference ranges. Sedation was stopped, and the patient awoke and was discharged on the fourth day, without any sequelae.

As soon as the patient left the operating room, the ventilator (Excel 210SE Datex-Ohmeda, Madison, WI) and the complete monitoring devices were removed and declared out of order until complete checkup. Examination of the halogenated anesthetic monitor (Viridia 24 C; Hewlett Packard, Boeblingen, Germany) memory indicated a progressive increase in end-expiratory desflurane concentration up to 23% (fig. 1). Physical examination of the vaporizer showed an internal crack of the control dial (fig. 2), which normally regulates the control valve; this severe dysfunction was probably due to an external shock.

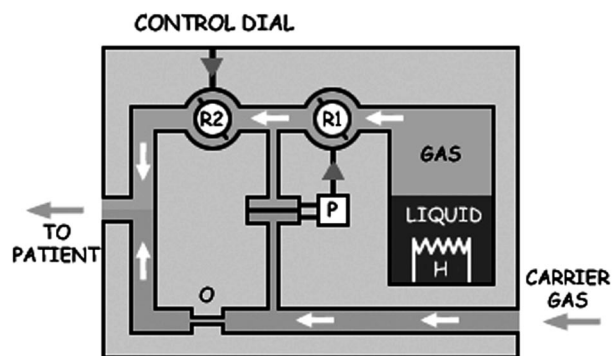


Fig. 2. Tec 6 Plus scheme.

This damage did not limit the rotation of the control valve (R2), which remained uncontrolled; this matter was considered by experts to be responsible for the massive administration of desflurane in the inhalation circuit.

Discussion

We report a case of cardiac arrest related to the accidental delivery of a high concentration of desflurane, due to a vaporizer malfunction. Cardiac arrest was probably due to the negative inotropic effect observed with halogenated anesthetics, explaining the reversible pulmonary edema. Similar cases have been previously reported a few decades ago with halothane and less sophisticated vaporizers.⁴⁻⁶

Among the halogenated anesthetics, desflurane possesses the highest volatility and the lowest blood-air partition coefficient (0.42 at 37°C), with a vapor pressure of 669 mmHg at 20°C and a boiling point of only 23.5°C, which is lower than room temperature, which implies the use of a boiling vaporizer. The Tec 6 vaporizer is an electrically heated, thermostatically controlled, constant-temperature, pressurized, electromechanically coupled dual-circuit, gas-vapor blender. It has both electronic monitors of vaporizer function and alarms. The pressure in the vapor circuit is electronically regulated to equal the pressure in the fresh gas circuit. At a constant fresh gas flow rate, the operator regulates vapor flow with a conventional concentration control dial. When the fresh gas flow rate increases, the working pressure increases proportionally. At a specific dial setting at different fresh gas flow rates, vaporizer output is constant because the amount of flow through each circuit is proportional. Independent confirmation of vaporizer performance and design characteristics awaits vaporizer availability.⁷⁻⁹ This vaporizer differs from previous ones designed for anesthesia in that electromechanical rather than mechanical controls accommodate the different physical characteristics of desflurane. This design may offer an increased risk of failure because of the sophisticated electronic components and circuit.⁹

Theoretically, the vaporizer offers the decreased likelihood of accidental delivery of very large concentrations of liquid anesthetic resulting from tilting or overfilling and alarms and warnings not previously incorporated into the design of other anesthetic vaporizers. The output characteristics of the vaporizer are as expected, based on the design: The accuracy of the output of desflurane concentration in oxygen ($\pm 15\%$) is similar to that of the mechanical vaporizers. Output decreases when nitrous oxide is added, as a result of the lower viscosity, but remains within 20% of the dial setting or 0.5% absolute. The new filling system is a significant improvement over previous Tec filling systems. The vaporizer requires a warm-up period before it may be used, but, when activated, it provides an output that is approx-

Downloaded from http://asa2.silverchair.com/anesthesiology/article-pdf/103/5/1095/358833/0000542-200511000-00025.pdf by guest on 01 March 2024

imately linear between 1 and 18% vapor concentrations, at flow rates between 0.2 and 10 l/min.¹⁰ The major problem presented by desflurane is that it is extremely volatile: At 22.8°C, its boiling point is only slightly above normal room temperature, which precludes the use of a normal variable bypass-type vaporizer. The Tec 6 vaporizer avoids this problem by heating the desflurane liquid to above its boiling point in a sealed chamber and mixing pure desflurane gas with the carrier gas. Liquid desflurane is heated to 39°C by a heating element, at which temperature its saturating vapor pressure is approximately 1,300 mmHg. The carrier gas flow is restricted by an orifice so that the pressure of the carrier gas within the vaporizer is proportional to gas flow. These devices need an annual assessment and must be completely checked by the firm every 2 yr. Riddle¹¹ reported the recall by the manufacturer Ohmeda of a series of vaporizers that delivered the anesthetic at a concentration superior to that posted on the regulating valve; this dysfunction was related to a malfunction of the control valves. More recently, a similar case report was published.¹⁰ Our case report shows the relative weakness of this kind of vaporizer, with an increased risk of failure because of sophisticated electronic components and internal circuitry.⁹ We suggest that a complete checkup of this apparatus is mandatory after a shock, and this information should be provided to all anesthesia teams. This

case report also reemphasizes the need for systematic monitoring of the halogenated anesthetic concentration during every anesthetic procedure using these gases.

The authors thank Bruno Riou, M.D., Ph.D. (Professor, Department of Anesthesiology, University Hospital Pitié Salpêtrière, Paris, France), who gave substantial advice for the manuscript.

References

1. Eger EI: New inhaled anesthetics. *ANESTHESIOLOGY* 1994; 80:906-22
2. Olsson GI, Hallen B: Cardiac arrest during anaesthesia: A computer-added study in 250,543 anaesthetics. *Acta Anaesthesiol Scand* 1988; 32:653-64
3. Morray JP, Geiduschek JM, Ramamoorthy C, Haberkern CM, Hackel A, Caplan RA, Domino KB, Posner K, Cheney FW: Anesthesia-related cardiac arrest in children: Initial findings of the Pediatric Perioperative Cardiac Arrest (POCA) Registry. *ANESTHESIOLOGY* 2000; 93:6-14
4. Kopriva CJ, Lowenstein E: An anesthetic accident: Cardiovascular collapse from liquid halothane delivery. *ANESTHESIOLOGY* 1969; 30:246-7
5. Janda A: Halothane-intoxication by failure of the halothane-vaporizer. *Prakt Anaesth* 1976; 10:236-7
6. Yamada T, Masuda J, Takeda J, Sekiguchi H, Fukushima K: Vaporizer malfunction: A cause of high concentration halothane vapor delivery. *Masui* 1994; 43:421-5
7. Andrews JJ, Johnston RV: The new Tec 6TM desflurane vaporizer. *Anesth Analg* 1993; 73:1338-41
8. Graham SG: The desflurane (Tec 6TM) vaporizer. *Br J Anaesth* 1994; 72:470-3
9. Weiskopf RB, Sampson D, Moore MA: The desflurane (Tec 6) vaporizer: Design, design considerations and performance evaluation. *Br J Anaesth* 1994; 72:474-9
10. Kayser D, Khodja M, Marguerite G: Delivery of desflurane by a Tec 6 vaporizer at a concentration superior to that posted on the regulating valve. *Ann Fr Anesth Reanim* 1999; 18:691-3
11. Riddle RT: Tec 6 TM recall. *ANESTHESIOLOGY* 1994; 81:791-2