

# Comparison of Two Techniques for Retrograde Tracheal Intubation in Human Fresh Cadavers

François Lenfant, M.D., Ph.D.,\* Mehdi Benkhadra, M.D.,\* Pierre Trouilloud, M.D., Ph.D.,† Marc Freysz, M.D., Ph.D.‡

**Background:** During retrograde tracheal intubation, the short distance existing between the cricothyroid membrane and vocal cords may be responsible for accidental extubation. The insertion of a catheter into the trachea before the removal of the guide wire may help to cope with this problem. This work was conducted to study the impact of such a modification on the success rate and the duration of the procedure.

**Methods:** Procedures of retrograde tracheal intubation following the classic and modified techniques were randomly performed in cadavers (n = 70). The duration of the procedure from the puncture of the cricothyroid membrane to the inflation of the balloon of the endotracheal tube was measured, and, at the end of the procedure, the position of the endotracheal tube was checked under laryngoscopy. The procedure was considered to have failed if it had taken more than 5 min or when the endotracheal tube was not positioned in the trachea.

**Results:** The mean time to achieve tracheal intubation was similar in both groups (123 ± 51 vs. 127 ± 41 s; not significant), but intubation failed significantly more frequently with the classic technique (22 vs. 8 failures;  $P < 0.05$ ). All failures were related to incorrect positioning of the endotracheal tube. In four cases, both techniques failed.

**Conclusions:** This efficient, simple modification of the technique significantly increases the success rate of the procedure, without prolonging its duration. These data should be confirmed in clinical conditions but may encourage a larger use of the retrograde technique in cases of difficult intubation.

SUCCESSFUL intubation can be accomplished in the majority of patients *via* direct laryngoscopy, but sometimes, tracheal intubation may be difficult or impossible. To cope with this problem, algorithms have been proposed by various societies of anesthesiologists. In such algorithms, different alternatives may be used to facilitate the tracheal intubation in case of unsuccessful tracheal intubation attempts when facemask ventilation is adequate.<sup>1</sup> The retrograde tracheal intubation is another possible technique that seems to be simple and quick in experienced hands<sup>2</sup> and that is indicated in various clinical situations,<sup>3</sup> including cervical and facial trauma<sup>4</sup> and limited mouth opening.<sup>5-7</sup> However, the success rate of

the retrograde tracheal intubation is irregular.<sup>8</sup> This may result from the operators' skill but mainly because of the short distance between the cricothyroid membrane and the vocal cords, which is responsible for accidental extubation that occurs during the removal of the guide. Many adaptations of the technique,<sup>9</sup> including infracricoid puncture,<sup>10</sup> the insertion of the guiding catheter through the distal lateral eye of the endotracheal tube,<sup>11</sup> or the use of a bronchoscope,<sup>12</sup> have been proposed to cope with this technical problem. The catheterization of the trachea using a bougie inserted through the endotracheal tube before the removal of the guide wire is one of the other possible adaptations.<sup>13</sup>

The aim of this study, conducted in cadavers, was to evaluate such a modification of the technique using catheterization of the trachea with a catheter guide before removal of the guide wire, and to compare the classic and originally described technique with the modified one in terms of success rate and time for achievement.

## Materials and Methods

After local ethical committee approval was obtained, this study was conducted in a university anatomical laboratory (Faculté de Médecine de Dijon, Université de Bourgogne, Dijon, France) in cadavers from patients who accepted the postmortem donation of their cadaver for scientific purposes according to French law.

### Description of the Technique

Retrograde tracheal intubation sets were kindly provided by Cook Laboratory (Cook Retrograde Intubation Set with Rapi-Fit<sup>®</sup> Adapters; Cook, Charenton, France). Each set contains an 18-gauge, 5-cm-long needle, a syringe, a needle holder, a straight and a curved safe-T-J double flexible tipped wire guide, and a guiding hollow catheter with Luer-lock connector and plastic connector adapters.

**Classic Technique.** After the cricothyroid membrane is punctured in the cephalad direction, the guide wire is inserted through the needle, pushed upward, and orally retrieved from the pharynx. Then, the hollow guiding catheter is introduced over the guide wire to facilitate the placement of the endotracheal tube. The endotracheal tube is inserted onto the guiding catheter and pushed into the trachea. Then, the guide wire and the catheter are removed while the endotracheal tube is maintained in the tracheal lumen<sup>12</sup> (fig. 1A).

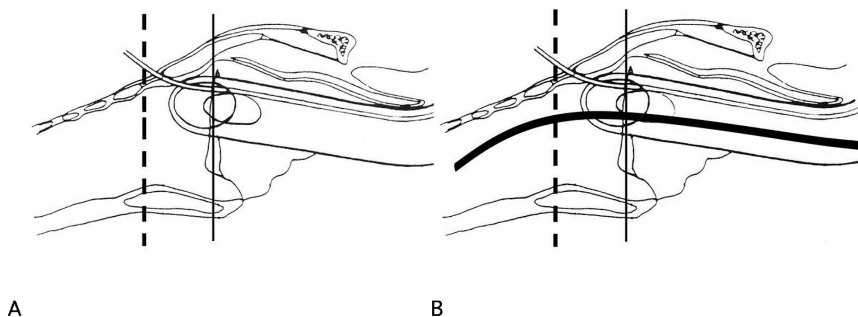
**Modified Technique.** The first steps of the modified technique do not differ from the classic one. But when

\* Staff Anesthesiologist, ‡ Professor of Anesthesiology and Critical Care and Chairman, Department of Anesthesiology and Critical Care, Hôpital Général, Centre Hospitalier Universitaire de Dijon. † Professor of Orthopedic Surgery and Chairman, University Laboratory of Anatomy, Faculté de Médecine de Dijon, Dijon, France.

Received from the Department of Anesthesiology and Critical Care, Hôpital Général, Centre Hospitalier Universitaire de Dijon, and Laboratoire d'Anatomie, Faculté de Médecine de Dijon, Université de Bourgogne, Dijon, France. Submitted for publication May 17, 2005. Accepted for publication September 21, 2005. Support was provided solely from institutional and/or departmental sources. Cook Laboratory, Charenton, France, provided the equipment, which was tested free of charge.

Address reprint requests to Dr. Lenfant: Département d'anesthésie-Réanimation, Hôpital Général, Centre Hospitalier Universitaire de Dijon, 3 rue du faubourg Raines, 21033 Dijon Cedex, France. Address electronic mail to: francois.lenfant@chu-dijon.fr. Individual article reprints may be purchased through the Journal Web site, www.anesthesiology.org.

**Fig. 1.** In the classic retrograde technique, the guide wire is removed while the endotracheal tube is maintained in its position (A). During the modified retrograde technique, a catheter is inserted into the trachea before the guide wire is removed (B). The *dashed line* indicates the level of the cricothyroid membrane, and the *full line* indicates the level of the vocal cords.



the endotracheal tube has been guided into the trachea and before the guide wire is removed, the hollow catheter is removed and reinserted through the endotracheal tube into the trachea. Then, the guide wire is removed, and the endotracheal tube is pushed into the trachea, using the hollow catheter as a guide. When placed into the trachea, the hollow catheter can be used for the patient's oxygenation and analysis of the expired gas to confirm its correct position in the trachea (fig. 1B).

#### Design of the Study

The study was conducted in fresh cadavers in our university laboratory of anatomy. Three anesthesiologists, experienced in retrograde tracheal intubation and familiar with the retrograde intubation set used in this study (at least 10 procedures of each technique successfully performed on cadavers), participated in the study. They were assigned to perform, consecutively on the same cadaver, a retrograde tracheal intubation following the classic technique and the modified technique. The operator and the sequence for the procedures were randomized for each cadaver. The duration of the procedure was measured from the puncture of the cricothyroid membrane to the inflation of the balloon of the endotracheal tube. At the end of the procedure, the position of the endotracheal tube was checked under laryngoscopy. The procedure was considered to have failed if it had taken more than 5 min, or if the endotracheal tube was not positioned in the trachea (pharyngeal or esophageal position). Laryngoscopy was performed before and after each procedure to detect any laryngeal damage due to the retrograde tracheal intubation.

#### Statistical Analysis

The main endpoint of this study was the proportion of success as defined above. To calculate the number of patients to include, we made the following assumptions: an  $\alpha$  risk of 0.05, a  $\beta$  risk of 0.10, a rate of success of 70% with the standard technique, an expected rate of success with the modified technique of 90%, and a proportion of discordant pairs of 30%. Using the McNemar test, we calculated that 67 pairs would be necessary (NQuery Advisor 3.0; Statistical Solutions Ltd., Corke, Ireland) and thus decided to include 70 cadavers in our study. The secondary endpoint was the duration of the procedures.

Randomization was performed using a random number table, equilibrated every 10 patients, using envelopes opened just before the procedure.

Data are expressed as mean  $\pm$  SD or percentage and 95% confidence interval. The comparison of two means was performed using the paired Student *t* test, and the comparison of two proportions was performed using the McNemar test. All *P* values were two tailed, and a *P* value of less than 0.05 was considered significant.

#### Results

No cadaver had any laryngeal or pharyngeal abnormalities or any anatomical specificity that could make the retrograde tracheal intubation difficult. In all cadavers, direct laryngoscopy was easy (Cormack and Lehane grade 1 or 2) in all cadavers.

Following the standard technique, mean time to achieve a retrograde intubation approached 120 s, and the modification of the technique did not make the procedure longer (table 1). Tracheal intubation failed significantly more frequently with the classic technique (table 1). The success rate was 69% (95% confidence interval, 22-43%) with the classic technique and 89% (95% confidence interval, 79-94%) with the modified technique. The between-group difference in the success rate was 20% (95% confidence interval, 7-32%). No failure was due to a procedure that lasted more than 5 min, and all were due to incorrect positioning of the endotracheal tube. In four cases, retrograde tracheal intubation failed using both the classic and the modified technique; no particular reasons for such failures could be identified.

**Table 1. Comparison of the Classic and Modified Retrograde Techniques (n = 70)**

	Classic Technique	Modified Technique	<i>P</i> Value
Duration of procedure, s	123 $\pm$ 51	127 $\pm$ 41	NS
Number of failed procedures	22 (31)	8 (11)	0.001
Duration > 5 min	0	0	NS
Wrong position of tracheal tube	22 (31)	8 (11)	0.001

Data are mean  $\pm$  SD or n (%).

NS = not significant.

After the procedures, the laryngoscopy did not reveal any serious damage to the vocal cords. The incidence of important vocal cord damage was thus 0%, with a 95% confidence interval of 0–3%.

## Discussion

Described in the early 1960s,<sup>14,15</sup> retrograde tracheal intubation is an alternative technique for difficult airway management.<sup>1,16</sup> However, although retrograde tracheal intubation is usually available,<sup>17</sup> it is not often used.<sup>18–20</sup> To enhance the success rate of the technique, the infracricoid puncture or the introduction of the guide through the distal lateral eye of the endotracheal tube have been proposed.<sup>10,11</sup> The availability of a ready-to-use set for retrograde tracheal intubation, containing a catheter guide, may bring a new adaptation of the technique. In fact, the catheterization of the trachea with the catheter guide before removal of the guide wire has already been reported in a case report.<sup>13</sup> It allows administration of oxygen to the patient, analysis of the expired gas to confirm the correct endotracheal placement of this catheter, and safe removal of the guide wire with no risk of extubation. This study was conducted to evaluate this modified technique for retrograde tracheal intubation in terms of duration of the procedure and success rate as compared with the classic technique.

In our study, the success rate of the classic technique was found to be unacceptably low (70%) for a technique that is proposed in case of difficult airway management. The modification of the technique significantly increased the success rate (89%), the number of failures being divided by three. Such a success rate is still far from completely satisfactory but approaches the success rate at the first attempt reported in the literature with other more popular techniques such as the *Fastrach*<sup>TM</sup> laryngeal mask (Laryngeal Mask Company, Henley-on-Thames, United Kingdom),<sup>21</sup> fibroscopy,<sup>21</sup> or the Trachlight<sup>®</sup> (Laerdal Medical, Armonk, NY).<sup>22</sup> In both retrograde techniques, all failures were due to incorrect positioning of the endotracheal tube. An accidental extubation occurring during the removal of the guide wire can easily occur with the classic technique. With the modified technique, the incorrect positioning of the endotracheal tube is more likely to be the reason why the catheter guide was not introduced into the tracheal lumen, which in turn means that the endotracheal tube was not positioned in the trachea at the moment of the insertion of this catheter. Another explanation could be that with the advancement of the endotracheal tube, the catheter moved cephalad, and then the endotracheal tube was introduced into the esophagus. Considering the rigidity of the catheter and the length introduced into the trachea, such hypothesis is more unlikely. Because the aim of the study was to compare two tech-

niques achieved in similar conditions, we decided to include a large number of cadavers (with no difficult airway) and few operators. When performed in clinical practice, many parameters, including the skill of the operators, a difficult airway anatomy, or the stress due to the situation, may greatly influence the success rate of the retrograde endotracheal intubations and decrease it. In our model, the conditions in which the retrograde tracheal intubation was performed did not integrate these parameters, and one can hypothesize that it may have introduced a bias in favor of success. However, performing a retrograde tracheal intubation following the modified technique in a living patient may be eased by the analysis of the expired gas at the extremity of the catheter, which allows doctors to confirm the correct position of the catheter before removing the guide wire and pushing in the endotracheal tube. Therefore, although our model may be considered as imperfect and not corresponding to the true reality, considering our data in term of success rate, we believe that the improvement of the technique may be beneficial in case of difficult intubation.

The modification of the retrograde technique did not make the procedure longer. The average time of 2 min to accomplish the procedures did not differ from the duration generally reported in the literature.<sup>2,5,8</sup> In clinical practice, the duration of the retrograde tracheal intubation procedure depends on the anatomical characteristics of the patient. In our study, the duration of the procedure was measured from the cricothyroid membrane puncture to the inflation of the balloon of the endotracheal tube, so the bias introduced by the anatomical differences between cadavers and the fact that two procedures were performed on the same cadaver would be negligible.

Publications about the complications of retrograde tracheal intubation are sparse and regard procedures using tools that were not designated for retrograde tracheal intubation (Tuohy needle, epidural catheters). Various complications, including sore throat, emphysema, laryngeal edema, or infections, have been reported,<sup>12,23–25</sup> but it seems to be a rather safe technique.<sup>5,26</sup> However, subcricoid puncture may be more dangerous than the cricothyroid membrane puncture, and the introduction of the guide wire through the distal lateral eye of the endotracheal tube, because the guide and the tube axes differ, may be more traumatic for the vocal cords than the classic technique. In the current study, when performing laryngoscopy, we did not observe any major laryngeal damage. However, on cadavers, bleeding or edema cannot be observed, and therefore only major damages such as laceration or perforation could be looked at and documented. Nevertheless, because the modification of the technique is very modest and consists of introducing a catheter into the trachea through the endotracheal tube, its complications should be no

different from or lower than those of the classic technique. Moreover, with this modified technique, the removal of the guide wire becomes easy and safe. Finally, such a modification of the technique does not increase the cost of the procedure, because the catheter is available in the ready-to-use set for retrograde intubation.

In conclusion, during the retrograde tracheal intubation procedure, the insertion of a catheter guide into the trachea through the endotracheal tube before the removal of the guide wire significantly increases the success rate of the procedure, with no modification of the duration of the procedure. With this modification of the technique, the success rate of the retrograde tracheal intubation is very high and similar to those of other tools dedicated to difficult airway management. Because our study was performed on cadavers with normal airways, it should be confirmed in clinical conditions, but this efficient simple modification should encourage a larger use of the retrograde technique in cases of difficult intubation.

The authors thank Didier Carnet, Ph.D. (Département d'Anglais Médical, Faculté de Médecine de Dijon, Dijon, France), for reviewing the manuscript.

## References

1. Practice guidelines for management of the difficult airway: An updated report by the American Society of Anesthesiologists Task Force on Management of the Difficult Airway. *ANESTHESIOLOGY* 2003; 98: 1269-77
2. van Stralen DW, Rogers M, Perkin RM, Fea S: Retrograde intubation training using a mannequin. *Am J Emerg Med* 1995; 13:50-2
3. Harrison W, Bertrand M, Andeweg S, Clark J: Retrograde intubation around an *in situ* Combitube: A difficult airway management strategy. *ANESTHESIOLOGY* 2005; 102:1061-2
4. McNamara RM: Retrograde intubation of the trachea. *Ann Emerg Med* 1987; 16:680-2
5. Barriot P, Riou B: Retrograde technique for tracheal intubation in trauma patients. *Crit Care Med* 1988; 16:712-3
6. Bhattacharya P, Biswas BK, Baniwal S: Retrieval of a retrograde catheter using suction, in patients who cannot open their mouths. *Br J Anaesth* 2004; 92:888-901
7. Seavello J, Hammer GB: Tracheal intubation in a child with trismus pseudo-camptodactyly (Hecht) syndrome. *J Clin Anesth* 1999; 11:254-6
8. Gill M, Madden MJ, Green SM: Retrograde endotracheal intubation: An investigation of indications, complications, and patient outcomes. *Am J Emerg Med* 2005; 23:123-6
9. Dhara SS: Retrograde intubation: A facilitated approach. *Br J Anaesth* 1992; 69:631-3
10. Shantha TR: Retrograde intubation using the subcricoid region. *Br J Anaesth* 1992; 68:109-12
11. Lleu JC, Forrier M, Forrier C, Pottecher T: Retrograde orotracheal intubation. *Ann Fr Anesth Reanim* 1989; 8:632-5
12. Sanchez A, Pallares V: Retrograde intubation technique, *Airway Management: Principles and Practice*. Edited by Benumof J. London, Mosby, 1996, pp 320-41
13. Cooper CM, Murray-Wilson A: Retrograde intubation: Management of a 4.8-kg, 5-month infant. *Anaesthesia* 1987; 42:1197-200
14. Butler FS, Cirillo AA: Retrograde tracheal intubation. *Anesth Analg* 1960; 39:333-8
15. Waters DJ: Guided blind endotracheal intubation: For patients with deformities of the upper airway. *Anaesthesia* 1963; 18:158-62
16. SFAR: Intubation difficile, expertise collective. *Ann Fr Anesth Reanim* 1996; 15: 207-14
17. Levitan RM, Kush S, Hollander JE: Devices for difficult airway management in academic emergency departments: Results of a national survey. *Ann Emerg Med* 1999; 33:694-8
18. Ezri T, Konichezky S, Geva D, Warters RD, Szmuk P, Hagberg C: Difficult airway management patterns among attending anaesthetists practising in Israel. *Eur J Anaesthesiol* 2003; 20:619-23
19. Rosenblatt WH, Wagner PJ, Ovassapian A, Kain ZN: Practice patterns in managing the difficult airway by anesthesiologists in the United States. *Anesth Analg* 1998; 87:153-7
20. Jenkins K, Wong DT, Correa R: Management choices for the difficult airway by anesthesiologists in Canada. *Can J Anaesth* 2002; 49:850-6
21. Langeron O, Semjen F, Bourgain JL, Marsac A, Cros AM: Comparison of the intubating laryngeal mask airway with the fiberoptic intubation in anticipated difficult airway management. *ANESTHESIOLOGY* 2001; 94:968-72
22. Hung OR, Pytka S, Morris I, Murphy M, Launcelott G, Stevens S, MacKay W, Stewart RD: Clinical trial of a new lightwand device (Trachlight) to intubate the trachea. *ANESTHESIOLOGY* 1995; 83:509-14
23. Akinyemi OO: Complications of guided blind endotracheal intubation. *Anaesthesia* 1979; 34:590-2
24. Beebe DS, Tran P, Belani KG, Adams GL: Pretracheal abscess following retrograde tracheal intubation. *Anaesthesia* 1995; 50:470 (letter)
25. Contrucci RB, Gottlieb JS: A complication of retrograde endotracheal intubation. *Ear Nose Throat J* 1990; 69:776-8
26. Weksler N, Klein M, Weksler D, Sidelnick C, Chorni I, Rozentsveig V, Brill S, Gurman GM, Ovadia L: Retrograde tracheal intubation: Beyond fiberoptic endotracheal intubation. *Acta Anaesthesiol Scand* 2004; 48:412-6