

Devices for Lung Isolation Used by Anesthesiologists with Limited Thoracic Experience

Comparison of Double-lumen Endotracheal Tube, Univent[®] Torque Control Blocker, and Arndt Wire-guided Endobronchial Blocker[®]

Javier H. Campos, M.D.,* Ezra A. Hallam, B.A.,† Timothy Van Natta, M.D.,‡ Kemp H. Kernstine, M.D., Ph.D.§

Background: Lung isolation is accomplished with a double-lumen tube or a bronchial blocker. Previous studies comparing lung isolation methods were performed by experienced anesthesiologists in thoracic anesthesia. Therefore, the results of these studies may not be relevant to the anesthesiologist with limited experience. This study compared the success rates of lung isolation devices among anesthesiologists with limited experience in thoracic anesthesia.

Methods: A prospective, randomized trial was designed to determine the success and time required for proper placement of the left-sided double-lumen tube (n = 22), the Univent[®] tube (Vitaaid Ltd., Lewiston, NY; n = 22), and the Arndt Blocker[®] (Cook Critical Care, Bloomington, IN; n = 22). Anesthesiologists with less than two lung isolation cases per month were included (faculty n = 17 and senior residents n = 11). Variables recorded included (1) successful placement (as determined by an independent observer), (2) time of placement, and (3) the number of times the fiberoptic bronchoscope was used.

Results: Participants failed to place or position their assigned device in 25 of 66 patients (failure was 39% among faculty and 36% among senior residents). The failure rate did not differ among the three devices (P = 0.65). The median (25th–75th percentile) times to complete the placement procedures were as follows: (1) double-lumen tube: 6.1 min (4.6–9.5 min), (2) Univent tube: 6.7 min (4.9–8.8 min), and (3) Arndt Blocker: 8.6 min (5.8–17.5 min) (P = 0.45 comparing all devices). After device malposition was identified, it took 1 min or less for the investigating anesthesiologist to achieve optimal position.

Conclusions: Anesthesiologists with limited experience in thoracic anesthesia frequently fail to successfully place lung isolation devices. Rapid successful device placement by an experienced anesthesiologist excluded any contribution of uniquely difficult anatomy. The nature of the malpositions suggests that the most critical factor in successful placement was the anesthesiologist's knowledge of endoscopic bronchial anatomy.

LUNG isolation techniques are commonly used to facilitate surgical exposure and provide one-lung ventilation in patients undergoing a variety of intrathoracic surgical procedures.¹⁻³ One-lung ventilation is currently achieved by two primary methods: (1) a double-lumen endotracheal tube⁴ or (2) a bronchial blocker (Univent[®] [Vitaaid Ltd., Lewiston, NY] torque control blocker⁵ or wire-guided endobronchial Arndt Blocker^{®6} [Cook Critical Care, Bloomington, IN]). The comparative efficacy of these devices has been extensively studied, and most studies suggest similar rates of successful placement and lung collapse.³

A limitation common to existing comparative studies is that they were all conducted by anesthesiologists with particular interest and expertise in thoracic anesthesia who perform lung isolation procedures on a routine basis.¹⁻¹³ However, in many practices, lung isolation is an uncommon procedure and is performed by anesthesiologists who do not specialize in thoracic anesthesia. In addition, lung isolation is needed for many procedures performed outside of the regular thoracic surgical suite—and hence is performed by clinicians with less experience. As a result, the available information regarding the utility of lung isolation devices may not apply to anesthesiologists who only occasionally need to establish one-lung ventilation. With the increasing demand for one-lung ventilation, it is important to define which device can be used most effectively by occasional users.

The aim of this study was to determine whether there were meaningful and significant differences in the success with which anesthesiologists with limited experience in the use of lung isolation methods were able to correctly place and position three different devices. The devices tested were (1) a left-sided double-lumen endotracheal tube, (2) a Univent[®] torque control blocker, and (3) an Arndt Blocker[®]. Specific endpoints were: (1) the incidence of failed device placement or malposition and (2) the time to complete the device placement procedure (regardless of subsequently assessed success). In addition, as an indirect measurement of the practitioner's skill with a fiberoptic bronchoscope, we also assessed the number of times the practitioner removed and reinserted the fiberoptic bronchoscope during their placement efforts. Finally, to insure that failures were not due to unique anatomical conditions, whenever a failure or malposition was identified, we recorded the

This article is featured in "This Month in Anesthesiology."
Please see this issue of ANESTHESIOLOGY, page 5A.

* Vice Chair of Clinical Affairs and Director of Cardiothoracic Anesthesia, Professor of Anesthesia, Department of Anesthesia, The University of Iowa Roy J. and Lucille A. Carver College of Medicine. † Medical Student, Roy J. and Lucille A. Carver College of Medicine, The University of Iowa. ‡ Assistant Professor of Surgery, Division of Cardiothoracic Surgery, Department of Surgery, University of Iowa Health Care. § Professor of Surgery, Director, Department of Thoracic Surgery, City of Hope National Medical Center, Duarte, California.

Received from the Department of Anesthesia, The University of Iowa Roy J. and Lucille A. Carver College of Medicine, Iowa City, Iowa. Submitted for publication July 21, 2005. Accepted for publication October 27, 2005. Support was provided solely from institutional and/or departmental sources. Presented at the Annual Meeting of the International Anesthesia Research Society, Honolulu, Hawaii, March 14, 2005. Jerrold Lerman, M.D., acted as Handling Editor for this article.

Address correspondence to Dr. Campos: 6406 JCP, Department of Anesthesia, 200 Hawkins Drive, Iowa City, Iowa 52242-1079. javier-campos@uiowa.edu. Individual article reprints may be purchased through the Journal Web site, www.anesthesiology.org.

time required for an experienced thoracic anesthesiologist (J. H. C.) to correctly reposition the device.

Materials and Methods

After approval by our Human Subjects Committee (Human Subjects Office, The University of Iowa, Iowa City, Iowa), written informed consent was obtained from each of the 66 patients who participated in the study and also from each of the 28 participating anesthesiologists. The anesthesiologists were either faculty members ($n = 17$) or senior residents in their last year of training ($n = 11$) in the Department of Anesthesia at The University of Iowa. Patients (age range, 21–82 yr; weight range, 49–140 kg) undergoing elective thoracic or esophageal surgical procedures for which one-lung ventilation was required were included in the study. Exclusion criteria included a history of difficult airway/intubation or a Mallampati class III or IV airway as determined during preoperative evaluation.¹⁴ To be eligible, study anesthesiologists needed to have some general familiarity with the three lung isolation devices but must have not performed an anesthetic procedure involving lung isolation more than twice in the preceding month.

The day before the study, each participating anesthesiologist was given a standardized tutorial on the use of all three devices. This included a hands-on demonstration on how to manipulate the devices and a pictorial review of the fiberoptic views that constituted proper positioning.

Patients were assigned randomly to one of three groups:

1. Double-lumen endotracheal tube: Patients in this group ($n = 22$; 13 men and 9 women) were managed with the left-sided Broncho-Cath[®] (Mallinckrodt Medical Inc., St. Louis, MO.)
2. Univent[®]: Patients in this group ($n = 22$; 17 men and 5 women) were managed with the Univent[®] torque control blocker (Vitaid Ltd.).
3. Arndt Blocker[®]: Patients in this group ($n = 22$; 11 men and 11 women) were intubated with a standard endotracheal tube (Mallinckrodt Medical Inc., St. Louis, MO), and lung isolation was then achieved with a wire-guided Arndt endobronchial blocker with a spherical-shaped balloon (Cook Critical Care).

Group assignments were made *via* random number sequence. Numbered, opaque envelopes were prepared containing the group assignments and chosen randomly. The envelope was then opened by the participating anesthesiologist just before anesthetic induction.

Anesthesia

One faculty anesthesiologist (J. H. C.) was responsible for the care of all patients. This individual managed the

induction of the patients as well as all aspects of their care after placement of the lung isolation device but did not attempt to advise or supervise the participating anesthesiologists during tube-placement efforts. All patients received intravenous glycopyrrolate (0.3–0.4 mg) before surgery. After placement of standard monitors and radial arterial catheters, anesthesia was induced with either thiopental (3–5 mg/kg), propofol (1–2 mg/kg), or etomidate (0.1–0.3 mg/kg) and maintained with fentanyl (5–10 μ g/kg) and inhaled isoflurane (0.5–2.0%) in oxygen. A nondepolarizing muscle relaxant was used for paralysis.

Intubation

While the criteria for selecting the proper size of endotracheal tube were reviewed in the training session (see Materials and Methods section, second paragraph), the decision regarding the specific size used for any patient was left to the participating anesthesiologist.

1. The styletted double-lumen endotracheal tube was introduced into the glottis *via* direct laryngoscopy. After the bronchial cuff had passed the vocal cords, the stylet was removed, and the tube was rotated 90° toward the left and advanced until slight resistance was encountered. A fiberoptic bronchoscope was then used to verify correct positioning of the tube. If a malposition was identified, the tube was withdrawn until the endobronchial lumen was above the carina. A fiberoptic bronchoscope was then placed *via* the endobronchial lumen into the left mainstem bronchus and the tube then advanced over the endoscope into the bronchus.
2. Univent[®]: When the trachea had been intubated *via* direct laryngoscopy, the endobronchial blocker was advanced through its channel and directed into the right or left mainstem bronchus under fiberoptic guidance.
3. Arndt: In this group, tracheal intubation with a standard endotracheal tube was first accomplished *via* direct laryngoscopy. Then, the wire-guided endobronchial blocker (Arndt Blocker[®]) was advanced through the blocker port of the Arndt Multiport Adapter[®], and a fiberoptic bronchoscope, which had been introduced through the fiberoptic port, was passed through the wire loop. The fiberoptic bronchoscope was then advanced into the desired mainstem bronchus, and the Arndt Blocker[®] was advanced into position.

In each patient, a stopwatch was started as soon as the endotracheal tube passed the vocal cords. The stopwatch was stopped (1) when the participating anesthesiologist concluded that the tube or bronchial blocker was correctly placed, (2) when the participating anesthesiologist concluded that placement was not possible, or (3) after a maximum of three placement attempts

Table 1. Malposition Criteria

Bronchial cuff herniated into carina (more than 50% of the cuff) (too far out)
Bronchial cuff edge not visible in the entrance of mainstem bronchus such that it would occlude a secondary bronchus (too far in)
Double-lumen endotracheal tube, Univent [®] , or Arndt Blocker [®] in opposite bronchus
If a right mainstem bronchus intubation was planned, the blocker was distal to origin of the right upper lobe bronchus
Unable to distinguish tracheal/bronchial anatomy

(each attempt was defined as either withdrawing the bronchial lumen of the double-lumen endotracheal tube or the bronchial blocker into the trachea and then attempting to reposition it). After the participating anesthesiologist had completed his or her efforts, with patients still in the supine position, the supervising anesthesiologist (J. H. C.) inserted a fiberoptic bronchoscope and determined whether proper positioning had been achieved. The criteria used to assess tube malposition and determinations of a failed study are specified in table 1. If the participating anesthesiologist failed to successfully complete device placement, the supervising anesthesiologist correctly placed the device. The amount of time to accomplish correct placement was also timed. In each case, tube/blocker positioning was again verified after the patient had been turned into the lateral position.

The following primary outcome variables were recorded: (1) the number of times tubes/devices were successfully positioned by the participating anesthesiologist; and (2) the time required by the participating anesthesiologist to complete his or her efforts, regardless of success. In addition, to indirectly assess the participating anesthesiologist's skill with the fiberoptic bronchoscope, the number of times that the fiberoptic bronchoscope was inserted into and then removed from the endotracheal tube during positioning efforts was recorded.

When satisfactory device placement was achieved in the supine position, the endobronchial cuff of the double-lumen endotracheal tube, or the Univent[®] or Arndt balloons were deflated. For the bronchial blockers (Univent[®] and Arndt), after the cuff was deflated, the blocker was also advanced 1 cm deeper into the airway before starting lateral decubitus positioning. This was done to limit blocker dislodgement when patients were turned.

Once patients were in the lateral decubitus position, endobronchial cuff inflation was performed, and tube placement was reassessed *via* fiberoptic bronchoscopy. Before extubation, fiberoptic bronchoscopy was performed in all patients to observe any damage to the tracheal or bronchial mucosa.

Statistical Analysis

Based on previous studies,³ the sample size was calculated to permit the detection of at least a 2-min differ-

Table 2. Surgical Procedures Requiring One-lung Ventilation

	Double-lumen Endotracheal Tube Group (n = 22)	Univent [®] Group (n = 22)	Arndt [®] Group (n = 22)
Lung biopsy	0	1	0
Lung wedge resection	7	6	10
Segmentectomy	0	1	0
Lobectomy	8	9	9
Pericardial window	1	0	0
Mediastinal mass resection	0	3	0
Esophageal surgery	3	1	0
Sympathectomy	0	1	0
Lingulectomy	0	0	1
Hiatal hernia repair	0	0	2
Wedge resection + pleurodesis	1	0	0
Lobectomy + pleurodesis	2	0	0

ence between any two groups in the time to device placement, with an α of 0.05 and power of 0.80.

Values are expressed as median with 25th–75th percentile (interquartile range) unless otherwise specified. The log-rank test was used to compare time to successful tube positioning of the three device types (double-lumen endotracheal tube *vs.* Univent[®] *vs.* Arndt Blocker[®] in the supine position). Failed attempts were considered as censored at the time of positioning of the failed attempt in the analysis of tube positioning time. The distribution of cumulative percentage of the devices correctly positioned after 4, 6, 8, and 10 min was calculated using Kaplan-Meier curves.

The proportion of failed attempts was compared among the devices, controlling for anesthesiologist, and between anesthesiologists (faculty *vs.* senior resident), controlling for device, using the Cochran-Mantel Haenszel statistic. The Kruskal-Wallis test was used to compare the number of fiberoptic bronchoscopies performed in the supine position and the total number of fiberoptic bronchoscopies among the three devices. The Wilcoxon rank sum test was used to compare the number of fiberoptic bronchoscopies in the successful and failed studies.

Results

The surgical procedures performed are listed in table 2. The number of thoroscopies and thoracotomies in each group did not significantly differ, nor did the numbers of left- and right-sided procedures.

The three groups of patients studied were equivalent with regard to age, weight, and sex. In the double-lumen endotracheal tube group, the tube sizes were 35 French (n = 3), 37 French (n = 6), 39 French (n = 5), and 41 French (n = 8). Univent[®] bronchial blockers placed were 7.5-mm ID (n = 5) and 8.0-mm ID (n = 17). Single-lumen endotracheal tubes for the Arndt Blocker[®]

Table 3. Failed Device Placement among Participating Anesthesiologists of 17 Faculty and 11 Senior Residents

Device	Total (for All Anesthesiologists)			Faculty			Senior Residents			Compare Faculty vs. Residents
	n	Failures		n	Failures		n	Failures		
		Count	Percent (95% CI)		Count	Percent (95% CI)		Count	Percent (95% CI)	
Total (all devices)	66	25	38 (26–51)	44	17	39 (24–55)	22	8	36 (17–59)	$P = 0.87^*$
DLT	22	8	36 (17–59)	14	7	50 (23–77)	8	1	13 (0–53)	$P = 0.17$
Univent®	22	7	32 (14–55)	15	3	20 (4–48)	7	4	57 (18–90)	$P = 0.14$
Arndt®	22	10	45 (24–68)	15	7	47 (21–73)	7	3	43 (10–82)	$P = 1.0$
Compare among devices		$P = 0.65^\dagger$			$P = 0.20$			$P = 0.22$		

* Controlling for device. † Controlling for anesthesiologist (faculty or resident).

CI = confidence interval; DLT = double-lumen endotracheal tube.

9.0F were 8.0-mm ID ($n = 5$), 8.5-mm ID ($n = 16$), and 9.0-mm ID ($n = 1$).

As shown in table 3, participating anesthesiologists failed to achieve proper position of the one-lung ventilation device in 25 of 66 patients (38%; 95% confidence interval, 26–51%). Figure 1 shows the success/failure studies for each device for faculty or senior residents. There was no significant difference among the three devices in the frequency of failure ($P = 0.65$; table 3). There was no significant difference between faculty and senior residents in the frequency of failure ($P = 0.87$; table 3). The reasons for failed studies for the three groups are listed in table 4.

The failed attempts were included in the analysis but were considered as censored at the time of positioning of the failed attempt. The median times (interquartile range = 25th–75th percentile) for placement of the devices are shown in table 5. There was no significant difference in time to successful tube positioning among the three devices (log-rank test, $P = 0.45$). After a failed placement was identified, it took between 10 and 105 additional seconds for the supervising anesthesiologist to achieve optimal position of any of the three devices studied.

There was no significant difference among the three devices in the number of fiberoptic bronchoscopies performed ($P = 0.85$ for supine; $P = 0.99$ for total). Comparison between successful and failed device placements showed that failed studies had required a significantly greater number of fiberoptic bronchoscopies than the successful studies during supine placement ($P < 0.0001$) as well as in total ($P < 0.0001$).

There were no recognized complications as a result of tube placement or one-lung ventilation. No abnormal findings were found in the tracheal or bronchial mucosa during bronchoscopic examination before withdrawal of these tubes.

Discussion

With the increasing demand for one-lung ventilation in both thoracic surgery and other procedures (e.g., spine

surgery), identifying the most effective device (double-lumen endotracheal tube or bronchial blocker) for the anesthesiologist with limited experience in lung isolation techniques would benefit our patients. However, we were unable to demonstrate any advantage associ-

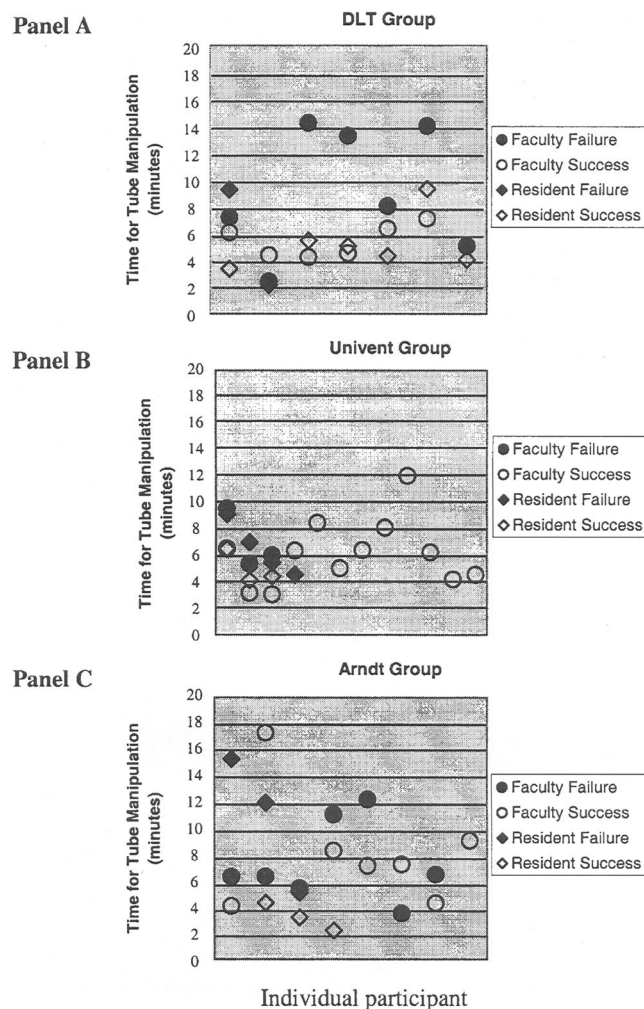


Fig. 1. Displays the success/failure of studies for each device for faculty or senior residents. X represents the number of subjects in each group (individual participants), and Y represents the time that it took to place the device. (A) Double-lumen tube (DLT) group, (B) Univent® group, and (C) Arndt® group.

Table 4. Reasons for Failure

Double-lumen endotracheal tube group	(n = 8)
DLT too far out (endobronchial lumen in the trachea)	3
Unable to identify tracheal or bronchial anatomy	2
Endobronchial cuff herniated above the tracheal carina	2
DLT too far in (endobronchial lumen occluding the entrance of left upper lobe)	1
Univent® group	(n = 7)
Bronchial blocker placed in the bronchus intermedius	2
Bronchial blocker fully inflated in the trachea	1
Bronchial blocker placed in the opposite bronchus	1
Bronchial blocker herniated above the tracheal carina	1
Bronchial blocker too far into the left bronchus	1
Univent tube too far in, unable to position bronchial blocker in the right mainstem bronchus	1
Arndt group	(n = 10)
Bronchial blocker herniated above the tracheal carina	3
Unable to identify tracheal-bronchial anatomy	2
Bronchial blocker too far in	2
Bronchial blocker placed in the bronchus intermedius	1
Bronchial blocker placed in the opposite bronchus	1
Bronchial blocker inflated in the trachea	1

DLT = double-lumen endotracheal tube.

ated with the use of any of the three devices tested. In fact, we observed a high incidence of placement failure or device malpositioning with all three techniques. Failure to properly place the three devices was similar

among faculty (39%) and senior residents (36%) despite each participant having received a tutorial before each study.

Previous studies have shown that time for successful tube placement of a double-lumen endotracheal tube or bronchial blocker range from 2 to 3 min among anesthesiologists with special interest and expertise in thoracic anesthesia.³ In contrast, in this study, the time for successful placement (correct placement only) averaged between 6 and 9 min, regardless of the device used. The long placement time and high malposition rate suggest (although do not prove) that the common problem may be unfamiliarity with anatomical landmarks or with the use of fiberoptic bronchoscopes.

Brodsky *et al.*¹¹ suggest that for anesthesiologists who only occasionally use a double-lumen endotracheal tube in their practice, adjuncts such as fiberoptic bronchoscopy are extremely helpful and should be used. Although we did not compare tube placement with or without fiberoptic bronchoscopy and hence cannot determine whether its use altered success rates, our study does suggest that fiberoptic bronchoscopy is often not sufficient to ensure success. A second associated problem was difficulty encountered while using the fiberoptic bronchoscope along with the device (e.g., the double-lumen endotracheal tube endobronchial cuff fully inflated within the trachea) and inability to continue the placement of the tube within the left bronchus. Several experts in thoracic anesthesia have advocated the use of fiberoptic bronchoscopy to place lung isolation devices and diagnose and correct malpositions (Campos,⁷ Brodsky and Lemmens,¹¹ Slinger,¹⁵ and Benumof¹⁶).

Malposition of a double-lumen endotracheal tube or bronchial blocker can result in either a lack of lung collapse or progressive desaturation. One study has

Table 5. Time for Placement of the Devices

Group	Time to Successful Positioning, Median (25th–75th Percentile), min	Cumulative Percentage of Successfully Positioned Device from Kaplan-Meier Curve		Compare Successful Positioning Distribution among Devices
		Minutes from Start	Cumulative Percentage (95% CI)	
DLT	6.1 (4.6–>9.5*)	4	9 (1–57)	Log-rank test, <i>P</i> = 0.45
		6	48 (22–83)	
		8	64 (34–92)	
		10	73 (39–97)	
Univent®	6.7 (4.9–8.7)	4	9 (1–57)	
		6	32 (11–71)	
		8	63 (31–93)	
		10	78 (43–98)	
Arndt Blocker®	8.5 (5.7–17.5)	4	9 (0.2–62)	
		6	29 (9–70)	
		8	49 (21–87)	
		10	64 (31–94)	

* 75th percentile not defined because only 73% were successfully positioned, with the longest observed time for successful positioning at 9.5 min.

DLT = double-lumen endotracheal tube.

shown that if the double-lumen endotracheal tube is malpositioned after the patient is turned into the lateral decubitus position, there is an increased incidence of hypoxemia during attempted one-lung ventilation.¹⁷ Also, previous studies have shown that the incidence of malpositions, if recognized, can be corrected after the tubes are placed.^{3,8,9} In the current study, greater than 90% of the malpositions occurred after initial placement in the supine position and were not recognized by the participating anesthesiologist.

The definition of malposition may have introduced observer bias and may have increased the probability of a type II error. In some cases, the endotracheal tube (device) might have functioned well despite being "malpositioned" as with a bronchial cuff herniation, tube position characteristics that would likely result in incomplete lung deflation or desaturation. However, in many cases, the nature of the malpositioning would have made lung deflation impossible if not corrected. Additional bias may be introduced by the fact that a single investigator (J. H. C.) determined tube malposition. However, this feature of the study design reduces variability in the determination of malposition. When malposition was identified, approximately 1 min was necessary to correct the problem by the supervising anesthesiologist. This effectively eliminates the possibility that malpositioning was due to some unique anatomical difficulty.

To date, there is no clinical trial that defines the experience necessary for proficiency in lung isolation techniques. It is important during training that every trainee become knowledgeable not only about the devices themselves, but about fiberoptic bronchoscopy techniques and tracheobronchial anatomy. Also, anesthesiologists with limited experience in one-lung ventilation devices should have more exposure to these types of devices. Perhaps a different teaching method, such as an anatomical simulator that combines correct placement of the devices along with correct fiberoptic bronchoscopy technique, would help the anesthesiologist with limited experience to gain more experience.

In conclusion, this study demonstrates a high rate of unrecognized malpositions among anesthesiologists with limited experience in lung isolation when placing a left-sided double-lumen endotracheal tube, Univent[®]

blocker, or Arndt Blocker[®]. In this study, no device provided an advantage to the anesthesiologist with limited experience in thoracic anesthesia. Therefore, the limiting factor was not the device itself. A review of the malpositions indicates that a combination of unfamiliarity with tracheobronchial anatomy and skill in fiberoptic bronchoscopy was responsible for most of the malpositions. Further studies are needed to compare the effectiveness of different methods to teach correct placement of lung isolation devices.

References

1. Campos JH: Current techniques for perioperative lung isolation in adults. *ANESTHESIOLOGY* 2002; 97:1295-302
2. Campos JH: An update on bronchial blockers during lung separation techniques in adults. *Anesth Analg* 2003; 97:1266-74
3. Campos JH, Kernstine KH: A comparison of left-sided Broncho-cath[®] with the torque control blocker Univent[®] and the wire guided blocker. *Anesth Analg* 2003; 96:283-89
4. Björk VO, Carlens E: The prevention of spread during pulmonary resection by the use of a double-lumen catheter. *J Thorac Surg* 1950; 20:151-7
5. Inoue H, Shohtsu A, Ogawa J, Kawada S, Koide S: New device for one-lung anesthesia: endotracheal tube with movable blocker. *J Thorac Cardiovasc Surg* 1982; 83:940-1
6. Arndt GA, DeLessio ST, Kranner PW, Ceranski B, Valtysson B: One-lung ventilation when intubation is difficult: Presentation of a new endobronchial blocker. *Acta Anaesthesiol Scand* 1999; 43:356-8
7. Campos JH: Progress in lung separation. *Thoracic Surg Clin* 2005; 15:71-83
8. Campos JH, Massa CF, Kernstine KH: The incidence of right upper-lobe collapse when comparing a right-sided double-lumen tube versus a modified left double lumen tube for a left-sided thoracic surgery. *Anesth Analg* 2000; 90:535-40
9. Campos JH, Massa CF: Is there a better right-sided tube for one-lung ventilation? A comparison of the right-sided double-lumen tube with the single-lumen tube with right-sided enclosed bronchial blocker. *Anesth Analg* 1998; 86:696-700
10. Benumof JL, Partridge BL, Salvatierra C, Keating J: Margin of safety in positioning modern double-lumen endotracheal tubes. *ANESTHESIOLOGY* 1987; 67:729-38
11. Brodsky JB, Lemmens HJM: Left double-lumen tubes: Clinical experience with 1,170 patients. *J Cardiothorac Vasc Anesth* 2003; 17:289-98
12. Ender J, Bury AM, Raumanns J, Schlünken S, Kiefer H, Bellinghausen W, Pety A: The use of a bronchial blocker compared with a double-lumen tube for single-lung ventilation during minimally invasive direct coronary artery bypass surgery. *J Cardiothorac Vasc Anesth* 2002; 16:452-5
13. Bauer C, Winter C, Hentz JG, Ducrocq X, Steib A, Dupeyron JP: Bronchial blocker compared to double-lumen tube for one-lung ventilation during thoracoscopy. *Acta Anaesthesiol Scand* 2001; 45:250-4
14. Benumof JL: Management of the difficult adult airway. *ANESTHESIOLOGY* 1991; 75:1087-110
15. Slinger P: A view of and through double-lumen tubes. *J Cardiothorac Vasc Anesth* 2003; 17:287-8
16. Benumof J: The position of double-lumen tubes should be routinely determined by fiberoptic bronchoscopy. *J Cardiothorac Vasc Anesth* 1993; 7:513-4
17. Inoue S, Nishimine N, Kitaguchi K, Furuya H, Taniguchi S: Double lumen tube location predicts tube malposition and hypoxemia during one lung ventilation. *Br J Anaesth* 2004; 92:195-201