

Postsurgical Safety of Opioid-sparing Cyclooxygenase-2 Inhibitors

To the Editor:—We read with great interest the excellent meta-analysis by Marret *et al.*¹ and the accompanying editorial by Professor Kehlet² on the effects of combined opioid and nonsteroidal antiinflammatory drugs (NSAIDs) use to relieve postsurgical pain. Marret *et al.* conclude that NSAIDs (cyclooxygenase 2 [COX-2] selective and nonselective), in the aggregate, provide approximately 30% reduction in morphine consumption, with associated reductions in postoperative nausea and vomiting and sedation, but not pruritus, urinary retention, and respiratory depression. Although the *efficacy* data support the use of multimodal analgesia involving opioids and COX-2 selective NSAIDs, we believe the safety data on the *short-term* perioperative use of COX-2 selective inhibitors are less than clear for the following reasons.

First, the US New Drug Application for rofecoxib was based almost exclusively on studies in patients with chronic pain. Studies to directly support the postsurgical pain indication consisted of 741 patients, of whom 85% received one dose for dental pain and 15% received five doses for orthopedic pain.³ Marret *et al.* note that the cardiovascular risk of rofecoxib was associated with “long-term use.” However, in the absence of robust studies in high-risk surgical patients and based on data on parecoxib, one cannot preclude similar safety risks with short-term postsurgical use of rofecoxib.

Second, although parecoxib (the injectable prodrug of the now withdrawn valdecoxib) is an effective analgesic, there remain serious unanswered questions about the safety of short-term use in the postsurgical setting. An important early adverse postsurgical safety signal came from a coronary artery bypass graft study included in the original US New Drug Application.⁴ In the parecoxib and valdecoxib group, 19.0% had serious adverse events, *versus* 9.9% in the placebo group. Citing deficiencies in the data, including a numerically higher incidence of myocardial infarctions (1.9% *vs.* 0.7%) and cerebrovascular events (2.6% *vs.* 0.7%) and deaths (4 *vs.* 0), parecoxib received a nonapprovable letter from the Food and Drug Administration in 2001. The Food and Drug Administration concluded that “the adverse event profile of parecoxib was generally worse than that of placebo in this trial. Although not statistically significantly different, the number of deaths, myocardial infarctions, cerebrovascular accidents, pulmonary embolisms, along with renal and pulmonary complications were also numerically more frequent for parecoxib during this IV dosing period than placebo. In fact, during the entire study period, the incidence of these clinically relevant adverse events associated with parecoxib/valdecoxib was statistically significantly different than placebo. Similarly, during the entire study period, more patients in the parecoxib/valdecoxib *versus* the placebo group withdrew from the study due to an adverse event.”⁵

Third, follow-up studies conducted with parecoxib have raised additional safety issues. In one trial,⁶ cardiovascular events (including

Dr. Babul works at TheraQuest, a pharmaceutical company involved in the development of opioid and non-opioid analgesics, including nonsteroidal antiinflammatory drugs, for acute pain and chronic pain. All three authors have consulted with and participated as investigators in analgesic clinical trials for a variety of pharmaceutical companies. David C. Wartier, M.D., Ph.D., acted as Handling Editor for this exchange. The above letter was sent to the author of the referenced Editorial View. The author did not feel that a response was required. —Michael M. Todd, Editor-in-Chief

* Food and Drug Administration Summary Basis for Approval for Vioxx, NDA 21-042. Available at: <http://www.fda.gov/cder/drug/>. Accessed September 21, 2005.

† Food and Drug Administration Medical Officer Review: Parecoxib NDA 21-294. <http://www.fda.gov/cder/drug/>. Accessed September 21, 2005.

myocardial infarction, cardiac arrest, stroke, and pulmonary embolism) occurred significantly more frequently in the parecoxib and valdecoxib group than with placebo (2.0% *vs.* 0.5%; $P = 0.03$). In another trial,⁴ there were significantly more sternal wound infections with parecoxib than with placebo (3.2% *vs.* 0%; $P = 0.03$).

Fourth, 3 yr ago, the European Medicines Evaluation Agency issued a public statement on parecoxib regarding the risk of serious hypersensitivity and skin reactions, including Stevens-Johnson syndrome, toxic epidermal necrolysis, erythema multiforme, and exfoliative dermatitis, as well as anaphylaxis and angioedema.⁵ The European Medicines Evaluation Agency has since contraindicated the use of parecoxib in patients with ischemic heart disease and stroke. Excluding individuals with silent ischemia, this translates to approximately 20 million at-risk patients in the United States. Immediately before its withdrawal in the United States, the Food and Drug Administration required a similarly worded box warning for valdecoxib. Notably, the warning indicated (1) a higher risk of serious skin reactions within the first 2 weeks, (2) a greater propensity for such reactions with valdecoxib than other COX-2 inhibitors, and (3) a recommendation to discontinue valdecoxib at the first appearance of skin rash. Since self-limiting pruritus and hypersensitivity are common in the postsurgical setting, causality assessment in patients with early signs of serious and unrelated skin reactions may prove difficult.

Fifth, there are indications that the increased COX-2 levels observed under pathologic conditions in endothelial cells and atherosclerotic lesions provides atheroprotection and modulates vascular remodeling through its principal metabolite, prostacyclin.⁶ In addition, in patients with acute pain, there is considerable spinal up-regulation of COX-1, which may provide a further rationale for the use of drugs that inhibit both isoforms of COX in acute pain.

Finally, survey data continue to support the view that postsurgical pain is undertreated. Although the efficacy of COX-2 selective NSAIDs such as parecoxib is comparable to nonselective NSAIDs, further safety data are required to support their short-term use in the perioperative setting.

Najib Babul, Pharm.D.,‡ Paul Sloan, M.D., Arthur G. Lipman, Pharm.D. ‡TheraQuest Biosciences, Blue Bell, Pennsylvania. nbabul@theraquestinc.com

References

1. Marret E, Kurdi O, Zufferey P, Bonnet F: Effects of nonsteroidal antiinflammatory drugs on patient-controlled analgesia morphine side effects: Meta-analysis of randomized controlled trials. *ANESTHESIOLOGY* 2005; 102:1249–60
2. Kehlet H: Postoperative opioid sparing to hasten recovery: What are the issues? *ANESTHESIOLOGY* 2005; 102:1083–5
3. Nussmeier NA, Whelton AA, Brown MT, Langford RM, Hoelt A, Parlow JL, Boyce SW, Verburg KM: Complications of the COX-2 inhibitors parecoxib and valdecoxib after cardiac surgery. *N Engl J Med* 2005; 352:1081–91
4. Ott E, Nussmeier NA, Duke PC, Feneck RO, Alston RP, Snabes MC, Hubbard RC, Hsu PH, Saidman IJ, Mangano DT: Efficacy and safety of the cyclooxygenase 2 inhibitors parecoxib and valdecoxib in patients undergoing coronary artery bypass surgery. *J Thorac Cardiovasc Surg* 2003; 125:1481–92
5. EMEA public statement on parecoxib sodium (Dynastat, Rayzon, Xapit): Risk of serious hypersensitivity and skin reactions EMEA/25175/02 October 22, 2002
6. Egan KM, Lawson JA, Fries S, Koller B, Rader DJ, Smyth EM, Fitzgerald GA: Cyclooxygenase-2-derived prostacyclin confers atheroprotection on female mice. *Obstet Gynecol Surv* 2005; 60:309–10

(Accepted for publication September 21, 2005.)

Anesthesiology 2006; 104:376

© 2006 American Society of Anesthesiologists, Inc. Lippincott Williams & Wilkins, Inc.

In Reply:—We thank Drs. Babul, Sloan, and Lipman for their interest in our meta-analysis,¹ which was primarily performed to study the effects of cyclooxygenase-selective and -nonselective inhibitors on morphine side effects. We agree with them (as we discussed in the article) that some concerns remain about the safety of short-term perioperative prescription of coxibs and that coxibs cannot be administered to all surgical patients, especially patients with coronary artery disease or at risk of cerebral infarction. Two studies have indeed clearly demonstrated that the use of parecoxib and valdecoxib was associated with an increased risk of arterial thrombotic adverse events in patients scheduled to undergo coronary artery bypass surgery.^{2,3} However, some evidence also suggests that short-term perioperative use of coxibs may offer benefits in comparison with nonsteroidal antiinflammatory drugs. For example, tonsillectomy is one of the most frequently performed ambulatory surgical procedures in children, and nonselective inhibition of cyclooxygenase by nonsteroidal antiinflammatory drugs increases significantly the rate of reoperation^{4,5} but also decreases nausea and vomiting.⁵ In that setting, celecoxib, has been demonstrated to relieve posttonsillectomy pain and to decrease bleeding risk in comparison with nonsteroidal antiinflammatory drugs.⁶ Moreover, the risk of adverse cardiovascular events is extremely low in this population of young patients, as it is in patients devoid of arterial thrombotic pathology scheduled to undergo noncardiac surgery. Therefore, short-term perioperative use of coxibs could have a favorable risk-benefit ratio compared with nonsteroidal antiinflammatory

drugs in patients without risk factors for arterial thrombotic events submitted to hemorrhagic surgical procedures.

Emmanuel Marret, M.D.,* Francis Bonnet, M.D. *Tenon University Hospital, Paris, France. emmanuel.marret@tnn.aphp.fr

References

1. Marret E, Kurdi O, Zufferey P, Bonnet F: Effects of nonsteroidal antiinflammatory drugs on patient-controlled analgesia morphine side effects: Meta-analysis of randomized controlled trials. *ANESTHESIOLOGY* 2005; 102:1249-60
2. Nussmeier NA, Whelton AA, Brown MT, Langford RM, Hoefft A, Parlow JL, Boyce SW, Verburg KM: Complications of the COX-2 inhibitors parecoxib and valdecoxib after cardiac surgery. *N Engl J Med* 2005; 352:1081-91
3. Ott E, Nussmeier NA, Duke PC, Feneck RO, Alston RP, Snabes MC, Hubbard RC, Hsu PH, Saidman LJ, Mangano DT: Efficacy and safety of the cyclooxygenase 2 inhibitors parecoxib and valdecoxib in patients undergoing coronary artery bypass surgery. *J Thorac Cardiovasc Surg* 2003; 125:1481-92
4. Marret E, Flahault A, Samama CM, Bonnet F: Effects of postoperative, nonsteroidal, antiinflammatory drugs on bleeding risk after tonsillectomy: Meta-analysis of randomized, controlled trials. *Anesthesiology* 2003; 98:1497-502
5. Moynich S, Romsing J, Dahl JB, Tramer MR: Nonsteroidal antiinflammatory drugs and the risk of operative site bleeding after tonsillectomy: A quantitative systematic review. *Anesth Analg* 2003; 96:68-77
6. Nikanne E, Kokki H, Salo J, Linna TJ: Celecoxib and ketoprofen for pain management during tonsillectomy: A placebo-controlled clinical trial. *Otolaryngol Head Neck Surg* 2005; 132:287-94

(Accepted for publication September 21, 2005.)

Anesthesiology 2006; 104:376

© 2006 American Society of Anesthesiologists, Inc. Lippincott Williams & Wilkins, Inc.

Facilitating Endotracheal Tube Advancement during Fiberscope-assisted Intubation: Giving Due Credit

To the Editor:—Johnson *et al.*'s¹ pictorial documentation of the structures that obstruct the passage of an endotracheal tube during fiberoptic intubation is brilliant and once again proves the usefulness of a 90° counterclockwise rotation of the endotracheal tube to facilitate advancement.²

Unfortunately, they have, like some authors before them, failed to acknowledge the contribution of Dr. Cossham, who first described this technique to facilitate the passage of an endotracheal tube over a gum elastic bougie.³ When passage of an endotracheal tube over a fiberscope is difficult, most clinicians had, hoping to bypass the obstruction, retried while or after twisting the tube left or right—a somewhat haphazard maneuver also mentioned by Ovassapian *et al.*⁴ It was Dr. Cossham, however, who actually clearly illustrated the technique. Whether over a gum elastic bougie or over a flexible bronchoscope, his technique is elegant and proven,⁵ and the principles are the same. It is such a useful “trick” that we believe that the first attempt to advance an endotracheal tube over a flexible bronchoscope should always be made with it already turned counterclockwise by 90°.⁶ Our experience is that the success rate exceeds 90% with only one attempt, thus saving time and reducing the risk of upper airway trauma and unpleasantness for the patient.

Anthony M.-H. Ho, M.S., M.D., F.R.C.P.C., F.C.C.P.,* Manoj K. Karmakar, M.B., M.D., F.R.C.A. *The Chinese University of Hong Kong, Shatin, NT, Hong Kong Special Administrative Region, Peoples' Republic of China. hoamh@cuhk.edu.hk

References

1. Johnson DM, From AM, Smith RB, From RP, Maktabi MA: Endoscopic study of mechanisms of failure of endotracheal tube advancement into the trachea during awake fiberoptic orotracheal intubation. *ANESTHESIOLOGY* 2005; 102:910-4
2. Kristensen MS: The Parker Flex-Tip Tube *versus* a standard tube for fiberoptic orotracheal intubation: A randomized double-blind study. *ANESTHESIOLOGY* 2003; 98:354-8
3. Cossham PS: Difficult intubation (letter). *Br J Anaesth* 1985; 57:239
4. Ovassapian A, Yelich SJ, Dykes MH, Edward EB: Fiberoptic nasotracheal intubation: Incidence and causes of failure. *Anesth Analg* 1983; 62:692-5
5. Dogra S, Falconer R, Latto IP: Successful difficult intubation: Tracheal tube placement over a gum-elastic bougie. *Anaesthesia* 1990; 45:774-6
6. Ho AMH, Chung DC, Karmakar MK: Is the Parker Flex-Tip Tube really superior to the standard tube for fiberoptic orotracheal intubation? (letter). *ANESTHESIOLOGY* 2003; 99:1236

(Accepted for publication October 11, 2005.)

Anesthesiology 2006; 104:377

© 2006 American Society of Anesthesiologists, Inc. Lippincott Williams & Wilkins, Inc.

Corniculate Cartilages Are Wrongly Labeled Arytenoid Cartilages

To the Editor:—The corniculate cartilages are commonly and wrongly referred to as the arytenoid cartilages. This common misconception is well illustrated by the labeling of the figure on the cover of the May 2005 issue of ANESTHESIOLOGY and its accompanying article.¹ The bilateral spherical bulges at the five o'clock and seven o'clock positions on the most proximal part of the laryngeal aperture are the corniculate cartilages,² not the arytenoid cartilages.

Jonathan L. Benumof, M.D., UCSD Medical Center, San Diego, California. jbenumof@ucsd.edu

References

1. Johnson D, From AM, Smith RB, From RP, Maktabi MA: Endoscopic study of mechanisms of failure of endotracheal tube advancement into the trachea during awake fiberoptic orotracheal intubation. ANESTHESIOLOGY 2005; 102:910-4
2. Gray H: Anatomy of the Human Body. Philadelphia, Lea & Febiger, 1918

(Accepted for publication October 11, 2005.)

Anesthesiology 2006; 104:377

© 2006 American Society of Anesthesiologists, Inc. Lippincott Williams & Wilkins, Inc.

Fiberoptic Intubation

To the Editor:—We read with interest the recent report by Johnson *et al.*¹ about problems encountered during fiberoptic intubations. This study validated our findings from 1989, where we showed that difficulty passing an endotracheal tube over a bronchoscope is most commonly due to contact with the right arytenoid.² Similar to Johnson *et al.*, we demonstrated that 90° rotation of the tube should be the first maneuver to advance the tube over the arytenoid.^{2,5} We have formally taught this technique to our residents during the past 10 yr.⁴ Of further interest, we have reported that contact with the right aryepiglottic fold is also the most common cause for difficulty in advancing an endotracheal tube using a Bullard laryngoscope.⁵

Donald Schwartz, M.D., Neil Roy Connelly, M.D.,* Steven M. Dunn, M.D. *Baystate Medical Center, Springfield, Massachusetts. neil.roy.connelly@bhs.org

References

1. Johnson D, From AM, Smith RB, From RP, Maktabi MA: Endoscopic study of mechanisms of failure of endotracheal tube advancement into the trachea during awake fiberoptic orotracheal intubation. ANESTHESIOLOGY 2005; 102:910-4
2. Schwartz D, Johnson C, Roberts J: A maneuver to facilitate flexible fiberoptic intubation (letter). ANESTHESIOLOGY 1989; 71:470-1
3. Connelly NR, Kyle R, Gotta J, Calimaran A, Robbins LD, Kanter G, Dunn SM: Comparison of wire reinforced tubes with warmed standard tubes to facilitate fiberoptic intubation. J Clin Anesth 2001; 13:3-5
4. Dunn S, Connelly NR, Robbins L: Resident training in advanced airway management. J Clin Anesth 2004; 16:472-6
5. Shulman GB, Nordin NG, Connelly NR: Teaching with a video system improves the training period but not subsequent success of tracheal intubation with the Bullard laryngoscope. ANESTHESIOLOGY 2003; 98:615-20

(Accepted for publication October 11, 2005.)

Anesthesiology 2006; 104:377-8

© 2006 American Society of Anesthesiologists, Inc. Lippincott Williams & Wilkins, Inc.

Difficulties in Advancing an Endotracheal Tube over a Fiberoptic Bronchoscope

To the Editor:—I read with interest the report of Johnson *et al.*,¹ assessing the reasons for difficulties in advancing an endotracheal tube over a fiberoptic bronchoscope. They state that their study is the first to provide pictorial evidence of the laryngeal structures that obstruct passage of the endotracheal tube during fiberoptic intubation. I point out that this statement is not correct: I had already shown pictorial evidence of this in 2002, using a method similar to theirs.²

They stated that the right arytenoid and the interarytenoid soft tissues were the sites of resistance to advancement of the endotracheal tube during awake fiberoptic orotracheal intubation.¹ This supports my statement in a review article on this topic that the main reasons for difficulty in advancing a tube over a fiberscope is that the tube tends to move posteriorly to the glottis.^{3,4} Another possible reason for the difficulty, that they did not observe, but I did, was that the endotracheal tube entered the esophageal inlet.²

There have been reports of esophageal intubation despite correct insertion of a fiberscope into the trachea.^{3,4} I have found that a curved tube was often advanced directly into the esophageal inlet, without impacting on the arytenoid cartilage.² In such a case, resistance was felt, not because the tube was impacting on the arytenoids, but because it was pushing the midsegment of the fiberscope into the

esophagus. These findings can explain why rotation of the tube does not always enable the tube into the larynx and why withdrawing the tube for a few centimeters (to remove the tube tip out of the esophagus) before rotating and advancing the tube would often facilitate tracheal intubation. I also have shown that cricoid pressure reduces the difficulty in advancing a tube over a fiberscope, by compressing the esophageal inlet.²

Johnson *et al.* have shown a variable finding that, when a fiberscope is located in contact with the arytenoids, it is more likely to be difficult to advance a tube into the trachea. They also stated that other factors (*e.g.*, awake *vs.* anesthetized) may also have played a role. I suggest that the difference between their and my studies in the incidence of esophageal intubation may be caused by a difference in the head and neck position. Most patients in the study of Johnson *et al.*¹ were neurosurgical cervical spine patients, and optimal positioning of the head and neck were limited, whereas in my study,² the head was placed on a pillow and mildly extended. The esophageal inlet is more likely to be open when the head is extended (imagine that, when one drinks, one would place the head and neck to a similar position to this, to open the esophageal inlet). Therefore, the incidence of an endotracheal tube migrating into the

esophageal inlet, in theory, is reduced by placing the head and neck into the neutral position.

Fiberoptic intubation is an established useful method in patients with difficult airways. Nevertheless, as Johnson *et al.*¹ pointed out, repetitive attempts at advancing a fiberoptic into the trachea and advancing a tube over the scope increase the risk of injury to the larynx and surrounding tissues, leading to bleeding from, or edema of, the tissues. Because the causes of difficulty in tracheal intubation over a fiberoptic and the inefficacy of each solution method have not been elucidated fully, we must continue to study to make fiberoptic intubation safer.

Takashi Asai, M.D., Ph.D., Kansai Medical University, Moriguchi City, Osaka, Japan. asait@takii.kmu.ac.jp

Anesthesiology 2006; 104:378

UNDO Your Troubles with the Tube: How to Improve Your Success with Endotracheal Tube Passage during Fiberoptic Intubation

To the Editor:—The article by Johnson *et al.*¹ once again highlights a problem commonly faced by practitioners using a fiberoptic scope to intubate the trachea, *i.e.*, resistance to passage of the endotracheal tube. As they discuss, this is usually attributed to the endotracheal tube being caught on structures of the supraglottic airway.^{2–6} Johnson *et al.* correctly report that when oral fiberoptic intubation is attempted, the most common cause of obstruction to endotracheal tube placement is the right arytenoid cartilage. The article that best describes the anatomical reasons for endotracheal tube obstruction is based on observation of obstruction to endotracheal tube placement in an intubating mannequin.³ Unfortunately, Johnson *et al.* neglect to credit this investigation, which found the same cause of obstruction, albeit not in human subjects, as they now report. In addition, as we reported in a letter to the editor of this journal, we have had years of experience with a high degree of successful oral endotracheal tube passage over the fiberoptic in children and adults using the method of *beginning* with the bevel in the down position or facing posteriorly.⁷ For example, in one of our recent publications examining the best method to teach fiberoptic intubation to residents, we found a high degree of successful initial endotracheal tube passage over the fiberoptic. By paying strict attention to bevel orientation, we had only 3 failures of 300 intubation attempts that were secondary to inability to pass the endotracheal tube.⁸ Overall, intubation was successful in 292 of 300 attempts; the 5 additional failures were secondary to being unable to correctly place the fiberoptic.⁸ This is a far higher success rate than the 50% obstruction Johnson *et al.* report when the bevel orientation is not down or posterior. It should also be noted that anatomical obstruction for nasal intubation differs.³ In this case, obstruction is usually secondary to the epiglottis, and, as we have advocated and continue to teach, when nasal intubation is performed, the bevel

Anesthesiology 2006; 104:378–9

Markedly Displaced Arytenoid Cartilage during Fiberoptic Orotracheal Intubation

To the Editor:—We read with great interest the article by Johnson *et al.*¹ in which the right arytenoid inhibited the advancement of the endotracheal tube (ETT) into the trachea during awake fiberoptic oro-tracheal intubation. We have been observing the process of oral fiberoptic

References

1. Johnson DM, From AM, Smith RB, From RP, Maktabi MA: Endoscopic study of mechanisms of failure of endotracheal tube advancement into the trachea during awake fiberoptic oro-tracheal intubation. *ANESTHESIOLOGY* 2005; 102:910–4
2. Asai T, Murao K, Johmura S, Shingu K: Effect of cricoid pressure on the ease of fiberoptic-aided tracheal intubation. *Anaesthesia* 2002; 57:909–13
3. Asai T, Shingu K: Difficulty in advancing a tracheal tube over a fiberoptic bronchoscope: Incidence, causes and solutions. *Br J Anaesth* 2004; 92:870–81
4. Koga K, Asai T, Latto IP, Vaughan RS: Effect of the size of a tracheal tube and the efficacy of the use of the laryngeal mask for fiberoptic-aided tracheal intubation. *Anaesthesia* 1997; 52:131–5

(Accepted for publication October 11, 2005.)

© 2006 American Society of Anesthesiologists, Inc. Lippincott Williams & Wilkins, Inc.

orientation should be up or facing anteriorly to assure the highest rate of successful endotracheal tube passage. An easy mnemonic to assist in remembering the endotracheal tube orientation is “*UNDO* your troubles with the tube”—*i.e.*, bevel *Up* for Nasal fiberoptic intubation and bevel *Down* for Oral fiberoptic intubation.

Melissa Wheeler, M.D.,* Richard M. Dsida, M.D. *Feinberg School of Medicine, Northwestern University, Chicago, Illinois. melissa-wheeler@msn.com

References

1. Johnson DM, From AM, Smith RB, From RP, Maktabi MA: Endoscopic study of mechanisms of failure of endotracheal tube advancement into the trachea during awake fiberoptic oro-tracheal intubation. *ANESTHESIOLOGY* 2005; 102:910–4
2. Ovassapian A, Yelich SJ, Dykes MH, Brunner EE: Fiberoptic nasotracheal intubation: Incidence and causes of failure. *Anesth Analg* 1983; 62:692–5
3. Katsnelson T, Frost EA, Farcon E, Goldiner PL: When the endotracheal tube will not pass over the flexible fiberoptic bronchoscope. *ANESTHESIOLOGY* 1992; 76:151–2
4. Kristensen MS: The Parker Flex-Tip tube *versus* a standard tube for fiberoptic oro-tracheal intubation: A randomized double-blind study. *ANESTHESIOLOGY* 2003; 98:354–8
5. Schwartz D, Johnson C, Roberts J: A maneuver to facilitate flexible fiberoptic intubation. *ANESTHESIOLOGY* 1989; 71:470–1
6. Jones HE, Pearce AC, Moore P: Fiberoptic intubation: Influence of tracheal tube tip design. *Anaesthesia* 1993; 48:672–4
7. Wheeler M, Dsida RM: Fiberoptic intubation: Troubles with the “tube.” *ANESTHESIOLOGY* 2003; 99:1236–7
8. Wheeler M, Roth AG, Dsida RM, Rae B, Seshadri R, Sullivan CL, Heffner CL, Cote CJ: Teaching residents pediatric fiberoptic intubation of the trachea: Traditional fiberoptic with an eyepiece versus a video-assisted technique using a fiberoptic with an integrated camera. *ANESTHESIOLOGY* 2004; 101:842–6

(Accepted for publication October 11, 2005.)

© 2006 American Society of Anesthesiologists, Inc. Lippincott Williams & Wilkins, Inc.

intubation during general anesthesia with the use of the similar double-fiberoptic technique and reported a case in which the right arytenoid cartilage prevented the ETT passage and the tube rotation solved the problem.² This problem often occurs not only during awake

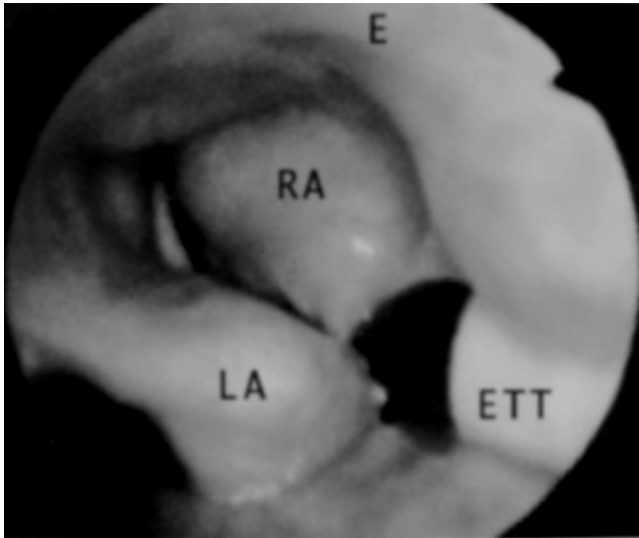


Fig. 1. View of the larynx during fiberoptic intubation through the second fiberscope passed nasally. The right arytenoid (RA) is markedly displaced by the endotracheal tube (ETT) threaded over the fiberscope for intubation. E = epiglottis; LA = left arytenoid.

fiberoptic intubation but during general anesthesia. Moreover, we experienced a case in which the ETT threaded over the fiberscope displaced the right arytenoid markedly despite gentle tube advancement (fig. 1). In this case, the operator could not feel the resistance until the ETT displaced the arytenoid markedly because the laryngeal tissues were soft, floppy, and relaxed. Therefore, we agree with the authors that this problem can lead to serious laryngeal injury and should be solved.

To avoid this problem, the authors recommend that the fiberscope should be placed in the center of the larynx before tube advancement. However, in usual intubation situations, the fiberscope itself cannot be seen, and the position relative to the larynx

cannot be identified. The fiberscope position may be changed during tube advancement. When the ETT cannot be passed into the trachea, the operator cannot identify whether the fiberscope is placed in the center. Therefore, it would be difficult to control the fiberscope position in the center of the larynx. For successful intubation, we should carefully consider other factors (*i.e.*, the size and type [design] of the ETT,^{3,4} the fiberscope size,⁵ and the sleeve for the fiberscope^{6,7}) before the intubation procedure. In any case, the ETT should be rotated at the first tube advancement.

Finally, regarding the study method, when the nasally placed second fiberscope for observation of the intubation procedure is positioned in the center against the larynx, it may be difficult for the operator to introduce the fiberscope for intubation in the center. If the fiberoptic view for observation is obtained from the left or right side, the intubating fiberscope position looks near another side. It seems to be difficult to identify the "true" fiberscope position.

Kazuyoshi Aoyama, M.D.,* Ichiro Takenaka, M.D. *Nippon Steel Yawata Memorial Hospital, Kitakyushu, Japan.
aoyama.k@ns.yawata-mhp.or.jp

References

1. Johnson DM, From AM, Smith RB, From RP, Maktabi MA: Endoscopic study of mechanisms of failure of endotracheal tube advancement into the trachea during awake fiberoptic orotracheal intubation. *ANESTHESIOLOGY* 2005; 102:910-4
2. Aoyama K, Takenaka I, Sata T, Shigematsu A: Use of the fibroscope-video camera system for difficult tracheal intubation. *Br J Anaesth* 1996; 77:662-4
3. Brull SJ, Wiklund R, Ferris C, Connelly NR, Ehrenwerth J, Silverman DG: Facilitation of fiberoptic orotracheal intubation with a flexible tracheal tube. *Anesth Analg* 1994; 78:746-8
4. Greer JR, Smith SP, Strang T: A comparison of tracheal tube tip designs on the passage of an endotracheal tube during oral fiberoptic intubation. *ANESTHESIOLOGY* 2001; 94:729-31
5. Hakala P, Randell T: Comparison between two fiberscopes with different diameter insertion cords for fiberoptic intubation. *Anaesthesia* 1995; 50:735-7
6. Ayoub CM, Rizk MS, Yaacoub CI, Baraka AS, Lteif AM: Advancing the tracheal tube over a flexible fiberoptic bronchoscope by a sleeve mounted on the insertion cord. *Anesth Analg* 2003; 96:290-2
7. Aoyama K, Yasunaga E, Takenaka I: Another sleeve for fiberoptic tracheal intubation. *Anesth Analg* 2003; 97:1205-6

(Accepted for publication October 11, 2005.)

Anesthesiology 2006; 104:379-80

© 2006 American Society of Anesthesiologists, Inc. Lippincott Williams & Wilkins, Inc.

In Reply:—I am delighted with the interest our recent article¹ sparked, and I thank the Editor-in-Chief for this opportunity to respond. I find common themes in all six letters. First, the subject of fiberoptic intubation is interesting and important. Second, more research is needed in this field. Third, several of the authors reported in one way or another in letters to the editor or clinical reports that endotracheal tubes stop at the arytenoid during fiberoptic intubation. Fourth, clinical observations in correspondences or clinical reports are good sources of ideas for rigorous scientific studies. Finally, for the record, Dana Johnson is not an M.D. yet. She is an outstanding medical student at the Carver College of Medicine at The University of Iowa (Iowa City, Iowa). I thank all of the authors for their insightful remarks and their interest in our article.

I agree with Drs. Ho and Karmakar that Cossham, in a letter to the editor in 1985, described the technique of inserting an endotracheal tube turned 90° counterclockwise over a gum elastic bougie in anesthetized patients.² I did refer to Cossham's letter in a previous article that described three cases of trauma to the airway by fiberoptic intubation.³ This was not the focus of the study and I certainly do not claim that I introduced this technique. The focus was to identify the structures that inhibit endotracheal tube advancement over a fiberoptic

bronchoscope. I believe this goal was achieved. I apologize for not referring again to Dr. Cossham's contribution.

Dr. Benumof is right, and I am right too. The corniculate cartilage is different from the arytenoid cartilage, although they are intimately related. According to Gray's *Anatomy*, the arytenoid cartilage is described in this fashion: "The apex of each cartilage is pointed, curved backward and medialward, and surmounted by a small conical, cartilaginous nodule, the corniculate cartilage" and also in this fashion: "The corniculate cartilages (*cartilagine corniculatae cartilages of Santorini*) are two small conical nodules consisting of yellow elastic cartilage, which articulate with the summits of the arytenoid cartilages and serve to prolong them backward and medialward." Also according to Gray's *Anatomy*, another small cartilage, the cuneiform cartilage, also sits on the apex of the arytenoid cartilage.⁴ Both corniculate and cuneiform cartilages may or may not be present in humans. The arytenoid is the one that dislocates after traumatic intubations, not the corniculate or the cuneiform. In the medical community, the term *arytenoid* is the one in common use and refers to the arytenoid complex, which encompasses all three structures. When the progress of the endotracheal tube is inhibited by the arytenoid cartilage, the tip of the tube may be stopped at the top of the arytenoids where the corniculate and the cuneiform cartilages are located, or it may reach all

the way to the posterolateral aspect of the arytenoid cartilage at the cricoarytenoid junction, as is well illustrated in figure 1A of our article.¹

I am aware of the remark of Schwartz *et al.*⁵ in a letter to the editor in 1989, and I apologize for not referring to it.

Dr. Asai, I read your article, Asai *et al.*,⁶ as well as your many other writings on fiberoptic intubation. In your article, you used two fiberoptic bronchoscopes simultaneously, as I did in my research,¹ one inserted orally and the other inserted through the nose. Having said that, I stand behind my statement that "our study is the first to provide pictorial evidence of the laryngeal structures that obstruct the passage of the [endotracheal tube] during fiberoptic intubation." In your article, you report that in 2 of 10 patients, the arytenoid cartilage stopped the advancement of the endotracheal tube. This is a perfectly valid clinical observation that was not supported by statistical analysis. I do agree that during the process of threading the tube over a bronchoscope, it is possible for the tube to enter the esophagus, although I did not make this observation in clinical practice or research.

In the article, I studied only oral fiberoptic intubation. I did not study nasal fiberoptic intubation. I agree with Drs. Wheeler and Dsida that the dynamics of threading the endotracheal tube are different in both types of intubations. With regard to oral fiberoptic intubation, the dynamics and the motility of the larynx and threading the endotracheal tube are widely variable between awake and anesthetized patients, let alone adding a plastic static human mannequin model into the comparison. Therefore, comparisons between a success rate of 298 in 300 in your study in threading the endotracheal tube in anesthetized patients⁷ and my success rate (50%) in awake patients should not be made, because they are two different clinical situations.

In Aoyama *et al.*,⁸ you made a valid clinical observation of the

endotracheal tube stopping at the arytenoid cartilage. I did not encounter significant difficulties in determining the position of the fiberoptic in relation to the arytenoids because, as shown in the pictures, the nasal fiberoptic came very close to the oral fiberoptic and the laryngeal structures. As you and Dr. Wheeler mention in your letters, there are many methods to facilitate successful threading of the endotracheal tube over the fiberoptic.

Mazen A. Maktabi, M.D., The University of Iowa, Iowa City, Iowa.
mazen-maktabi@uiowa.edu

References

1. Johnson D, From A, From RP, Smith R, Maktabi MA: Endoscopic study of laryngeal structures that obstruct smooth threading of the endotracheal tube during transoral fiberoptic intubation. *ANESTHESIOLOGY* 2005; 102:910-4
2. Cossam PS: Difficult intubation (letter). *Br J Anaesth* 1985; 57:239
3. Maktabi MA, From RP, Hoffman H, Funk G: Trauma to the larynx during awake fiberoptic intubation. *Anesth Analg* 2002; 95:1112-4
4. Gray H: Anatomy of the Human Body. Philadelphia, Lea & Febiger, 1918
5. Schwartz D, Johnson C, Roberts J: A maneuver to facilitate flexible fiberoptic intubation (letter). *ANESTHESIOLOGY* 1989; 71:470-1
6. Asai T, Murao K, Johmura S, Shingu K: Effect of cricoid pressure on the ease of fiberoptic-aided tracheal intubation. *Anaesthesia* 2002; 57:909-13
7. Wheeler M, Roth AG, Dsida RM, Rae B, Seshadri R, Sullivan CL, Heffner CL, Cote CJ: Teaching residents pediatric fiberoptic intubation of the trachea: Traditional fiberoptic with an eyepiece *versus* a video-assisted technique using a fiberoptic with an integrated camera. *ANESTHESIOLOGY* 2004; 101:842-6
8. Aoyama K, Takenaka I, Sata T, Shigematsu A: Use of the fiberoptic-video camera system for difficult tracheal intubation. *Br J Anaesth* 1996; 77:662-4

(Accepted for publication October 11, 2005.)

Anesthesiology 2006; 104:380

© 2006 American Society of Anesthesiologists, Inc. Lippincott Williams & Wilkins, Inc.

Preoxygenation during Pregnancy in the Head-up *versus* the Supine Position

To the Editor:—I read with interest the article of Dixon *et al.*¹ The results show in the class III obese patients that preoxygenation in the 25° head-up position achieves 23% higher oxygen tensions, allowing a clinical increase in the desaturation safety period. The report postulated that preoxygenation in the head-up position may be advantageous in many other clinical circumstances in which respiratory function may be impaired in the supine position, *e.g.*, advanced pregnancy, ascites, bowel obstruction.

Baraka *et al.*² (1992) reported about "Preoxygenation of Pregnant and Nonpregnant Women in the Head-up versus Supine Position." The results showed that after 3 min of preoxygenation, desaturation to 95% during subsequent apnea, as monitored by pulse oximetry, was more rapid in pregnant than in nonpregnant patients. Also, changing from the supine to the 45° head-up position prolonged the desaturation time in the nonpregnant women but had no significant effect in the pregnant women (table 1). These results were unanticipated because a change from the supine to the sitting position has been shown to increase the functional residual capacity in both pregnant³ and nonpregnant patients.⁴ Baraka *et al.* postulated that adopting the 45°

head-up position rather than the sitting position may not significantly increase the functional residual capacity in the pregnant woman at term, because the gravid uterus at term may not allow a significant descent of the diaphragm in the head-up position.

Anis S. Baraka, M.D., F.R.C.A.(Hon), American University of Beirut, Beirut, Lebanon. abaraka@aub.edu.lb

References

1. Dixon BJ, Dixon JB, Carden JR, Bum AJ, Schachter LM, Playfair JM, Laurie CP, O'Brien PE: Preoxygenation is more effective in the 25° head-up position than in the supine position in severely obese patients. *ANESTHESIOLOGY* 2005; 102:1110-5
2. Baraka AS, Hanna MT, Jabbour SI, Nawfal MF, Siba A, Yazbeck VG, Khoury NI, Karam KS: Preoxygenation of pregnant and nonpregnant women in the head-up versus supine position. *Anesth Analg* 1992; 75:757-9
3. Russel IF, Chambers WA: Closing volume in normal pregnancy. *Br J Anaesth* 1981; 53:1043-7
4. Nunn JF: Elastic forces and lung volumes, *Applied Respiratory Physiology*, 3rd edition. Edited by Nunn JF. London, Butterworths, 1987, pp 39-40

(Accepted for publication October 12, 2005.)

Table 1. Preoperative Oxygen Saturation (So₂%) and Times to So₂ 95% in Nonpregnant *versus* Pregnant Patients in the Supine and Head-up Positions

	Nonpregnant Control Groups		Cesarean Delivery Groups	
	Supine (n = 10)	Head-up (n = 10)	Supine (n = 10)	Head-up (n = 10)
Preoperative So ₂ %	98.1 ± 1.5	98.5 ± 9.94	97.5 ± 1.3	97.9 ± 0.77
Time(s) to So ₂ 95%	243 ± 7.4	331 ± 7.2	173 ± 4.8	156 ± 2.8

Anesthesiology 2006; 104:381

© 2006 American Society of Anesthesiologists, Inc. Lippincott Williams & Wilkins, Inc.

Mechanism of Benefit of Head-up Preoxygenation in Obese Patients

To the Editor:—I read with interest the study report in the June 2005 issue of ANESTHESIOLOGY by Dixon *et al.*¹ regarding the benefits of head-up preoxygenation in obese patients. Although I do not dispute the basic findings of the study or the benefit of head-up position in obese patients, I question the conclusions drawn in the abstract and discussion.

Although there was a strong correlation between oxygen tension and time to desaturation, it cannot be concluded that the higher arterial oxygen tension (PaO₂) itself was protective. The oxygen content of blood in the form of dissolved oxygen under nonhyperbaric pressure conditions is minimal. At the preinduction PaO₂ achieved after 3 min of preoxygenation in both supine and head-up subjects, hemoglobin would be expected to be 100% saturated, providing maximal blood oxygen content in both study groups. The additional time to desaturation afforded by the small increase in dissolved oxygen reserve in the head-up group is unlikely to have been significant. More likely, the benefit of head-up positioning in delaying desaturation (as well as

increasing PaO₂) is a result of factors of pulmonary mechanics mentioned in the study background as they relate to oxygen reserve.

Also for this reason, changing the patient's position from head-up to supine at induction as suggested possible to ease intubation may partially or completely negate the benefits of the head-up preoxygenation despite the increased preinduction PaO₂. This repositioning maneuver might be useful in a follow-up study to test this hypothesis.

David B. Wax, M.D., Mount Sinai School of Medicine, New York, New York. david.wax@mssm.edu

Reference

1. Dixon BJ, Dixon JB, Carden JR, Burn AJ, Schachter LM, Playfair JM, Laurie CP, O'Brien PE: Preoxygenation is more effective in the 25° head-up position than in the supine position in severely obese patients. ANESTHESIOLOGY 2005; 102:1110-5

(Accepted for publication October 12, 2005.)

Anesthesiology 2006; 104:381

© 2006 American Society of Anesthesiologists, Inc. Lippincott Williams & Wilkins, Inc.

In Reply:—We thank Drs. Wax and Baraka for their interest in our article on the benefits of the head-up position for preoxygenation in class III obese patients.¹ They draw attention to two aspects of our article.

It is interesting that Dr. Baraka *et al.*² found, in a small study of similar design, no benefit in desaturation safety with preoxygenation in the 45° head-up position in pregnant women at term. Perhaps as speculated, the effect of the gravid uterus on the movement of the diaphragm has a negative impact on lung mechanics. Although the gravid uterus does decrease functional residual capacity, the mechanism and distribution of mass are considerably different to those seen in obesity, and therefore, the favorable effects we found with posture change may not be applicable. Our comments were speculative only, indicating that the head-up position may achieve a prolongation of the desaturation safety period. The gravid uterus may have a varying impact on lung mechanics depending on the posture: supine, 25°, 45°, and sitting up. This is an area for further research because severe obesity and the advanced gravid state are associated with increased difficulty in airway management and higher metabolic rates increasing the risk of hypoxia during anesthetic induction. Oxygen tensions taken in various positions may assist in optimizing preoxygenation, and further investigation into the role of position in preoxygenation should continue in several high-risk groups.

Dr. Wax correctly points out that the dissolved oxygen in blood under atmospheric conditions is trivial and unlikely by itself to alter the desaturation safety period. We agree and indicate within the discussion that the aim is to optimize lung oxygen content by achieving a posture

that provides optimal respiratory mechanics, lung volumes, functional residual capacity, and arterial oxygen tension during preoxygenation. We found a strong correlation between the oxygen tension achieved and the desaturation safety period suggesting that end preoxygenation oxygen tension is an indicator of improved pulmonary oxygen reserves. We speculate that the extended desaturation safety period in head-up subjects is due to continued oxygenation of blood from increased pulmonary reserves and not directly due to the higher initial oxygen tension. In addition, we caution that after head-up preoxygenation, a change to the supine position for intubation may reduce these favorable conditions and shorten the desaturation safety period.

Benjamin J. Dixon, M.B.B.S.,* John B. Dixon, M.B.B.S., Ph.D., Linda M. Schachter, M.B.B.S., F.R.A.C.P., Jennifer R. Carden, M.B.B.S., F.A.N.Z.C.A. *Australian Centre for Obesity Research and Education, Monash University, Melbourne, Australia. john.dixon@med.monash.edu.au

References

1. Dixon BJ, Dixon JB, Carden JR, Burn AJ, Schachter LM, Playfair JM, Laurie CP, O'Brien PE: Preoxygenation is more effective in the 25° head-up position than in the supine position in severely obese patients: A randomized controlled study. ANESTHESIOLOGY 2005; 102:1110-5
2. Baraka AS, Hanna MT, Jabbour SI, Nawfal MF, Sibai AA, Yazbeck VG, Khoury NI, Karam KS: Preoxygenation of pregnant and nonpregnant women in the head-up versus supine position. Anesth Analg 1992; 75:757-9

(Accepted for publication October 12, 2005.)

Sildenafil for Pulmonary Hypertension in Pregnancy?

To the Editor:—We read with interest the comprehensive series presented by Bonnin *et al.*¹ Their report of the treatment of severe pulmonary hypertension (PHTN) during pregnancy in their institution from 1992 to 2002 is a timely reminder of the high maternal and fetal mortality from this condition. We would like to draw the readers' attention to the emerging role of phosphodiesterase inhibitors (PDEs), such as sildenafil, in the treatment of PHTN. Clinical trials have demonstrated that oral sildenafil is effective in the treatment of both acute and chronic PHTN²⁻⁴ of a variety of etiologies.^{5,6} In addition, several recent reports exist of its successful use in pregnant patients with this devastating disease process.^{7,8}

Phosphodiesterase inhibition has been demonstrated to treat PHTN by reducing cyclic guanosine monophosphate breakdown, making pulmonary vascular smooth muscle more sensitive to endogenous and administered nitric oxide.⁹ This reduces ventilation perfusion mismatch and hypoxia.^{3,10} Of the PDE5 inhibitors studied, sildenafil has the greatest selectivity for the pulmonary circulation and arterial oxygenation.¹¹ The use of PDE inhibitors seems safe in both ischemic heart disease¹² and heart failure.¹³ The effect of PDEs on pulmonary vasculature and pulmonary artery pressure has been studied in comparison to and in combination with inhaled iloprost and inhaled nitric oxide,¹⁴⁻¹⁶ and it augments their vasodilatory effects.^{17,18} In fact, sildenafil is at least as effective as inhaled nitric oxide in relaxing the pulmonary vasculature and may have fewer side effects.¹⁹ Coadministration of sildenafil with nitric oxide also leads to less rebound PHTN, a major problem with nitric oxide administration, caused by down-regulation of nitric oxide synthetase.¹⁵

Sildenafil has other potentially beneficial effects in this context. It causes uterine artery vasodilation and has been shown to improve uterine muscle wall thickness in *in vitro* fertilization patients with previous poor endometrial response.²⁰ In addition, sildenafil and nitric oxide are being used successfully to treat preterm and term neonatal and childhood PHTN.^{21,22}

The therapeutic potential of sildenafil in the treatment of PHTN during pregnancy awaits definitive demonstration in the form of a clinical trial. However, its proven effectiveness and safety in other forms of pulmonary hypertension, coupled with ease of oral administration and its apparent lack of teratogenicity, mean that it is a highly promising therapy for severe pulmonary hypertension in pregnant patients.

Tadhg D. Lynch, M.B., B.Ch., B.A.O.,* John G. Laffey, M.D.
*University College Hospital Galway, Galway, Ireland.
tadhglynch@hotmail.com

References

- Bonnin M, Mercier FJ, Sitbon O, Roger-Christoph S, Jais X, Humbert M, Audibert F, Frydman R, Simonneau G, Benhamou D: Severe pulmonary hypertension during pregnancy: Mode of delivery and anesthetic management of 15 consecutive cases. *ANESTHESIOLOGY* 2005; 102:1133-7
- Preston IR, Klinger JR, Houtches J, Nelson D, Farber HW, Hill NS: Acute and chronic effects of sildenafil in patients with pulmonary arterial hypertension. *Respir Med* 2005; 99:1501-10
- Ghofrani HA, Wiedemann R, Rose F, Schermuly RT, Olschewski H, Weissmann N, Gunther A, Walrath D, Seeger W, Grimminger F: Sildenafil for treatment of lung fibrosis and pulmonary hypertension: A randomised controlled trial. *Lancet* 2002; 21:360:895-900
- Sastry BK, Narasimhan C, Reddy NK, Raju BS: Clinical efficacy of sildenafil in primary pulmonary hypertension: A randomized, placebo-controlled, double-blind, crossover study. *J Am Coll Cardiol* 2004; 43:1149-53
- Richalet JP, Grataudour P, Robach P, Pham I, Dechaux M, Joncquiert-Latarjet A, Mollard P, Brugniaux J, Cornolo J: Sildenafil inhibits altitude-induced hypoxemia and pulmonary hypertension. *Am J Respir Crit Care Med* 2005; 171:275-81
- Zhao L, Mason NA, Morrell NW, Kojonazarov B, Sadykov A, Maripov A, Mirrakhimov MM, Aldashev A, Wilkins MR: Sildenafil inhibits hypoxia-induced pulmonary hypertension. *Circulation* 2001; 104:424-8
- Molelekwa V, Akhter P, McKenna P, Bowen M, Walsh K: Eisenmenger's syndrome in a 27 week pregnancy-management with bosentan and sildenafil. *Ir Med J* 2005; 98:87-8
- Lacassie HJ, Germain AM, Valdes G, Fernandes MS, Allamand F, Lopez H: Management of Eisenmenger syndrome in pregnancy with sildenafil and L-arginine. *Obstet Gynecol* 2004; 103:1118-20
- Zhao L, Mason NA, Morrell NM, Kojonazarov B, Sadykov A, Maripov A, Mirrakhimov MM, Aldashev A, Wilkins MR: Sildenafil inhibits hypoxia-induced pulmonary hypertension. *Circulation* 2001; 104:424-8
- Dishy V, Sofowora G, Harris PA, Kandcer M, Zhan F, Wood AJ, Stein CM: The effect of sildenafil on nitric oxide mediated-vasodilation in healthy men. *Clin Pharmacol Ther* 2001; 70:270-9
- Ghofrani HA, Voswinckel R, Reichenberger F, Olschewski H, Haredza P, Karadas B, Schermuly RT, Weissmann N, Seeger W, Grimminger F: Differences in hemodynamic and oxygenation responses to three different phosphodiesterase-5 inhibitors in patients with pulmonary arterial hypertension: A randomized prospective study. *J Am Coll Cardiol* 2004; 44:1488-96
- Bush HS: Safe use of sildenafil in patients with coronary artery disease. *Cleveland Clin J Med* 2001; 68:349-52
- Shakar SF, Bristow MR: Low level inotropic stimulation with type III phosphodiesterase inhibitors in patients with advanced symptomatic heart failure receiving beta-blocking agents. *Curr Cardiol Rep* 2001; 3:224-31
- Wilkins H, Guth A, König J, Forestier N, Cremers B, Hennen B, Bohm M, Sybrecht GW: Effect of inhaled iloprost plus oral sildenafil in patients with primary pulmonary hypertension. *Circulation* 2001; 104:1218-22
- Ghofrani HA, Wiedemann R, Rose F, Olschewski H, Schermuly RT, Weissmann N, Seeger W, Grimminger F: Combination therapy with oral sildenafil and inhaled iloprost for severe pulmonary hypertension. *Ann Intern Med* 2002; 136:515-22
- Michelakis E, Tymchak W, Lein D, Webster L, Hashimoto K, Archer S: Oral sildenafil is an effective and specific pulmonary vasodilator in patients with pulmonary arterial hypertension: Comparison with inhaled nitric oxide. *Circulation* 2002; 105:2398-403
- Lepore JJ, Maroo A, Bigatello LM, Dec GW, Zapol WM, Bloch KD, Semigran MJ: Hemodynamic effects of sildenafil in patients with congestive heart failure and pulmonary hypertension: Combined administration with inhaled nitric oxide. *Chest* 2005; 127:1647-53
- Ghofrani HA, Rose F, Schermuly RT, Olschewski H, Wiedemann R, Weissmann N, Schudt C, Tenor H, Seeger W, Grimminger F: Amplification of the pulmonary vasodilatory response to inhaled iloprost by subthreshold phosphodiesterase type 3 and 4 inhibition in severe pulmonary hypertension. *Crit Care Med* 2002; 30:2489-92
- Mychaskiw G, Sachdev V, Heath BJ: Sildenafil (Viagra) facilitates weaning of inhaled nitric oxide following placement of a biventricular-assist device. *J Clin Anesth* 2001; 13:218-20
- Sher G, Fisch JD: Effect of vaginal sildenafil on the outcome of in vitro fertilization (IVF) after multiple IVF failures attributed to poor endometrial development. *Fertil Steril* 2002; 78:1073-6
- Karatzas AA, Bush A, Magee AG: Safety and efficacy of sildenafil therapy in children with pulmonary hypertension. *Int J Cardiol* 2005; 100:267-73
- Travadi JN, Patole SK: Phosphodiesterase inhibitors for persistent pulmonary hypertension of the newborn: A review. *Pediatr Pulmonol* 2003; 36:529-35

(Accepted for publication October 12, 2005.)

Anesthesiology 2006; 104:383

© 2006 American Society of Anesthesiologists, Inc. Lippincott Williams & Wilkins, Inc.

In Reply:—We thank Drs. Lynch and Laffey for their interest in our series of 15 cases of severe pulmonary arterial hypertension (PAH) during pregnancy and their useful comment on therapeutic options.¹ Our series gathered patients from 1992 to 2002. During this period, therapeutic options have expanded markedly and patient management has become more active. Nonetheless, even when considering our most recent cases only, pregnancy must be still discouraged undoubtedly. Therefore, therapeutic abortion is the first-line treatment we offer to patients who are pregnant already. In our experience, however, some patients decline this option. For these patients who are willing to continue with their pregnancy, it is particularly important to make sure that an updated optimal treatment is actually implemented. Although there is no curative treatment for idiopathic PAH, several drugs are now available to target the main dysfunctional pathways of the disease.

These drugs included namely (1) prostaglandin I₂ (prostacyclin), (2) endothelin-1 receptor antagonists, and (3) type 5 phosphodiesterase inhibitors. According to our group² and to European³ and American⁴ guidelines, intravenous prostacyclin (epoprostenol) is the treatment of choice for patients with PAH in functional class IV. For patients with PAH in functional class III, endothelin-1 receptor antagonists or prostacyclin analogs (inhaled iloprost or subcutaneous treprostinil) may be used as an alternative. Guidelines do not provide specific recommendations in pregnant patients with regard to drug choice, except that the endothelin-1 receptor antagonist bosentan should be contraindicated.^{2,4} This is because animal data indicate that bosentan could provide potential major birth defects.^{5,6}

Sildenafil is the first type 5 phosphodiesterase inhibitor approved for clinical use in the United States in patients with PAH, and it is currently in registration process in Europe (20 mg three times a day). As pointed out by Drs. Lynch and Laffey, it has several advantages over inhaled nitric oxide, and it is also particularly appealing for long-term treatment because of its oral administration, in contrast to other drugs. However, despite a few promising reports, more information is needed in pregnant patients with functional class III or IV PAH before it could be

considered as a true alternative option to the above-mentioned guidelines. Meanwhile, we believe that prostacyclin therapy is a more validated approach.⁷ Whatever the drug or combination of drugs chosen, it is important to report back both the positive and negative outcomes observed, because the experience remains (we hope) particularly scarce in this subpopulation of pregnant patients.

Frédéric J. Mercier, M.D., Ph.D.,* Martine Bonnin, M.D., Marc Humbert, M.D., Ph.D. *Antoine Beclere Hospital-Assistance Publique des Hôpitaux de Paris, France. frederic.mercier@abc.ap-hop-paris.fr

References

1. Bonnin M, Mercier FJ, Sitbon O, Roger-Christoph S, Jais X, Humbert M, Audibert F, Frydman R, Simonneau G, Benhamou D: Severe pulmonary hypertension during pregnancy: Mode of delivery and anesthetic management of 15 consecutive cases. *ANESTHESIOLOGY* 2005; 102:1133–7
2. Humbert M, Sitbon O, Simonneau G: Treatment of pulmonary arterial hypertension. *N Engl J Med* 2004; 351:1425–36
3. Galie N, Torbicki A, Barst R, Dartevelle P, Haworth S, Higenbottam T, Olschewski H, Peacock A, Pietra G, Rubin LJ, Simonneau G, Priori SG, Garcia MA, Blanc JJ, Budaj A, Cowie M, Dean V, Deckers J, Burgos EF, Lekakis J, Lindahl B, Mazzotta G, McGregor K, Morais J, Oto A, Smiseth OA, Barbera JA, Gibbs S, Hoeper M, Humbert M, Naeije R, Pepke-Zaba J, Task Force: Guidelines on diagnosis and treatment of pulmonary arterial hypertension. The task force on diagnosis and treatment of pulmonary arterial hypertension of the European Society of Cardiology. *Eur Heart J* 2004; 25:2243–78
4. Badesch DB, Abman SH, Ahearn GS, Barst RJ, McCrory DC, Simonneau G, McLaughlin VV American College of Chest Physicians: Medical therapy for pulmonary arterial hypertension: ACCP evidence-based clinical practice guidelines. *Chest* 2004; 126 (suppl):35S–62S
5. Cheng JW: Bosentan. *Heart Dis* 2003; 5:161–9
6. Kenyon KW, Nappi JM: Bosentan for the treatment of pulmonary arterial hypertension. *Ann Pharmacother* 2003; 37:1055–62
7. Elliot CA, Stewart P, Webster VJ, Mills GH, Hutchinson SP, Howarth ES, Bu'lock FA, Lawson RA, Armstrong IJ, Kiely DG: The use of iloprost in early pregnancy in patients with pulmonary arterial hypertension. *Eur Respir J* 2005; 26:168–73

(Accepted for publication October 12, 2005.)

Anesthesiology 2006; 104:383–4

© 2006 American Society of Anesthesiologists, Inc. Lippincott Williams & Wilkins, Inc.

Effectiveness of Isoflurane in Inducing Delayed Preconditioning against Myocardial Infarction *In Vivo*

To the Editor:—We read with great interest the article by Chiari *et al.*¹ regarding a potential role of endothelial nitric oxide synthase in isoflurane-induced delayed preconditioning in rabbit myocardium. The authors are to be congratulated for performing an important study about the remote effects of isoflurane in attenuating myocardial infarct after acute coronary occlusion and reperfusion. In particular, they addressed the potential role of endothelial nitric oxide synthase and subsequently of nitric oxide in isoflurane-induced myocardial protection.

Nitric oxide donors have been shown to mimic the protective effects of delayed ischemic preconditioning in rabbits.² The protective effect of nitric oxide donor was completely abrogated when this agent was given in conjunction with the peroxynitrite (ONOO⁻) and hydroxyl radical (.OH) scavenger mercaptopropionyl glycine,² suggesting nitric oxide induced late preconditioning involved the generation of reactive oxygen species. This is similar in nature to isoflurane in that isoflurane preconditioning requires the generation of reactive oxygen species as a trigger.³ Furthermore, transient systemic ischemic preconditioning enhanced early functional recovery of reperfused hearts in the rabbits, accompanied by an increase in plasma nitric oxide concentration as well as increases in plasma superoxide dismutase activi-

ty.⁴ This latter observation seems to suggest nitric oxide as a potential mediator of ischemic preconditioning in rabbits. This is supportive of the study of Chiari *et al.*¹ showing that endogenous nitric oxide may function as a mediator of isoflurane-induced delayed preconditioning.

It should be noted, however, that in all of the studies^{1–4} mentioned above, the duration of coronary occlusion was limited to 30 min. A study conducted by Kehl *et al.*⁵ (from the same research group as Chiari *et al.*¹) clearly demonstrated that isoflurane did not produce a delayed preconditioning against myocardial infarction *in vivo* in dogs when the duration of coronary occlusion was extended to 60 min. Although the animal species used are different in the two studies,^{1,5} the duration of coronary occlusion could have played a determinant role regarding the effectiveness of isoflurane in inducing delayed preconditioning against myocardial infarct. It is unexpected that Chiari *et al.*¹ did not comment on this potential limitation of isoflurane preconditioning effects. Study has shown that in ischemic-reperfused isolated guinea pig hearts, the therapeutic time frame for anesthetic preconditioning against postischemic contractile dysfunction and infarction is approximately 25–40 min.⁶ The protection is maximal when ischemic duration is between 30 and 35 min. This suggests that anesthetic

preconditioning may be useful therapy only if the typical duration of ischemia during coronary artery bypass falls within this range. Therefore, we have good reason to postulate that isoflurane-induced delayed preconditioning, if any, is confined to a specific time frame.

As commented by Chiari *et al.* in the Discussion, aging modulates (reduces the efficiency of) anesthetic preconditioning. One possible explanation for this phenomenon is that antioxidant capacity is reduced with aging. That is, aging is associated with increased formation of reactive oxygen species. Therefore, theoretically, further enhancement of oxygen free radical production by volatile anesthetics may even prove to be detrimental to an aged population. The oxygen free radical-induced lipid peroxidation end product 15-F_{2t}-isoprostane *per se* has been shown to be an independent risk marker of cardiac complications and can exacerbate myocardial ischemia-reperfusion injury.⁷ In contrast to volatile anesthetics, the intravenous anesthetic propofol has antioxidant property and has been shown experimentally to better protect hearts of aging animals than hearts of younger animals against postischemic myocardial injury.⁸ Large prospective clinical trials comparing volatile anesthetic preconditioning and intravenous "anesthetic treatment" or trials comparing a combination of the two are merited, in particular, in the aged population or in those patients with an expected duration of ischemia during coronary artery bypass longer than 40 min.

Zhengyuan Xia, M.D., Ph.D.,* Fang Wang, M.D., Tao Luo, M.D.
*Renmin Hospital, Wuhan University, Wuhan, China, and University of British Columbia, Vancouver, British Columbia, Canada.
zhengyuan_xia@yahoo.com

Anesthesiology 2006; 104:384-5

In Reply:—We thank Xia *et al.* for their gracious comments about our recent work characterizing the role of endothelial nitric oxide synthase in delayed preconditioning against myocardial infarction produced by isoflurane.¹ The authors mention that isoflurane-induced preconditioning requires the generation of reactive oxygen species. In fact, we have previously demonstrated that isoflurane produces small quantities of reactive oxygen species independent of ischemia and reperfusion as detected using dihydroethidium staining and confocal laser microscopy.² These data provided direct evidence that exposure to isoflurane produces a small burst of reactive oxygen species *via* opening of mitochondrial adenosine triphosphate-sensitive potassium channels that triggers preconditioning.³

Xia *et al.* suggest that the duration of coronary artery occlusion may contribute to the relative efficacy of volatile anesthetics during acute or delayed preconditioning. Previous data indicated that isoflurane did not produce delayed preconditioning in dogs exposed to a 60-min left anterior descending coronary artery occlusion,⁴ in contrast to the findings in rabbits when a 30-min coronary occlusion was used.¹ Although these results may have been related to the duration of coronary occlusion, it is more likely the findings were related to differences in systemic hemodynamics and coronary collateral blood flow between species. Coronary artery occlusions of 30 or 60 min in duration typically produce myocardial infarct sizes of approximately 40 and 33% in rabbits and dogs, respectively. Heart rates in barbiturate-anesthetized rabbits and dogs are approximately 240 and 130 beats/min, respectively. As a result, myocardial oxygen consumption before and during coronary occlusion is substantially higher in rabbits as compared with dogs. In addition to this more pronounced ischemic burden, rabbits have little if any coronary collateral blood flow.⁵ In contrast, the canine model of ischemia and reperfusion used in our previous investigation⁴ is complicated by variable degrees of coronary collateral perfusion, which must be considered when interpreting the results. We believe that it would also be premature to extrapolate our findings in barbiturate-anesthetized, acutely instrumented rabbits¹ to

References

- Chiari PC, Bienengraeber MW, Weihrauch D, Krolkowski JG, Kersten JR, Wartier DC, Pagel PS: Role of endothelial nitric oxide synthase as a trigger and mediator of isoflurane-induced delayed preconditioning in rabbit myocardium. *ANESTHESIOLOGY* 2005; 103:74-83
- Takano H, Tang XL, Qiu Y, Guo Y, French BA, Bolli R: Nitric oxide donors induce late preconditioning against myocardial stunning and infarction in conscious rabbits via an antioxidant-sensitive mechanism. *Circ Res* 1998; 83:73-84
- Mullenheim J, Ebel D, Frassdorf J, Preckel B, Thamer V, Schlack W: Isoflurane preconditions myocardium against infarction *via* release of free radicals. *ANESTHESIOLOGY* 2002; 96:934-40
- Xia Z, Xia R, Lan HT, Luo T, Tang QZ, Xia ZY, Liu XY: Systemic ischemic preconditioning plus hemodilution enhanced early functional recovery of reperfused heart in the rabbits. *Interactive Cardiovasc Thoracic Surg* 2004; 3:528-532
- Kehl F, Pagel PS, Krolkowski JG, Gu W, Toller W, Wartier DC, Kersten JR: Isoflurane does not produce a second window of preconditioning against myocardial infarction *in vivo*. *Anesth Analg* 2002; 95:1162-8
- Kevin LG, Katz P, Camara AK, Novalija E, Riess ML, Stowe DF: Anesthetic preconditioning: Effects on latency to ischemic injury in isolated hearts. *ANESTHESIOLOGY* 2003; 99:385-91
- Xia Z, Kuo KH, Godin DV, Walker MJ, Tao MC, Ansley DM: 15-F_{2t}-isoprostane exacerbates myocardial ischemia-reperfusion injury of isolated rat hearts. *Am J Physiol Heart Circ Physiol* 2005; 289:H1366-72
- Xia Z, Godin DV, Ansley DM: Propofol enhances ischemic tolerance of middle-aged rat hearts: Effects on 15-F_{2t}-isoprostane formation and tissue antioxidant capacity. *Cardiovasc Res* 2003; 59:113-21

(Accepted for publication October 20, 2005.)

© 2006 American Society of Anesthesiologists, Inc. Lippincott Williams & Wilkins, Inc.

patients with coronary artery disease undergoing cardiac surgery using cardiopulmonary bypass, as suggested by Xia *et al.*

In contrast to the arguments of Xia *et al.*, there is little experimental evidence supporting the hypothesis that propofol produces substantial cardioprotective effects against ischemia-reperfusion injury *in vivo*. However, a large body of experimental evidence supports the contention that volatile anesthetics exert important protective effects against reversible and irreversible ischemic injury.⁶ To date, several clinical trials have provided preliminary data to corroborate these experimental findings. In particular, De Hert *et al.*⁷ demonstrated that sevoflurane but not propofol preserved myocardial function and attenuated increases in troponin I release in patients undergoing coronary artery bypass graft surgery. These data suggested that sevoflurane but not propofol produces myocardial protection in humans at risk for ischemic injury.⁷ Further large-scale, multicenter clinical trials should be performed to define the utility of volatile anesthetics as cardioprotective agents in humans.

Paul S. Pagel, M.D., Ph.D.,* David C. Wartier, M.D., Ph.D., Judy R. Kersten, M.D. *Medical College of Wisconsin and the Clement J. Zablocki Veterans Affairs Medical Center, Milwaukee, Wisconsin.
pspagel@mcw.edu

References

- Chiari PC, Bienengraeber MW, Weihrauch D, Krolkowski JG, Kersten JR, Wartier DC, Pagel PS: Role of endothelial nitric oxide synthase in isoflurane-induced delayed preconditioning in rabbits. *ANESTHESIOLOGY* 2005; 103:74-83
- Tanaka K, Weihrauch D, Kehl F, Ludwig LM, LaDisa JF Jr, Kersten JR, Pagel PS, Wartier DC: Mechanism of preconditioning by isoflurane in rabbits: A direct role for reactive oxygen species. *ANESTHESIOLOGY* 2002; 97:1485-90
- Tanaka K, Weihrauch D, Ludwig LM, Kersten JR, Pagel PS, Wartier DC: Mitochondrial adenosine triphosphate-regulated potassium channel opening acts as a trigger for isoflurane-induced preconditioning by generating reactive oxygen species. *ANESTHESIOLOGY* 2003; 98:935-43
- Kehl F, Pagel PS, Krolkowski JG, Gu W, Toller W, Wartier DC, Kersten JR: Isoflurane does not produce a second window of preconditioning against myocardial infarction *in vivo*. *Anesth Analg* 2002; 95:1162-8

5. Maxwell MP, Hearse DJ, Yellon DM: Species variation in the coronary collateral circulation during regional myocardial ischaemia: A critical determinant of the rate of evolution and extent of myocardial infarction. *Cardiovasc Res* 1987; 21:737-46

6. Tanaka K, Ludwig LM, Kersten JR, Pagel PS, Wartier DC: Mechanisms of cardioprotection by volatile anesthetics. *ANESTHESIOLOGY* 2004; 100:707-21

7. De Hert SG, ten Broeck PW, Mertens E, Van Sommeren EW, De Blier IG, Stockman BA, Rodrigus IE: Sevoflurane but not propofol preserves myocardial function in coronary surgery patients. *ANESTHESIOLOGY* 2002; 97:42-9

(Accepted for publication October 20, 2005.)

Anesthesiology 2006; 104:385

© 2006 American Society of Anesthesiologists, Inc. Lippincott Williams & Wilkins, Inc.

Implications of Postoperative Pruritus

To the Editor:—In a recent Review Article about postoperative pruritus regarding anesthesia, Waxler *et al.*¹ discussed in detail the pathway, mechanism, and treatment modalities for postoperative pruritus. However, the saga of postoperative pruritus may not end simply with a diagnosis of pruritus and its treatment. There may be a turning point after the exacerbation of the coexisting skin disease as a sequela to pruritus and scratching.²⁻⁵ In this phenomenon, referred to as the *Koebner* or *isomorphic phenomenon*, trauma in a person with certain skin diseases is followed by new lesions in the traumatized but otherwise normal skin, and these new lesions are identical to those in the diseased skin. Although best known in psoriasis, it may also occur in other skin diseases, notably lichen planus, lichen nitidus, pityriasis rubra pilaris, vitiligo, and Darier disease. The Koebner phenomenon begins 8-10 days after injury. However, it may appear within 3 days or may be delayed as long as 18 days.^{3,4} In these diseases, any physical and chemical trauma to skin, including scratching, may precipitate further lesions.⁵ Neuraxial opioids have been implicated to precipitate Koebner phenomenon subsequent to postoperative itching and pruritus. Ideologically, any of the drugs mentioned by the authors that can lead to itching and scratching can precipitate the Koebner phenomenon.¹

However, the late manifestation of the Koebner phenomenon after the skin trauma and the loss of contact between anesthesiologist and the patient by this time may lead to ignorance about this important

David C. Wartier, M.D., Ph.D., served as Handling Editor for this exchange.

Anesthesiology 2006; 104:385

In Reply:—We appreciate the interest and comments of Drs. Mahajan, Gupta, and Sharma regarding our Review Article about postoperative pruritus.¹ In our Review Article, we summarized coexisting conditions that contribute to the choice of anesthesia and treatment of postoperative pruritus. Two major purposes for our article were (1) to summarize up-to-date knowledge about prevention and treatment of itching after surgery and (2) to illustrate basic principles for diagnosis and treatment for postoperative itching for practicing anesthesiologists. We appreciate the suggestions of Dr. Mahajan *et al.*² that anesthesiologists should be vigilant about the Koebner phenomenon in patients with certain skin diseases and avoid the use of medications that would lead to pruritus.

In a variety of skin diseases, trauma to the skin may result in the isomorphic Koebner phenomenon.³⁻⁵ We would like to emphasize that exacerbation of coexisting skin disease is not a sequela to pruritus. To the best of our knowledge, there is no study that linked mechanisms of pruritus with the Koebner phenomenon. Of course, if itching is left untreated, it may lead to scratching, and trauma caused by scratching (but not to itching *per se*) may cause the Koebner phenomenon. Our review focused on early diagnosis and treatment of pruritus not only to avoid sequelae of itching (scratching, as well as the isomorphic Koebner phenomenon in certain cutaneous diseases), but also to improve patients' satisfaction and to shorten their time in the

clinical event after pruritus. It is worth noting that the Koebner phenomenon after medical therapy may encompass medicolegal implications.^{3,4} Therefore, one must be vigilant regarding this entity and cautious in using any medications or interventions that can lead to pruritus, especially in patients with coexisting skin diseases that can manifest the Koebner phenomenon.

Rajesh Mahajan, M.B.B.S., M.D.,* Rahul Gupta, M.B.B.S., M.D., Anju Sharma, M.B.B.S. *Acharya Shri Chander College of Medical Sciences, Jammu and Kashmir, India. drmahajan@yahoo.com or drmahajan@rediffmail.com

References

1. Waxler B, Dadabhoy ZP, Stojiljkovic L, Rabito SF: Primer of postoperative pruritus for anesthesiologists. *ANESTHESIOLOGY* 2005; 103:168-78
2. Mahajan R, Grover VK: Neuraxial opioids and Koebner phenomenon: Implications for anesthesiologist. *ANESTHESIOLOGY* 2003; 99:229-30
3. Ramsay DL, Hurlay HJ: Papulosquamous eruptions and exfoliative dermatitis. *Dermatology*, 2nd edition. Edited by Moschella SL, Hurley HJ. Philadelphia, Saunders, 1985, pp 499-556
4. Falco OB, Plewig G, Wolff HH, Winkelmann RK: Psoriasis and other exfoliative skin disorders. *Dermatology*, 3rd edition. New York, Springer Verlag, 1984, pp 403-6
5. Smith MF: Skin and connective tissue diseases, Anesthesia and Uncommon Pediatric Diseases, 2nd edition. Edited by Ketz J, Steward DJ. Philadelphia, Saunders, 1993, pp 501-62

(Accepted for publication October 20, 2005.)

© 2006 American Society of Anesthesiologists, Inc. Lippincott Williams & Wilkins, Inc.

recovery room. In addition, we emphasized the increasing need for effective preventive measures, which are often still missing.

Also, we think that in the future, anesthesiologists will have access to more specific drugs that will act only at the intended receptor. With them, anesthesiologists will be able to modulate specific sites for specific anesthetic and surgical goals instead of causing undesirable effects (such as itching).

Beverly Waxler, M.D.,* Zerine P. Dadabhoy, M.D., Ljuba Stojiljkovic, M.D., Ph.D., Sara F. Rabito, M.D., F.A.H.A. *John H. Stroger Jr. Hospital of Cook County, Chicago, Illinois. bwaxler@rush.edu

References

1. Waxler B, Dadabhoy ZP, Stojiljkovic L, Rabito SF: Primer of postoperative pruritus for anesthesiologists. *ANESTHESIOLOGY* 2005; 103:168-78
2. Mahajan R, Kumar Grover V: Neuraxial opioids and Koebner phenomenon: Implications for anesthesiologists. *ANESTHESIOLOGY* 2003; 99:229-30
3. Rubin AI, Stiller MJ: A listing of skin conditions exhibiting the Koebner and pseudo-Koebner phenomena with eliciting stimuli. *J Cutan Med Surg* 2002; 6:29-34
4. Jolly M: Discoid lupus erythematosus after tattoo: Koebner phenomenon (letter). *Arthritis Rheum* 2005; 53:627
5. Durani BK, Kurzen H, Hartschuh W, Naeher H: Koebner phenomenon due to scratch test in scleromyxoedema. *Br J Dermatol* 2001; 145:306-8

(Accepted for publication October 20, 2005.)

Anesthesiology 2006; 104:386

© 2006 American Society of Anesthesiologists, Inc. Lippincott Williams & Wilkins, Inc.

Droperidol Has Been Reported to Cause Serious Arrhythmias

To the Editor:—In their recent report on QT interval changes associated with droperidol, White *et al.*¹ state: “Interestingly, despite the use of these high doses of droperidol as part of a neurolept anesthetic technique for more than 30 yr, there has not been a single report of a serious arrhythmia during or after anesthesia in the peer reviewed literature.” White made a similar statement in an editorial in 2002.² However, such a report was published in 2002.³

Mitchel B. Sosis, M.S., M.D., Ph.D., Holy Redeemer Hospital and Medical Center, Meadowbrook, Pennsylvania. mitchelsosis@hotmail.com

Anesthesiology 2006; 104:386

© 2006 American Society of Anesthesiologists, Inc. Lippincott Williams & Wilkins, Inc.

In Reply:—The interest of Dr. Sosis in our recent article¹ demonstrating the absence of a clinically significant effect of low-dose droperidol on the QT interval after a propofol induction is appreciated. As stated in my earlier editorial,² despite widespread clinical use in anesthesia for more than 30 yr, not a single case report describing a droperidol-induced arrhythmia has appeared in the peer-reviewed anesthesia literature despite the US Food and Drug Administration-imposed “black box” warning (excluding the questionable case report³ mentioned by Dr. Sosis, which appeared in a Japanese journal in 2002). Even with extensive use of high-dose droperidol as part of a standard “neurolept” anesthetic technique, there have not been any reported cases of droperidol-induced dysrhythmias during anesthesia.

In considering the facts of this particular case report,³ Dr. Sosis neglected to mention that the administered dose of droperidol was more than 10 times the standard antiemetic dosage. Second, the alleged case of droperidol-induced multifocal ventricular dysrhythmias occurred in a woman with chronic renal failure who was receiving hemodialysis. Importantly, there was no mention of her electrolyte status at the time of the acute event. Third, she was given a 10-mg intravenous bolus dose of droperidol during general inhalation anesthesia with a combination of isoflurane and nitrous oxide. This combination of inhaled and intravenous drugs would hardly be described as classic neurolept anesthesia.

Anesthesiology 2006; 104:386-7

© 2006 American Society of Anesthesiologists, Inc. Lippincott Williams & Wilkins, Inc.

Drug-induced Prolongation of the QT Interval: What’s the Point?

To the Editor:—In his recent editorial,¹ Scuderi appropriately suggested that the action of the US Food and Drug Administration (FDA) in placing a “black box” on the use of low-dose droperidol for the treatment and prevention of postoperative nausea and vomiting “is clearly specious and does a tremendous disservice to the American public.”

Although the editorial is excellent, it incorrectly stated that White *et al.*² “demonstrated a prolongation of QTc when droperidol (either 0.625 or 1.25 mg) is administered intravenously” for antiemetic prophylaxis. In fact, the effect of low-dose droperidol was not found to be different from saline (placebo). Given the rigid position taken by the

References

1. White PF, Song D, Abrao J, Klein K, Navarette B: Effect of low-dose droperidol on the QT interval during and after general anesthesia: A placebo-controlled study. *ANESTHESIOLOGY* 102:1101-1105.
2. White PF: Droperidol: A cost effective antiemetic for over thirty years. *Anesth Analg* 2002; 98:789-90
3. Shigeyama T, Yanagidani T: Droperidol causes multifocal ventricular dysrhythmias. *Masui* 2002; 51:53-5

(Accepted for publication October 20, 2005.)

I stand by my earlier published statements that there has not been a single documented case of a serious cardiac arrhythmia occurring in a patient receiving an antiemetic dose (*e.g.*, 0.625-1.25 mg) of droperidol or even a large dose of droperidol (*e.g.*, 10 mg) as part of a true neurolept anesthetic technique. Hopefully, the decision-makers at the Food and Drug Administration will come to their senses and remove the unwarranted black box warning on this highly cost-effective antiemetic drug.

Paul F. White, Ph.D., M.D., University of Texas Southwestern Medical Center, Dallas, Texas. paul.white@utsouthwestern.edu

References

1. White PF, Song D, Abrao J, Klein KW, Navarette B: Effect of low-dose droperidol on the QT interval during general anesthesia: A placebo-controlled study. *ANESTHESIOLOGY* 2005; 102:1101-5
2. White PF: Droperidol: A cost-effective antiemetic for over thirty years. *Anesth Analg* 2002; 98:89-90
3. Shigeyama T, Yanagidani T: Droperidol causes multifocal ventricular dysrhythmias. *Masui* 2002; 51:53-5

(Accepted for publication October 20, 2005.)

The above letter was sent to the author of the referenced Editorial View. The author did not feel that a response was required.—Michael M. Todd, Editor-in-Chief

values of 720, 615, 742, and 641 ms at 1, 2, 3, and 4 h after surgery, respectively. The patient's postoperative recovery was completely uneventful, and she was discharged home despite the persistently prolonged QTc interval. If this patient had received droperidol (or one of the 5-hydroxytryptamine type 3 antagonists⁴) for antiemetic prophylaxis, this otherwise "unexplained" prolongation of the QTc interval in the postoperative period would almost certainly have been incorrectly ascribed to the antiemetic drug.

In a recent perspective on drugs and the QT interval, Liu and Juurlink³ stated that "most of what is known about drug-induced QT-interval prolongation derives from spontaneous reporting mechanisms." Unfortunately, these anecdotal reports are not subject to peer-review, and other potential causative factors for a resultant dysrhythmia are often overlooked. Analogous to the widely used antibiotic erythromycin, droperidol has been successfully used by anesthesiologists for the treatment and prevention of postoperative nausea and vomiting in millions of patients during the past 30+ years.^{5,6} As a result of the FDA-imposed "black box" warning mandating additional electrocardiographic monitoring when this cost-effective antiemetic is administered, droperidol has been effectively eliminated from the anesthesiologist's armamentarium at many medical centers in this country and abroad. As pointed out by Roden⁷ in his recent review article on drug-induced prolongation of the QT interval, "since rare side effects occur with many otherwise highly-effective drugs, their withdrawal from the market probably harms more patients than it helps."

In the opinion of many clinicians around the world, the FDA's recent obsession with drug-induced QT prolongation is an example of "mak-

ing a mountain out of a molehill."⁸ Could someone please explain the basis for the FDA's preoccupation with an apparent *nonproblem* of QT prolongation in the population at large?

Paul F. White, Ph.D., M.D., F.A.N.Z.C.A.,* Joao Abrao, M.D., Ph.D., *University of Texas Southwestern Medical Center, Dallas, Texas. paul.white@utsouthwestern.edu

References

1. Scuderi PE: You (still) can't disprove the existence of dragons. *ANESTHESIOLOGY* 2005; 102:1081-2
2. White PF, Song D, Abrao J, Klein KW, Navarette B: Effect of low-dose droperidol on the QT interval during and after general anesthesia: A placebo-controlled study. *ANESTHESIOLOGY* 2005; 102:1101-5
3. Liu B, Juurlink DN: Drugs and the QT interval: Caveat doctor. *N Engl J Med* 2004; 351:1053-96
4. Charbit B, Albaladejo P, Funck-Brentano C, Legrand M, Samain E, Marty J: Prolongation of QTc interval after postoperative nausea and vomiting treatment by droperidol or ondansetron. *ANESTHESIOLOGY* 2005; 102:1094-100
5. White PF: Droperidol: A cost-effective antiemetic for over thirty years. *Anesth Analg* 2002; 95:789-90
6. Apfel CC, Korttila K, Abdalla M, Kerger H, Turan A, Vedder I, Zernak C, Danner K, Jokela R, Pocock SJ, Trenkler S, Kredel M, Biedler A, Sessler DI, Roewer N, IMPACT Investigators: A factorial trial of six interventions for prevention of postoperative nausea and vomiting. *N Engl J Med* 2004;350:2441-51
7. Roden DM: Drug-induced prolongation of the QT interval. *N Engl J Med* 2004; 350:1013-22
8. Bailey P, White PF: Droperidol editorial: Making a mountain out of a molehill! (letter). *ANESTHESIOLOGY* 2003; 99:760-1

(Accepted for publication December 21, 2005.)

Anesthesiology 2006; 104:387-8

© 2006 American Society of Anesthesiologists, Inc. Lippincott Williams & Wilkins, Inc.

Preoxygenation in Claustrophobic Patients

To the Editor:—Preoxygenation before induction of general anesthesia is problematic in claustrophobic patients. Anesthesia masks often cause patients to feel as though they are being smothered, and when a mask is applied by someone other than the patient, claustrophobia may be compounded by the patient's perceived loss of control in a threatening environment. Alternative approaches to traditional preoxygenation, such as using a "blow-by" of supplemental oxygen from the anesthesia circuit or the application of a face shield containing supplemental oxygen, can increase inspired and arterial oxygenation but do not permit the maximum increases in oxygen or the displacement of nitrogen that is attained with a closed system.^{1,2}

These challenges with preoxygenation can be overcome in the majority of claustrophobic patients with use of standard anesthesia equipment. With the anesthesia circuit fresh oxygen flow set to a large value (e.g., 10 l/min) and the pop-off valve opened, the patient is instructed to hold the anesthesia circuit tubing with the preferred hand. Next, the patient is instructed to place the L-connector between the lips and to seal the lips around the connector and breathe exclusively through the mouth. If continued nasal breathing is of concern, he may elect to use the contralateral hand to pinch the nose and facilitate mouth-only breathing; however, this addition may not be tolerated in some. The technique is demonstrated in figure 1.

The efficacy of this mouth-to-circuit (MTC) method is determined by three factors: (1) the patient's ability to sustain MTC breathing for sufficient time to wash oxygen into, and nitrogen from, the lungs; (2) the ability of the patient to breath exclusively from the mouth and circuit, not around the circuit or through the nose; and (3) the diminished dead space of the circuit compared with a traditional mask approach.

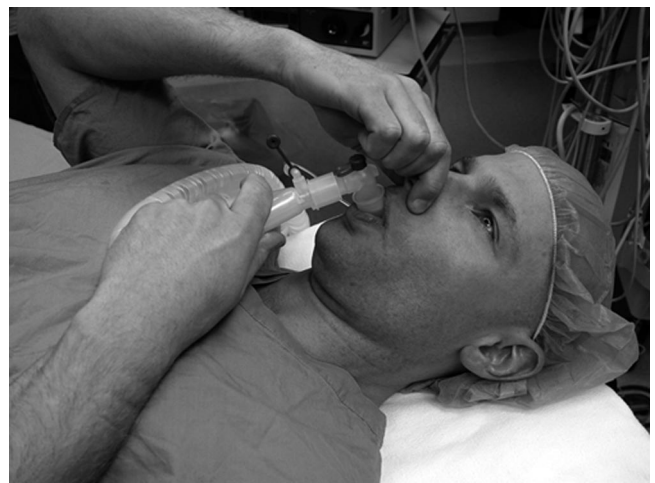

Fig. 1. A volunteer demonstrating the mouth-to-circuit technique. The lips are sealed around the L-connector before initiating normal tidal volume breaths through the circuit. Pinching the nose to reduce nasal breathing is optional.

During a 3-yr period and in more than 50 patients reporting intense claustrophobia, we have collectively observed that every single one asked to use the MTC technique was able to make a good seal around the L-connector, without evidence of leak or nasal breathing. Before this experience, we had determined that patients seemed to tolerate normal tidal volume breathing through the circuit (which in turn required longer periods of nitrogen wash-out), compared with fewer, larger, "cleansing" breaths.³ Normal breathing was reported to result in less of a sensation of "breathing through a straw" when compared with

Support was provided solely from institutional and/or departmental sources.

supranormal tidal volume breaths. There seemed little need to have the patient manually pinch the nose to prevent nasal breathing, although this may certainly be an option in some patients.

To determine the efficiency of the MTC technique, we conducted an institutional review board–approved, minimal risk protocol in 10 healthy, nonclaustrophobic volunteers. End-expired oxygen, nitrogen, and carbon dioxide concentrations were measured with a Rascal II gas monitor (Ohmeda, Louisville, CO) *via* a sampling catheter attached to the L-piece of the circuit. Each volunteer pinched his own nose closed. Measurements were recorded before initiation of preoxygenation and at 30, 60, 90, 120, 150, and 180 s thereafter. The study divided the volunteers into two groups and used a crossover design. Mean concentrations of circuit oxygen, nitrogen, or carbon dioxide were similar between the two arms of the study. For example, mean carbon dioxide concentrations never differed by more than 1 mmHg, denoting constant respiratory effort. Circuit nitrogen concentration (mean \pm SD) for MTC *versus* facemask breathing were 25 ± 5 and $30 \pm 7\%$, respectively, at 30 s; 11 ± 5 and $15 \pm 6\%$ at 60 s; 3 ± 2 and $6 \pm 5\%$ at 120 s; and 2 ± 1 and $4 \pm 6\%$ at 180 s.

After preoxygenation with this technique and anesthesia induction with an intravenous drug, ventilation of the lungs can be rapidly converted to a standard mask technique immediately after the patient loses consciousness.

The advantages of the MTC technique for claustrophobic patients are that it requires no special equipment, the patient's face is not covered by a mask, and the patient is in total control of the airway (hence reducing the sense of helplessness). When a complete seal is formed around the L-connector and mouth breathing is used exclusively, the oxygen wash-in, nitrogen wash-out properties of the patient–circuit unit should be nearly identical to that attained with the more traditional mask-facilitated preoxygenation used in nonclaustrophobic patients.

Kirstin M. Erickson, M.D.,* **William L. Lanier, M.D.** *Mayo Clinic, Rochester, Minnesota. erickson.kirstin@mayo.edu

References

1. Gibson RL, Comer PB, Beckham RW, McGraw CP: Actual tracheal oxygen concentration with commonly used oxygen equipment. *ANESTHESIOLOGY* 1976; 33:71-3
2. Kory RC, Bergmann JC, Sweet RD, Smith JR: Comparative evaluation of oxygen therapy techniques. *JAMA* 1962; 179:767-72
3. Baraka AS, Taha SK, Aouad MT, El-Khatib MF, Kawkabani NI: Preoxygenation: Comparison of maximal breathing and tidal volume breathing techniques. *ANESTHESIOLOGY* 1999; 9:612-6

(Accepted for publication October 24, 2005.)