

Preventing and Treating Pain after Thoracic Surgery

Allan Gottschalk, M.D., Ph.D.,* Steven P. Cohen, M.D.,* Stephen Yang, M.D.,† E. Andrew Ochroch, M.D., M.S.C.E.‡

THE pain that accompanies thoracic surgery is notable for its intensity and duration. Acutely, moderate to severe levels of pain may not decrease substantially over the course of hospitalization and the first postoperative month.¹ Chronically, pain can last for months to years, and even low levels of pain can decrease function.^{1,2} Other than pain syndromes associated with limb amputation, pain after thoracic surgery may be the most recognized pain syndrome associated with a specific surgery. Although used with increasing frequency, thoracoscopic approaches have not had the favorable impact on pain that many had anticipated.^{3,4} Given that the adverse effects of thoracic surgery on pulmonary function can be mitigated by effective perioperative analgesia,⁵⁻⁷ it is not surprising that thoracic surgeons have joined anesthesiologists in becoming strong advocates of analgesic interventions known to limit the pain accompanying thoracic surgery. Here, we review evidence-based strategies for preventing and treating this type of pain.

Intensity, Duration, and Impact of Pain after Thoracic Surgery

Noxious input associated with thoracic surgery is conveyed to the central nervous system along the intercostal, vagus, and phrenic nerves. Afferent phrenic activity is believed to be the source of the shoulder pain that frequently accompanies thoracic procedures because this is curtailed by phrenic⁸ but not suprascapular or epidural blockade.⁹ Intercostal nerve dysfunction resulting from incision, retraction, trocar placement, or suture is common¹⁰ and likely plays a significant role in the pain accompanying thoracic surgery. In addition, the need for

constant respiratory effort and enhanced pulmonary toilet produces an intense and relentless barrage of noxious input to the central nervous system.

Initial reports indicated that 50% of patients describe pain 1 yr after thoracotomy, with many continuing to report pain even years later.² Fortunately, the prevalence of postthoracotomy pain may be modifiable, with rates as low as 21% one year after surgery when perioperative pain is managed aggressively.¹ Surprisingly, video-assisted thoracic surgery (VATS) is associated with a prevalence of chronic pain comparable to that of open procedures,^{3,4} with rates of pain ranging from 22%³ to 63%,⁴ which is probably due to intercostal nerve and muscle damage from trocar insertion. In contrast, residual pain 1 yr after surgery is reported to be 25% after median sternotomy,¹¹ emphasizing the role that reduced intercostal nerve disruption and improved stability of the closure may play in reducing chronic pain. Several demographic and clinical factors help to identify patients predisposed to development of chronic postsurgical pain. These include anxiety, depression, previous surgery, concurrent pain, lesions of the chest wall, youth, female sex, and increased levels of pain and analgesic use in the perioperative period.^{1,12-19}

Lung volumes after thoracic surgery may be reduced by up to 50%, and aggressive analgesic therapy leads to improvements in pulmonary function not observed with standard therapy.⁵⁻⁷ Supraventricular tachydysrhythmias are commonly observed after thoracic surgery²⁰ and may be less likely in conjunction with certain thoracic epidural analgesic regimens,²¹ although this is more likely due to modification of sympathetic outflow than the associated analgesia. When pain persists, physical activity is reduced,¹ and even low levels of pain have been associated with reduced physical and social activity as well as global perceptions of decreased health.^{1,12}

Perioperative Strategies

The optimal perioperative analgesic strategy (fig. 1) is preemptive and multimodal. Although the definition²² and efficacy²³ of preemptive analgesia are debated, several studies strongly suggest that preemptive approaches lead to reductions in pain and/or analgesic use after thoracic surgery.^{1,7,24-27} However, it is equally clear that intraoperative nociception represents only a small por-

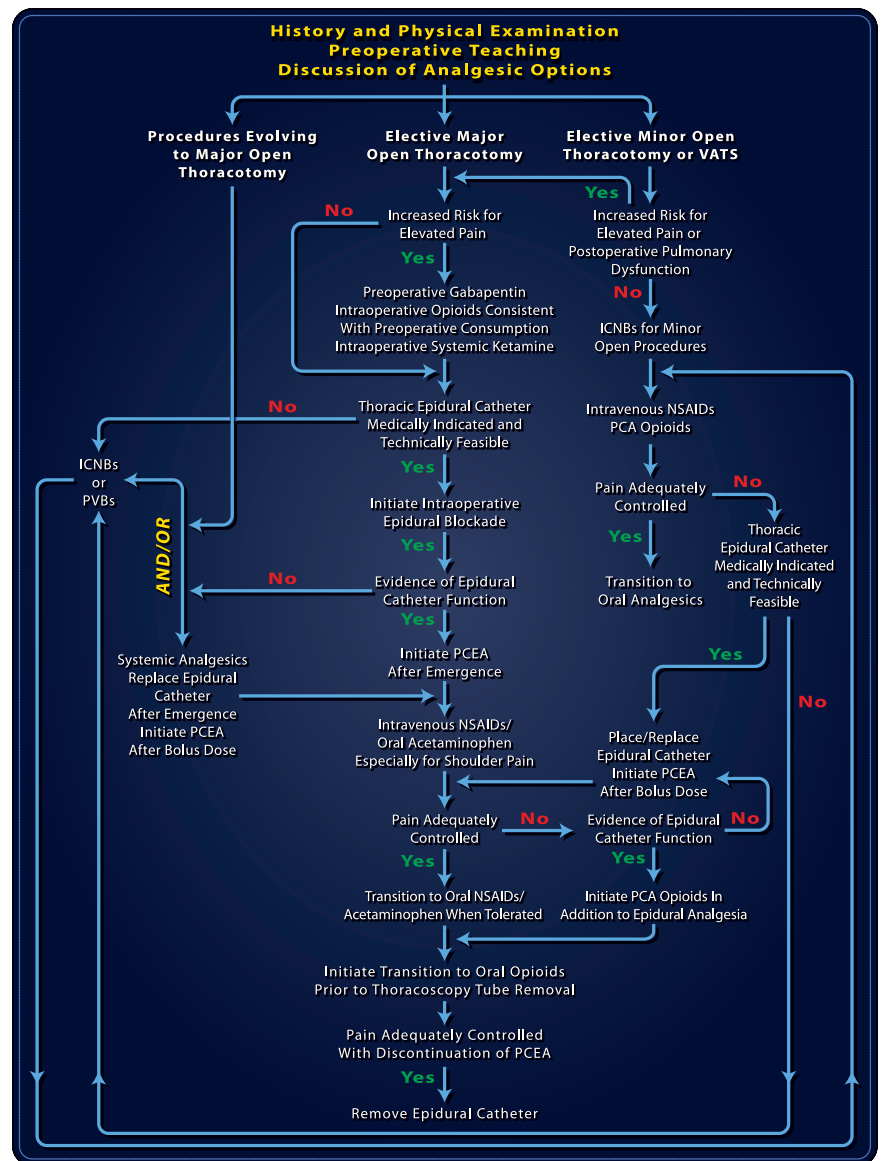
* Associate Professor of Anesthesiology and Critical Care Medicine, † Assistant Professor of Surgery, Johns Hopkins Medical Institutions, Baltimore, Maryland. ‡ Assistant Professor of Anesthesiology and Critical Care, University of Pennsylvania Medical Center, Philadelphia, Pennsylvania.

Received from the Departments of Anesthesiology and Critical Care Medicine and Surgery, Johns Hopkins Medical Institutions, Baltimore, Maryland, and the Department of Anesthesiology and Critical Care, University of Pennsylvania Medical Center, Philadelphia, Pennsylvania. Submitted for publication September 22, 2005. Accepted for publication November 21, 2005. Supported in part by grant Nos. R01 NS041865 and K23 HD040914 from the National Institutes of Health, Bethesda, Maryland.

The illustrations for this section have been prepared by Dimitri Karetnikov, 7 Tennyson Drive, Plainsboro, New Jersey 08536.

Address correspondence to Dr. Gottschalk: Department of Anesthesiology and Critical Care Medicine, Meyer 8-134, Johns Hopkins Hospital, 600 North Wolfe Street, Baltimore, Maryland 21287-4965. agottschalk@jhmi.edu. Individual article reprints may be accessed at no charge through the Journal Web site, www.anesthesiology.org.

Fig. 1. Flow diagram for management of acute perioperative pain associated with thoracic surgery. Preoperative evaluation and teaching permits risk assessment for increased pain, appropriateness of potential interventions, and the opportunity to ally anxiety. Thoracic epidural analgesia is the mainstay of recommended therapy, with alternative interventions for situations where thoracic epidural analgesia is not suitable. Special attention should be paid to patients at risk for increased perioperative pain or pulmonary dysfunction where more aggressive interventions and additional adjuncts may be valuable. When epidural catheters fail intraoperatively, intercostal nerve blocks (ICNBs) or paravertebral blocks may supplant epidural analgesia or serve as a bridge to the immediate postoperative period when an epidural catheter can be safely replaced. Ideally, the analgesic plan considers the entire perioperative period. See text for additional details. NSAID = nonsteroidal antiinflammatory drug; PCA = patient-controlled analgesia; PCEA = patient-controlled epidural analgesia; PVB = paravertebral block; VATS = video-assisted thoracic surgery.



tion of the noxious activity encountered during the entire perioperative period that could ultimately sensitize the central nervous system, exacerbating acute pain and initiating chronic pain. A multimodal approach takes into account the multiple pathways by which nociceptive input is conveyed to the central nervous system, the number of pharmacologically distinct mechanisms of modulating this input, the need for effective analgesia throughout the perioperative period and after discharge, and the importance of minimizing side effects, particularly respiratory depression. Although many aspects of analgesic management focus on specific analgesic interventions by the anesthesiologist and surgeon, other features of the surgical management may also impact on the intensity and duration of pain experienced by the patient.

Analgesic Strategies

Thoracic Epidural Analgesia. Thoracic epidural analgesia is currently the standard for analgesia for thoracic

surgery and, in the absence of contraindications, all patients undergoing major open thoracic surgical procedures should have a thoracic epidural catheter placed preoperatively.^{28,29} Epidural catheter placement may also be useful in smaller open procedures and VATS in patients at high risk of severe perioperative pain, pulmonary dysfunction, or both. Ideally, for posterolateral and transverse sternothoracotomy, the tip of the catheter should reside at the dermatome along which the incision will be made. In the case of median sternotomy and muscle-sparing incisions, placement at the T6 interspace is effective. Although the *intraoperative* use of epidural analgesia may not confer substantial long-term benefits,¹ intraoperative use may still be desirable as an adjunct to general anesthesia, to ensure epidural catheter function and to facilitate a comfortable transition to the immediate postoperative period.

Typical intraoperative management of a thoracic epi-

dural catheter incorporates initial and maintenance doses with a combination of a local anesthetic and a relatively lipophilic opioid. Maintenance doses can be administered as boluses or continuous infusions. Some degree of hypotension is to be expected given the potential for sympathectomy. Judicious fluid and pressor administration avoids the large fluid shifts that could adversely affect physiology, particularly in patients who present with limited cardiac or pulmonary reserve.

Postoperatively, patient-controlled epidural analgesia should be initiated and continued until after thoracotomy tube removal. Typically, for thoracic epidural catheters, the epidural infusate combines a low concentration of a long-acting local anesthetic (e.g., 0.5–1 mg/ml bupivacaine or 1–2 mg/ml ropivacaine) and a relatively lipophilic opioid (e.g., 5 μ g/ml fentanyl³⁰ or 10–25 μ g/ml hydromorphone). Several well-designed studies have demonstrated improved analgesia when 2 μ g/ml epinephrine was added to the infusate.^{31,32} A large number of drugs, including ketamine³³ (with some reservations),³⁴ clonidine,³⁵ and neostigmine,³⁶ have been advocated as components of epidural analgesia but have not gained widespread acceptance. Typical patient-controlled epidural analgesia regimens after thoracotomy with an epidural catheter at the optimal dermatome would combine a continuous infusion of 4–6 ml/h with demand boluses of 2–4 ml every 10 min. Dysfunctional catheters should be replaced as quickly as possible.

Postoperatively, intravenous nonsteroidal antiinflammatory drugs are useful for treating shoulder pain refractory to epidural analgesia and, given their safety and effectiveness as analgesic adjuncts, patients using patient-controlled epidural analgesia should continuously receive oral or intravenous nonsteroidal antiinflammatory drugs during hospitalization and upon discharge.^{37,38} Although the limited effect on platelets of drugs that specifically inhibit cyclooxygenase 2 may be important, the potential of these drugs in the setting of thoracic surgery awaits resolution of their cardiovascular safety.³⁹ Regular administration of acetaminophen may also be useful for treating shoulder pain⁴⁰ and can be used in addition to nonsteroidal antiinflammatory drugs. Patient-controlled analgesia with opioids can be used to supplement working epidural infusions, particularly in opioid-tolerant patients. For simplicity, a fixed epidural infusion is complemented by a patient-controlled intravenous infusion of opioids, where the safest initial approach is to permit patient-controlled analgesia demand doses only. For analgesic continuity when making the transition to oral opioid analgesics, the first oral dose should be administered at the time patient-controlled epidural analgesia is discontinued. For patients where pain management may be difficult, the epidural catheter

can remain in place to permit rescue analgesia until a satisfactory oral analgesic regimen is established.

Alternatives to Thoracic Epidural Analgesia. There are times when for technical, medical, or other reasons thoracic epidural catheter placement is unsuccessful, undesirable, or not possible. There may also be times when surgery, thoracoscopic or other, evolves to an open thoracic procedure or when it is learned intraoperatively that an epidural catheter is dysfunctional. The prompt identification of these situations and institution of alternatives is essential for preventing severe postoperative pain. Although it may facilitate pain management, several case reports demonstrate the profound risks of placing or replacing an epidural catheter while a patient is under general anesthesia.⁴¹ Although a degree of safety has been demonstrated for *lumbar* epidural catheter placement during general anesthesia,⁴² it has been argued⁴³ that such data may not be reassuring when considering rare but catastrophic events. In addition to addressing problems with thoracic epidural catheter placement, alternatives to epidural catheter placement may also be suitable for VATS and smaller thoracic procedures when many practitioners would otherwise not place an epidural catheter.

Alternatives to midthoracic epidural analgesia include lower thoracic and lumbar epidural catheter placement, intercostal nerve blocks (ICNBs), paravertebral blocks, intrapleural catheters, local anesthetic infiltration, and systemic analgesia with one or more agents. Epidural catheters placed several dermatomes from the surgical site require larger volumes of analgesic. Even lumbar placement can be efficacious, particularly when used with hydrophilic opioids such as morphine.^{44,45} ICNBs can be performed percutaneously or under direct vision, using single injections or placement of an intercostal catheter, or with cryotherapy. ICNBs are generally administered as single injections at least two dermatomes above and below the incision. Intercostal catheters can be placed, they but tend to be associated with less reliable spread of local anesthetic as well as rapid local anesthetic absorption and may be less effective than epidural analgesia.^{46–48} Although cryotherapy of the intercostal nerves under direct vision avoids many of these issues, it is not as effective as epidural analgesia with respect to both quality of acute pain relief and preservation of lung function,⁴⁹ and it may also lead to increases in chronic pain.⁷ Paravertebral blocks can be performed as single injections or *via* a paravertebral catheter. Paravertebral catheters can be placed percutaneously or intraoperatively under direct vision and are more suitable than epidural catheters when coagulopathy is of concern. Intraoperative paravertebral catheter placement precludes to an extent its use in a preemptive fashion. However, as indicated earlier, experience with epidural catheters suggests that this may not be very detrimental,

particularly if analgesia for the remainder of the perioperative period is effective. In at least some studies of acute pain, paravertebral blocks may be as effective as thoracic epidural analgesia with respect to pain control and preservation of pulmonary function after thoracotomy.⁵⁰ Intrapleural catheter placement can be performed percutaneously or under direct vision at the time of surgery. Intrapleural catheters are notable for the absorption of local anesthetic and less effective pain control when compared with epidural analgesia.⁵¹ Local anesthetic infiltration added little to a combination of epidural analgesia and ICNBs.⁵²

Systemic Analgesics and Adjuncts. Systemic analgesics are the main alternative to more invasive techniques, can be adjuncts to these techniques, and become the mainstay of analgesic therapy when invasive approaches are discontinued. Opioids, ideally administered initially *via* intravenous patient-controlled analgesia and upon discharge orally, are the main component of systemic analgesic therapy for thoracic procedures. Although respiratory depression is a potential side effect with systemic opioids, it should be appreciated that some patients may hypoventilate because of inadequate analgesia, in which case ventilation may actually improve after systemic opioid administration. As with more invasive approaches, nonsteroidal antiinflammatory drugs continue to be an important adjunct to opioid analgesia,^{53,54} along with acetaminophen.⁴⁰ Tramadol administered by continuous intravenous infusion may be as effective as thoracic epidural morphine.⁵⁵ Given their efficacy in other types of surgery, the *N*-methyl-D-aspartate receptor antagonists ketamine and dextromethorphan, which both enhance *epidural* analgesia,⁵⁶⁻⁵⁸ and the anticonvulsant gabapentin⁵⁹⁻⁶¹ may eventually play prominent roles in providing analgesia for thoracic procedures. Their ability to decrease subsequent pain and analgesic consumption in other procedures and animal models of thoracotomy pain argue for their use, particularly in individuals at high risk of development of substantial perioperative pain or in those individuals in whom more invasive analgesic regimens are not possible.

Complications. Initial concern that thoracic epidural catheter insertion would lead to more frequent complications has not been borne out. In fact, upper thoracic epidural catheter placement may be associated with fewer serious complications than lower thoracic or lumbar epidural placement.^{62,63} The reason for this probably resides in the increased distance from nerve roots involved in lower extremity, bowel, and bladder function. The potentially catastrophic complications of epidural or intraspinal hematoma are best prevented by realization that motor blockade should not occur with dilute local anesthetic solutions, and postoperative motor weakness should trigger immediate imaging studies and neurosurgical consultation. Clearly, concerns about coagulopathy can limit epidural catheter placement.

The concern about pneumothorax with performance of ICNBs is obviated in the case of thoracic surgery because a chest tube is generally placed. However, the total dose of local anesthetic should be carefully calculated, because ICNBs are notable for high systemic blood levels from rapid absorption of local anesthetic. The issues related to paravertebral blocks are similar to those of ICNBs and also include hypotension from sympathectomy in some patients because of the proximity of the paravertebral space to the neuraxis.

Surgical Strategies

Although many factors related to patient selection and the need for a particular surgical procedure are unalterable, there remain a number of modifiable technical aspects of the surgery purported to affect postoperative pain. These include the surgical approach (open thoracotomy *vs.* VATS), the type of incision for open procedures (posterolateral *vs.* muscle sparing *vs.* sternotomy *vs.* transverse sternothoracotomy ["clamshell"]), whether or not ribs are resected, the extent of intercostal nerve preservation, and the method of rib approximation at the conclusion of the procedure. As delineated above, the minimally invasive approach offered by VATS seems to have limited impact on the development of long-term postthoracotomy pain,^{3,4} which is probably due to intercostal nerve and chest wall muscle trauma from trocar insertion. However, there is some evidence that VATS is associated with reductions in acute postsurgical pain, which is likely related to the smaller length of the incision and less rib retraction.⁶⁴ Although the surgical objective may dictate the operative approach, it is useful to note that the incidence of long-term pain after sternotomy¹¹ is reported to be less than after thoracotomy. This may be the result of less intercostal nerve and chest wall muscle trauma coupled with a surgical closure that produces a more stable chest wall. Although there are currently no data on pain after transverse sternothoracotomy, the possibility of intercostal nerve trauma and chest wall instability seems to be at least as great as for thoracotomy. Despite their distinct cosmetic advantages, muscle-sparing incisions seem to have minimal impact on postoperative pain development when compared with posterolateral incisions.⁶⁵⁻⁶⁷ This is somewhat inconsistent with data indicating reduced intercostal nerve dysfunction after muscle sparing incisions when compared with posterolateral incisions.¹⁰ Rib resection could reduce intercostal nerve trauma by avoiding trauma created by rib retraction or trocar insertion, and retrospective data from open thoracotomy⁷ and VATS⁶⁸ support this contention. However, it is conceivable that periosteal scarring from rib resection might become a source of pain. Although preservation of the intercostal nerves seems to be a worthy surgical goal, accomplishing this is encumbered by frequent anatomical variation in the course of the nerves⁶⁹ and their lack of bony

protection along the entire length of the rib.⁷⁰ Finally, techniques that approximate the ribs so as to minimize suture impingement of the intercostal nerves⁷¹ or improve rib fixation⁷² have been demonstrated to reduce pain after surgery.

Strategies for Treating Long-term Pain

Although effective analgesic therapy seems to reduce the intensity and prevalence of chronic pain after thoracic surgery,^{1,7,26,27} some patients, whether undergoing VATS or open procedures, still have development of chronic pain after thoracic surgery. Chronic postthoracotomy pain has been defined somewhat arbitrarily as “pain that recurs or persists along a thoracotomy scar at

least two months following the surgical procedure.”⁷³ Despite this definition, it is important to identify as early as possible patients with higher than expected pain levels so that appropriate therapy can be initiated, because analgesic therapy that is initiated earlier may be more effective.^{74,75} As indicated above, a number of demographic and clinical factors help to identify patients predisposed to development of chronic postsurgical pain.

Long-term pain after thoracic surgery can be localized or radicular in nature and burning or aching in quality. The pain may have a pleuritic component and be exacerbated by movement of the ipsilateral shoulder.⁷³ The development of complex regional pain syndrome in the ipsilateral upper extremity can also occur.⁷⁶ As with

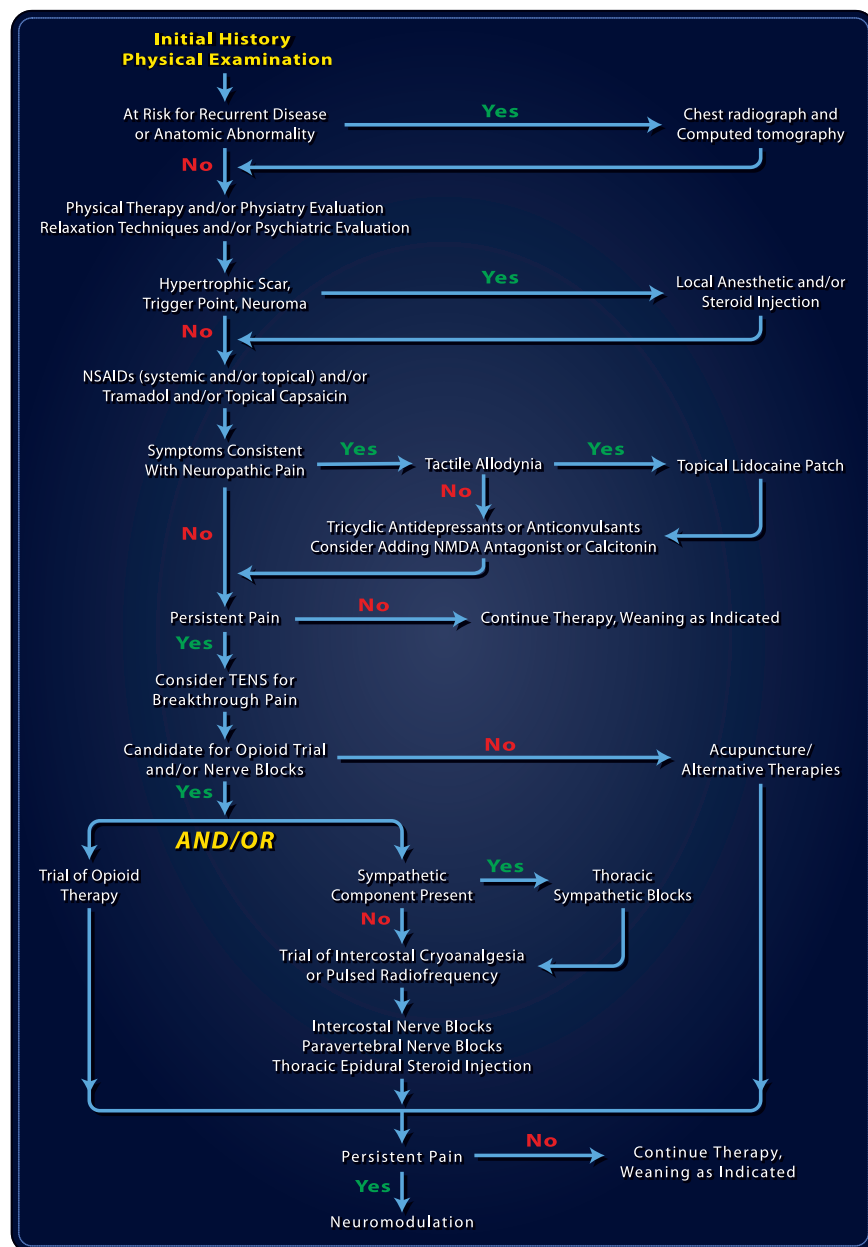


Fig. 2. Flow diagram for management of chronic pain following thoracic surgery. As part of the initial evaluation, medical or surgical problems that could initiate or exacerbate pain must be identified. Although most pain syndromes after thoracic surgery are neuropathic, it is important to identify myofascial pain which is treatable with specific interventions. Multiple topical and systemic medications are available for treating the various types of pain. In suitable patients, a trial of opioids can be instituted in parallel, before, or after a series of nerve blocks. Not all therapeutic options are appropriate for all patients, and care must be individualized. See text for additional details. NMDA = *N*-methyl-D-aspartate; NSAID = nonsteroidal antiinflammatory drug; TENS = transcutaneous electrical nerve stimulation.

the evaluation of any pain syndrome, it is essential to consider whether the pain is an indicator of some other process. This is of particular concern when evaluating patients with previous pleural or chest wall lesions, although bony instability, broken wires, retained foreign bodies, and lung herniation can also serve as pain generators. Although most cases of postthoracotomy pain are believed to be neuropathic in origin, myofascial pain can be a contributing and treatable source of discomfort.⁷⁷ The approach to pain after thoracic surgery is guided by the intensity of the pain as well as any associated disability. After a comprehensive evaluation, an individualized treatment plan should be crafted from one or more pharmacologic, interventional, and behavioral options (fig. 2).⁷⁷⁻⁸⁷ Because there are still relatively few outcome studies on the treatment of chronic pain after thoracic surgery, most aspects of the approach advocated in figure 2 are imputed from studies and experience with other types of chronic pain. Referral to a pain specialist may be necessary for pain that is refractory.

Conclusions

The acute and chronic pain that accompanies thoracic surgery is significant but often underappreciated, with an established level of physiologic and functional impact, and unknown social and economic costs. It is likely that an aggressive perioperative analgesic regimen, apart from its more immediate benefits with respect to comfort and pulmonary function, will lead to reductions in longer-term pain.^{1,7,26,27} When it manifests itself, such long-term pain should be pursued early and aggressively using an analgesic strategy tailored to the specific features of that pain.

The authors thank Daniel Nyhan, M.D. (Professor, Anesthesiology and Critical Care Medicine, Johns Hopkins Medical Institutions, Baltimore, Maryland), for comments and suggestions.

References

- Ochroch EA, Gottschalk A, Augostides J, Carson KA, Kent L, Malayaman N, Kaiser LR, Aukburg SJ: Long-term pain and activity during recovery from major thoracotomy using thoracic epidural analgesia. *ANESTHESIOLOGY* 2002; 97:1234-44
- Dajczman E, Gordon A, Kreisman H, Wolkove N: Long-term postthoracotomy pain. *Chest* 1991; 99:270-4
- Landreneau RJ, Mack MJ, Hazelrigg SR, Naunheim K, Dowling RD, Ritter P, Magee MJ, Nunchuck S, Keenan RJ, Ferson PF: Prevalence of chronic pain after pulmonary resection by thoracotomy or video-assisted thoracic surgery. *J Thorac Cardiovasc Surg* 1994; 107:1079-85
- Bertrand PC, Regnard JF, Spaggiari L, Levi JF, Magdeleinat P, Guibert L, Levasseur P: Immediate and long-term results after surgical treatment of primary spontaneous pneumothorax by VATS. *Ann Thorac Surg* 1996; 61:1641-5
- Sabanathan S, Eng J, Mearns AJ: Alterations in respiratory mechanics following thoracotomy. *J R Coll Surg Edinb* 1990; 35:144-50
- Shulman M, Sandler AN, Bradley JW, Young PS, Brebner J: Postthoracotomy pain and pulmonary function following epidural and systemic morphine. *ANESTHESIOLOGY* 1984; 61:569-75
- Sabanathan S: Has postoperative pain been eradicated? *Ann R Coll Surg Engl* 1995; 77:202-9
- Scawn ND, Pennefather SH, Soorae A, Wang JY, Russell GN: Ipsilateral shoulder pain after thoracotomy with epidural analgesia: The influence of phrenic nerve infiltration with lidocaine. *Anesth Analg* 2001; 93:260-4
- Tan N, Agnew NM, Scawn ND, Pennefather SH, Chester M, Russell GN: Suprascapular nerve block for ipsilateral shoulder pain after thoracotomy with thoracic epidural analgesia: A double-blind comparison of 0.5% bupivacaine and 0.9% saline. *Anesth Analg* 2002; 94:199-202
- Benedetti F, Vighetti S, Ricco C, Amanzio M, Bergamasco L, Casadio C, Cianci R, Giobbe R, Oliaro A, Bergamasco B, Maggi G: Neurophysiologic assessment of nerve impairment in posterolateral and muscle-sparing thoracotomy. *J Thorac Cardiovasc Surg* 1998; 115:841-7
- Kalso E, Mennander S, Tasmuth T, Nilsson E: Chronic post-sternotomy pain. *Acta Anaesthesiol Scand* 2001; 45:935-9
- Haythornthwaite JA, Raja SN, Fisher B, Frank SM, Brendler CB, Shir Y: Pain and quality of life following radical retropubic prostatectomy. *J Urol* 1998; 160:1761-4
- Katz J, Jackson M, Kavanagh BP, Sandler AN: Acute pain after thoracic surgery predicts long-term post-thoracotomy pain. *Clin J Pain* 1996; 12:50-5
- Bachiocco V, Scesi M, Morselli AM, Carli G: Individual pain history and familial pain tolerance models: Relationships to post-surgical pain. *Clin J Pain* 1993; 9:266-71
- Taenzler P, Melzack R, Jeans ME: Influence of psychological factors on postoperative pain, mood and analgesic requirements. *Pain* 1986; 24:331-42
- Perttunen K, Tasmuth T, Kalso E: Chronic pain after thoracic surgery: A follow-up study. *Acta Anaesthesiol Scand* 1999; 43:563-7
- Keller SM, Carp NZ, Levy MN, Rosen SM: Chronic post thoracotomy pain. *J Cardiovasc Surg (Torino)* 1994; 35:161-4
- Ugolini D, Boddi V, Fontana I, Nesi A, Taddei M, Santini PF, Dragotto A, Notaristefano T, Regio S, Gigli PM, Salani G, Palmiello A: Features and evolution of postoperative pain in patients undergoing thoracotomy [in Italian]. *Minerva Chir* 1996; 51:109-20
- Perkins FM, Kehlet H: Chronic pain as an outcome of surgery: A review of predictive factors. *ANESTHESIOLOGY* 2000; 93:1123-33
- Amar D, Roistacher N, Burt M, Reinsel RA, Ginsberg RJ, Wilson RS: Clinical and echocardiographic correlates of symptomatic tachyarrhythmias after non-cardiac thoracic surgery. *Chest* 1995; 108:349-54
- Oka T, Ozawa Y, Ohkubo Y: Thoracic epidural bupivacaine attenuates supraventricular tachyarrhythmias after pulmonary resection. *Anesth Analg* 2001; 93:253-9
- Kissin I: Preemptive analgesia: Why its effect is not always obvious. *ANESTHESIOLOGY* 1996; 84:1015-9
- Moiniche S, Kehlet H, Dahl JB: A qualitative and quantitative systematic review of preemptive analgesia for postoperative pain relief: The role of timing of analgesia. *ANESTHESIOLOGY* 2002; 96:725-41
- Katz J, Kavanagh BP, Sandler AN, Nierenberg H, Boylan JF, Friedlander M, Shaw BF: Preemptive analgesia: Clinical evidence of neuroplasticity contributing to postoperative pain. *ANESTHESIOLOGY* 1992; 77:439-46
- Doyle E, Bowler GM: Pre-emptive effect of multimodal analgesia in thoracic surgery. *Br J Anaesth* 1998; 80:147-51
- Obata H, Saito S, Fujita N, Fuse Y, Ishizaki K, Goto F: Epidural block with mepivacaine before surgery reduces long-term post-thoracotomy pain. *Can J Anaesth* 1999; 46:1127-32
- Sentürk M, Özca PE, Talu GK, Kiyani E, Çamci E, Özyalçın S, Dilege S, Pembeci K: The effects of three different analgesia techniques on long-term postthoracotomy pain. *Anesth Analg* 2002; 94:11-5
- Soto RG, Fu ES: Acute pain management for patients undergoing thoracotomy. *Ann Thorac Surg* 2003; 75:1349-57
- Ochroch EA, Gottschalk A: Impact of acute pain and its management for thoracic surgical patients. *Thorac Surg Clin* 2005; 15:105-21
- Tan CN, Guha A, Scawn ND, Pennefather SH, Russell GN: Optimal concentration of epidural fentanyl in bupivacaine 0.1% after thoracotomy. *Br J Anaesth* 2004; 92:670-4
- Niemi G, Breivik H: Adrenaline markedly improves thoracic epidural analgesia produced by a low-dose infusion of bupivacaine, fentanyl and adrenaline after major surgery: A randomized, double-blind, crossover study with and without adrenaline. *Acta Anaesthesiol Scand* 1998; 42:897-909
- Niemi G, Breivik H: Epinephrine markedly improves thoracic epidural analgesia produced by a small-dose infusion of ropivacaine, fentanyl, and epinephrine after major thoracic or abdominal surgery: A randomized, double-blinded crossover study with and without epinephrine. *Anesth Analg* 2002; 94:1598-605
- Ozyalçin NS, Yucel A, Camlica H, Dereli N, Andersen OK, Rendt-Nielsen L: Effect of pre-emptive ketamine on sensory changes and postoperative pain after thoracotomy: Comparison of epidural and intramuscular routes. *Br J Anaesth* 2004; 93:356-61
- Eisenach JC, Yaksh TL: Epidural ketamine in healthy children—what's the point? *Anesth Analg* 2003; 96:626-7
- Sveticic G, Gentilini A, Eichenberger U, Zanderigo E, Sartori V, Luginbuhl M, Curatolo M: Combinations of bupivacaine, fentanyl, and clonidine for lumbar epidural postoperative analgesia: A novel optimization procedure. *ANESTHESIOLOGY* 2004; 101:1381-93
- Omais M, Lauretti GR, Paccola CA: Epidural morphine and neostigmine for postoperative analgesia after orthopedic surgery. *Anesth Analg* 2002; 95:1698-701
- Singh H, Bossard RF, White PF, Yeatts RW: Effects of ketorolac versus bupivacaine coadministration during patient-controlled hydromorphone epidural analgesia after thoracotomy procedures. *Anesth Analg* 1997; 84:564-9

38. McCrory C, Diviney D, Moriarty J, Luke D, Fitzgerald D: Comparison between repeat bolus intrathecal morphine and an epidurally delivered bupivacaine and fentanyl combination in the management of post-thoracotomy pain with or without cyclooxygenase inhibition. *J Cardiothorac Vasc Anesth* 2002; 16:607-11
39. Levesque LE, Brophy JM, Zhang B: The risk for myocardial infarction with cyclooxygenase-2 inhibitors: A population study of elderly adults. *Ann Intern Med* 2005; 142:481-9
40. Mac TB, Girard F, Chouinard P, Boudreault D, Lafontaine ER, Ruel M, Ferraro P: Acetaminophen decreases early post-thoracotomy ipsilateral shoulder pain in patients with thoracic epidural analgesia: A double-blind placebo-controlled study. *J Cardiothorac Vasc Anesth* 2005; 19:475-8
41. Drasner K: Thoracic epidural anesthesia: Asleep at the wheel? *Anesth Analg* 2004; 99:578-9
42. Horlocker TT, Abel MD, Messick JM Jr, Schroeder DR: Small risk of serious neurologic complications related to lumbar epidural catheter placement in anesthetized patients. *Anesth Analg* 2003; 96:1547-52
43. Rosenquist RW, Birnbach DJ: Epidural insertion in anesthetized adults: Will your patients thank you? *Anesth Analg* 2003; 96:1545-6
44. Grant GJ, Zakowski M, Ramanathan S, Boyd A, Turndorf H: Thoracic versus lumbar administration of epidural morphine for postoperative analgesia after thoracotomy. *Reg Anesth* 1993; 18:351-5
45. Sandler AN, Stringer D, Panos L, Badner N, Friedlander M, Koren G, Katz J, Klein J: A randomized, double-blind comparison of lumbar epidural and intravenous fentanyl infusions for postthoracotomy pain relief: Analgesic, pharmacokinetic, and respiratory effects. *ANESTHESIOLOGY* 1992; 77:626-34
46. Perntunen K, Nilsson E, Heinonen J, Hirvisalo EL, Salo JA, Kalso E: Extradural, paravertebral and intercostal nerve blocks for post-thoracotomy pain. *Br J Anaesth* 1995; 75:541-7
47. Kaiser AM, Zollinger A, De LD, Largiader F, Weder W: Prospective, randomized comparison of extrapleural versus epidural analgesia for postthoracotomy pain. *Ann Thorac Surg* 1998; 66:367-72
48. Debrenceni G, Molnar Z, Szelig L, Molnar TF: Continuous epidural or intercostal analgesia following thoracotomy: A prospective randomized double-blind clinical trial. *Acta Anaesthesiol Scand* 2003; 47:1091-5
49. Brichon PY, Pison C, Chaffanjon P, Fayot P, Buchberger M, Neron L, Bocca A, Verdier J, Sarrazin R: Comparison of epidural analgesia and cryoanalgesia in thoracic surgery. *Eur J Cardiothorac Surg* 1994; 8:482-6
50. Karmakar MK: Thoracic paravertebral block. *ANESTHESIOLOGY* 2001; 95:771-80
51. Schneider RF, Villamena PC, Harvey J, Surick BG, Surick IW, Beattie EJ: Lack of efficacy of intrapleural bupivacaine for postoperative analgesia following thoracotomy. *Chest* 1993; 103:414-6
52. Cerfolio RJ, Bryant AS, Bass CS, Bartolucci AA: A prospective, double-blinded, randomized trial evaluating the use of preemptive analgesia of the skin before thoracotomy. *Ann Thorac Surg* 2003; 76:1055-8
53. Rhodes M, Conacher I, Morrill G, Hilton C: Nonsteroidal antiinflammatory drugs for postthoracotomy pain: A prospective controlled trial after lateral thoracotomy. *J Thorac Cardiovasc Surg* 1992; 103:17-20
54. Pavy T, Medley C, Murphy DF: Effect of indomethacin on pain relief after thoracotomy. *Br J Anaesth* 1990; 65:624-7
55. Bloch MB, Dyer RA, Heijke SA, James MF: Tramadol infusion for postthoracotomy pain relief: A placebo-controlled comparison with epidural morphine. *Anesth Analg* 2002; 94:523-8
56. Suzuki M, Kinoshita T, Kikutani T, Yokoyama K, Inagi T, Sugimoto K, Haraguchi S, Hisayoshi T, Shimada Y: Determining the plasma concentration of ketamine that enhances epidural bupivacaine-and-morphine-induced analgesia. *Anesth Analg* 2005; 101:777-84
57. Kararmaz A, Kaya S, Karaman H, Turhanoglu S, Ozyilmaz MA: Intraoperative intravenous ketamine in combination with epidural analgesia: Postoperative analgesia after renal surgery. *Anesth Analg* 2003; 97:1092-6
58. Yeh CC, Jao SW, Huh BK, Wong CS, Yang CP, White WD, Wu CT: Preincisional dextromethorphan combined with thoracic epidural anesthesia and analgesia improves postoperative pain and bowel function in patients undergoing colonic surgery. *Anesth Analg* 2005; 100:1384-9
59. Dirks J, Fredensborg BB, Christensen D, Fomsgaard JS, Flyger H, Dahl JB: A randomized study of the effects of single-dose gabapentin versus placebo on postoperative pain and morphine consumption after mastectomy. *ANESTHESIOLOGY* 2002; 97:560-4
60. Pandey CK, Priye S, Singh S, Singh U, Singh RB, Singh PK: Preemptive use of gabapentin significantly decreases postoperative pain and rescue analgesic requirements in laparoscopic cholecystectomy. *Can J Anaesth* 2004; 51:358-63
61. Buvanendran A, Kroin JS, Kerns JM, Nagalla SN, Tuman KJ: Characterization of a new animal model for evaluation of persistent postthoracotomy pain. *Anesth Analg* 2004; 99:1453-60
62. Giebler RM, Scherer RU, Peters J: Incidence of neurologic complications related to thoracic epidural catheterization. *ANESTHESIOLOGY* 1997; 86:55-63
63. Tanaka K, Watanabe R, Harada T, Dan K: Extensive application of epidural anesthesia and analgesia in a university hospital: Incidence of complications related to technique. *Reg Anesth* 1993; 18:34-8
64. Forster R, Storck M, Schafer JR, Honig E, Lang G, Liewald F: Thoracoscopy versus thoracotomy: A prospective comparison of trauma and quality of life. *Langenbecks Arch Surg* 2002; 387:32-6
65. Hazelrigg SR, Landreneau RJ, Boley TM, Priesmeyer M, Schmaltz RA, Nawarawong W, Johnson JA, Walls JT, Curtis JJ: The effect of muscle-sparing versus standard posterolateral thoracotomy on pulmonary function, muscle strength, and postoperative pain. *J Thorac Cardiovasc Surg* 1991; 101:394-400
66. Landreneau RJ, Pigula F, Luketich JD, Keenan RJ, Bartley S, Fetterman LS, Bowers CM, Weyant RJ, Ferson PF: Acute and chronic morbidity differences between muscle-sparing and standard lateral thoracotomies. *J Thorac Cardiovasc Surg* 1996; 112:1346-50
67. Ochroch EA, Gottschalk A, Augoustides JG, Aukburg SJ, Kaiser LR, Shrager JB: Pain and physical function are similar following axillary, muscle-sparing vs posterolateral thoracotomy. *Chest* 2005; 128:2664-70
68. Richardson J, Sabanathan S: Pain management in video assisted thoracic surgery: Evaluation of localised partial rib resection: A new technique. *J Cardiovasc Surg (Torino)* 1995; 36:505-9
69. Schaloch G, Aho A, Lang G: Microanatomy and number of nerve fibres of the lower intercostal nerves with respect to a nerve anastomosis: Donor nerve analysis. I. (IV). *Electromyogr Clin Neurophysiol* 1992; 32:171-85
70. Moore DC: Anatomy of the intercostal nerve: Its importance during thoracic surgery. *Am J Surg* 1982; 144:371-3
71. Cerfolio RJ, Price TN, Bryant AS, Sale BC, Bartolucci AA: Intercostal sutures decrease the pain of thoracotomy. *Ann Thorac Surg* 2003; 76:407-11
72. Iwasaki A, Hamatake D, Shirakusa T: Biosorbable poly-L-lactide rib-connecting pins may reduce acute pain after thoracotomy. *Thorac Cardiovasc Surg* 2004; 52:49-53
73. Task Force on Taxonomy of the International Association for the Study of Pain: Classification of Chronic Pain: Descriptions of Chronic Pain Syndromes and Definitions of Pain Terms, 2nd edition. Edited by Mersky H, Bogduk N. Seattle, IASP Press, 1994, pp 143-4
74. AbuRahma AF, Robinson PA, Powell M, Bastug D, Boland JP: Sympathectomy for reflex sympathetic dystrophy: Factors affecting outcome. *Ann Vasc Surg* 1994; 8:372-9
75. Muizelaar JP, Kleyer M, Hertogs IA, DeLange DC: Complex regional pain syndrome (reflex sympathetic dystrophy and causalgia): Management with the calcium channel blocker nifedipine and/or the alpha-sympathetic blocker phenoxylbenzamine in 59 patients. *Clin Neurol Neurosurg* 1997; 99:26-30
76. Bonica JJ: Chest pain related to cancer, *The Management of Pain*, 2nd edition. Edited by Bonica JJ, Loeser JD, Chapman CR, Fordyce WE. Philadelphia, Lea & Febiger, 1990, pp 1083-113
77. Hamada H, Moriwaki K, Shiroyama K, Tanaka H, Kawamoto M, Yuge O: Myofascial pain in patients with postthoracotomy pain syndrome. *Reg Anesth Pain Med* 2000; 25:302-5
78. Watson CP, Evans RJ: The postmastectomy pain syndrome and topical capsaicin: A randomized trial. *Pain* 1992; 51:375-9
79. Devers A, Galer BS: Topical lidocaine patch relieves a variety of neuropathic pain conditions: An open-label study. *Clin J Pain* 2000; 16:205-8
80. Yosipovitch G, Widjanti SM, Goon A, Chan YH, Goh CL: A comparison of the combined effect of cryotherapy and corticosteroid injections versus corticosteroids and cryotherapy alone on keloids: A controlled study. *J Dermatolog Treat* 2001; 12:87-90
81. Fishbain D: Evidence-based data on pain relief with antidepressants. *Ann Med* 2000; 32:305-16
82. Gilron I, Bailey JM, Tu D, Holden RR, Weaver DF, Houlnden RL: Morphine, gabapentin, or their combination for neuropathic pain. *N Engl J Med* 2005; 352:1324-34
83. Moore RA, Tramer MR, Carroll D, Wiffen PJ, McQuay HJ: Quantitative systematic review of topically applied non-steroidal anti-inflammatory drugs. *BMJ* 1998; 316:333-8
84. Carrol EN, Badura AS: Focal intense brief transcutaneous electric nerve stimulation for treatment of radicular and postthoracotomy pain. *Arch Phys Med Rehabil* 2001; 82:262-4
85. Pastor J, Morales P, Cases E, Cordero P, Piqueras A, Galan G, Paris F: Evaluation of intercostal cryoanalgesia versus conventional analgesia in postthoracotomy pain. *Respiration* 1996; 63:241-5
86. Turner JA, Loeser JD, Deyo RA, Sanders SB: Spinal cord stimulation for patients with failed back surgery syndrome or complex regional pain syndrome: A systematic review of effectiveness and complications. *Pain* 2004; 108:137-47
87. Watson CP: The treatment of neuropathic pain: Antidepressants and opioids. *Clin J Pain* 2000; 16:549-55