

Intracranial Hypotension: A Case of Spontaneous Arachnoid Rupture in a Parturient

Andrea Albertin, M.D.,* Chiara Marchetti, M.D.,† Daniela Mamo, M.D.,† Davide Poli, M.D.,† Elisa Dedola, M.D.†

INTRACRANIAL hypotension is an important cause of new daily persistent postural headaches.¹ Among the causes of intracranial hypotension, many cases are due to spontaneous cerebrospinal fluid (CSF) leak, often associated with an underlying generalized connective tissue disorder.² Intracranial hypotension may also be due to dural puncture after epidural catheter positioning.

Most cases of intracranial hypotension are believed to be self-limiting, and initial treatment is based on anti-inflammatory drugs, bed rest, and hydration. In some patients, persistent symptoms are present; for them, available treatment options include epidural blood patching,³ percutaneous fibrin sealant placement,⁴ and surgical repair of the underlying CSF leak.⁵

We report a case of intracranial hypotension due to spontaneous arachnoid rupture in a parturient woman during the effort of delivery.

Case Report

A 36-yr-old primiparous woman started spontaneous term labor after a physiologic pregnancy. Her only clinical record was recurrent tensive cephalgia and a sense of tightness in her shoulders and neck few days before delivery.

At 3 cm of dilatation, with the baby's head at level 0 in the correct position, epidural catheter positioning was performed by a skilled anesthesiologist. Aspiration was performed, and a test dose of 40 mg lidocaine was administered to rule out intravascular or intrathecal placement of the catheter. Fentanyl, 100 µg, was then administered, followed by boluses of 8 mg ropivacaine, 0.2%, up to 32 mg local anesthetic solution. After approximately 20 min, good analgesia was achieved, and continuous infusion of 8-12 mg/h ropivacaine, 0.15%, was started. When complete dilatation was reached, the continuous infusion of local anesthetic solution was stopped.

During the expulsive phase of delivery, the patient was kept in the squatting position. This phase lasted 20 min. The newborn was female, weighed 3,200 mg, had an Apgar score of 10/10, and had a cord pH of 7.37. During labor and delivery, no motor blockade was observed.

One hour after delivery, the patient began to report frontal headache, radiating to the whole head and exacerbated by movement. No laboratory blood abnormality was present, nor was any blood pressure alteration. Ketorolac, 30 mg, was administered without any benefit.

On the seventh postdelivery day, the headache became worse: The symptoms were continuous even in the recumbent position, worsen-

ing when the patient was upright. Vertigo, obtundation, and nausea were also present.

The patient was treated as if she had a dural break due to the epidural catheter positioning: She received hydration with 2,000 ml/day intravenous saline, 90 mg/day ketorolac, and 3 g/day paracetamol with no benefit.

Ten days after delivery, the patient underwent cranial magnetic resonance imaging scanning. The scanning was performed without contrast because the patient was breastfeeding. Neuroimaging showed diffuse bilateral subdural collections in both hemispheres and in the posterior cranial fossa extending to the craniospinal junction, with a modest downward displacement of the cerebellar tonsilla. A C5-C6 herniation was also present. No extradural CSF collection was present (fig. 1).

The diagnosis was spontaneous effort-related rupture of the arachnoid membrane. It is possible that the cervical hernia may have caused the presence of an easier point of break and that the position kept by the patient during expulsive phase of delivery may have played a role. The symptoms were due both to the intracranial hypotension and to the compression on the brain by the CSF sequestered between the arachnoid membrane and dura madre. Bed rest proved to be the appropriate therapy, with relief of the symptoms within 1 month.

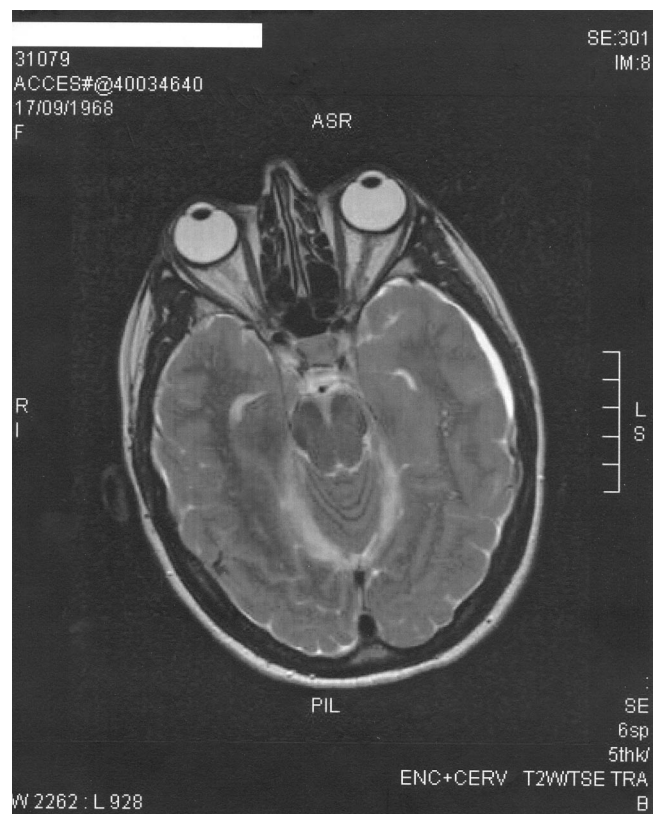


Fig. 1. Magnetic resonance image showing diffuse bilateral subdural collections of cerebral spinal fluid in both hemispheres.

* Staff Anesthesiologist, † Anesthesia Fellow.

Received from the Department of Anesthesiology, Vita-Salute University of Milan, IRCCS San Raffaele, Milan, Italy. Submitted for publication August 8, 2005. Accepted for publication November 10, 2005. Support was provided solely from institutional and/or departmental sources.

Address correspondence to Dr. Albertin: Department of Anesthesiology, IRCCS H San Raffaele, Via Olgettina 60, Milan 20132, Italy. albertin.andrea@hsr.it. Individual article reprints may be purchased through the Journal Web site, www.anesthesiology.org.

Discussion

The syndrome of low-pressure headache is usually due to a leak of CSF through the dura, either because of a spontaneous tear or as a complication of a dural puncture. In this case, the dura was intact, and the leak involved only the arachnoid, so that CSF collection was subdural. In spontaneous intracranial hypotension syndrome, the occurrence of subdural collections is secondary to the rupture of bridging veins when the brain pulls away from the dura as the CSF decreases.⁶

The main controversial question of this report can be considered the potential of unrecognized dural puncture. However, the anesthesiologist excluded a wet tap defined as an inadvertent dural puncture by the epidural needle or catheter with CSF return or clinical evidence of motor blockade.⁷ Moreover, the start of symptoms in addition to the evidence of C5-C6 herniation suggested a different etiology.

The different forms of low-pressure headache must be distinguished to start a correct treatment. Treatment of spontaneous intracranial hypotension syndrome begins with noninvasive therapeutic modalities, including bed rest, use of an abdominal binder, oral caffeine, and ste-

roids. If the patient continues to be symptomatic, available treatment options include epidural blood patching, percutaneous fibrin sealant placement, and surgical repair of the underlying CSF leak. Treatment options for postdural puncture headache include bed rest, intravenous saline infusion, steroids, and antiinflammatory drugs. Our patient was successfully treated with bed rest, while antiinflammatory drugs and intravenous saline infusion proved to be inefficient.

References

1. Schievink WI, Maya MM, Louy C: Cranial MRI predicts outcome of spontaneous intracranial hypotension. *Neurology* 2005; 64:1282-4
2. Schievink WI, Gordon OK, Tourje J: Connective tissue disorders with spontaneous spinal cerebrospinal fluid leaks and intracranial hypotension: a prospective study. *Neurosurgery* 2004; 54:65-70
3. Sencakova D, Mokri B, McClelland RL: The efficacy of epidural blood patch in spontaneous CSF leaks. *Neurology* 2001; 57:1921-3
4. Schievink WI, Maya MM, Moser FM: Treatment of spontaneous intracranial hypotension with percutaneous placement of a fibrin sealant: Report of four cases. *J Neurosurg* 2004; 100:1098-100
5. Schievink WI, Morreale VM, Atkinson JL, Meyer FB, Piepgras DG, Ebersold MJ: Surgical treatment of spontaneous spinal cerebrospinal fluid leaks. *J Neurosurg* 1998; 88:243-6
6. O'Carroll CP, Brant-Zawadzki M: The syndrome of spontaneous intracranial hypotension. *Cephalalgia* 1999; 19:80-7
7. Pan PH, Bogard TD, Owen MD: Incidence and characteristics of failures in obstetric neuraxial analgesia and anesthesia: A retrospective analysis of 19,259 deliveries. *Int J Obstet Anesth* 2004; 13:227-33

Anesthesiology 2006; 104:610-2

© 2006 American Society of Anesthesiologists, Inc. Lippincott Williams & Wilkins, Inc.

Intracranial Subdural Hematomas and Cerebral Herniation after Labor Epidural with No Evidence of Dural Puncture

George A. Mashour, M.D., Ph.D.,* Lee H. Schwamm, M.D.,† Lisa Leffert, M.D.‡

INTRACRANIAL subdural hematoma is an infrequent but well-documented neurologic complication of epidural catheter placement that is typically associated with obvious dural puncture at the time of insertion.¹⁻⁵ This complication is also associated with spinal anesthesia (in which dural puncture is intrinsic to the procedure), as well as other instances of frank durotomy.⁶⁻¹¹ We report the case of a 40-yr-old parturient who received uncomplicated labor epidural analgesia with no evidence of dural puncture and who subsequently developed intracranial subdural hematomas leading to seizures and cerebral herniation.

Case Report

The patient was a previously healthy, primiparous 40-yr-old Chinese woman pregnant with twins. Her medical and surgical history was unremarkable, with the exception of a history of hepatitis B. She took no medications and reported an allergy to aspirin leading to rash. The patient presented to the obstetric service at 38 weeks' gestation for scheduled induction of labor and subsequently requested epidural analgesia. During the epidural placement, the patient was in the seated position, was prepared and draped in the usual sterile fashion, and received a 1% lidocaine skin wheal. The L4-L5 epidural space was then accessed using a 17-gauge Tuohy-Weiss needle using a loss of resistance to saline technique. The epidural placement was uncomplicated: It occurred on the first attempt without paresthesia and did not result in a visible cerebrospinal fluid (CSF) leak or any other clinical signs of dural puncture. Adequate epidural analgesia was easily attained with the usual dosages of local anesthetic.

Despite 2.5 h of maternal pushing, the presenting twin remained in the occiput-posterior position at 2+ station, and the decision was made to proceed with cesarean delivery. The delivery of her twins was subsequently uncomplicated, and the patient was discharged on postoperative day 3 with visiting nursing care. At the time of discharge, the patient was without specific complaints.

Three weeks later, the patient presented to the labor floor with a vague history of worsening headache, not clearly positional, which she said had been developing since her discharge. She reported a near-syncope episode and the presence of blurry vision, but she denied

* Clinical Fellow in Anaesthesia, Harvard Medical School. Chief Resident, Department of Anesthesia and Critical Care, Massachusetts General Hospital.
† Associate Professor of Neurology, Harvard Medical School. Director of Acute Stroke Services, Department of Neurology, Massachusetts General Hospital.
‡ Instructor in Anaesthesia, Harvard Medical School. Co-Chief of Obstetric Anesthesia, Massachusetts General Hospital.

Received from the Department of Anesthesia and Critical Care, Massachusetts General Hospital, Harvard Medical School, Boston, Massachusetts. Submitted for publication August 12, 2005. Accepted for publication November 10, 2005. Support was provided solely from institutional and/or departmental sources.

Address correspondence to Dr. Mashour: 55 Fruit Street, Clinics 309, Boston, Massachusetts 02114. gmashour@partners.org. Individual article reprints may be purchased through the Journal Web site, www.anesthesiology.org.

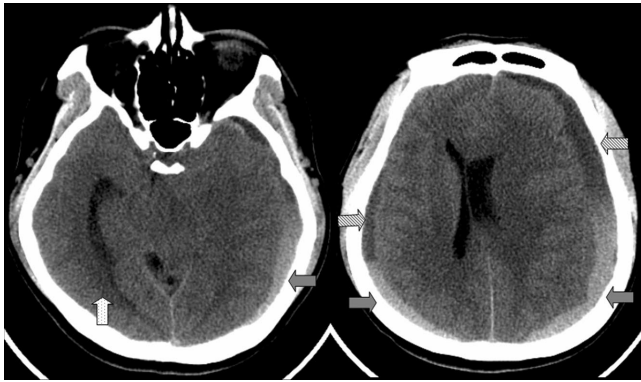

Fig. 1. Unenhanced computerized tomography scan of the brain on presentation demonstrates acute blood in a dependent position with a “hematocrit effect” (solid gray arrows), subacute blood (striped gray arrows), and entrapment of the right temporal horn (stippled white arrow).

weakness, numbness, nausea, or vomiting. Upon arrival to the hospital, the patient had a witnessed seizure in the elevator. Urgent, noncontrast computerized tomography of the head revealed large bilateral subdural hematomas containing acute and subacute blood (fig. 1). There was evidence of subfalcine and uncus herniation, entrapment of the right lateral ventricle, and mass effect with 7 mm of shift of midline structures to the right (fig. 1).

A neurosurgical consultation was immediately obtained, and urgent burr-hole craniotomies were performed for evacuation of the subdural hematomas. Other than a mild headache, the patient felt well and was without neurologic deficit in the postoperative setting. Despite the absence of a documented dural puncture or the presence of ongoing symptoms, the treating neurosurgeon requested that an epidural blood patch be performed to prevent further CSF loss and reaccumulation of the subdural hematomas.

The day after evacuation, the patient was sent to our Pain Clinic for fluoroscopic-guided epidural blood patch. Despite the additional pre-

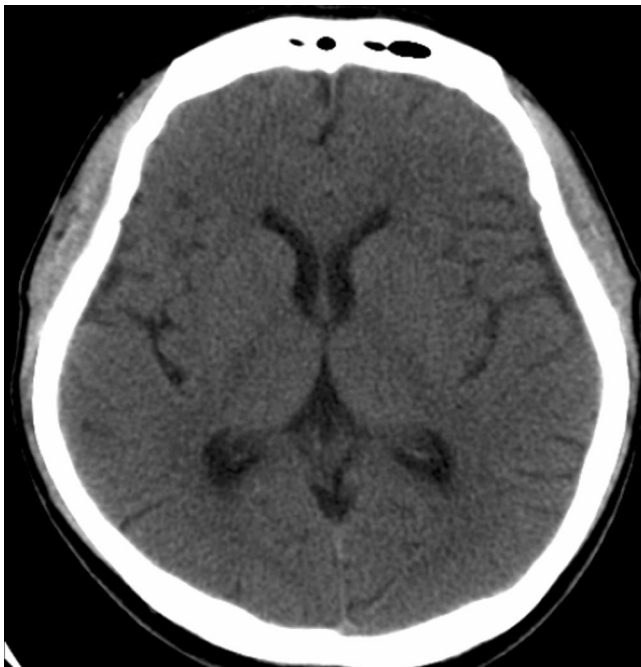


Fig. 2. Unenhanced computerized scan of the brain 1 month after surgical drainage demonstrates resolution of the subdural hematomas and mass effect.

caution of visualization under fluoroscopy, inadvertent dural puncture occurred at L3–L4 with a 20-gauge needle during the initial attempt, which was accompanied by the expected event of CSF fluid output under pressure. A second attempt at L4–L5 resulted in a successful epidural blood patch. The patient remained supine, with the head of the bed flat for 2 days. Subsequent neuroimaging revealed no significant interval change or evidence of new intracranial hemorrhage, subdural hemorrhage, or subdural fluid collection. The patient was subsequently discharged on postoperative day 5 without deficit. One month later, computerized tomography revealed no recurrence of hematoma or mass effect (fig. 2).

Discussion

The differential diagnosis of headache in the peripartum population includes muscle tension headache, migraine, preeclampsia or eclampsia, subarachnoid hemorrhage, stroke, tumor, and cerebral venous thrombosis.^{12,13} Post-dural puncture headache and meningitis must also be considered in the setting of recent neuraxial analgesia or anesthesia. Intracranial subdural hematoma is a rare but well-documented complication of epidural anesthesia.^{1–5} In these published reports, dural puncture was clearly noted at the time of epidural placement. In the current report, however, the patient had an apparently uncomplicated epidural placement, reported her headache 3 weeks postpartum, and had a nearly fatal neurologic outcome.

Given the absence of a frank wet tap in this patient, it was important to consider other possible etiologies of her bilateral subdural hematomas, such as traumatic brain injury, coagulopathy, intense Valsalva, or preexisting intracranial hypotension. The absence of a history of domestic abuse or external bruising, as well as the bilaterality of the hematomas, argues against traumatic etiology. An unrecognized coagulopathy that increased her risk of bleeding was also considered. If that had been the case, however, she would likely have been at risk for excessive bleeding at the time of her cesarean delivery and for development of a spinal epidural hematoma, neither of which occurred.

The question of whether the intense Valsalva during the 2.5 h of pushing could itself explain the subdural bleeding was raised. Spontaneous subdural hematoma is typically reported in elderly patients presumably due to brain atrophy and stretching of dural veins. It may also occur in younger individuals with preexisting spontaneous intracranial hypotension.¹⁴ In this patient population, there may be no detectable CSF pressure during lumbar puncture with a 20- or 22-gauge needle. In the event of dural compromise with the 17-gauge needle used during epidural placement in such a patient, it is unclear whether the typical signs of a wet tap would be evident.

The intracranial pressure in this patient underwent a dynamic course. Intracranial hypotension was likely a precipitating cause of the subdural hematoma formation,

either from preexisting disease or induced by occult dural tear. Accumulation of subdural blood and potential sealing of the CSF leak led to intracranial hypertension, resulting in herniation and ultimately relieved by craniotomy. At the time of epidural blood patch placement, however, the patient did demonstrate sufficient CSF pressure to manifest an obvious wet tap. This fact, in addition to her lack of symptoms before labor and epidural placement, argues against an underlying spontaneous intracranial hypotension. The most likely explanation is that this patient had an occult dural puncture that extended in the postpartum period, leading to the complication of rapid and significant CSF leak. This may have subsequently caused intracranial hypotension, stretching of the dural veins and subdural bleeding. The stoic nature of this particular patient, perhaps combined with a cultural unwillingness to complain, may have contributed to her late presentation.

The role of the epidural blood patch in this case is controversial. As first described by Gormley¹⁵ in 1960, the blood patch was proposed to treat a postdural puncture headache by tamponading the CSF leak. It followed, then, that a blood patch could be used to prevent further CSF leak and accumulation or reaccumulation of subdural hematomas. This outcome is not always the case: Subdural hematomas have been found to develop after inadvertent dural puncture even when an epidural blood patch was placed.³ Furthermore, blood patches themselves are not without known risks and have been reported to exacerbate neurologic symptoms of inadvertent dural punctures.¹⁶ It has also been suggested that administration of an epidural blood patch induced seizures in a patient with a postpartum headache and an undiagnosed intracranial subdural hematoma.¹⁷

Despite the use of fluoroscopy, our patient experienced the complication of inadvertent dural puncture during an attempted blood patch. One can only speculate as to why this documented dural puncture did not result in additional subdural bleeding. Possible explanations include the fact that the patient remained strictly supine for 2 days after the procedure (perhaps decreasing the likelihood of extending the dural tear and minimizing the gravitational forces on the potential CSF leak) and that a smaller needle was used for the blood patch than for the initial epidural (20 gauge *vs.* 17 gauge).

Postpartum headache can be relatively benign or alternatively can be a sign of significant pathology and should be evaluated promptly. Furthermore, in cases where the clinical history, signs, and symptoms are not clearly consistent with a dural puncture, neuroimaging should be strongly considered before epidural blood patch is performed. Detection of CSF leakage is also a diagnostic strategy that could be performed before further intervention.¹⁸ In conclusion, this case exemplifies that serious neurologic sequelae such as intracranial subdural hematomas and cerebral herniation can occur even in the absence of obvious dural puncture.

References

1. Skoldfors EK, Olofsson CI: Intracranial subdural haematoma complicates accidental dural tap during labour. *Eur J Obstet Gynecol Reprod Biol* 1998; 81:119-21
2. Vaughan DJA, Stirrup CA, Robinson PN: Cranial subdural haematoma associated with dural puncture in labour. *Br J Anaesth* 2000; 84:518-20
3. Davies JM, Murphy A, Smith M, O'Sullivan G: Subdural haematoma after dural puncture headache treated by epidural blood patch. *Br J Anaesth* 2001; 86:720-3
4. Kayacan N, Arici G, Karsli B, Erman M: Acute subdural haematoma after accidental dural puncture during epidural anaesthesia. *Int J Obstet Anesth* 2004; 13:47-9
5. Nolte CH, Lehmann TN: Postpartum headache resulting from bilateral chronic subdural hematoma after dural puncture. *Am J Emerg Med* 2004; 22:241-2
6. Bjarnhall M, Ekseth K, Bostrom S, Vegfors M: Intracranial subdural haematoma: A rare complication following spinal anaesthesia. *Acta Anaesthesiol Scand* 1996; 40:1249-51
7. Cohen JE, Godes J, Morales B: Postpartum bilateral subdural hematomas following spinal anesthesia: Case report. *Surg Neurol* 1997; 47:6-8
8. Acharya R, Chhabra SS, Ratra M, Sehgal AD: Cranial subdural haematoma after spinal anaesthesia. *Br J Anaesth* 2001; 86:893-5
9. Acharya R: Chronic subdural haematoma complicating spinal anaesthesia. *Neurol Sci* 2005; 25:348-50
10. Yildirim GB, Colakoglu S, Atakan TY, Buyukkirli H: Intracranial subdural hematoma after spinal anesthesia. *Int J Obstet Anesth* 2005; 14:159-62
11. Lu CH, Ho ST, Kong SS, Cherng CH, Wong CS: Intracranial subdural hematoma after unintended durotomy during spine surgery. *Can J Anaesth* 2002; 49:100-2
12. Stocks GM, Wooller DJA, Young JM, Fernando R: Postpartum headache after epidural blood patch: Investigation and diagnosis. *Br J Anaesth* 2000; 84:407-10
13. Silberstein SD: Headaches in pregnancy. *Neurol Clin* 2004; 22:727-56
14. DeNoronha RJ, Sharrack B, Hadjivassiliou M, Romanowski CA: Subdural haematoma: A potentially serious consequence of spontaneous intracranial hypotension. *J Neurol Neurosurg Psychiatry* 2003; 74:752-5
15. Gormley JB: Treatment of post-spinal headache. *ANESTHESIOLOGY* 1960; 21:565-6
16. Woodward WM, Levy DM, Dixon AM: Exacerbation of post-dural puncture headache after epidural blood patch. *Can J Anaesth* 1994; 41:628-31
17. Kardash K, Morrow F, Beique F: Seizures after epidural blood patch with undiagnosed subdural hematoma. *Reg Anesth Pain Med* 2002; 27:433-6
18. Takahashi M, Momose T, Kameyama M, Mizuno S, Kumakura Y, Ohtomo K: Detection of cerebrospinal fluid leakage in intracranial hypotension with radionuclide cisternography and blood activity monitoring. *Ann Nucl Med* 2005; 19:339-43

Cerebral Rebleeding by Spinal Anesthesia in a Patient with Undiagnosed Chronic Subdural Hematoma

Ahed Zeidan, M.D.,* Mohamed Chaaban, M.D.,† Oussama Farhat, M.D.,‡ Anis Baraka, M.D., F.R.C.A.§

SUBDURAL hematoma is a serious but rare complication of dural puncture. Cases have been reported after spinal anesthesia and also after accidental dural puncture with an epidural needle.^{1,2} The current report shows that spinal anesthesia can also produce subdural rebleeding in a patient with undiagnosed chronic subdural hematoma.

Case Report

The patient was a 69-yr-old man who sustained a mild head trauma after falling down, for which he was admitted to the emergency department. Neurologic examination and cranial computed tomography scan were normal. He was discharged on the same day. However, mild nonspecific headache that did not require any treatment appeared on the 4th day and disappeared on the 7th day. On the 10th day, the patient was scheduled to undergo right inguinal hernia repair. Physical examination was unremarkable, and the patient agreed to undergo spinal anesthesia. With the patient in the sitting position, spinal anesthesia was performed at the L3-L4 interspace with a 25-gauge pencil-point needle, using 12 mg isobaric bupivacaine, which resulted in adequate bilateral T8 sensory block. The patient remained hemodynamically stable throughout the procedure. Postoperatively, the patient experienced after few hours later a mild fronto-occipital headache that was more intense in the sitting position, suggesting a post-dural puncture headache. The headache was treated by analgesics (paracetamol), bed rest, and hydration. However, on the next day, the characteristics of the headache changed to a severe nonpostural headache associated with right hemiplegia. Urgent cranial computed tomography revealed a 2.5-cm-thick acute-on-chronic left subdural hematoma shifting the brain laterally and compressing the ventricles (fig. 1). Immediate surgical evacuation was achieved and showed an acute-on-chronic hematoma. The patient's condition improved rapidly, and he was discharged home 7 days later after uneventful recovery and with full resolution of his symptoms.

Discussion

Spinal anesthesia can be followed by post-dural puncture headache and even cerebral hemorrhage.^{1,2} It is postulated that the hemorrhage is caused by sudden decrease in intracranial pressure consequent to the loss of cerebrospinal fluid at the lumbar puncture site. Sud-

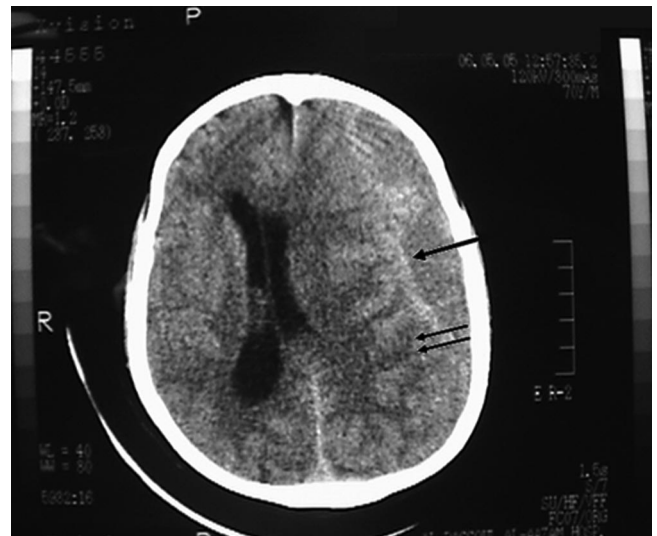


Fig. 1. Cranial computed tomography scan performed 24 h after spinal anesthesia, showing left-sided acute (↑↑)—on—chronic (↑) subdural hematoma shifting the brain laterally to the right side and compressing the ventricles.

den caudal shift of the brain may cause traction on the arachnoid mater, venous structures (bridging veins), or both and may lead to bleeding from ruptured vessels. Intracranial subdural hematoma is rare but could be a lethal complication as evident from the deaths recorded as a complication of lumbar puncture.³⁻⁷ Electron microscopic data on human bridging veins show that the thinnest parts of the bridging veins' walls are in the subdural space and the thickest are in the subarachnoid portion.⁸ This implies that bridging veins are more fragile in the subdural portion than in the subarachnoid space. Traction on the bridging veins may cause a rupture at their weakest point in the subdural space, which results in subdural hematoma. The current report shows that spinal anesthesia which is known to cause subdural hematoma can also produce rebleeding in a patient with undiagnosed subdural hematoma, resulting in acute-on-chronic subdural hematoma. The acute-on-chronic subdural hematoma was diagnosed by the computed tomography scan and confirmed during surgical evacuation of the hematoma. Because our patient had no coagulation disorders and was not receiving any anticoagulants, it is possible that the spinal anesthesia, which resulted in cerebral spinal fluid leakage, cerebrospinal fluid hypovolemia, and subsequent intracranial hypotension, was the most likely cause of the subdural rebleeding and might have produced a dramatic brain herniation syndrome. The brain herniation, rebleeding, or both may precipi-

* Staff Anesthesiologist, Department of Anesthesiology, † Resident in Anesthesiology, ‡ Staff Neurosurgeon, Department of Neurosurgery, Sahel General Hospital, § Professor and Chairman, Department of Anesthesiology, American University of Beirut, Medical Center, Beirut, Lebanon.

Received from the Department of Anesthesiology, Sahel General Hospital, Beirut, Lebanon. Submitted for publication September 29, 2005. Accepted for publication November 10, 2005. Support was provided solely from institutional and/or departmental sources.

Address correspondence to Dr. Zeidan: Department of Anesthesiology, Sahel General Hospital, Airport Avenue, P. O. Box 99/25-Ghobeiry, Beirut, Lebanon. doczeidan@hotmail.com. Individual article reprints may be purchased through the Journal Web site, www.anesthesiology.org.

tate severe neurologic deterioration, which may be transient or persistent.⁹

In summary, the current report shows that spinal anesthesia in a patient with subdural hematoma may produce subdural rebleeding, resulting in brain herniation syndrome and subsequent neurologic deterioration.

References

1. Macon ME, Armstrong L, Brown EM: Subdural hematoma following spinal anesthesia. *ANESTHESIOLOGY* 1990; 72:380-1
2. Kayacan N, Arici G, Karsli B, Erman M: Acute subdural haematoma after accidental dural puncture during epidural anaesthesia. *Int J Obstet Anesth* 2004; 13:47-9
3. Newrick P, Read D: Subdural haematoma as a complication of spinal anaesthetic. *BMJ* 1982; 285:341-2
4. Welch K: Subdural hematoma following spinal anesthesia. *AMA Arch Surg* 1959; 79:49-1
5. Beal JL, Royer JM, Freysz M, Poli L, Wilkening M: Acute intracranial subdural hematoma of arterial origin after spinal anesthesia. *Ann Fr Anesth Reanim* 1989; 8:143-5
6. Cantais E, Behnamou D, Petit D, Palmier B: Acute subdural hematoma following spinal anesthesia with a very small spinal needle. *ANESTHESIOLOGY* 2000; 93:1354-6
7. Deglaire B, Duverger P, Muckensturm B, Maissin F, Desbordes JM: Acute intracranial subdural hematoma after accidental dural puncture in epidural anesthesia. *Ann Fr Anesth Reanim* 1988; 7:156-8
8. Yamashima T, Friede RL: Why do bridging veins rupture into the virtual subdural space? *J Neurol Neurosurg Psychiatry* 1984; 47:121-7
9. Samadani U, Huang JH, Baranov D, Zager EL, Grady MS: Intracranial hypotension after intraoperative lumbar cerebrospinal fluid drainage. *Neurosurgery* 2003; 52:148-51