

# Interscalene Brachial Plexus Block: Can the Risk of Entering the Spinal Canal Be Reduced?

## A Study of Needle Angles in Volunteers Undergoing Magnetic Resonance Imaging

Anand M. Sardesai, F.R.C.A.,\* Roger Patel, F.R.C.R.,† Nicholas M. Denny, F.R.C.A.,‡ David K. Menon, F.R.C.A.,§ Adrian K. Dixon, F.R.C.R.,|| Martin J. Herrick, F.R.C.A.,\* Alan W. Harrop-Griffiths, F.R.C.A.#

**Background:** Spinal cord damage during interscalene brachial plexus block has been attributed to needle entry into the spinal canal. The purpose of this study was to identify the angles and depths of needle insertion that increase the likelihood of such an event, using the traditional classic interscalene approach and two more proximal entry points.

**Method:** Magnetic resonance images of the neck from 10 healthy volunteers were used to obtain the three-dimensional spatial coordinates of three skin markers and the right-sided cervical nerves at the exiting neural foramina. The distance of the intervertebral foramina from the skin markers and the angles of the needle vector and the foramina were calculated.

**Results:** The distance from the skin to the intervertebral foramen may be as short as 2.5 cm with the classic approach. A caudal angulation greater than 50° seemed to eliminate the risk of needle entry through the foramen.

**Conclusion:** With the classic approach to the interscalene block, there is a greater possibility of the needle passing through the intervertebral foramen if the needle is advanced too deeply. More proximal entry points and techniques that use a more steeply angled needle may reduce the risk of entry into the spinal space.

IN 1970, Alon Winnie described the classic interscalene brachial plexus block (ISBPB).<sup>1</sup> In this technique, a needle is passed into the groove between the anterior and middle scalene muscles (the interscalene groove) at the level of the cricoid cartilage. Winnie advocated that the direction of the needle be “perpendicular to the skin in every plane,” and that it should therefore be pointing in

a direction that is mostly medial but slightly posterior and slightly caudad.<sup>2</sup> There are a number of case reports in the literature that document accidental spinal and epidural anesthesia as complications of attempted interscalene block.<sup>3-11</sup> These complications have been attributed either to the direct entry of the needle into the subarachnoid or epidural space or, alternatively, to the central passage of local anesthetic from a needle that has punctured a dural cuff surrounding a target nerve. Recently, there have been reports of spinal cord damage after attempted ISBPB.<sup>12</sup> Magnetic resonance imaging (MRI) in these patients has demonstrated syrinxes in the substance of the cord that are thought to have resulted from needle entry through the intervertebral foramen and direct injection of local anesthetic into the cord. This complication has potentially devastating consequences for the patient and detracts from an otherwise safe and useful technique.

Two modified approaches to the interscalene brachial plexus have recently been described.<sup>13,14</sup> Although the two techniques differ in their skin entry points, both approaches advocate directing the needle such that it is more markedly caudad than the direction originally described for the classic approach. The proponents of both new approaches have claimed that the advantages of their technique include ease of location of the plexus, ease of catheter insertion, and increased safety. The angle of approach necessary to block the brachial plexus has already been studied using MRI<sup>15</sup> and corresponds to a mean angle to the sagittal plane of 61.1° (SD, 6.1°; range, 50°-78°). However, this study investigated the angle necessary to achieve the best approach to the plexus; it made no attempt to determine the approach angle that could lead the needle to pass through the intervertebral foramen into the neuraxis.

There exists a possibility that the needle angle originally described by classic interscalene might perfectly align the skin entry point of the needle with the intervertebral foramen, and neuraxial complications may therefore relate in part to the described technique itself rather than to incorrect application of the technique. The purpose of our study was to identify the angles and depths of needle insertion that would increase the likelihood of the entry of the needle into the intervertebral foramen. We studied three approaches to the inter-

This article is accompanied by an Editorial View. Please see: Borgeat A: All roads do not lead to Rome. ANESTHESIOLOGY 2006; 105:1-2.

\* Consultant Anesthesiologist, Department of Anesthesia, Addenbrooke's Hospital. † Clinical Fellow, Department of Radiology, Papworth Hospital, Cambridge, United Kingdom. ‡ Consultant Anesthesiologist, Department of Anesthesia, King's Lynn, United Kingdom. § Professor of Anesthesia, University Department of Anesthesia, Cambridge, United Kingdom. || Professor of Radiology, Department of Radiology, University of Cambridge, Cambridge, United Kingdom. # Consultant Anesthesiologist, Department of Anesthesia, St. Mary's Hospital, London, United Kingdom.

Received from the Department of Anesthesiology, Addenbrooke's Hospital, Cambridge, United Kingdom. Submitted for publication July 4, 2005. Accepted for publication March 7, 2006. Supported by the Anglia Society of Regional Anesthesia, Cambridge, United Kingdom.

Address correspondence to Dr. Sardesai: Department of Anaesthetics, Box No. 93, Addenbrooke's Hospital, Cambridge CB2 2QQ, United Kingdom. sardesai1@aol.com. Individual article reprints may be purchased through the Journal Web site, www.anesthesiology.org.

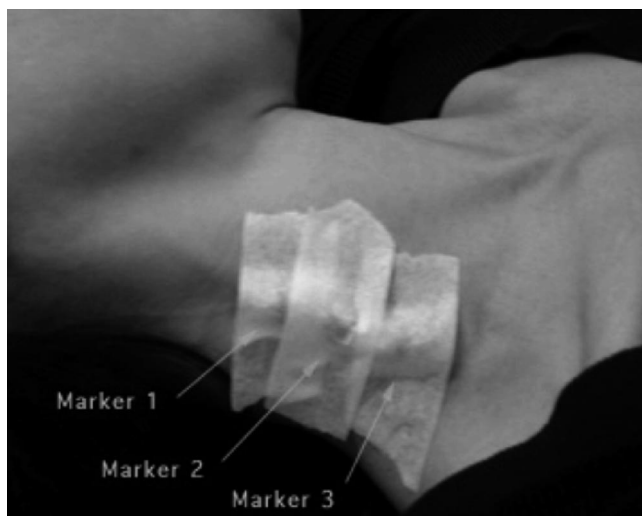


Fig. 1. Position of a volunteer in the MRI scanner showing the cod liver capsules placed on the neck as markers. Marker 1 = high approach; marker 2 = middle approach; marker 3 = classic interscalene approach.

scalene brachial plexus and calculated the distances and angles from skin entry points to the intervertebral foramen.

## Materials and Methods

After local research ethics committee approval (Addenbrooke's Hospital, Cambridge, United Kingdom) and written, informed consent, 10 volunteers underwent MRI of the neck. There were 6 male and 4 female volunteers. The median age was 46 yr (range, 33–57 yr). They were positioned in the MRI scanner so as to simulate the standard position for performing an ISBPB, *i.e.*, with the neck in the neutral position and the head turned slightly away from the side of the block. Cod liver oil capsules were used as external markers. An anesthesiologist with substantial experience in the performance of ISBPBs placed cod liver oil capsules on the interscalene groove on the right-hand side at three levels (fig. 1). These represented the entry points for interscalene approaches to the brachial plexus that have been cited previously<sup>13,14</sup> and one additional entry point:

Marker 1 (high approach): at the level of the superior thyroid notch<sup>13</sup>

Marker 2 (middle approach): midway between mastoid process and clavicle<sup>14</sup>

Marker 3 (classic interscalene approach): at the level of the cricoid cartilage

Volunteers were studied in a 1.5-T MRI machine (LX2 EchoSpeed; General Electric Medical Systems, Milwaukee, WI). After initial localizing images, a three-dimensional data acquisition was made using a gradient echo sequence of the steady state precession type (FIESTA 3D; GE Medical Systems). The field of view was wide

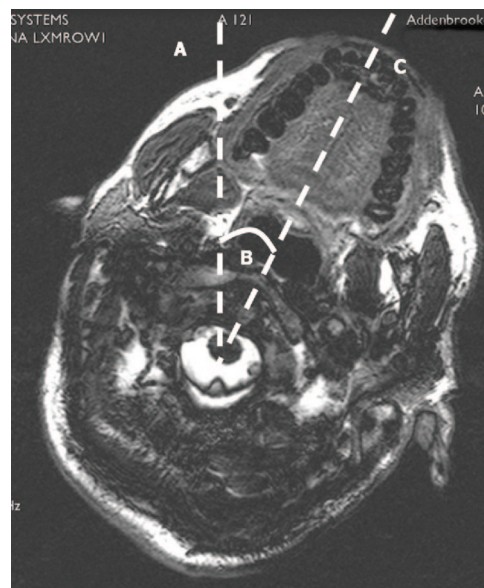

Fig. 2. Measurement of the sagittal plane and the turn angle (At the level of first cervical vertebra). The patient's sagittal plane was taken to be a straight line (A) drawn between the center of the vertebral body and was perpendicular to the surface on which the patient was lying. The turn angle is the angle (B) between this line and a line (C) drawn passing through the midline of the palate and the center of the body of cervical vertebra.

enough to include the full width and anteroposterior distance of the neck, and the area of interest was imaged from above the first cervical (C1) vertebral body down to the thoracic inlet. The benefits of the MRI sequence used include high spatial resolution and high contrast between nerves and cerebrospinal fluid. This three-dimensional sequence was also quick (approximately 15 min). The main disadvantages were relatively low signal-to-noise ratio, suboptimal differentiation of muscle from nerve, and some degradation from artifacts. None of these disadvantages compromised our ability to make the measurements required. Measurements were done by one of the investigators (R.P.). Data were analyzed using a multiplanar reformat on a workstation (Advantage Windows; GE Medical Systems).

The following data were derived from measurements made on the MRI scans:

- The *length of the neck* was measured from the superior surface of the odontoid process of the axis (C2) to the anteroinferior margin of C7.
- The *width of the neck* was measured at the anteroinferior margin of C4 in the coronal plane.
- The *sagittal plane* of the neck was taken to be a line that passed through the center of the body of cervical vertebra and was perpendicular to the surface on which the patient was lying (fig. 2).
- The *turn angle* was the angle by which the volunteer's head was turned to simulate the standard position for the performance of the block. A line was drawn pass-

ing through the midline of the palate and the center of the body of cervical vertebra. The angle that this line made with the sagittal plane was measured as the turn angle (fig. 2).

- The *intervertebral foramen angle* was measured as the angle between the *sagittal plane* and a line drawn from the center of the spinal cord to the intervertebral foramen (fig. 3).
- The *foramen depth* was measured as the distance between the skin below a skin marker and the intervertebral foramen.

Magnetic resonance images were used to obtain the three-dimensional spatial coordinates of the three skin markers and the right-sided nerves at the exiting neural foramina of the vertebral bodies of C4, C5, C6, C7, and T1. Using the three-dimensional spatial coordinates, we plotted vectors joining the external markers to the nerve foramina (*approach vectors*). We also separately plotted the vectors (*exit vectors*) corresponding to the course of the exiting nerves in the foramina, assuming that, at least initially, the exiting nerve and neural foramen share the same vector. The angles between the approach vectors and the exit vectors (called *discrepancy angles* for the purpose of this article) were calculated (fig. 4).

All statistical analysis was conducted using Statview (Abacus Inc, Cary, IN). Discrepancy angles with the different techniques were compared at each level using a factorial analysis of variance. The Scheffé test (with

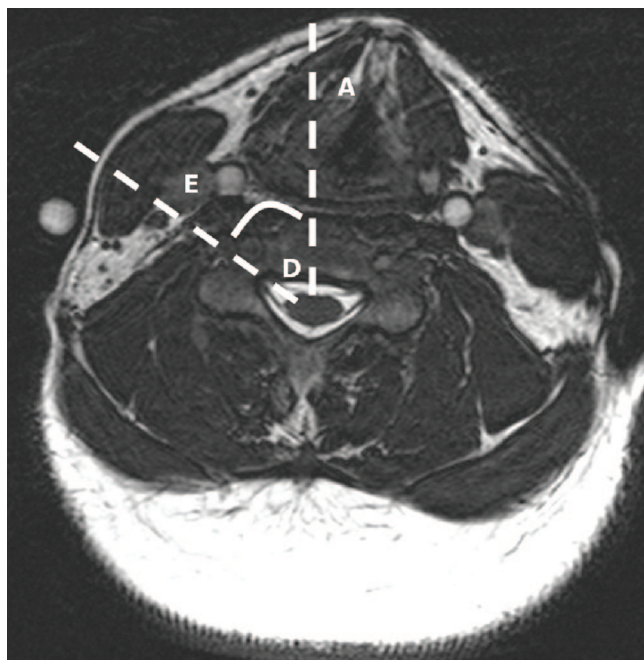


Fig. 3. Measurement of the intervertebral foramen angle at the level of the fifth cervical vertebra (*angle D*): Measurement of the intervertebral foramen angle (*angle D*), which was taken to be the angle between the line drawn between the center of the spinal cord and the intervertebral foramen (*line E*) and the patient's sagittal plane (*line A*).

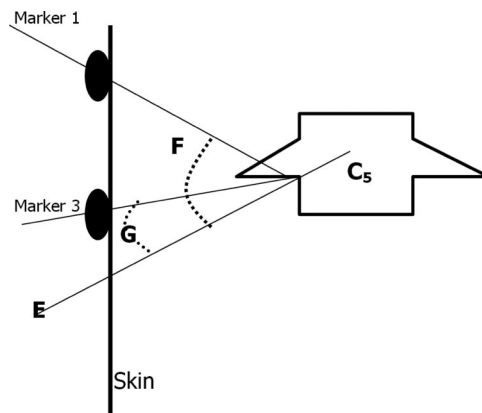


Fig. 4. Schematic two-dimensional representation of the calculation of the discrepancy angle. The angle between the exit vector (*E*) and the approach vector passing between the skin marker and the intervertebral foramen is termed the *discrepancy angle*. In this illustration, the discrepancy angle for a higher approach through marker 1 (*angle F*) is larger than that for a lower entry point (*angle G*). For definitions of vectors, see text.

Bonferroni corrections) was used for *post hoc* comparisons.

The caudal angulation (fig. 5) necessary for a needle with an entry point at marker 3 (classic interscalene approach) to access the intervertebral foramens of C6 and C7 was measured for each volunteer.

**Results**

Six male and four female volunteers were studied. The median (range) width of the neck was 11.4 (9.6-12.7) cm. The median (range) length of the neck was 11.6 (10.3-12.6) cm. The median (range) turn angle was 30.5° (20.7°-37.1°). This rotation was distributed non-uniformly across the cervical vertebrae. The median (range) turn angle at C1 was 29.9° (20.7°-37.1°), whereas at C5 and C6 it was 6.38° (3.1°-11.9°) and 5.5° (2.7°-9.8°), respectively. The intervertebral foramen angles, foramen depths, and discrepancy angles were also calculated (table 1).

The discrepancy angles for the classic interscalene approach (marker 3) were significantly lower than those for the middle approach (marker 2) for C6 and C7

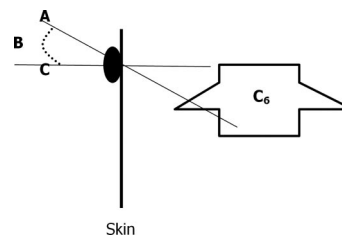


Fig. 5. Schematic two-dimensional representation of the calculation of the caudal angulation. The angle between the direction of the needle (*A*) at skin entry point and the line perpendicular to the skin in coronal plane (*C*) is termed the *caudal angulation (B)*.

Downloaded from http://aas2.silverchair.com/anesthesiology/article-pdf/105/1/9/382475/0000542-200607000-00006.pdf by guest on 24 January 2022



**Table 1. Median (Range) Intervertebral Foramen Angles, Foramen Depths, and Discrepancy Angles for the Three Approaches Assessed**

Cervical Vertebra	Intervertebral Foramen Angle, °	Marker	Foramen Depth, cm	Discrepancy Angle, °
C4	45.7 (42.0–56.9)	1	3.24 (2.8–3.77)	44.1 (24.8–69.9)
		2	3.54 (2.8–4.21)	49.9 (35.4–74.4)
		3	4.31 (3.76–5.65)	58.5 (37.1–77.6)
C5	48.8 (33.0–62.9)	1	3.29 (2.85–4.14)	40.4 (21.2–69.4)
		2	3.30 (2.91–4.14)	35.8 (12.0–70.3)
		3	3.68 (3.2–4.83)	41.9 (23.6–71.1)
C6	50.4 (40.0–65.4)	1	4.26 (3.4–5.55)	49.9 (33.3–71.4)
		2	3.91 (3.31–5.26)	40.2 (24.6–70.3)
		3	3.67 (2.51–5.95)	29.6 (18.6–66.0)
C7	50.4 (41.1–59.3)	1	5.52 (4.6–6.77)	57.2 (46.6–71.7)
		2	4.57 (4.11–6.9)	49.5 (34.1–70.0)
		3	3.84 (3.1–4.75)	35.9 (21.1–62.8)
T1	53.9 (41.6–65.5)	1	7.06 (5.7–9.04)	60.5 (53.2–70.9)
		2	6.29 (5.37–8.97)	54.6 (43.7–69.1)
		3	5.04 (3.8–6.91)	44.4 (33.3–62.0)

Median (range) intervertebral foramen angles, foramen depths, and discrepancy angles for the three approaches assessed. Definitions of angles and depths are given in the text. The discrepancy angles for the classic interscalene approach (marker 3) were significantly lower than those for the middle approach (marker 2) for C6 and C7 vertebrae ( $P < 0.01$ ) and for the T1 vertebra ( $P < 0.05$ ).

vertebrae ( $P < 0.01$ ) and for the T1 vertebra ( $P < 0.05$ ). The discrepancy angles for the Winnie approach (marker 3) were significantly lower than those for the high approach (marker 1) for C6, C7, and T1 vertebrae ( $P < 0.01$ ).

The median (range) caudal angulation necessary for a needle inserted at marker 3 (classic interscalene approach) to access the intervertebral foramen of C6 was  $6.8^\circ$  ( $-9.9^\circ$  to  $26.8^\circ$ ). The median (range) caudal angulation for the same needle (classic interscalene approach) to access the intervertebral foramen of C7 was  $28.8^\circ$  ( $15.9^\circ$ – $46.9^\circ$ ).

Because as concise a field of view as possible was obtained (to increase the spatial resolution of the magnetic resonance image), a limited image was obtained. The pleural margin was at the periphery of this field of view, where signal return was poor. Therefore, we cannot provide accurate data about this aspect.

## Discussion

In theory, for a needle to gain access through the intervertebral foramen into the neuraxis during an ISBPB, it must be sufficiently long, it must be directed toward the foramen, and its approach angle should approximate to the exit angle of the foramen. The question posed by this study is as follows: Does the classic interscalene block technique for ISBPB pose the greatest risk of needle passage into the neuraxis in terms of all the three above requirements?

The first consideration is needle length and the depth from the skin of the intervertebral foramen. Given that the C6 root is the accepted target of an ISBPB, the important data in this respect are the distances between the three markers and the C6 intervertebral foramen.

The classic interscalene approach marker (marker 3) left the skin at a median (range) distance from the intervertebral foramen of 3.7 (2.5–5.9) cm. This implies that if a 5-cm needle is used, the intervertebral foramina of the majority of patients could be reached using the classic interscalene approach. A 2.5-cm needle has been recommended in the literature.<sup>16</sup> If a 2.5-cm needle were used, it would still be possible in some patients to insert the needle into the intervertebral foramen, especially if the skin were indented by the anesthesiologist's finger resting, for example, on the interscalene groove. The distance data for marker 1 and marker 2 are 4.3 (3.4–5.6) and 3.9 (3.3–5.3) cm, respectively. These data suggest, but do not conclusively prove, that it would be difficult to gain access to the intervertebral foramen with a 2.5-cm using these approaches in some patients, although a 5-cm needle would be able to reach the foramen in the majority of patients. However, when using higher approaches, it is possible that the distance between the skin and the upper root of the brachial plexus may be more than 2.5 cm, thereby mandating the use of a 5-cm needle.

The second consideration is whether the needle is directed toward the intervertebral foramina in traditional ISBPB approaches. Winnie's original description of the needle angle was vague: mostly medial but slightly posterior and slightly caudad.<sup>2</sup> Our data suggest that the median (range) caudal angle that would allow needle access to the intervertebral foramen of the C6 vertebra is  $6.8^\circ$  ( $-9.9^\circ$  to  $26.8^\circ$ ), *i.e.*, slightly caudad for the majority of patients. However, a needle angulation of greater than  $30^\circ$  would seem to ensure that the needle will pass below the C6 foramen. However, the cricoid landmark is not a reliable guide to vertebral level and may lie anywhere between the C5 and C7 levels.<sup>17</sup> The caudal angle

necessary to gain access to the C7 intervertebral foramen from the classic interscalene entry point (marker 3) was  $28.8^\circ$  ( $15.9^\circ$ – $46.9^\circ$ ), which suggests that a caudal angle greater than  $50^\circ$  would ensure that the needle passes below the C7 foramen.

The third consideration is whether the needle approach angle, *i.e.*, the vector of the needle during its insertion, is in alignment with the exit angle, *i.e.*, the vector at which the nerves are exiting from the intervertebral foramen. It is likely that the smaller this angle is, and therefore the greater the degree of alignment is, the greater the chance is that the needle can pass into the foramen. Again, taking the C6 vertebra and the three approaches determined by the three markers, the greatest degree of alignment, *i.e.*, the smallest discrepancy angle, is seen with the classic interscalene approach (marker 3). The median (range) discrepancy angle for the classic interscalene approach to the C6 vertebra is  $29.6^\circ$  ( $18.6^\circ$ – $66.0^\circ$ ), the smallest discrepancy angle for the three approaches to any of the five cervical vertebrae studied.

There is a question of whether the extent to which the neck is turned before insertion of the needle affects the needle entry angles relative to the spine. Our data suggest that when a healthy patient's neck is turned in preparation for an ISBPB, there is little rotation (turn angle) at the vertebrae in the "target area" for the block, and hence this factor is unlikely to affect the needle angles.

Our results seem to be supported by a study performed by Wong *et al.*,<sup>15</sup> who calculated the ideal needle angle to access the upper roots of the brachial plexus with a traditional ISBPB entry point at the C6 vertebral level. Using magnetic resonance images, they calculated that the median (range) ideal angle relative to the sagittal plane was  $61.1^\circ$  ( $50^\circ$ – $78^\circ$ ). Two points arise from the article of Wong *et al.* First, this angle is similar to the C6 intervertebral foramen angle that we measured ( $50.4^\circ$  [ $40.0^\circ$ – $65.4^\circ$ ]). Second, the illustration in the article of Wong *et al.* of the "ideal" angle shows the needle path passing through the spinal cord.

The introduction to this article posed the question of whether the traditional classic interscalene approach for ISBPB aligned the needle path necessary to reach the upper roots of the brachial plexus with the path that would allow passage of the needle through the intervertebral foramen and into the spinal canal. The answer to this question that emerges from our data, albeit from a small study, is that the alignment is not perfect and that a competently performed classic interscalene ISBPB with a short (2.5 cm) needle should not pose a threat to a patient's neuraxis. However, of the three needle approaches studied, represented by the three markers, the

classic interscalene approach (marker 3) creates the greatest degree of alignment.

Does this conclusion mean that the classic interscalene approach is unsafe and should be abandoned in favor of more proximal entry points? The answer is not simple. The classic interscalene approach has been used for many years and seems to be safe in the hands of an experienced, competent practitioner. Currently, there are no clinical data to suggest that it is more unsafe than the proximal approaches. However, not all practitioners are experienced and competent, and we think that our data adds support to the view that a more proximal ISBPB approach with a markedly caudad needle angle offers the patient a greater degree of protection against entry into the spinal cord from regional anesthetic practice that falls short of ideal. Whether a higher approach needing a direction of needle more parallel to the cervical spine can increase the risk of other complications such as pneumothorax remains unanswered with this study.

The authors thank all of the radiographers in the MRI Unit at Addenbrooke's Hospital, Cambridge, United Kingdom, without whom this study would not have been possible.

## References

1. Winnie AP: Interscalene brachial plexus block. *Anesth Analg* 1970; 49: 455-66
2. Winnie AP: Plexus Anesthesia. Vol 1. Fribourg, Switzerland, Mediglobe SA, 1990, p 174
3. Dutton R, Eckhardt W, Sunder N: Total spinal Anesthesia after block of the brachial plexus. *ANESTHESIOLOGY* 1994; 80:939-41
4. Ross S, Scarborough C: Total spinal anesthesia following interscalene block. *ANESTHESIOLOGY* 1973; 39:458
5. Tetzlaff JE, Yoon HJ, Dilger J, Brems J: Subdural anesthesia as a complication of an interscalene brachial plexus block. Case report. *Reg Anesth* 1994; 19:357-9
6. Norris D, Klahsen A, Milne B: Delayed bilateral spinal anesthesia following interscalene brachial plexus block. *Can J Anaesth* 1996; 43:303-5
7. McGlade DP: Extensive central neural blockade following interscalene brachial plexus blockade. *Anaesth Intensive Care* 1992; 20:514-6
8. Gregoretti S: Case of high spinal anesthesia as a complication of an interscalene brachial plexus block. *Minerva Anestesiol* 1980; 46:437-9
9. Durrani Z, Winnie AP: Brainstem toxicity with reversible locked-in syndrome after intrascapular brachial plexus block. *Anesth Analg* 1991; 72:249-52
10. Kumar A, Battit GE, Froese AB, Long MC: Bilateral cervical and epidural blockade complicating interscalene brachial plexus block: a report of two cases. *ANESTHESIOLOGY* 1971; 35:650-2
11. Scammell SJ: Case report: Inadvertent epidural anesthesia as a complication of interscalene brachial plexus block. *Anaesth Intensive Care* 1979; 7:56-7
12. Benumof JL: Permanent loss of cervical spinal cord function associated with interscalene block performed under general anesthesia. *ANESTHESIOLOGY* 2000; 93:1541-4
13. Meier G, Bauereis C, Heinrich C: Interscalene brachial plexus catheter for anesthesia and postoperative pain therapy: Experience with a modified technique. *Anaesthesist* 1997; 46:715-9
14. Boezaart AP, de Beer JF, du Toit C, van Rooyen K: A new technique of continuous interscalene nerve block. *Can J Anaesth* 1999; 46:275-81
15. Wong GY, Brown DL, Miller GM, Cahill DR: Defining the cross-sectional anatomy important to interscalene brachial plexus block with MRI. *Reg Anesth Pain Med* 1998; 23:77-80
16. Chelly JE, Greger J, Gebhard R, Casati A: How to prevent catastrophic complications when performing interscalene blocks (letter). *ANESTHESIOLOGY* 2001; 95:1302
17. Smith KJ, Dobranowski J, Yip G, Dauphin A, Choi PT: Cricoid pressure displaces the esophagus: An observational study using magnetic resonance imaging. *ANESTHESIOLOGY* 2003; 99:60-4