

## Role of Presynaptic Acetylcholine Autoreceptors at Motor Nerve Endings on Tetanic and Train-of-four Fade Seen during a Nondepolarizing Neuromuscular Block

*To the Editor:*—We read with interest article by Jonsson *et al.*<sup>1</sup> suggesting that nondepolarizing neuromuscular blocking agents concentration-dependently inhibit human neuronal acetylcholine autoreceptors (nAChRs). The authors argue that the inhibition of the presynaptic  $\alpha_3\beta_2$  nAChR subtype plays an important role in tetanic and train-of-four fade seen during nondepolarizing neuromuscular blockade.<sup>1</sup> However, there is evidence from previous studies that are not consistent with this explanation. For example,  $\alpha$ -conotoxin MII, a highly selective antagonist for  $\alpha_3\beta_2$ -containing nAChRs, does not result in tetanic fade, although acetylcholine release was decreased. This may be related to the high safety margin of neuromuscular transmission. If the fluid bathing the synapse is changed to one with a high concentration of magnesium, which reduces the release of acetylcholine,  $\alpha$ -conotoxin MII significantly decreases the tetanic ratio.<sup>2</sup> These results suggested that, only under conditions of decreased safety margin, blockade of presynaptic  $\alpha_3\beta_2$  nAChRs could induce tetanic and train-of-four fade.

Nondepolarizing neuromuscular blocking agents might influence synaptic safety margins in two ways. First, most nondepolarizing neuromuscular blocking agents used currently are nonselective antagonists for both presynaptic and postsynaptic nAChRs, and postsynaptic nAChRs are clearly one of the most important factors involved in transmission safety. Second, recent studies have found that release of acetylcholine was mediated by some metabotropic receptors, which coexisted with nicotinic receptors at nerve endings. For example, purinergic P2Y,<sup>3</sup> adenosine A<sub>1</sub>,<sup>4</sup> and muscarinic M<sub>1</sub> receptors<sup>5</sup> were related to inhibition of acetylcholine release at rat neuromuscular junction. At least up to now, we cannot exclude the possibility that

nondepolarizing neuromuscular blocking agents would impact acetylcholine release through these receptors.

In summary, we think that during nondepolarizing neuromuscular blockade, tetanic and train-of-four fade cannot be explained simply by blockade of presynaptic  $\alpha_3\beta_2$  nAChRs; other unknown factors may be involved.

**Zhijun Lu, M.D.,\* Buwei Yu, M.D.** \*Rui Jin Hospital, Shanghai Jiao Tong University School of Medicine, Shanghai, China. lusamacn@sjtu.edu.cn

### References

1. Jonsson M, Gurley D, Dabrowski M, Larsson O, Johnson EC, Eriksson LI: Distinct pharmacologic properties of neuromuscular blocking agents on human neuronal nicotinic acetylcholine receptors. *ANESTHESIOLOGY* 2006; 105:521–33
2. Faria M, Oliveira L, Timóteo MA, Lobo MG, Correia-De-Se P: Blockade of neuronal facilitatory nicotinic receptors containing subunits contribute to tetanic fade in the rat isolated diaphragm. *Synapse* 2003; 49:77–88
3. Lorenzo SD, Veggetti M, Muchnik S, Losavio A: Presynaptic inhibition of spontaneous acetylcholine release mediated by P2Y receptors at the mouse neuromuscular junction. *Neuroscience* 2006; 142:71–85
4. Lorenzo SD, Veggetti M, Muchnik S, Losavio A: Presynaptic inhibition of spontaneous acetylcholine release induced by adenosine at mouse neuromuscular junction. *Br J Pharmacol* 2004; 142:113–24
5. Santafé MM, Salon I, Garcia N, Lanuza MA, Uchitel OD, Tomàs J: Modulation of ACh release by presynaptic muscarinic autoreceptors in the neuromuscular junction of the newborn and adult rat. *Eur J Neurosci* 2003; 17:119–27

(Accepted for publication January 31, 2007.)

*In Reply:*—We thank Drs. Lu and Yu for their comments on our article<sup>1</sup> and for bringing up an important discussion about the impact of different transmitter systems in the neuromuscular junction. Although the neuromuscular junction has been extensively studied, the interplay between cholinergic and purinergic transmitters is not fully understood.

In our article, we demonstrate that nondepolarizing neuromuscular blocking agents inhibit human neuronal nicotinic acetylcholine receptors (nAChRs), including the  $\alpha_3\beta_2$  subtype, expressed in *Xenopus* oocytes.<sup>1</sup> Notably, there has for a long time been physiologic and pharmacologic evidence for presynaptic nAChRs at the motor nerve ending in the neuromuscular junction; however, the exact nature of these nicotinic receptors has not been known (for reviews, see Bowman *et al.*<sup>2</sup> and Vizi and Lendvai<sup>3</sup>). Immunohistochemical analysis has demonstrated presence of the  $\alpha_3$  nAChR subunit at the presynaptic motor nerve ending.<sup>4</sup> Recently, it was demonstrated that a selective block of the  $\alpha_3\beta_2$  nAChR in an *in vitro* nerve-muscle preparation reduced the presynaptic acetylcholine release, and furthermore caused tetanic fade after a magnesium-induced reduction of the safety factor of synaptic transmission.<sup>5</sup> Moreover, nicotinic inhibitors with a mixed antagonist profile (*i.e.*, both  $\alpha_3\beta_2$  and  $\alpha_1\beta_1\delta\epsilon$  antagonists) both inhibited acetylcholine release and caused tetanic fade.<sup>5</sup> Altogether, a selective inhibition of the  $\alpha_3\beta_2$  nAChR reduces the presynaptic acetylcholine release, thus working as an autoreceptor, and during conditions of

reduced safety factor in the neuromuscular junction, produced a tetanic fade.<sup>5</sup> Based on this and our recent findings,<sup>1</sup> an inhibition of the presynaptic  $\alpha_3\beta_2$  nAChR is a possible molecular explanation for the mechanism behind tetanic and train-of-four fade because the safety factor indeed is reduced during a nondepolarizing neuromuscular blockade.

As we point out in our article,<sup>1</sup> there is evidence that adenosine and adenosine triphosphate, acting *via* purinergic receptors, also play an important role in the modulation of acetylcholine release and tetanic fade.<sup>6</sup> In addition, muscarinic M1 and M2 receptors are present in the neuromuscular junction and are involved in the modulation of acetylcholine release, but do not seem to be key players in the mechanism(s) behind tetanic fade.<sup>2,3</sup>

In conclusion, inhibition of presynaptic  $\alpha_3\beta_2$  nAChRs inhibits acetylcholine release and causes tetanic fade and most likely train-of-four fade.<sup>1–5</sup> We do agree with Drs. Lu and Yu that purinergic and/or muscarinic receptors are important players in the synaptic transmission in the neuromuscular junction, but to what extent clinically used neuromuscular blocking agents interact with these receptor systems remains to be evaluated.

**Malin Jonsson, M.D., Ph.D.,\* Lars I. Eriksson, M.D., Ph.D.** \*Karolinska University Hospital and Karolinska Institutet, Stockholm, Sweden. malin.jonsson@karolinska.se

## References

1. Jonsson M, Gurley DA, Dabrowski M, Larsson O, Johnson EC, Eriksson LI: Distinct pharmacological properties of neuromuscular blocking agents on human neuronal nicotinic acetylcholine receptors: A possible mechanism behind the train-of-four fade. *ANESTHESIOLOGY* 2006; 105:521-33
2. Bowman WC, Marshall IG, Gibb AJ, Harborne AJ: Feedback control of transmitter release at the neuromuscular junction. *Trends Pharmacol Sci* 1988; 9:16-20
3. Vizi ES, Lendvai B: Side effects of nondepolarizing muscle relaxants: Relationship to their antinicotinic and antimuscarinic actions. *Pharmacol Ther* 1997; 73:75-89

4. Tsuneki H, Kimura I, Dezaki K, Kimura M, Sala C, Fumagalli G: Immunohistochemical localization of neuronal nicotinic receptor subtypes at the pre- and postjunctional sites in mouse diaphragm muscle. *Neurosci Lett* 1995; 196:13-6
5. Faria M, Oliveira L, Timoteo MA, Lobo MG, Correia-De-Sa P: Blockade of neuronal facilitatory nicotinic receptors containing alpha 3 beta 2 subunits contribute to tetanic fade in the rat isolated diaphragm. *Synapse* 2003; 49:77-88
6. Henning RH: Purinoreceptors in the neuromuscular transmission. *Pharmacol Ther* 1997; 74:115-28

(Accepted for publication January 31, 2007.)

Anesthesiology 2007; 106:1244

Copyright © 2007, the American Society of Anesthesiologists, Inc. Lippincott Williams & Wilkins, Inc.

## Ultrasound Detects Intraneural Injection

*To the Editor:*—We read with interest the recent article by Paul Bigeleisen titled “Nerve Puncture and Apparent Intraneural Injection during Ultrasound-guided Axillary Block Do Not Invariably Result in Neurologic Injury.”<sup>1</sup> The author is to be commended for this small study, which supports the ability of ultrasound to detect intraneural injection during peripheral nerve blockade. Bigeleisen’s experience with ultrasound and low-volume intraneural injection complements our own in both the laboratory and clinical settings. In our recently completed study of ultrasound-detected intraneural injection, we inserted blunt-tipped insulated 22-gauge needles (Stimuplex®; B. Braun, Bethlehem, PA) directly into axillary brachial plexus nerves of anesthetized pigs and then injected dye-stained dextrose under ultrasound imaging.<sup>2,3</sup> After injecting 4 ml dye-stained dextrose, we visualized a 57% (median) increase in nerve diameter using real-time ultrasound imaging. We then harvested the injected nerves for histologic examination and found that dye had penetrated the epineurium in all 24 cases where nerve expansion was visualized on ultrasound. The dye had penetrated the perineurium in 2 of these cases, and none of the cases demonstrated fascicular dysplasia. Much like Bigeleisen, we concluded that ultrasound is a useful technique to detect intraneural injection. Unlike Bigeleisen, we know for certain that our needle was indeed intraneural at the time of nerve expansion on ultrasound. Subsequent to definitively characterizing the sonographic appearance of intraneural injection (pig study completed August 2005), we have performed more than 411 ultrasound-guided axillary brachial plexus blocks to date and have identified 12 patients in whom we accidentally performed one or more probable intraneural injections using a 50:50 mixture of 2% lidocaine:0.5% bupivacaine with 0.005 mg/ml epinephrine. We stopped the injection immediately after recognizing the pattern of nerve expansion, which was usually visible after injecting 1-3 ml local anesthetic. Bigeleisen reported that intraneural injection elicited paresthesiae or dysesthesiae with gross variability. By stark contrast, none of our 12 patients reported pain or dysesthesiae at the time of intraneural injection. We contacted each of these 12 patients on postoperative days 1 and 7 to find that none had any reports of pain, paresthesiae, dysesthesiae, or weakness associated with their recent axillary nerve block.

Our needle choice differs from that of Bigeleisen and may at least partially explain why we failed to demonstrate significant perineural penetration in our laboratory or elicit pain or dysesthesiae in our block room. We use a blunt-tipped insulated needle, whereas the needle used in Bigeleisen’s study was a sharp hypodermic B-bevel needle, which, as Bigeleisen suggests, may conceivably confer a greater risk of perineural puncture, intrafascicular injection, and consequent nerve damage.<sup>4</sup> Our clinical experience using a blunt-

tipped needle is that the nerve floats away from the needle tip upon routine ultrasound-guided injection of local anesthetic. This seemingly protective phenomenon may be a function of needle choice, in addition to tissue displacement. Another reason why ultrasound-detected intraneural injection may not always result in nerve damage is because injectate tends to leak out of the nerve during injection. In our pig study, we directly observed dye-stained injectate leak out of the nerve along the needle tract after injecting as little as 1 ml.<sup>5</sup>

In summary, we agree with Bigeleisen’s discussion and Borgeat’s accompanying insightful editorial commentary.<sup>5</sup> We believe that needle penetration and small-volume injection through the epineurium may be more common than anticipated in daily practice and most often benign in nature, and that the true danger zone for nerve damage likely lies beyond the perineurium. Unfortunately, current ultrasound technology does not allow the operator to visually differentiate the epineurium from perineurium. Nonetheless, ultrasound seems to be a useful tool to detect as little as 1-2 ml intraneural injectate and thus avoid presumably injurious high-volume local anesthetic intraneural injection. Whether ultrasound-detected intraneural injection culminates in clinical neurologic deficit is currently under investigation at our institution.

**Richard Brull, M.D., F.R.C.P.C.,\* Vincent W. S. Chan, M.D., F.R.C.P.C., Colin J. L. McCartney, M.B., Ch.B., F.R.C.A., F.R.C.P.C., Anahi Perlas, M.D., F.R.C.P.C., Daquan Xu, M.B., M.Sc.** \*University of Toronto, Toronto, Ontario, Canada. richard.brull@uhn.on.ca

## References

1. Bigeleisen PE: Nerve puncture and apparent intraneural injection during ultrasound-guided axillary block do not invariably result in neurologic injury. *ANESTHESIOLOGY* 2006; 105:779-83
2. Brull R, Chan VWS, Shannon P: Intraneural electrical stimulation and ultrasound detection of intraneural injection. *Reg Anesth Pain Med* 2006; 30:A1
3. Chan VWS, Brull R, McCartney CJL, Xu D, Abbas S, Shannon P: An ultrasonographic and histological study of intraneural injection and electrical stimulation in pigs. *Anesth Analg* 2007; 104:1281-4
4. Hadzic A, Dilberovic F, Shah S, Kulenovic A, Kapur E, Zaciragic A, Cosovic E, Vuckovic I, Divanovic KA, Mornjakovic Z, Thys DM, Santos AC: Combination of intraneural injection and high injection pressure leads to fascicular injury and neurologic deficits in dogs. *Reg Anesth Pain Med* 2004; 29:417-23
5. Borgeat A: Regional anesthesia, intraneural injection, and nerve injury: Beyond the epineurium. *ANESTHESIOLOGY* 2006; 105:647-8

(Accepted for publication February 1, 2007.)

Anesthesiology 2007; 106:1244-5

Copyright © 2007, the American Society of Anesthesiologists, Inc. Lippincott Williams & Wilkins, Inc.

## Ultrasound-guided Intraneural Injections and Neurologic Injury

*To the Editor:*—In the October 2006 issue of *ANESTHESIOLOGY*, Bigeleisen reported that intraneural injections do not invariably lead to neurologic injury.<sup>1</sup> After premedicating patients, Bigeleisen used a 22-gauge short bevel

needle and a 10-MHz linear ultrasound transducer to anesthetize brachial plexus at the axilla by guiding the needle to elicit paresthesia or piercing the fascia around the individual nerves by the sensation of a pop. In all, 72 of total

of 104 nerves received an intraneural injection, without neurologic consequences.

Dr. Bigeleisen deserves accolade for taking on a responsibility of formally documenting what we long suspected: Intraneural injections indeed do not inevitably result in neurologic injury. In clinical practice of peripheral nerve blockade (PNB), injection of local anesthetic is typically followed by a latency of 10–20 min for the blockade to develop. In contrast, injections of the same local anesthetic for the same PNBs occasionally result in nearly instantaneous, dense, and unusually long-lasting nerve blockade. It is almost certain that such blocks are the result of intraneural injections and the consequent intimate exposure of neural tissue to high concentrations and volumes of local anesthetics.<sup>1,2</sup> However, the potentially hazardous clinical implications of Bigeleisen's data deserve careful considerations.

First, intraneural injections can be extrafascicular or intrafascicular. The intraneural-*extrafascicular* injections are characterized by a diffuse spread of the injectate within the epineurium with escape of the fluid into the extraneural space. Such injections indeed do not necessarily result in nerve injury.<sup>1–6</sup> In contrast, *intrafascicular* injections almost invariably lead to some degree of neurologic impairment,<sup>4</sup> and possibly a substantial proximal spread of the injectate toward the neuraxis.<sup>7,8</sup> As Dr. Bigeleisen correctly points out, neurologic injury after PNBs is uncommon; therefore, his study is underpowered to draw any meaningful conclusions on the safety of intraneural injections.

Second, our ability to monitor and avoid intrafascicular injection during PNBs has been limited. Real-time monitoring of needle placement by ultrasound guidance is useful, but of inadequate resolution to avoid intrafascicular injection.<sup>6</sup> Recent data in animal models suggest that nerve stimulation with currents of less than 0.2 mA (0.1 ms) may be associated with intraneural injection<sup>9</sup>; however, nerve stimulation is inconsistent and unreliable after injection of even miniscule volumes of local anesthetic.

Third, we do not agree with Dr. Bigeleisen in that an initial injection of a small volume (2–3 ml) of local anesthetic is a satisfactory precautionary measure to avoid an intrafascicular injection. Fascicles are small structures, and injury occurs even with minute volumes of local anesthetic ( $\leq 0.5$  ml).<sup>2,4,7,10</sup> Injections into fascicles are characterized by high opening injection pressure ( $\geq 20$  psi), followed by a rapid decrease of injection pressure to normal as the perineurium ruptures and local anesthetic leaks out perineurally.<sup>2,7,10</sup> Therefore, intraneural injection of even small volumes of local anesthetic are hazardous without monitoring the injection pressure.<sup>11</sup>

Fourth, Bigeleisen<sup>1</sup> reports that paresthesia results in intraneural injections in 96% of attempts; however, intraneural injection may not always result in paresthesia. These findings speak once more against the use of paresthesia-guided techniques for block placement.

In conclusion, we are in agreement with the accompanying editorial<sup>12</sup>; needles should *not* be routinely inserted intraneurally in the absence of reliable monitoring to guard against an intrafascicular needle placement. We believe that for success and safety of PNBs, a combination of real-time ultrasound needle guidance along with in-line injection pressure monitoring<sup>11</sup> and avoidance of injection with stimulation of less than 0.2 mA<sup>9</sup> may prove to be the ultimate monitoring during PNBs. However, more clinical data are needed before any such monitoring can be suggested as a routine practice.

**Marco Baciarello, M.D., Andrea Casati, M.D., Guido Fanelli, M.D.\***

\*University Hospital of Parma, Parma, Italy. guido.fanelli@unipr.it

## References

1. Bigeleisen PE: Nerve puncture and apparent intraneural injection during ultrasound-guided axillary block does not invariably result in neurologic injury. *ANESTHESIOLOGY* 2006; 105:779–83
2. Kapur E, Dilberovic F, Zacicragic A, Cosovic E, Vuckovic I, Divanovic KA, Mornjakovic Z, Mirsad B, Borgeat A, Thys DM, Hadzic A: Neurologic and histologic outcome after intraneural injections of lidocaine in canine sciatic nerves. *Acta Anaesthesiol Scand* 2007; 51:101–7
3. Sala-Blanch X, Pomes J, Matute P, Valls-Sole J, Carrera A, Tomas X, Al G-D: Intraneural injection during anterior approach for sciatic nerve block. *ANESTHESIOLOGY* 2004; 101:1027–30
4. Mackinnon S, Hudson A, Llamas F, Dellon A, Kline D, Dan A, Hunter R: Peripheral nerve injury by chymopapain injection. *J Neurosurg* 1984; 61:1–8
5. Mackinnon S, Dellon A: Classification of nerve injuries as the basis of treatment, *Surgery of the Peripheral Nerve*. Edited by Mackinnon S. New York, Thieme Medical Publishers, 1988, pp 35–63
6. Schafhalter-Zoppoth I, Zeitz I, Gray A: Inadvertent femoral nerve impalement and intraneural injection visualized by ultrasound. *ANESTHESIOLOGY* 2004; 99:620–30
7. Selander D, Sjostrand J: Longitudinal spread of intraneurally injected local anesthetics: An experimental study of the initial neural distribution following intraneural injections. *Acta Anesth Scand* 1978; 22:622–34
8. Dutton R, Eckhardt W III, Sunder N: Total spinal anesthesia after interscalene blockade of the brachial plexus. *ANESTHESIOLOGY* 1994; 80:939–41
9. Voelckel W, Klima G, Krismer C, Halsonger C, Stadlbauer H, Wenzel V, von Goedecke A: Signs of inflammation after sciatic nerve block in pigs. *Anesth Analg* 2005; 101:1844–6
10. Hadzic A, Dilberovic F, Shah S, Kulenovic A, Kapur E, Zacicragic A, Cosovic E, Vuckovic I: Combination of intraneural injection and high injection pressure leads to fascicular injury and neurologic deficits in dogs. *Reg Anesth Pain Med* 2004; 29:417–23
11. Tsui BCH, Li L, Pillay J: Compressed air injection technique to standardize block injection pressures. *Can J Anesth* 2006; 53:1098–102
12. Borgeat A: Regional anesthesia, intraneural injection, and nerve injury: Beyond the epineurium. *ANESTHESIOLOGY* 2006; 105:647–8

(Accepted for publication February 1, 2007.)

## Intraneural Injection of Local Anesthetics during Ultrasound-guided Peripheral Nerve Block May Lead to Nerve Injury

*To the Editor:*—I read with interest the article by Bigeleisen.<sup>1</sup> In this article, the author presented a prospective study of ultrasound-guided axillary blocks and determined the incidence of nerve puncture, intraneural injection of local anesthetics, and transient or permanent nerve injuries. After reading this well-written article it occurred to me that there are some points that may add to discussion. Damage may be caused to peripheral nerves after regional anesthesia techniques by mechanical, chemical, or ischemic injuries, which may occur alone or in combination.<sup>2</sup> Iohom *et al.*<sup>2</sup> reported that intraneural injection of ropivacaine in rat sciatic nerve, in a concentration routinely used in clinical practice, caused no deleterious effect on motor function. Hadzic *et al.*<sup>3</sup> reported varying degrees of damage to the neural architecture after high-pressure injection of local anesthetic in dog sciatic nerve. This damage ranged from mechanical disruption and delamination to fragmentation of the myelin sheath and marked cellular infiltration. They also reported severe and persistent motor deficits.<sup>3</sup>

Since the introduction of ultrasound-guided peripheral nerve blocks at my institution, I frequently observe nerve puncture during this procedure. In my experience, the combination of electrical stimulation does not result always in motor response even if the needle tip is positioned intraneurally. In the same condition, I also sometimes observe no pain on intraneural injection. The advantage of ultrasound-guided nerve blocks in my practice is that I can watch the needle's advancement in real time. Accordingly, in case I suspect nerve puncture, I slightly withdraw the needle and avoid intraneural injection to increase safety. In this study, the author excluded 22 patients from the study because of preoperative abnormalities in their motor and sensory examination. In daily practice, patients may present some degree of neurologic abnormalities before surgery. They may also be at high risk of nerve damage. Furthermore, intraneural injection in these patients may lead to an aggravating condition of their preexisting neuropathy. There are multiple causes and a combi-

nation of factors that may lead nerve injury after regional anesthesia techniques.<sup>4</sup> However, peripheral nerves have a dual blood supply of intrinsic exchange vessels in the endoneurium and an extrinsic plexus of supply vessels in the epineurial space that cross the perineurium to anastomose with intrinsic circulation.<sup>2</sup> Accordingly, nerve ischemia due to intraneural compression (local anesthetic volume or edema) and/or perineural compression (local anesthetic volume) may cause permanent or transient nerve damage.<sup>4</sup> Moreover, high-pressure intrafascicular or endoneural injection may also cause neural damage.<sup>3</sup> Consequently, the combination of ischemia, high-pressure intrafascicular or endoneural injection and local anesthetic toxicity could be deleterious to peripheral nerves.<sup>3,4</sup>

According to my experience, it is difficult to tell from the ultrasound image after apparent intraneural placement of the needle tip, whether the needle is positioned perineurally, epineurally, or endoneurally. The injection of the local anesthetic, even in a small quantity, in one of these positions may not lead to the same outcome. Furthermore, endoneural injection could result in nerve damage by promoting ischemic changes.<sup>2</sup> For this reason, I believe that avoidance of intraneural placement of the needle tip should be a major concern during ultrasound-guided peripheral nerve blocks. Moreover, performing a peripheral nerve block in real time and under direct vision gives us the possibility to correct the needle position, avoid intraneural injections, and avoid nerve injury.

In conclusion, although this study and other reports<sup>1,2</sup> suggested that nerve puncture and intraneural injection of low to moderate volumes of local anesthetic do not inevitably lead to neurologic injury, the role of ultrasound-

guided peripheral nerve blocks is to increase safety. Even if we hypothesize that intraneural injections do not lead to neurologic damage, they present no advantage over perineural injections in rapidity of installation or in success rate after ultrasound-guided techniques. Finally, practitioners who have already experienced neurologic problems after regional anesthesia techniques always remember the difficulties encountered during the long way of patient care.

**Bassam Al-Nasser, M.D.**, Clinique du Parc saint Lazare, Beauvais, France. balnasser@wanadoo.fr

## References

1. Biegeleisen PE: Nerve puncture and apparent intraneural injection during ultrasound-guided axillary block does not invariably result in neurologic injury. *ANESTHESIOLOGY* 2006; 105:779-83
2. Iohom G, Lan GB, Diarra DP, Grignon Y, Kinirons BP, Girard F, Merle M, Granier G, Cahn V, Bouaziz H: Long-term evaluation of motor function following intraneural injection of ropivacaine using walking track analysis in rats. *Br J Anaesth* 2005; 94:524-9
3. Hadzic A, Dilberovic F, Shah S, Kulenovic A, Kapur E, Zaciragic A, Cosovic E, Vuckovic I, Divanovic KA, Mornjakovic Z, Thys DM, Santos AC: Combination of intraneural injection and high injection pressure leads to fascicular injury and neurologic deficits in dogs. *Reg Anesth Pain Med* 2004; 29:417-23
4. Al-Nasser B: Local toxicity of local anaesthetics: Do experimental data apply to clinical manifestations? (letter). *Anaesthesia* 2002; 57:1236-7

(Accepted for publication February 1, 2007.)

*Anesthesiology* 2007; 106:1246-7

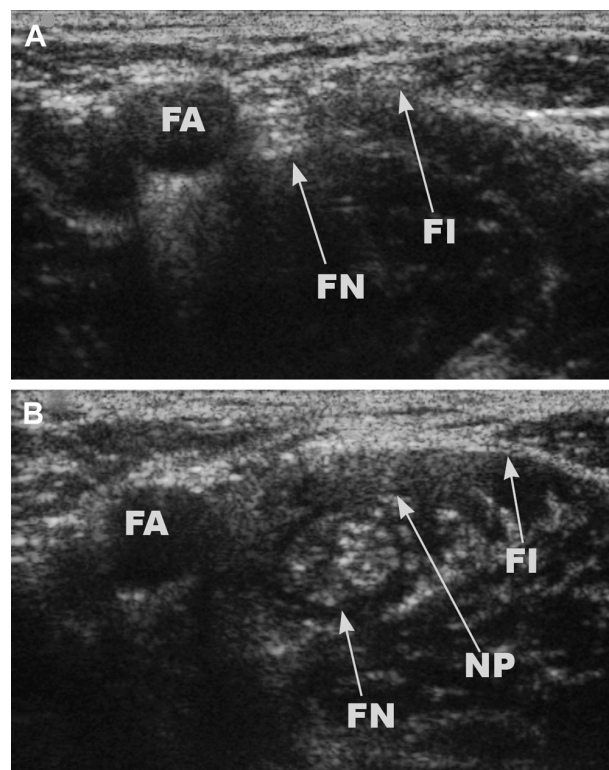
Copyright © 2007, the American Society of Anesthesiologists, Inc. Lippincott Williams & Wilkins, Inc.

## Evidence of Nerve Puncture during Ultrasound-guided Peripheral Nerve Blocks

*To the Editor:*—The article by Biegeleisen<sup>1</sup> is a nice illustration of gross anatomical changes that may occur in a nerve during performance of a peripheral nerve block (PNB) and highlights the emerging role of ultrasound in the performance of PNB. The author used a 10-MHz linear transducer to demonstrate the findings. Transducers with higher frequencies are now becoming increasingly available and will in the future provide better definition of the anatomic details, particularly when superficial nerves are imaged.

However, we have a few comments. (1) In this study, patients were sedated with 1–2 mg midazolam and 50–100 µg fentanyl, which may have interfered with the ability to report paresthesia during performance of the PNB. Because the nerves were identified by the report of paresthesia by the subject or the feeling of a pop, one would like to know the distribution of the techniques in identifying the nerves. (2) The title is misleading. Although the author uses the phrase “ultrasound-guided axillary block” in the title, according to the methods, the actual nerve was identified (according to the author) only “when a paresthesia was elicited or a pop was felt.” The author does not report the plane at which the needle was advanced in relation to the ultrasound beam in the methods section. If the needle was advanced perpendicular to the beam at any time, it might have been difficult to comment on whether the needle entered the substance of the nerve. (3) No age range of patients was reported in the results section.

We do agree with the author that intraneural injection may not always lead to nerve injury. We work in a tertiary care pediatric center and perform almost all of our PNBs during general anesthesia. Most of our PNB are increasingly being performed with ultrasound guidance in conjunction with a nerve stimulator. We would like to report a case where a left femoral nerve block was performed during general anesthesia for postoperative analgesia in a 12-yr-old, 33-kg girl who underwent a left distal femoral and proximal tibial epiphysiodesis. The femoral nerve block was performed using a nerve stimulator with ultrasound guidance. Thirty milliliters ropivacaine, 0.1%, was injected



**Fig. 1.** Appearance of the femoral nerve on ultrasound before injection of local anesthetic (A) and after completion of injection of local anesthetic (B) (shows swelling of the nerve). FA = femoral artery; FI = fascia iliaca; FN = femoral nerve; NP = needle path.

in increments without resistance *via* a 22-gauge Braun Stimuplex needle (B. Braun Medical, Bethlehem, PA) at a stimulation threshold of 0.31 mA. Postoperatively, the patient had complete sensory blockade in the distribution of the left femoral and lateral cutaneous nerve of the thigh and did not need any opioids for 23 h. The patient had no residual numbness (after 24 h), paresthesia, or dysesthesia. A review of the ultrasound images obtained during the block showed swelling of the nerve after injection of the local anesthetic (figs. 1A and B, similar to the images obtained by Bigeleisen).<sup>1</sup>

As reported by Bigeleisen,<sup>1</sup> the occurrence of intraneural injection during PNB is probably not uncommon, and only a larger series can determine the consequences of intraneural injection noted on ultrasound.

Anesthesiology 2007; 106:1247

Copyright © 2007, the American Society of Anesthesiologists, Inc. Lippincott Williams & Wilkins, Inc.

*In Reply:*—I appreciate the thoughtful comments about my article titled “Nerve Puncture and Apparent Intraneural Injection during Ultrasound-guided Axillary Block Does Not Invariably Result in Neurologic Injury.”<sup>1</sup> My comments to the individual physicians are listed below.

Drs. Brull, Chan, McCartney, Perlas, and Xu report interesting results from their clinical work and pig studies. My own experience is that needle bevel type does make a great deal of difference in the incidence of neural injury during ultrasound-guided block. The B-bevel needle I commonly use is designed for nerve blocks and has a tip that is similar to the bevel on the Braun needle that Brull *et al.* use. In contrast, I used an ordinary 22-gauge hypodermic needle for ultrasound-guided blocks in 25 patients. The incidence of nerve injury with motor weakness lasting 3–12 months in this group was 4 out of 25. The incidence of sensory injury lasting up to 3 months was 7 out of 1,324 using a B-bevel needle with ultrasound guidance. There were no motor or long-term sensory injuries in any of the patients in whom a B-bevel needle was used with ultrasound guidance.

Drs. Baciarello, Casati, and Faneli have misinterpreted my comments. Small injectate volumes do not imply that the perineurium has not been violated. Selander's study suggests that nerve stimulation may be safer than a paresthesia technique, but is without power to prove it. A commercially available device designed to measure pressures during nerve block would be very

Dr. Borgeat was contacted for reply to the Baciarello *et al.* letter but did not feel that a response was necessary.—James C. Eisenach, M.D., Editor-in-Chief

Anesthesiology 2007; 106:1247–8

Copyright © 2007, the American Society of Anesthesiologists, Inc. Lippincott Williams & Wilkins, Inc.

## Prediction of a Low Success Rate of Astronauts in Space in Performing Endotracheal Intubation

*To the Editor:*—We certainly concur with Rabitsch *et al.*<sup>1</sup> that tracheal intubation using direct laryngoscopy by astronauts in space is likely to have a high failure rate. Roan first presented this concept and the use of the *Laryngeal Mask Airway*<sup>TM</sup> (LMA<sup>TM</sup>; LMA North America, Inc., San Diego, CA) as a backup emergency airway device to the National Aeronautics and Space Administration in October 1999\* and later at the Aerospace Medical Association Conference in 2001.† In fact, since 2003, the LMA-Fastrach<sup>TM</sup> has been used on the space shuttle as a backup airway device.

\* Roan RM: An airway for medical emergencies in space. Presented at: National Aeronautics and Space Administration Johnson Space Center; October 1999; Houston, Texas.

† Roan RM, Johnston S: An airway for medical emergencies in space. Presented at: Aerospace Medicine Association Annual Meeting; May 2001; Reno, Nevada.

Anesthesiology, V 106, No 6, Jun 2007

**Arjunan Ganesh, M.B.B.S.,\* Giovanni Cucchiario, M.D.** \*The Children's Hospital of Philadelphia and University of Pennsylvania School of Medicine, Philadelphia, Pennsylvania. ganasha@email.chop.edu

### Reference

1. Bigeleisen PE: Nerve puncture and apparent intraneural injection during ultrasound-guided axillary block does not invariably result in neurologic injury. *ANESTHESIOLOGY* 2006; 105:779–83

(Accepted for publication February 1, 2007.)

useful, especially if it were built into the nerve stimulation device that many practitioners prefer to use. Data to prove that such a device would prevent nerve injuries are not available. Use of devices that are not approved by the US Food and Drug Administration has its own perils.

Dr. Al-Nasser suggests that ultrasound should be used to avoid intraneural injection. This is certainly a safe and prudent practice. My own experience is that injections that surround the nerve but are outside the epineurium do not provide rapid reliable nerve block. At the Lindsay House Surgery Center (Rochester, NY), some individual surgeons perform 20 joint surgeries in a single day. The technique that Dr. Al-Nasser uses is not fast or reliable enough to keep up with this pace in my hands.

Drs. Ganesh and Cucchiario: All blocks were performed with the tip and shaft of the needle in line with the transducer. In some cases, the needle and/or transducer had to be manipulated to ensure visualization of the entire needle.

**Paul Bigeleisen, M.D.**, University of Pittsburgh School of Medicine, Pittsburgh, Pennsylvania. bigeleisenpe@upmc.edu

### Reference

1. Bigeleisen PE: Nerve puncture and apparent intraneural injector during ultrasound-guided axillary block does not invariably result in neurologic injury. *ANESTHESIOLOGY* 2006; 105:779–83

(Accepted for publication February 1, 2007.)

Several reasons exist that predict a low success rate of astronauts in space in performing tracheal intubation. Although some crew medical officers (CMOs) are physicians, often the CMO may have no medical background. The training CMOs receive on the proper use of the bag valve mask resuscitator, oral airway, tracheal intubation, and surgical cricothyroidotomy is limited, and even physician CMOs are likely to have had several years pass since the last clinical exposure to this scenario. Studies have found that experienced emergency medical technicians (basic), with two to three times the amount of training provided to CMOs, have only approximately a 50% success rate of tracheal intubation in human subjects.<sup>2,3</sup> A compounding factor further increasing the likelihood of failed intubation is the condition of microgravity while in orbit.

The ideal airway for astronaut CMOs would possess a very short learning curve as well as require little experience to master and

maintain proficiency. Rabitsch *et al.*<sup>1</sup> chose the Esophageal Tracheal Combitube® (Kendall Sheridan Healthcare Products Company, Argyle, NY) as a backup airway device for failed tracheal intubation. Although requiring less training and skill than direct laryngoscopy, the use of the Combitube® as a rescue airway for failed intubation has shown an overall complication rate of up to 40%, including failure to place, aspiration, pneumothorax, esophageal perforation and laceration, among others.<sup>4,5</sup> Also, the presence of two lumens may prove confusing to the relative novice under the many stressors of an emergency; clearly, the wrong lumen choice would have disastrous consequences.

Although an oral airway and manual resuscitator with facemask is another option, it is well known that ventilation with this device can be challenging for even the most highly trained personnel. On the other hand, 100% of 32 nurses without previous experience in the use of the *LMA*™ were able to successfully ventilate live patients 3 months after manikin-only training.<sup>6</sup> The complication rate of the *LMA*™ is quite low, and when used as a primary airway rescue device for failed intubation, it has provided rescue ventilation without complication in 94% of failed intubation cases.<sup>7</sup>

Although the standard *LMA*™ has a high success rate as a conduit for tracheal intubation, the *LMA-Fastrach*™ is specifically designed to facilitate this. Therefore, it was chosen for the shuttle orbiters and the International Space Station because it most closely meets the criteria delineated above of a short learning curve with a high success rate and easily maintained insertion proficiency.

Anesthesiology 2007; 106:1248

Copyright © 2007, the American Society of Anesthesiologists, Inc. Lippincott Williams & Wilkins, Inc.

*In Reply:*—We appreciate the letter by Roan and Boyd regarding our article.<sup>1</sup> Their footnotes are presentations at specialty meetings and no data are available for review; therefore, these footnotes cannot be regarded as legitimately indicating that the *Fastrach Laryngeal Mask Airway*™ (*LMA*™; LMA North America, Inc., San Diego, CA) has already been used on the space shuttle. We agree that the learning curve should require little experience to master and maintain proficiency. In this letter, we want to explain why we believe that the Combitube® (Tyco Healthcare, Nellcor Mallinckrodt, Pleasanton, CA) is superior to the *LMA*™.

First, it provides an almost perfect seal against aspiration especially in vomiting and bleeding patients.<sup>2-4</sup> Second, it allows application of high ventilatory pressures.<sup>3</sup> Third, the diameter of the Combitube® is very small and therefore allows insertion even in patients with a small interincisor distance and/or trismus. Fourth, training time is short.<sup>5</sup> Fifth, studies with the Combitube® show that skills are not only easily acquired but also easily maintained even in small emergency medical systems when the device is used only once in a period of 18 months.<sup>2-4</sup> Sixth, all studies directly comparing the *LMA*™ and the Combitube® are in favor of the Combitube®: Emergency medical technicians rate the Combitube® best with regard to overall performance and adequacy of airway patency and ventilation; success rates of insertion and ventilation are highest with the Combitube®.<sup>3</sup> Seventh, significantly more emergency care physicians prefer the Combitube® as a nonsurgical alternative for coniotomy as compared with the *LMA*™.<sup>5</sup> Physicians rate the Combitube® best with regard to effectiveness and easiness to learn.<sup>5</sup> Eighth, the Combitube® has proven to be a salvage airway when conventional rapid sequence tracheal intubation fails with no reported complications.<sup>6</sup> Ninth, the Combitube® is used as a salvage airway by anesthesiologists when tracheal intubation or *LMA*™ fail in out-of-operating-room resuscitation.<sup>7</sup>

**Ronald M. Roan, M.D., Maj., U.S.A.F., M.C., F.S., Gwendolyn L. Boyd, M.D.†** †University of Alabama at Birmingham, Birmingham, Alabama. gboyd@uab.edu

## References

1. Rabitsch W, Moser D, Inzunza MR, Niedermayr M, Kostler WJ, Staudinger T, Locker G, Schellongowski P, Wulkersdorfer B, Rich JM, Meyer B, Benumof JL, Frass M: Airway management with endotracheal tube *versus* Combitube® during parabolic flights. *ANESTHESIOLOGY* 2006; 105:696-702
2. Bradley JS, Billows GL, Olinger ML, Boha SP, Cordell WH, Nelson DR: Prehospital oral endotracheal intubation by rural basic emergency medical technicians. *Ann Emerg Med* 1998; 32:26-32
3. Sayre MR, Sakles JC, Mistler AF, Evans JL, Kramer AT, Pancioli AM: Field trial of endotracheal intubation by basic EMTs. *Ann Emerg Med* 1998; 31:228-33; *Ann Emerg Med* 1998; 32(pt 1):391-2
4. Calkins TR, Miller K, Langdorf MI: Success and complication rates with prehospital placement of an esophageal-tracheal Combitube as a rescue airway. *Prehospital Disaster Med.* 2006; 21 (suppl 2):97-100
5. Vezina MC, Trepanier CA, Nicole PC, Lessard MR: Complications associated with the Esophageal-Tracheal Combitube in the pre-hospital setting. *Can J Anaesth* 2007; 54:124-8
6. Roberts I, Allsop P, Dickinson M, Curry P, Eastwick-Field P, Eyre G: Airway management training using the laryngeal mask airway: A comparison of two different training programmes. *Resuscitation* 1997; 33:211-4
7. Parmet JL, Colonna-Romano P, Horrow JC, Miller F, Gonzales J, Rosenberg H: The laryngeal mask airway reliably provides rescue ventilation in cases of unanticipated difficult tracheal intubation along with difficult mask ventilation. *Anesth Analg* 1998; 87:661-5

(Accepted for publication February 1, 2007.)

We strongly emphasize training of whatever device is being used. Although the *LMA*™ provides a fascinating outstanding concept for in-hospital routine use, the obstacles of inadequate prevention of aspiration and inability to apply high ventilatory pressures limit its value in emergencies.

**Werner Rabitsch, M.D., Doris Moser, Ph.D., Michael Frass, M.D.,\* James M. Rich, Jonathan L. Benumof, M.D.** \*Medical University, Vienna, Austria. michael.frass@meduniwien.ac.at

## References

1. Rabitsch W, Moser D, Inzunza MR, Niedermayr M, Kostler WJ, Staudinger T, Locker G, Schellongowski P, Wulkersdorfer B, Rich JM, Meyer B, Benumof JL, Frass M: Airway management with endotracheal tube *versus* Combitube® during parabolic flights. *ANESTHESIOLOGY* 2006; 105:696-702
2. Lefrancois DP, Dufour DG: Use of the esophageal tracheal Combitube by basic emergency medical technicians. *Resuscitation* 2002; 52:77-83
3. Rumball CJ, MacDonald D: The PTL, Combitube, laryngeal mask, and oral airway: A randomized prehospital comparative study of ventilatory device effectiveness and cost-effectiveness in 470 cases of cardiorespiratory arrest. *Prehosp Emerg Care* 1997; 1:1-10
4. Tanigawa K, Shigematsu A: Choice of airway devices for 12,020 cases of nontraumatic cardiac arrest in Japan. *Prehosp Emerg Care* 1998; 2:96-100
5. Winterhalter M, Brummerloh C, Luttje K, Panning B, Hecker H, Adams HA: Emergency intubation with Magill tube, laryngeal mask and esophageal tracheal Combitube in a training-course for emergency care physicians [in German]. *Anesthesiol Intensivmed Notfallmed Schmerzther* 2002; 37:532-6
6. Davis DP, Valentine C, Ochs M, Vilke GM, Hoyt DB: The Combitube as a salvage airway device for paramedic rapid sequence intubation. *Ann Emerg Med* 2003; 42:697-704
7. Mort TC: Laryngeal mask airway and bougie intubation failures: The Combitube as a secondary rescue device for in-hospital emergency airway management. *Anesth Analg* 2006; 103:1264-6

(Accepted for publication February 1, 2007.)

## What Happened to the Old Visual Evoked Potential Monitoring?

*To the Editor:*—I read with interest the results of the American Society of Anesthesiologists Postoperative Visual Loss Registry and the analysis of the 93 spine surgery cases with postoperative visual loss.<sup>1</sup> Striking to me was that the majority of the complications happened in settings that were thought safe in the past. It has long been taught that prevention of direct ocular pressure, severe hypoxia, anemia, and hypotension prevent blindness in the majority of patients undergoing prone spine surgery. This report and analysis of data showed that direct ocular pressure contributed to only a small percentage of the documented cases, and that blindness occurred over a wide range of systolic pressure, hemodynamics, and hemoglobin concentrations. That led me to conclude that while prevention is the best cure for this problem, best prevention is not currently understood; it raised in my mind the question of intraoperative visual system monitoring. Today, we routinely use pulse oximetry, capnography, and even processed electroencephalographic monitoring to identify and promptly correct hypoxemia, ventilatory inadequacy, and awareness. Isn't it logical that in high-risk cases where blindness is possible that we should be monitoring the patient intraoperatively to identify early retinal changes that could correlate with this tragic event and try to prevent that outcome?

Intraoperative retinal monitoring through visual evoked potentials, with the aim of preserving visual fields, has been used successfully in many cases such as intracranial surgeries,<sup>2</sup> occipital corticectomy for epilepsy,<sup>3</sup> functional endoscopic sinus surgery,<sup>4</sup> optic nerve function surgery, and other surgeries involving the visual pathway. Currently, the use of the visual evoked potential is limited and not routinely practiced in spine surgery performed in prone positioning. It seems obvious that this modality should be used more frequently and even routinely in all prone spine surgeries.

I am aware of conflicting reports about the usefulness of this monitoring modality, but I believe that our reading and correlation of retinal evoked potentials will improve as the monitoring becomes routine. I hope that the future will focus on improving monitoring of the visual evoked potential, perhaps in a form as simple as bispectral monitoring (such as the Bispectral Index®; Aspect Medical Systems Inc., Norwood, MA). Such monitoring may allow us to accurately detect early, reversible damage to the visual pathway and enable us to prevent permanent problems. This would be in the best tradition of anesthesiology.

**Adballah I. Kabbara M.D.**, Louis Stokes Cleveland Department of Veterans Affairs Medical Center, Cleveland, Ohio. draikabbara@yahoo.com

### References

1. Lee LA, Roth S, Posner KL, Cheney FW, Caplan RA, Newman NJ, Domino KB: The American Society of Anesthesiologists Postoperative Visual Loss Registry: Analysis of 93 spine surgery cases with postoperative visual loss. *ANESTHESIOLOGY* 2006; 105:652-9
2. Hidayat RR, McLay JL, Goode DH, Hidayat JR: The value of VEP in the diagnosis and post-operative monitoring of meningioma. *Doc Ophthalmol* 2006; 113:165-9
3. Curatolo JM, Macdonell RA, Berkovic SF, Fabinyi GC: Intraoperative monitoring to preserve central visual fields during occipital corticectomy for epilepsy. *J Clin Neurosci* 2000; 7:234-7
4. Herzon GD, Zeale DL: Intraoperative monitoring of the visual evoked potential during endoscopic sinus surgery. *Otolaryngol Head Neck Surg* 1994; 111:575-9

(Accepted for publication February 8, 2007.)

## Excessive Crystalloid Infusion May Contribute to Ischemic Optic Neuropathy

*To the Editor:*—It is unfortunate that Drs. Lee *et al.*<sup>1</sup> and Warner<sup>2</sup> feel compelled to conclude that blindness may be an inevitable consequence of prolonged spine surgery in the prone position, and that patients should be warned of that possibility. While perhaps correct, my experience in supervising many hundreds of such cases without this complication leads me to believe that it is preventable. Although briefly considered by Dr. Lee *et al.* in the Discussion section, sufficient attention was not focused on the large average volume of crystalloid solution ( $9.7 \pm 4.7$  l) infused in the 83 patients who developed ischemic optic neuropathy. This volume of infusion is far in excess of what is necessary for maintenance of either blood pressure or urine output. In addition, it has a serious negative impact on the hematocrit, as well as promoting edema of the orbs and optic nerves. Although the etiology of blindness may be multifactorial, as anesthesiologists we must critically assess those aspects of care over which we have control. Limiting crystalloid administration, avoiding severe anemia (hematocrit < 26), and limiting the duration of controlled hypotension, if used, to the dissection period only (not the instrumentation period) are all controllable. I would urge anesthesiologists to limit crystalloid volume in prone spine surgical cases to no more than 40 ml/kg (approximately 3 l in adults) for the entire operative procedure regardless of duration. If additional fluid is deemed necessary, it should be hetastarch (not to

exceed 20 ml/kg), albumin, or blood. If necessary, a low-dose dopamine infusion can be used to support circulation and improve urine output. Finally, urine output should not be the benchmark for fluid requirements in these patients. Urine output is commonly diminished while patients are in the prone position for reasons that have not been documented. Diminished urine output in this setting does not lead to renal insufficiency postoperatively.

**C. Philip Larson, Jr., M.D.**, David Geffen School of Medicine at UCLA, Los Angeles, California. plarson@ucla.edu

### References

1. Lee LA, Roth S, Postner KL, Cheney FW, Caplan RA, Newman NJ, Domino KB: The American Society of Anesthesiologists Postoperative Visual Loss Registry: Analysis of 93 spine surgery cases with postoperative visual loss. *ANESTHESIOLOGY* 2006; 105:652-9
2. Warner MA: Postoperative visual loss: Experts, data, and practice. *ANESTHESIOLOGY* 2006; 105:641-2

(Accepted for publication February 8, 2007.)

## Visual Loss after Spinal Surgery

*To the Editor:*—The American Society of Anesthesiologists (ASA) Closed Claims Project has provided valuable information regarding risks and potential etiologies of untoward events related to the practice of anesthesia.<sup>1</sup> The ASA Registry for Postoperative Visual Loss arose from some of the same concerns as did the Closed Claims Project: an attempt to understand problems that have become medical-legal issues and to provide better care for our patients.<sup>2</sup> Lee *et al.*<sup>3</sup> have provided a valuable service in documenting data associated with this rare and devastating adverse event. Their report follows closely the recent ASA "Practice Advisory for Perioperative Visual Loss Associated with Spine Surgery."<sup>4</sup> Inasmuch as randomized prospective clinical trials to discern etiology and efficacy of the suggested therapies of increasing blood pressure and hemoglobin concentration would not be feasible, owing to the low incidence, estimated to be approximately 0.03–0.1% for ischemic optic neuropathy (ION)<sup>5,6</sup> (a reduction of 25% would require a study of approximately 200,000–750,000 patients per group), other methodologies are needed to assess possible etiologies and therapies. As pointed out by Lee *et al.*, unfortunately, information regarding the total number of surgical procedures represented by the reports in their database is not available. The registry could be improved by asking those who provide case reports to also indicate the number of similar operations performed during a several-year period (a short period would produce an artificially estimated high incidence). Even this, however, would overstate the incidence, because this complication has never been encountered by most spine surgeons,<sup>7</sup> and likely most institutions. Of greater concern is the recommendation contained in the report and the absence of other recommendations.

We question the recommendation regarding routine preoperative discussion of the possibility of postoperative visual loss, given the exceedingly low incidence. Complications of such low incidence<sup>5,6</sup> (e.g., masseter muscle rigidity/malignant hyperthermia<sup>8,9</sup>) are not routinely discussed, and the rarity of ION makes it unlikely that discussion would be a relevant consideration in whether the patient elected to proceed. In addition, once mentioned, little can be said regarding prevention or therapy, inasmuch as the etiologies of anterior ION and posterior ION are uncertain, and prophylactic and therapeutic maneuvers are of unproven value.

Of interest are the surprising data that the patients' eyes were documented as having been checked in only 51% of cases of ION (frequency not given) and in just 6 of 10 cases of central retinal artery occlusion (frequency of between every 30 min and only once during the entire procedure), which is widely regarded as being caused by direct trauma or pressure applied to the eye. Our spine anesthesia team was established in 1991, and our routine care includes checking the eyes every 15 min of every patient in the prone position. We previously reported 7 cases of visual disturbances after 3,450 spinal surgeries, including four IONs, one central retinal venous thrombosis, and no central retinal arterial thromboses.<sup>5</sup> We are surprised that the registry report contained no recommendation regarding the advisability of frequent checks for absence of direct pressure on the patient's eyes: something that is easily performed, is of no cost, and makes sense physiologically, although of unproven efficacy in preventing central retinal artery thrombosis. In addition, we recommend a simple, quick test of crude visual function and visual fields (e.g., tell how many fingers, and when they can be seen as they are moved from the periphery to a central position) as soon as possible in the immediate postoperative period. The ASA practice advisory<sup>4</sup> and Myers *et al.*<sup>7</sup> in

their evaluation of a series of 37 cases of visual loss after spinal surgery also recommend an early postoperative assessment of visual function. This allows for rapid consultation, documentation of the timing of the event, and institution of any recommended, although unproven, therapy.

The report provides a good discussion regarding possible etiologies of ION, including increased venous pressure and trapping of the optic nerve owing to increased interstitial fluid accumulation and thus pressure in an enclosed bony canal. It is possible that the latter issue may also decrease arterial blood flow. As discussed in the report, placing a patient prone in a position with the head slightly elevated decreases intraocular venous pressure. We practice and recommend this, as does the ASA practice advisory for "high-risk patients."<sup>4</sup> In addition, we also limit the volume of crystalloid solution to reduce the possibility of increased interstitial fluid and pressure, although, admittedly, neither this nor the slightly head-up tilted position is a proven efficacious prophylactic therapy.

We were surprised that the report did not consider patients' fraction of inspired oxygen or arterial oxygen tension. We have shown that anemia-induced neurologic deficits in healthy people can be reversed by increasing arterial oxygen concentration.<sup>10</sup> We are further concerned that both Lee *et al.* and the ASA Task Force suggest that protracted surgery and amount of blood loss are risk factors for the development of postoperative visual loss. Neither is physiologically grounded. A more sensible assessment, in the absence of a validated monitor for visual function during anesthesia, would focus on blood loss replacement and maintenance of normovolemia, rather than the volume of loss itself, and the duration of factors that might influence inadequate perfusion of the ophthalmic vasculature, rather than the duration of the surgery. The latter may be a poorly correlating surrogate for hypovolemia/hypoperfusion and may appear erroneously as a univariate factor in a database of a limited number of events. These might also be surrogates for the intravenous infusion of substantial amounts of salt solutions, with the potential adverse action noted above. Anesthesiologists and surgeons should work together to minimize potential contributing factors to this devastating complication; however, in the absence of definitive data, the Task Force's suggestion to alter accepted surgical practice<sup>11,12</sup> is questionable.

**Richard B. Weiskopf, M.D.,\* John Feiner, M.D., Jeremy Lieberman, M.D., Serena S. Hu, M.D.** \*University of California, San Francisco, California. [rwes@novonordisk.com](mailto:rwes@novonordisk.com)

## References

1. Cheney FW: The American Society of Anesthesiologists Closed Claims Project: What have we learned, how has it affected practice, and how will it affect practice in the future? *ANESTHESIOLOGY* 1999; 91:552–6
2. Warner MA: Postoperative visual loss: Experts, data, and practice. *ANESTHESIOLOGY* 2006; 105:641–2
3. Lee LA, Roth S, Posner KL, Cheney FW, Caplan RA, Newman NJ, Domino KB: The American Society of Anesthesiologists Postoperative Visual Loss Registry: Analysis of 93 spine surgery cases with postoperative visual loss. *ANESTHESIOLOGY* 2006; 105:652–9
4. Practice advisory for perioperative visual loss associated with spine surgery: A report by the American Society of Anesthesiologists Task Force on Perioperative Blindness. *ANESTHESIOLOGY* 2006; 104: 1319–28.
5. Stevens WR, Glazer PA, Kelley SD, Lietman TM, Bradford DS: Ophthalmic complications after spinal surgery. *Spine* 1997; 22:1319–24
6. Chang SH, Miller NR: The incidence of vision loss due to perioperative ischemic optic neuropathy associated with spine surgery: The Johns Hopkins Hospital Experience. *Spine* 2005; 30:1299–302
7. Myers MA, Hamilton SR, Bogosian AJ, Smith CH, Wagner TA: Visual loss as a complication of spine surgery: A review of 37 cases. *Spine* 1997; 22:1325–9
8. Monnier N, Krivosic-Horber R, Payen JF, Kozak-Ribbens G, Nivoche Y,

At the time of the writing and acceptance of this letter, Dr. Weiskopf was an employee of Novo Nordisk A/S, Bagsvaerd, Denmark. All authors contributed to the writing of this letter.



Adnet P, Reyford H, Lunardi J: Presence of two different genetic traits in malignant hyperthermia families: Implication for genetic analysis, diagnosis, and incidence of malignant hyperthermia susceptibility. *ANESTHESIOLOGY* 2002; 97:1067-74

9. Ording H: Incidence of malignant hyperthermia in Denmark. *Anesth Analg* 1985; 64:700-4

10. Weiskopf RB, Feiner J, Hopf HW, Viele MK, Watson J, Kramer JH, Ho R, Toy P: Oxygen reverses deficits of cognitive function and memory and increased heart rate induced by acute severe isovolemic anemia. *ANESTHESIOLOGY* 2002; 96:871-7

11. Bradford DS, Boachie-Adjei O: One-stage anterior and posterior hemivertebral resection and arthrodesis for congenital scoliosis. *J Bone Joint Surg Am* 1990; 72:536-40

12. Dick J, Boachie-Adjei O, Wilson M: One-stage *versus* two-stage anterior and posterior spinal reconstruction in adults. Comparison of outcomes including nutritional status, complications rates, hospital costs, and other factors. *Spine* 1992; 17:S310-6

(Accepted for publication February 8, 2007.)

Anesthesiology 2007; 106:1251

Copyright © 2007, the American Society of Anesthesiologists, Inc. Lippincott Williams & Wilkins, Inc.

*In Reply:*—In response to Dr. Larson's rather dogmatic conclusions on how to avoid perioperative ischemic optic neuropathy, I am pleased that he has never personally experienced this complication in one of his patients. His observation drives home the primary point of the report by Dr. Lee *et al.*<sup>1</sup> and my editorial<sup>2</sup>: There are too few of these complications at this time to scientifically deduce causative risk factors. Quite simply, it is not logistically or financially possible at this time to prospectively search for causative risk factors of this devastating complication as it occurs in patients undergoing spine surgery while positioned prone.

Therefore, it is difficult to understand what data Dr. Larson uses as a basis for his recommendations. There are no data to suggest that limiting crystalloid administration to less than 40 ml/kg regardless of duration of the surgical procedure impacts ischemic optic neuropathy (negatively or positively). The same can be said for his suppositions about hematocrit levels of less than 26 and limiting durations of controlled hypotension to only the dissection period of spine surgery. Data from multiple studies document that many patients who have Dr. Larson's "risk factors" do not develop ischemic optic neuropathy—and many who develop ischemic optic neuropathy receive crystalloid volumes of less than 40 ml/kg, have hematocrits intraoperatively well above 26, and are provided care without the use of controlled hypotension. In short, there is no scientific reasoning to justify Dr. Larson's strongly worded, unsupported recommendations.

Dr. Weiskopf raises two points to which I would like to respond. First, he speculates that periodic intraoperative checks of the eyes for absence of direct pressure on patients' eyes may be useful in preventing central retinal artery thrombosis. His spine team evidently established periodic intraoperative eye checks for all prone-positioned spine surgery patients and found that none of their 3,450 patients developed this complication.<sup>3</sup> However, as he notes, the frequency of this event is very low. It is, therefore, impossible to draw any conclusion or even inference that his team's eye checks had anything to do with the outcomes that their patients experienced. Regarding the use of eye checks, it is disappointing to find that 6 of the 10 patients with central retinal artery occlusion in the American Society of Anesthesiologists Visual Loss Registry had at least one eye check during their proce-

dures.<sup>1</sup> In those 6 patients, eye checks apparently did not prevent this problem from occurring. Therefore, should eye checks be done? Intuitively, yes—they are certainly cheap and easy. However, there are no data showing that they are effective in reducing the frequency or severity of central retinal artery occlusion.

Dr. Weiskopf also indirectly suggests that increased inspired oxygen concentrations, resulting in elevated arterial oxygen tension, may be helpful in decreasing the frequency of perioperative vision loss. He cites an excellent study that he and colleagues performed in volunteers who were made acutely anemic, finding that increased inspired oxygen concentrations reversed the negative cognitive effects of the anemia.<sup>4</sup> Ironically, hyperoxia has an autoregulation-related vasoconstrictive effect on the end-retinal arterioles of the central retinal artery, reducing both the diameter of the arterioles and also their blood flow and velocity.<sup>5</sup> It is not clear what impact this finding has on blood flow to the various regions of optic nerves, but increasing inspired oxygen concentrations may not be as helpful as he seems to suggest.

**Mark A. Warner, M.D.**, Mayo Clinic, Rochester, Minnesota.  
warner.mark@mayo.edu

## References

1. Lee LA, Roth S, Posner KL, Cheney FW, Caplan RA, Newman NJ, Domino KB: The American Society of Anesthesiologists Postoperative Visual Loss Registry: Analysis of 93 spine surgery cases with postoperative visual loss. *ANESTHESIOLOGY* 2006; 105:652-9
2. Warner MA: Postoperative visual loss: Experts, data, and practice. *ANESTHESIOLOGY* 2006; 105:641-2
3. Stevens WR, Glazer PA, Kelly SD, Lietman TM, Bradford DS: Ophthalmic complications after spinal surgery. *Spine* 1997; 22:1319-24
4. Weiskopf RB, Feiner J, Hopf HW, Viele MK, Watson J, Kramer JH, Ho R, Toy P: Oxygen reverses deficits of cognitive function and memory and increased heart rate induced by acute severe isovolemic anemia. *ANESTHESIOLOGY* 2002; 96:871-7
5. Rose PA, Hudson C: Comparison of retinal arteriolar and venular variability in healthy subjects. *Microvasc Res* 2007; 73:35-8

(Accepted for publication February 8, 2007.)

Anesthesiology 2007; 106:1251-2

Copyright © 2007, the American Society of Anesthesiologists, Inc. Lippincott Williams & Wilkins, Inc.

*In Reply:*—We gratefully acknowledge the interest that Drs. Kabbara, Larson, and Weiskopf *et al.* have shown in our article on spine surgery and postoperative visual loss (POVL).<sup>1</sup> It is only through the continued interest and investment of time and resources by anesthesiologists, ophthalmologists, and surgeons that we will develop preventative strategies and/or treatment for this devastating perioperative

complication. These letters provide an opportunity to discuss and expand on topics that space limitations would not allow in the original article.

Dr. Kabbara makes an insightful deduction in noting that our current lack of proven risk factors for ischemic optic neuropathy (ION), and its possible multifactorial etiology, would make an intraoperative monitor of optic nerve function a logical means to prevent ION. Unfortunately, previous studies have demonstrated that anesthetics diminish or ablate visual evoked potentials, making their intraoperative reliability poor.<sup>2,3</sup> Additional technical problems include poor sensitivity of the light-flash

Dr. Roth has received financial compensation for providing expert witness testimony on behalf of patients, hospitals, and physicians in cases of perioperative visual loss.

as opposed to pattern-evoked potentials. Further research and technical advances will be required before the sensitivity and specificity of this monitor for detecting optic nerve dysfunction are acceptable for routine clinical use. Moreover, some patients do not develop clinical visual deficits until several days after surgery, and it is unclear how useful an "intraoperative" optic nerve monitor would be in these situations.

Dr. Larson summarized his personal experience over many years and his personal beliefs about cause-and-effect relations regarding ION. Unfortunately, there is no way to validate the summary statements and beliefs derived from his anecdotal experience. Moreover, our clinical experience makes us concerned that limiting fluids to a specific amount, without regard to urine output or blood loss, may lead to underresuscitation and increase the risk of organ failure.

Although the American Society of Anesthesiologists POVL Registry has provided detailed descriptive characteristics of patients who develop ION after major spine surgery, it cannot be used to determine risk factors because there are no denominator data and no unaffected patients for comparison. Because of the nature of complex spine surgery, it is possible that patients who do not develop ION after major spine surgery have received similar amounts of crystalloid. The American Society of Anesthesiologists recently reviewed the scientific evidence and expert opinion regarding the anesthetic management to reduce the risk of perioperative visual loss in prone spine surgery. Because of the lack of scientific literature, an advisory, not a guideline, resulted. Although the advisory recommended the use of both colloid and crystalloid, specific amounts of these solutions could not be recommended because of the absence of any evidence-based literature.<sup>4</sup>

Dr. Weiskopf *et al.*'s point about frequent eye checks to prevent central retinal artery occlusion from globe compression is appreciated. Because the focus of our article was ION, we did not explicitly state, but do completely agree, that frequent eye checks during major prone spine surgery are of unquestionable value to prevent globe compression. Data on inspired oxygen concentration and arterial oxygen were not collected and therefore could not be examined with respect to anemia. The clinical use of high inspired oxygen concentration in the potential presence of ischemia remains controversial because of theoretical risks of reactive oxygen species tissue damage.<sup>5</sup> Other details regarding clinical care of spine patients at the authors' institution were noted, including limitation of crystalloid infusion, but again, the benefit of this practice with respect to prevention of ION cannot be validated based on the literature.

We agree with Dr. Weiskopf that consenting patients undergoing major spine surgery for the risk of POVL is challenging, but our experience reading closed claims files for POVL has repeatedly revealed that patients believe that they should have been consented for the risk of blindness associated with major spine surgery. The fact that the authors have made four significant intraoperative interventions aimed at preventing POVL demonstrates that it is of great concern to anesthesiologists and surgeons. Rest assured that it is of even more concern for patients. There is no widely accepted threshold of incidence of complications to preclude discussion of risks. Most states use the "reasonable patient" standard for consent as described by O'Leary, in which a physician is required "to disclose information that a reasonable patient under similar circumstances would want to know to make an informed decision."<sup>6</sup> These risks would include common side effects and complications of low severity, and those that are less common, but with significant impact, such as blindness.

The data are clear regarding the types of spine cases in which ION

occurs: prolonged operations in the prone position with large blood loss.<sup>1</sup> We, like others, speculate that the physiologic basis for these findings may have more to do with the prone position in which venous pressures are elevated and the time that it takes for optic nerve axons to become dysfunctional. Large blood loss increases the potential for hypovolemia and the occurrence of anemia, and increases fluid administration and transfusion of blood products, all of which may affect oxygen delivery to the tissues. However, any theory of causation for ION remains to be proven. We agree with the authors that maintenance of normovolemia is important and would be useful data to analyze, but this assessment is subject to varied interpretation, particularly in the prone position. This information would have to be collected in a prospective fashion with rigid criteria and uniform monitoring. We would like to clarify that we did not advocate a change in surgical practice, except for consent, without a randomized controlled trial comparing the effects of staged surgery for major spine procedures with single-stage surgery, because this alternative also has the potential for significant morbidity. We agree that surgeons and anesthesiologists must work together to minimize potential contributing factors to the development of POVL for our patients. The data demonstrate that two of these factors are prolonged spine surgery in the prone position and large blood loss.<sup>1</sup>

Finally, we would like to reiterate that the clinical phenomenon of perioperative ION occurs at such a low frequency (highest incidence reported to date 0.1%)<sup>7</sup> that prospective clinical studies randomizing patients to treatment arms would require a multicenter, long-term, costly study. Currently, there is no evidence-based medicine to support any causative (or preventative) statements regarding the development of ION. Because of the low incidence of ION, and the predominance of these cases in spine operations of 6 h or longer and blood loss of 1,000 ml or greater,<sup>1</sup> most anesthesiologists are fortunate enough to have never encountered this complication, regardless of their anesthetic management. However, good fortune should not be equated with best practice when the etiology and prevention of ION remain unproven.

**Lorri A. Lee, M.D.,\* Steven Roth, M.D., Karen L. Posner, Ph.D., Frederick W. Cheney, M.D., Robert A. Caplan M.D., Nancy J. Newman, M.D., Karen B. Domino, M.D., M.P.H.** \*University of Washington, Seattle, Washington. lorlee@u.washington.edu

## References

1. Lee LA, Roth S, Posner KL, Cheney FW, Caplan RA, Newman NJ, Domino KB. The American Society of Anesthesiologists Postoperative Visual Loss Registry: Analysis of 93 spine surgery cases. *ANESTHESIOLOGY* 2006; 105:652-9
2. Cedzich C, Schramm J, Mengedoh CF, Fahlbusch R: Factors that limit the use of flash visual evoked potentials for surgical monitoring. *Electroencephalogr Clin Neurophysiol* 1988; 71:142-5
3. Tenenbein PK, Lam AM, Lee LA: Effects of sevoflurane and propofol on flash visual evoked potentials (abstract). *ANESTHESIOLOGY* 2006; 105:A196
4. Practice advisory for perioperative visual loss associated with spine surgery: A report by the American Society of Anesthesiologists Task Force on Perioperative Blindness. *ANESTHESIOLOGY* 2006; 104:1319-28
5. Liu S, Liu W, Doing W, Miyake M, Rosenber GA, Liu KJ. Electron paramagnetic resonance-guided normobaric hyperoxia treatment protects the brain penumbral oxygenation in a rat model of transient focal cerebral ischemia. *J Cereb Blood Flow Metabol* 2006; 26:1274-84
6. O'Leary CE. Informed consent for anesthesia: Has the time come for a separate written consent document? *ASA Newsletter* 2006; 70 (6)
7. Stevens WR, Glazer PA, Kelley SD, Lietman TM, Bradford DS: Ophthalmic complications after spinal surgery. *Spine* 1997; 22:1319-24

(Accepted for publication February 8, 2007.)

## Loss of Gag Reflex and Swallowing Ability after Administration of Intrathecal Fentanyl

*To the Editor:*—Spinal analgesia using opioid with or without local anesthetic is commonly used for labor analgesia, usually as part of a combined spinal-epidural technique. Common side effects or complications include pruritus, hypotension, fetal bradycardia or other fetal heart rate tracing alterations, and of course, post-dural puncture headache. We have noted a rare but recurring complication, the loss of swallowing ability and gag reflex. We noted a few cases in the mid-1990s, when the fentanyl doses administered were in a range (25–35  $\mu\text{g}$ ) higher than generally given now (10–20  $\mu\text{g}$ ). Although this complication has been alluded to in the literature,<sup>1–3</sup> even most very experienced clinicians have not seen it or heard of it. We therefore present two cases describing the loss of the parturient's swallowing ability and gag reflex after the administration of subarachnoid fentanyl. In both cases, the gag reflex and the ability to swallow returned after administration of naloxone.

The first case was a 23-yr-old, gravida 1 para 0 woman who received combined spinal-epidural analgesia for labor at cervical dilation of 4 cm. The procedure was uneventful. A 17-gauge Tuohy needle was used to identify the epidural space using loss of resistance to saline 4.5 cm deep to the skin; the subarachnoid space was entered with a 27-gauge Whitacre needle, and 20  $\mu\text{g}$  fentanyl and 2.5 mg bupivacaine were injected into the cerebrospinal fluid. A 20-gauge epidural catheter was threaded into the epidural space. Approximately 10–12 min after spinal injection (with no epidural injection or infusion yet), the patient reported "difficulty breathing." The oxygen saturation as measured by pulse oximetry throughout the procedure and at this time was 99–100% with the patient breathing room air. It was rapidly determined that the difficulty was not with breathing but rather with swallowing. Sensory block to ice was at about T8 or T7. Motor strength in the upper extremities was completely normal and was 3–4/5 in the lower extremities, as expected with the given dose of bupivacaine. Placing a cotton swab and tongue blade in the posterior pharynx revealed an absent gag reflex. 40  $\mu\text{g}$  naloxone was given intravenously, and within a minute or two, the patient was able to swallow and her gag reflex had returned. Approximately 30 min later, she again noted difficulty swallowing, and again the gag reflex was absent. Another dose of 40  $\mu\text{g}$  naloxone was given, with resolution of her symptoms, and they did not return. Analgesia remained excellent throughout this period. She proceeded to an uneventful delivery with excellent analgesia from both the spinal and epidural portions of her analgesic.

The second case involved a 19-yr-old, gravida 1 para 0 woman undergoing a cesarean delivery for breech presentation. The patient received spinal anesthesia in the sitting position with 12 mg hyperbaric bupivacaine, 0.2 mg preservative-free morphine, and 20  $\mu\text{g}$  fentanyl, resulting in a C4 sensory level and C8 motor level (grip 2/4). Approximately 3 min after the spinal dose, the patient experienced an episode of hypotension that resolved with 160  $\mu\text{g}$  phenylephrine. Approxi-

mately 20 min after the spinal dose, the patient reported decreased ability to swallow, and physical examination revealed an absent gag reflex with otherwise intact cranial nerves. Approximately 25 min after the spinal dose, the patient was treated with 80  $\mu\text{g}$  naloxone. Her ability to swallow returned, as did her gag reflex, and she remained without further difficulty swallowing.

This phenomenon has been mentioned in the literature, but never fully described. In a 1993 retrospective review of 90 patients receiving intrathecal sufentanil (10  $\mu\text{g}$  in 1 ml saline), Cohen *et al.*<sup>2</sup> mention a patient who reported "transient difficulty swallowing and taking a deep breath." The patient was noted to have a loss of pinprick to her face and was unable to swallow water. This event sounds similar to our cases described above. Gadalla *et al.*<sup>3</sup> mention difficulty swallowing as a presumed marker of excessive cephalad intrathecal opioid spread. A large series reported by Albright and Forster<sup>1</sup> indicates that the phenomenon may occur with a higher frequency than generally appreciated. The authors describe the results of 6,002 combined spinal-epidurals with 10, 15, or 20  $\mu\text{g}$  intrathecal sufentanil with 2.5 mg bupivacaine. The side effects included 71 cases of dysphagia treated with nalbuphine or naloxone. There was an increased prevalence of dysphagia with increasing doses of sufentanil (0.9% vs. 3.8% vs. 3.1%, respectively) and an average onset of symptoms of 24 min.

Despite this incidence, the phenomenon or a potential mechanism for it has not been widely discussed in the literature. Previous reports have focused on the loss of swallowing ability, but the current demonstration of the loss of the gag reflex in association with the swallowing defect suggests that these pregnant patients could be at increased risk of aspiration and that an opioid antagonist should be administered. Both patients were concerned and frightened by the sensation, and therapy was effective. The fact that therapy with opioid antagonists appears to reverse the effect seems to confirm that its mechanism involves the opioid receptor. It is not clear how or why this should be the case, so this observation could also provide some insight into the pathophysiology and treatment of swallowing disorders.

**Richard M. Smiley, M.D., Ph.D.,\* Robert P. Moore, M.D.**  
\*Columbia University, New York, New York. rms7@columbia.edu

### References

1. Albright GA, Forster RM: The safety and efficacy of combined spinal and epidural analgesia/anesthesia (6,002 blocks) in a community hospital. *Reg Anesth Pain Med* 1999; 24:117–25
2. Cohen SE, Cherry CM, Holbrook RH Jr, el-Sayed YY, Gibson RN, Jaffe RA: Intrathecal sufentanil for labor analgesia: Sensory changes, side effects, and fetal heart rate changes. *Anesth Analg* 1993; 77:1155–60
3. Gadalla F, Lee SH, Choi KC, Fong J, Gomillion MC, Leighton BL: Injecting saline through the epidural needle decreases the iv epidural catheter placement rate during combined spinal-epidural labour analgesia. *Can J Anaesth* 2003; 50:382–5

Support was provided solely from institutional and/or departmental sources.

(Accepted for publication January 8, 2007.)

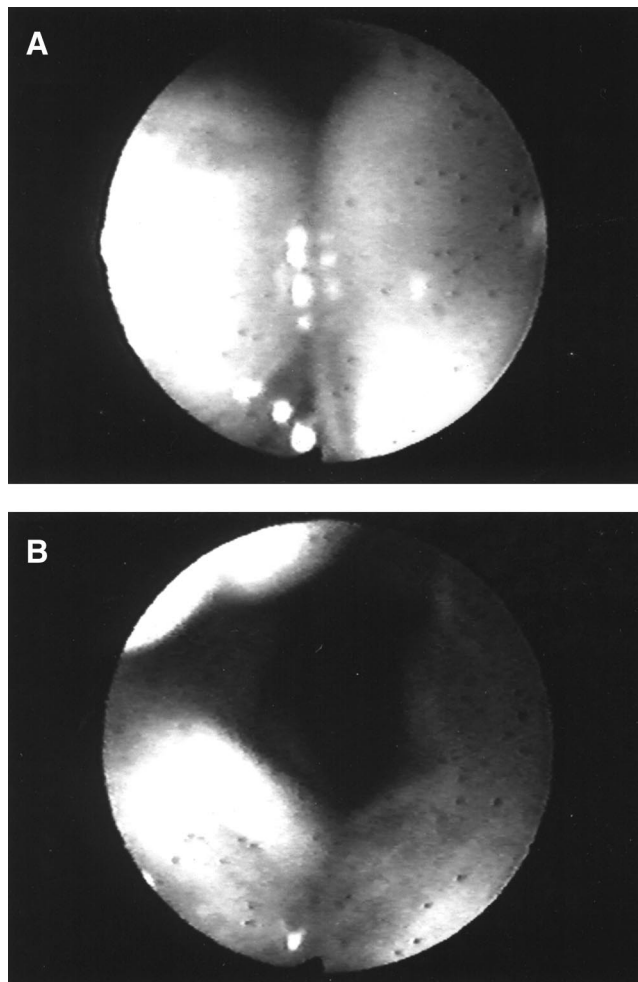
## Treatment of Supraglottic Airway Edema by Local Hyaluronidase

*To the Editor:*—The incidence of laryngeal edema after extubation is approximately 2–15%.<sup>1</sup> Supraglottic edema, which is one of the causes of failed extubation, is most often underdiagnosed because of its spontaneous regression.<sup>2</sup> However, in its severe form, it may necessitate reintubation and long-term airway care, associated with high morbidity. Hyaluronidase has been used in various clinical conditions to reduce tissue edema,<sup>3,4</sup> but its use to reduce supraglottic airway edema has not previously been reported. Over the past 5 yr, we used hyaluronidase to relieve airway obstruction caused by supraglottic edema that interfered with extubation of the tracheostomy in seven patients with neurologic disease. These patients were receiving ventilatory support *via* oral or nasal endotracheal tube and tracheostomy tube for 19 days (range, 10–28 days) and 21 days (range, 10–56 days), respectively. Five patients underwent a tracheostomy as an elective procedure for their poor neurologic condition, and two patients required tracheostomy because of stridor after extubation, which did not respond to medical treatment. When the patients were considered ready for decannulation, the tracheostomy tube was reduced to a smaller size for a few days followed by attempted occlusion. Attempt at tracheostomy tube occlusion was considered as failed when the patient developed stridor or paradoxical breathing immediately or within a few hours of occlusion.

All of the patients received intravenous injection of 4 mg dexamethasone 8 hourly and oral trypsin-chymotrypsin (Chymoral forte®, a combination of 100,000 Armour units of enzymatic activity of trypsin and chymotrypsin in the ratio of 6:1; Elder Pharma, Maharashtra, India) 8 hourly for 3 days before the trial of tracheostomy occlusion. All patients underwent a diagnostic bronchoscopy when extubation failed. The major finding in all of the patients was supraglottic airway edema, which narrowed the laryngeal inlet (fig. 1A). The arytenoids, supraglottic area, and vocal cords were edematous. Five patients had no pathology in the subglottic region, at the tracheostomy stoma or up to the tracheal bifurcation. Subglottic suprastomal edema was seen in one patient. One patient had severe subglottic stenosis. On occlusion of the tracheostomy tube during bronchoscopy, the edematous tissue in the supraglottic area caved in, narrowing the laryngeal inlet further.

After the diagnosis of supraglottic edema, a direct laryngoscopy was performed. Freshly prepared hyaluronidase solution of 750 U in 1 ml was injected into the submucosal tissue of the edematous supraglottic area, using a 10-cm-long, 23-gauge spinal needle. All patients received one injection of 750 U hyaluronidase. The dose of hyaluronidase varies in different clinical situations. A total dose of up to 300 U has been used to relieve edema in paraphimosis. In our patients, considering the severity of the edema, a total dose of 750 U was used. In a recent case report, a dose of 1,500 U was used in the treatment of extensive edema to facilitate reduction of intussusception.<sup>4</sup> In one patient who had subglottic suprastomal edema, hyaluronidase was injected into the subglottic tissue using a transtracheal approach under direct vision through the bronchoscope. Fiberoptic bronchoscopy was repeated 24–48 h after hyaluronidase injection. Occlusion of the tracheostomy tube was attempted when there was bronchoscopic evidence of resolution of the edema. Repeat bronchoscopy 24–48 h after the injection of hyaluronidase showed a significant reduction of the supraglottic airway edema (fig. 1B). On occlusion of the tracheostomy tube, all patients except one could breathe comfortably around the tube. One patient with

Support was provided solely from institutional and/or departmental sources.



**Fig. 1.** Bronchoscopic view in a patient showing severe laryngeal inlet edema obstructing the airway before injection of hyaluronidase (A) and resolution of edema 48 h after hyaluronidase injection (B).

severe subglottic narrowing could not tolerate the occlusion and required the tracheostomy tube to be left *in situ*. Occlusion of the tracheostomy tube could be started within 48 h of hyaluronidase injection in six patients, and decannulation was successful over the next 24–48 h in five patients. One patient died before decannulation due to causes unrelated to airway compromise. Tracheostomy occlusion failed in one patient with severe subglottic stenosis; this patient required a surgical correction later.

Prolonged tracheal intubation and tracheostomy predispose to laryngotracheal stenosis.<sup>5</sup> The major abnormalities commonly reported after prolonged tracheal intubation or tracheostomy are glottic stenosis, granulomas, subglottic stenosis, and tracheomalacia.<sup>6,7</sup> Supraglottic edema as the primary cause of failed tracheostomy tube decannulation is rarely reported. In our patients, we proved by bronchoscopy that supraglottic airway edema was solely responsible for failed decannulation in five of the seven patients.

In a series of pediatric patients, Cotton and Myer<sup>8</sup> showed that the first bronchoscopy, performed to examine the cause for failed extubation, showed supraglottic airway narrowing. The cause for

supraglottic narrowing could be multifactorial: intubation trauma, tube-tissue interface in the posterior larynx, coughing on the tube due to inadequate sedation or persistent hypotension. These factors result in trauma to the tracheal mucosa at the tube-tissue interface resulting in airway edema.<sup>9</sup>

Conservative treatment of supraglottic edema in the acute phase generally consists of corticosteroids and epinephrine nebulization. Many studies, however, did not demonstrate the efficacy of corticosteroids in this setting.<sup>10-12</sup> In our series also, the patients developed stridor despite dexamethasone therapy for 72 h before attempted tracheostomy closure. When our patients did not respond to conservative management including corticosteroids, we used hyaluronidase for its ability to increase the membrane permeability and promote resorption of the edema fluid.

Allergic reactions and angioedema after hyaluronidase injection have been reported. Most of these reports are related to its use in ophthalmic surgery.<sup>13,14</sup> None of our patients had any such complications of hyaluronidase. Hyaluronidase is not indicated in the presence of local infection because this may facilitate spread of infection. The usefulness of hyaluronidase in reducing the airway edema has not been previously reported. Hyaluronidase may not be useful in patients who have permanent structural damage with fibrosis as the underlying pathology, as it happened in one of our patients.

In conclusion, our case series indicates that failure of extubation or tracheostomy decannulation could result from supraglottic edema. Local hyaluronidase injection may be considered an option to treat this form of airway edema when other medical measures have failed.

**Keshavan H. Venkatesh, M.D., D.N.B.,\* Ganne S. Umamaheswara Rao, M.D.** \*National Institute of Mental Health Neurosciences, Bangalore, India. venkynimhans@rediffmail.com

## References

1. Burns HP, Dayal VS, Scott A, Van Nostrand AW, Bryce DP: Laryngotracheal trauma: Observations on its pathogenesis and its prevention following prolonged OT intubation in adult. *Laryngoscope* 1979; 89:1316-25
2. Law JH, Barnhart MS, Rowlett W, de la Rocha O, Lowenberg S: Increased frequency of obstructive airway abnormalities with long term tracheostomy. *Chest* 1993; 104:136-8
3. DeVries CR, Miller AK, Packer MG: Reduction of paraphimosis with hyaluronidase. *Urology* 1996; 48:464-5
4. McGuire B, Brannigan AE, O'Connell PR: Hyaluronidase assisted reduction of intestinal intussusception: A novel application. *Ir Med J* 2005; 98:146-7
5. Stauffer JL, Olson DE, Petty TK: Complication and consequences of endotracheal intubation and tracheostomy: A prospective study of 150 critically ill adult patients. *Am J Med* 1981; 70:65-76
6. Bryant LR, Trinkel JK, Dubilier L: Reappraisal of tracheal injury from cuffed tracheostomy tubes. *JAMA* 1971; 215:625-8
7. Kastanos N, Estopa MR, Marin Perez A, Xaubert Mir A, Aquisti-Vidal A: Laryngotracheal injury due to endotracheal intubation: incidence, evolution, and predisposing factors: A prospective long-term study. *Crit Care Med* 1983; 11:362-7
8. Cotton RT, Myer CM: Contemporary surgical management of laryngeal stenosis in children. *Am J Otolaryngol Head Neck Surg* 1984; 5:360-8
9. Whited RE: Prospective study of laryngotracheal sequelae in long-term intubation. *Laryngoscope* 1984; 94:367-77
10. Anene O, Meert KL, Uy H, Simpson P, Sarnaik AP: Dexamethasone for the prevention of postextubation airway obstruction: A prospective, randomized, double-blind, placebo-controlled trial. *Crit Care Med* 1996; 24:1666-9
11. Ho LI, Harn HJ, Lien TC, Hu PY, Wang JH: Postextubation laryngeal edema in adults: Risk factor evaluation and prevention by hydrocortisone. *Intensive Care Med* 1996; 22:933-6
12. Darmon JY, Rauss A, Dreyfuss D, Bleichner G, Elkharrat D, Schlemmer B, Tenailon A, Brun-Buisson C, Huet Y: Evaluation of risk factors for laryngeal edema after tracheal extubation in adults and its prevention by dexamethasone: A placebo-controlled, double-blind, multicenter study. *ANESTHESIOLOGY* 1992; 77:245-51
13. Agarwal A, McLure HA, Dabbs TR: Allergic reaction to hyaluronidase after peribulbar injection. *Anaesthesia* 2003; 58:493-4
14. Eberhart AH, Weiler CR, Eric JC: Angioedema related to the use of hyaluronidase in cataract surgery. *Am J Ophthalmol* 2004; 138:142-3

(Accepted for publication January 25, 2007.)

Anesthesiology 2007; 106:1255-6

Copyright © 2007, the American Society of Anesthesiologists, Inc. Lippincott Williams & Wilkins, Inc.

## Airway Obstruction due to Cuff Herniation of a Classic Reusable Laryngeal Mask Airway

*To the Editor:*—We report a 59-yr-old woman (height, 160 cm; weight, 58 kg) scheduled to undergo knee arthroscopy during general anesthesia. We used a reusable size 4 *Laryngeal Mask Airway Classic™* (*LMA™*; The Laryngeal Mask Company, Henley-on-Thames, United Kingdom) as an airway device. Before insertion of the *LMA™*, the cuff was inflated with 20 ml of air and totally deflated for confirmation of adequate function as recommended by the manufacturer. No problems were detected at this time. Anesthesia was induced with 0.1 mg fentanyl and 150 mg propofol. Insertion of the *LMA™* was easy, and ventilation was sufficient after one attempt. Anesthesia was maintained with desflurane and remifentanyl, and the lungs were ventilated with an oxygen-air mixture (fraction of inspired oxygen 0.5). A tidal volume of 420 ml was administered *via* controlled mechanical ventilation with a peak airway pressure of 14 mbar. Twenty minutes after insertion of the *LMA™*, an airway leak occurred. The anesthesiologist inflated the cuff of the *LMA™* with an additional 10 ml of air, postulating a leak due to insufficient inflation of the cuff. Directly thereafter, ventila-

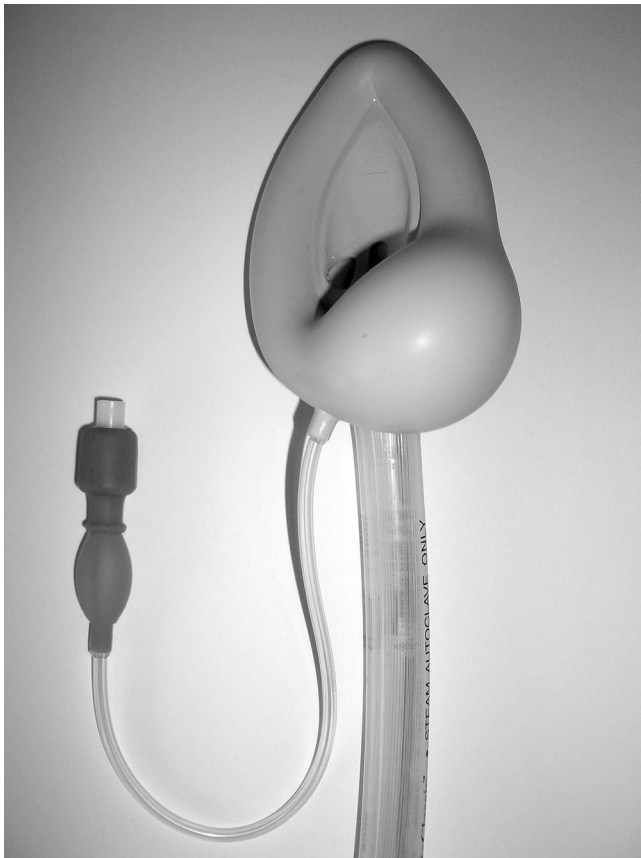tion was impossible. Consequently, the *LMA™* was totally deflated, removed from the pharynx, and reinserted. Once again, ventilation was impossible after reinflating the cuff of the *LMA™* with 20 ml of air. Finally, the *LMA™* was removed and tracheal intubation was performed. Inspection of the *LMA™* revealed a cuff hernia (fig. 1 with inflated and fig. 2 with deflated cuff) that did not exist before the first insertion when the cuff was checked by the anesthesiologist.

Another case of herniation with the *LMA™* airway was reported with a disposable *LMA™*,<sup>1</sup> where plastic layers between the inflated cuffs had separated and resulted in a herniation. In this case, the airway obstruction developed over 1.5 h. In our case, the obstruction occurred suddenly after inflation of additional air into the cuff. Here, fatigue of material due to repeated sterilization is the most likely cause. The manufacturer advises in the instruction manual not to use silicon-based lubricants and to use an *LMA™* cuff deflator before sterilization to prevent cuff hernia. However, we used solely water as a lubricant, and sterilization was performed as recommended by the manufacturer.

Therefore, if ventilation is not possible with a reusable *LMA™* airway, particularly after repeated sterilization, a herniated cuff should be considered, even if initial testing was inconspicuous.

Support was provided solely from institutional and/or departmental sources.

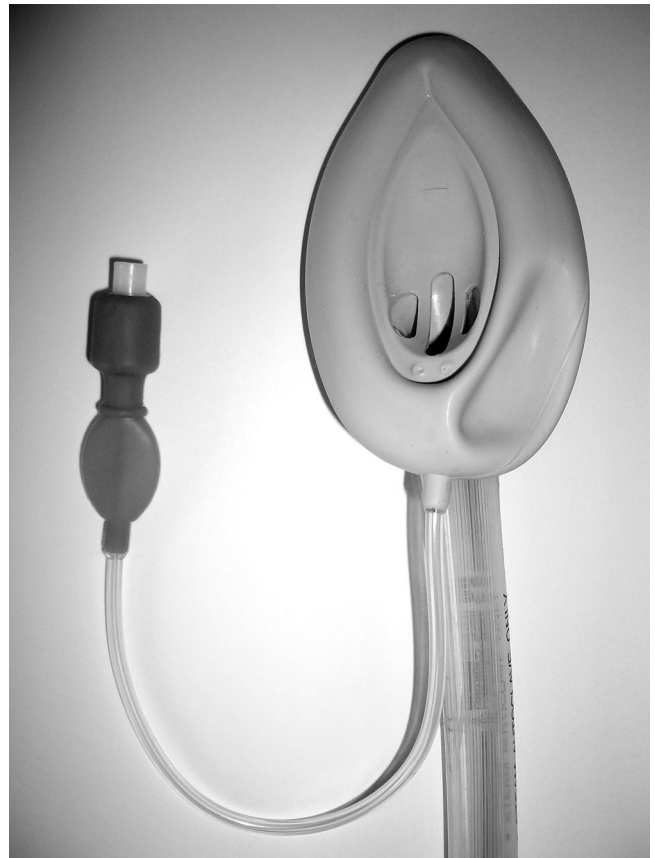The above letter was sent to the manufacturer for reply. The manufacturer did not feel that a response was necessary.—James C. Eisenach, M.D., Editor-in-Chief



**Fig. 1.** Laryngeal mask airway with inflated cuff.

Removal of the LMA™ and inspection of the cuff should be considered to rule out this potentially deleterious technical problem.

**Marc Wrobel, M.D.,\* Stephan Ziegler, M.D., Ulrich Grundmann, M.D.** \*University of Saarland, Homburg/Saar, Germany.  
marc.wrobel@uniklinikum-saarland.de



**Fig. 2.** Laryngeal mask airway with deflated cuff.

## Reference

1. England AJ: Respiratory obstruction secondary to laryngeal mask failure. *Anaesthesia* 2004; 59:1030-1

*(Accepted for publication January 25, 2007.)*