

# Craniocervical Motion during Direct Laryngoscopy and Orotracheal Intubation with the Macintosh and Miller Blades

## An In Vivo Cinefluoroscopic Study

Scott A. LeGrand, M.D.,\* Bradley J. Hindman, M.D.,† Franklin Dexter, M.D., Ph.D.,‡ Julie B. Weeks, M.P.T.,§ Michael M. Todd, M.D.||

**Background:** Previous studies have characterized segmental craniocervical motion that occurs during direct laryngoscopy and intubation with a Macintosh laryngoscope blade. Comparable studies with the Miller blade have not been performed. The aim of this study was to compare maximal segmental craniocervical motion occurring during direct laryngoscopy and orotracheal intubation with Macintosh and Miller blades.

**Methods:** Eleven anesthetized and pharmacologically paralyzed patients underwent two sequential orotracheal intubations, one with a Macintosh blade and another with a Miller in random order. During each intubation, segmental craniocervical motion from the occiput to the fifth cervical vertebra (C5) was recorded using continuous lateral cinefluoroscopy. Single-frame images corresponding to the point of maximal cervical motion for both blade types were compared with a preintubation image. Using image analysis software, angular change in the sagittal plane at each of five intervertebral segments was compared between the Macintosh and Miller blades.

**Results:** Extension at occiput–C1 was greater with the Macintosh blade compared with the Miller ( $12.1^\circ \pm 4.9^\circ$  vs.  $9.5^\circ \pm 3.8^\circ$ , respectively; mean difference =  $2.7^\circ \pm 3.0^\circ$ ;  $P = 0.012$ ). Total craniocervical extension (occiput–C5) was also greater with the Macintosh blade compared with the Miller ( $28.1^\circ \pm 9.5^\circ$  vs.  $23.2^\circ \pm 8.4^\circ$ , respectively; mean difference =  $4.8^\circ \pm 4.4^\circ$ ;  $P = 0.008$ ).

**Conclusions:** Compared with the Macintosh, the Miller blade was associated with a statistically significant, but quantitatively small, decrease in cervical extension. This difference is likely too small to be important in routine practice.

DURING direct laryngoscopy and orotracheal intubation, forces applied by the laryngoscope blade cause simultaneous displacement of the tongue and epiglottis and craniocervical extension,<sup>1</sup> creating a line of sight between the superior aspect of the oral cavity and the glottic inlet. Previous studies using a Macintosh laryngoscope blade have shown craniocervical extension during intubation is greatest between the occiput and first cervical vertebra (C1) and between C1 and C2,<sup>1-3</sup> with relatively little extension in subaxial segments. Subsequently, numerous studies have characterized craniocervical motion during intubation with alternative airway devices such as the Bullard laryngoscope,<sup>2-4</sup> intubating laryngeal mask,<sup>4-6</sup> light wand,<sup>7</sup> and other devices.<sup>4,6-8</sup> Surprisingly, despite the widespread use of the Miller laryngoscope blade, craniocervical motion during intubation with a Miller blade has not been well characterized. Previous studies have used only surrogate measures of spine motion, such as vertebral body displacement in the anterior–posterior plane,<sup>9-11</sup> distance between spinous processes,<sup>9,11</sup> or external head/neck extension angles<sup>12</sup>; none have measured segmental craniocervical motion during intubation. Because of differing blade design and application of forces, there could be meaningful differences between the Macintosh and Miller blades in the location and/or magnitude of craniocervical motion that occurs during intubation. Therefore, the aim of this study was to measure and compare maximal segmental craniocervical motion occurring during direct laryngoscopy and orotracheal intubation with Macintosh and Miller blades.

This article is accompanied by an Editorial View. Please see: Lanier WL: Developing and exercising the language of airway management. ANESTHESIOLOGY 2007; 107:867-8.

Additional material related to this article can be found on the ANESTHESIOLOGY Web site. Go to <http://www.anesthesiology.org>, click on Enhancements Index, and then scroll down to find the appropriate article and link. Supplementary material can also be accessed on the Web by clicking on the "ArticlePlus" link either in the Table of Contents or at the top of the Abstract or HTML version of the article.

\* Resident, Department of Anesthesia and Critical Care, Massachusetts General Hospital, Harvard Medical School, Boston, Massachusetts. † Professor and Vice-Chair (Faculty Development), ‡ Professor, § Research Assistant, || Professor and Head, Department of Anesthesia, University of Iowa Roy J. and Lucille A. Carver College of Medicine.

Received from the Department of Anesthesia, University of Iowa Roy J. and Lucille A. Carver College of Medicine, Iowa City, Iowa. Submitted for publication February 16, 2007. Accepted for publication June 12, 2007. Supported in part by a Doris Duke Clinical Research Fellowship for Medical Students, New York, New York (to Dr. LeGrand). Other support was provided by the Department of Anesthesia, The University of Iowa Roy J. and Lucille A. Carver College of Medicine, Iowa City, Iowa. Portions of this work were presented in abstract form at the Doris Duke Clinical Research Fellowship Meeting, Cold Spring Harbor, New York, June 24-26, 2003. This work was also presented in part at the Annual Meeting of the American Society of Anesthesiologists, Las Vegas, Nevada, October 13, 2003, and published in abstract form (LeGrand SA, Hindman BJ, Todd MM, Brian JE: The influence of straight versus curved laryngoscope blades on cervical spine motion during endotracheal intubation. ANESTHESIOLOGY 2003; 99:A353).

Address correspondence to Dr. Hindman: Department of Anesthesia, University of Iowa Hospitals and Clinics, Iowa City, Iowa 52242. [brad-hindman@uiowa.edu](mailto:brad-hindman@uiowa.edu). Information on purchasing reprints may be found at [www.anesthesiology.org](http://www.anesthesiology.org) or on the masthead page at the beginning of this issue. ANESTHESIOLOGY's articles are made freely accessible to all readers, for personal use only, 6 months from the cover date of the issue.

## Materials and Methods

### Subjects

This study was conducted in accordance with guidelines set forth by the University of Iowa Institutional

Review Board for Human Subjects and Medical Radiation Protection Committee, Iowa City, Iowa. All patients gave written informed consent before participation.

Previous studies had shown that intervertebral segmental motion (extension) during intubation with the Macintosh blade is greatest at occiput-C1, approximately  $10^\circ \pm 5^\circ$  (mean  $\pm$  SD).<sup>1-3</sup> We hypothesized that a 40-50% difference in extension (*i.e.*,  $4^\circ$ - $5^\circ$ ) at this segment could be potentially clinically significant. Using paired data, approximately 12 patients were required to detect a  $4^\circ$ - $5^\circ$  difference (two-sided test,  $\alpha = 0.05$ ,  $1 - \beta = 0.80$ ). Of the initial 12 patients studied, data from three were rejected because of inadequate image quality (see Data Acquisition, Processing, and Image Analysis). Therefore, with institutional review board approval, an additional 2 patients were enrolled, for a total of 14 patients.

Patients were adults (American Society of Anesthesiologists physical status I or II) scheduled to undergo elective spine surgery in which lateral fluoroscopy was to be used during the procedure (anterior cervical,  $n = 13$ ; posterior lumbar,  $n = 1$ ). All patients were free of myelopathic symptoms. Preoperative head and neck mobility were clinically unrestricted. Patients were excluded if they had (1) radiologic abnormalities of the cervical spine that precluded direct laryngoscopy (*e.g.*, anatomic instability, severe stenosis, or severe immobility), (2) a body habitus that seemed likely to interfere with radiographic visualization of the cervical spine, and/or (3) any other contraindication to direct laryngoscopy. After consenting to participate, patients were assigned a study identification number. Thereafter, a sealed opaque envelope with a matching identification number was opened a few minutes before induction. The envelope contained a card indicating the randomized order of laryngoscope blades that were to be used during two sequential intubations. Either (1) the first intubation was to be performed with a Macintosh blade and the second was to be performed with a Miller or (2) the first intubation was to be performed with a Miller blade and the second was to be performed with a Macintosh.

#### *Intubation Protocol*

Each patient was supine on a flat operating table with the occiput resting on a 7-cm semicompressible pad. After initiation of standard respiratory and hemodynamic monitoring and preoxygenation, general anesthesia was induced with intravenous thiopental or propofol, and mask ventilation was established without the use of either oral or nasal airways. Patients' lungs were ventilated with either isoflurane or sevoflurane in oxygen. Neuromuscular blockade was achieved by intravenous vecuronium or rocuronium.

After an adequate depth of anesthesia was established and after disappearance of the fourth twitch of the train-of-four, lateral fluoroscopy was used to obtain a baseline

still image of the cervical spine and occiput. This initial, preintubation, baseline image (baseline 1) was obtained after removing the ventilating mask and after allowing the head and neck to assume an unsupported midline resting position.

After obtaining baseline image 1, the first of two direct laryngoscopies and oroendotracheal intubations were performed according to the assigned order. One intubation was performed with a Miller 2 blade, and the other intubation was performed with a Macintosh 3 (one patient required a Macintosh 4). After the first intubation (intubation 1), correct endotracheal tube position was verified, and the patient was ventilated with a volatile anesthetic in oxygen. If needed, anesthetic medications were administered and/or adjusted before the second intubation. When hemodynamically stable and when adequately oxygenated and ventilated, the patient was extubated, and mask ventilation was resumed. A second baseline image (baseline 2) was obtained after removal of the ventilating mask, again allowing the head and neck to assume an unsupported midline resting position. Thereafter, the second intubation was performed (intubation 2). After the second intubation, correct endotracheal tube position was verified, and the protocol was completed. Surgery then proceeded.

In each patient, each of the two intubations was performed by the same faculty anesthesiologist. Four experienced anesthesiologists participated, all of whom were facile with both Macintosh and Miller blades. All intubations were performed without the use of any external airway manipulations such as cricoid pressure or laryngeal lift. Anesthesiologists were instructed to obtain glottic exposure that was sufficient to reliably insert the endotracheal tube. With the Macintosh blade, the distal tip of the laryngoscope blade was placed in the vallecula, followed by application of anterior- and slightly inferior-directed force to indirectly elevate the epiglottis and expose the glottis. With the Miller blade, the tip of the laryngoscope blade was placed posterior and slightly distal to the posterior surface of the epiglottis, followed by a largely anterior- and slightly superior-directed force so as to directly elevate the epiglottis and expose the glottis. After each intubation, the anesthesiologist rated the extent of glottic visualization using the four-point scale and diagram of Cormack and Lehane: 1 = most of the glottis visible; 2 = only the posterior aspect of the glottis visible (at least the arytenoids); 3 = no part of the glottis seen, but epiglottis seen; 4 = not even the epiglottis exposed.<sup>13</sup> During all intubations, the occiput remained in contact with the foam pad, but there was no other restriction of head or neck movement. Patients were intubated with either a 7.0- or 7.5-mm-ID wire-reinforced endotracheal tube (Mallinckrodt Incorporated, St. Louis, Missouri) containing a removable inner wire stylet. Stylets and wire-reinforced tubes were used

to aid visualization of the endotracheal tube on fluoroscopic images.

#### *Data Acquisition, Processing, and Image Analysis*

Each laryngoscopy and intubation sequence was monitored with continuous lateral fluoroscopy of the cervical spine (OEC models 9000 and 9800; OEC Diasonics, Salt Lake City, UT), affording visualization of the skull base, craniocervical junction, and cervical vertebrae through C5. Cervical vertebrae caudal to C5 could not be visualized in all patients because they were obscured by the shoulders. Exposure was adjusted to optimize visualization of the cervical spine with the autoexposure function of the fluoroscopy unit disabled to provide uniform exposure conditions. The fluoroscope was stationary throughout all imaging sessions. The tube-to-patient and patient-to-image intensifier distances were constant throughout all imaging sessions. Real-time analog fluoroscopic images were converted to digital format using a Dazzle Hollywood DV-Bridge (SCM Microsystems, Fremont, CA) and recorded on a laptop computer using digital video software (iMovie; Apple Computer, Cupertino, CA). Additional information regarding this is available on the ANESTHESIOLOGY Web site at <http://www.anesthesiology.org>.

Because of incomplete roentgenographic visualization of the cervical spine ( $n = 2$ ) and poor image quality ( $n = 1$ ), images from 3 of 14 patients could not be analyzed.

Digital cinefluoroscopic images were reviewed off-line by an investigator assigned to create masked and coded images for subsequent image analysis. First, this investigator reviewed the entire laryngoscopy and intubation sequence of each patient's two intubations. A previous study from our group showed that cervical spine movement during laryngoscopy and intubation was maximal during the interval from when the endotracheal tube was seen to enter the posterior oropharynx to the point of glottic intubation.<sup>1</sup> Accordingly, from each of the two intubation sequences, this investigator selected a single still image where endotracheal tube position corresponded to this point of maximal cervical spine motion, usually when the endotracheal tube was just superior to the glottic inlet. Thereafter, to conceal the laryngoscope blade and endotracheal tube on the image, this investigator digitally masked each of the four still images derived from each patient (baseline 1, intubation 1, baseline 2, intubation 2) (Photoshop; Adobe Systems, San Jose, CA). Masking was performed by overlaying an opaque white rectangle of uniform size over portions of the image that revealed the presence and/or type of laryngoscope blade. Because these regions were always in the anterior part of the image, masking did not obscure the occiput or cervical spine.

For each patient, the four masked images were kept grouped together as a set, but, for subsequent image analysis, both patient identity and image sequence (*i.e.*, whether the image corresponded to baseline 1, intuba-

tion 1, and so on) were coded. Using the masked and coded images, spine motion analysis was performed completely independently by two observers using image analysis software (Scion Image 4.02 Beta; Scion Corporation, Frederick, MD). In each set of four masked images, the position of each bony structure (occiput, C1, C2, C3, C4, and C5) in two dimensions (lateral view) was defined by a line formed between two anatomic reference points. As much as possible, each observer selected reference points that included points on the anterior and posterior aspect of each bony structure. Owing to variations in anatomy and image quality, the precise location of reference points varied between observers and among patients. However, care was taken to assure that, for each bony structure, identical reference points were selected on each of the four masked images of a given set. Therefore, each image had a total of six paired reference points corresponding to the occiput and C1-C5.

After all reference points for an image set were selected, each observer measured the angle formed between the line connecting each pair of reference points and a horizontal line. The difference in this angle's value between that obtained at the initial preintubation baseline (baseline 1) and subsequent images (intubation 1, baseline 2, intubation 2) was equal to the angular rotation in the sagittal plane of each bony structure compared with the initial preintubation position (*i.e.*, relative to baseline 1). Cephalad rotations were assigned a positive value, and caudal rotations were assigned a negative value. These angle changes constitute the absolute rotational movement of each bony structure in the sagittal plane, independent of the motion of adjacent vertebrae.

Then, to calculate the degree of motion that occurred between adjacent bony structures (*i.e.*, intervertebral angle changes), angular changes for adjacent levels were combined mathematically (the angular change of the cephalad structure minus the angular change of the caudad structure). Accordingly, positive values correspond to intervertebral extension, whereas negative values correspond to flexion. Therefore, for each of five intervertebral segments (occiput-C1, C1-C2, and so on), as well as for the entire cervical spine (occiput-C5), intervertebral motion relative to the initial preintubation baseline (baseline 1) was measured for each of the three subsequent images (intubation 1, baseline 2, intubation 2). Values for intervertebral motions derived from each of the two independent observers were combined to obtain mean values, which were used for subsequent statistical analysis.

To quantify intraobserver measurement variation in intervertebral angle changes, images from 3 of the 11 patients were duplicated but were assigned different codes. Hence, each observer received a total of 14 sets of coded and masked images (8 patients with one image set per patient, and 3 patients with two image sets per patient). This process created a total of 45 intraobserver comparisons for

each of the two observers (3 duplicated patients  $\times$  5 intervertebral segments per patient  $\times$  3 angle changes per segment = 45 duplicated measurements). For each of the two observers, the difference between each of the 45 paired intervertebral angle changes was calculated. To quantify interobserver variation in intervertebral angle change measurement, the difference between the two observers in each of the 210 intervertebral angle changes was calculated (14 image sets  $\times$  5 segments/set  $\times$  3 angle changes/segment = 210 measures).

### Statistical Analysis

**Interobserver Differences.** Repeated-measures analysis of variance was used to determine whether interobserver differences ( $n = 210$ ) significantly varied with either experimental stage (e.g., Macintosh, Miller, baseline 2) or intervertebral segment (e.g., occiput-C1, C1-C2, and so on). The dependence of interobserver differences on the magnitude of intervertebral angle changes was assessed by the Spearman rank correlation coefficient. Calculations were performed using Systat 10.0 (Systat Software; Inc., San Jose, CA).

**Intervertebral Angle Changes.** At baseline 1, intervertebral angle changes were defined as  $0^\circ$ . The Wilcoxon signed rank test was used to determine whether intervertebral angle changes at baseline 2 differed from those at baseline 1. Because we anticipated that the two baseline positions would be equivalent, our original analysis plan was to use baseline 1 as the reference position for intubation 1 and baseline 2 as the reference position for intubation 2. However, as shown in the Results section, cervical spine position at baseline 2 differed significantly from that at baseline 1. To compare craniocervical motion between the Macintosh and Miller blades, a common baseline reference position was needed. Therefore, changes in spine motion with both intubations were referenced to baseline 1. The Wilcoxon signed rank test was also used to determine whether intervertebral angle changes from baseline 1 significantly differed between Macintosh and Miller blades. The effect of order (Macintosh first or Miller first) on these differences was determined by use of the Wilcoxon Mann-Whitney test. Analyses were performed using StatXact-6 (Cytel Software Corporation, Cambridge, MA).

$P$  values are two-sided and exact.  $P$  values of 0.05 or less were considered to be significant. All significant  $P$  values were also significant using corresponding parametric tests and *vice versa*. We report the more conservative distribution-free methods, because of our limited sample sizes and lack of previous knowledge of the statistical distributions.

## Results

All patients were intubated with both laryngoscope blades. There were no study-related complications. Be-

**Table 1. Patient Demographics and Preoperative Airway Characteristics**

Age, yr	46 $\pm$ 8 (44, 34–59)
Sex, n	
Male	6
Female	5
Height, m	1.74 $\pm$ 0.09 (1.79, 1.63–1.85)
Weight, kg	79 $\pm$ 14 (80, 55–102)
Body mass index, kg/m <sup>2</sup>	26.1 $\pm$ 5.2 (24.8, 20.8–38.6)
Mallampati class,* n	
I	10
II	0
III	0
IV	1
Interdental distance, cm	5.2 $\pm$ 1.0 (5.0, 4.0–7.0)
Thyromental distance, cm	5.9 $\pm$ 0.9 (6.0, 5.0–8.0)

Data are presented as mean  $\pm$  SD (median, range) unless otherwise indicated.

\* Mallampati oropharyngeal classification as modified by Samssoon and Young.<sup>14</sup>

cause of incomplete roentgenographic visualization of the cervical spine ( $n = 2$ ) or poor image quality ( $n = 1$ ), images from 3 patients were excluded from cervical spine motion analysis. All 3 of these patients had body mass indices exceeding 30 kg/m<sup>2</sup>, as compared with 2 of 11 patients in whom image analysis was feasible.

Demographic and preoperative airway characteristics of the 11 patients for whom spine motion analysis was conducted are summarized in table 1. Five patients were first intubated with the Macintosh blade, and 6 were first intubated with the Miller. There was no significant difference in glottic visualization between the Macintosh and Miller blades (Macintosh: grade 1 ( $n = 7$ ), grade 2 ( $n = 4$ ); Miller: grade 1 ( $n = 6$ ), grade 2 ( $n = 5$ ); with 8 of 11 patients having the same glottic view with both blades, 2 patients with a better view with the Macintosh, and 1 patient with a better view with the Miller).

Observer A had a mean intraobserver difference in intervertebral angle change equal to  $-0.2^\circ \pm 1.0^\circ$  (median =  $-0.3^\circ$ ). Observer B had a mean intraobserver difference in intervertebral angle change equal to  $0.0 \pm 2.0^\circ$  (median =  $0.1^\circ$ ). The mean interobserver difference in intervertebral angle change equaled  $0.1^\circ \pm 3.8^\circ$  (median =  $0.2^\circ$ ). Interobserver differences did not significantly vary with either the three experimental stages (e.g., Macintosh blade, Miller blade, baseline 2:  $F_{2,39} = 1.16$ ,  $P = 0.32$ ) or the five segments being analyzed (e.g., occiput-C1, C1-C2, and so on:  $F_{4,156} = 1.66$ ,  $P = 0.16$ ). Interobserver variation differed over the range of intervertebral angle changes ( $P < 0.001$ ) but was so small as to be clinically irrelevant. For the lower quintile of angle changes ( $0^\circ$ – $1.2^\circ$ ,  $n = 42$ ), the interobserver difference was  $-1.2^\circ \pm 3.1^\circ$  (median =  $-1.3^\circ$ ). For the upper quintile ( $7.0^\circ$ – $24.0^\circ$ ,  $n = 43$ ), the interobserver difference was  $2.0^\circ \pm 4.5^\circ$  (median =  $1.8^\circ$ ).

Cervical spine position at baseline 2 differed significantly from that at baseline 1, with a total of  $7.4^\circ \pm 5.0^\circ$  of extension from the occiput to C5 ( $P = 0.0076$ ). Individual intervertebral segments in which there was a significant

**Table 2. Intervertebral Angle Change Compared with Preintubation Baseline Position (Baseline 1)**

Experimental Stage	Occiput-C1	C1-C2	C2-C3	C3-C4	C4-C5	Occiput-C5
Intubation-Macintosh	12.1 ± 4.9	6.0 ± 5.3	3.9 ± 3.1	4.1 ± 3.7	1.8 ± 3.6	28.1 ± 9.5
Intubation-Miller	9.5 ± 3.8	5.5 ± 4.6	3.3 ± 3.4	4.0 ± 3.7	1.0 ± 2.9	23.2 ± 8.4
Macintosh/Miller difference	2.7 ± 3.0	0.6 ± 2.1	0.7 ± 1.6	0.1 ± 2.2	0.8 ± 2.6	4.8 ± 4.4
<i>P</i> value*	0.012	0.508	0.242	0.833	0.432	0.008

Data are presented as mean ± SD, in degrees.

\* Two-sided Wilcoxon signed rank test.

difference between baseline 1 and baseline 2 were occiput-C1 (3.1° ± 3.4° of extension; *P* = 0.010) and C1-C2 (2.1° ± 2.5° of extension; *P* = 0.025). Therefore, cervical spine extension occurring during intubation 1 was not completely reversed by subsequent extubation and reestablishment of mask ventilation and head position before intubation 2. For this reason, all motion data were referenced to baseline 1.

Intervertebral motion data, comparing Macintosh and Miller blades *versus* baseline 1, are summarized in table 2. With both blades, laryngoscopy and intubation resulted in extension at each of the five segments relative to baseline. Total craniocervical extension (occiput-C5) was greater with the Macintosh blade compared with the Miller (28.1° ± 9.5° *vs.* 23.2° ± 8.4°, respectively; mean difference = 4.8° ± 4.4°; *P* = 0.008). The difference between Macintosh and Miller blades did not vary with the order of intubation (*P* = 0.999). The occiput-C1 segment was the only individual intervertebral segment in which there was a significant difference

between Macintosh and Miller blades in the degree of extension (12.1° ± 4.9° *vs.* 9.5° ± 3.8°, respectively; mean difference = 2.7° ± 3.0°; *P* = 0.012). At occiput-C1, the difference between Macintosh and Miller blades did not depend on order of intubation (*P* = 1.000).

## Discussion

### Key Findings and Clinical Relevance

This study is the first to characterize segmental cranio-cervical motion during intubation with the Miller blade and to compare it with that occurring with the Macintosh. Table 3 shows that our values for maximum cranio-cervical motion (extension) during intubation with the Macintosh blade are consistent with previous studies. In this study, the Miller blade was associated with a statistically significant but quantitatively small decrease in cervical extension when compared with the Macintosh, on average 2.7° at occiput-C1 and 4.8° overall (occiput-C5). In a previous study using an external angle finder,

**Table 3. Previous Studies Quantifying Intervertebral Angle Change Compared with Preintubation Baseline Position during Orotracheal Intubation with a Macintosh 3 Blade**

Study	Patients, n	Preintubation Head Position	Glottic View	Occiput-C1	C1-C2	C2-C3	C3-C4	C4-C5	Occiput-C5
Hastings <i>et al.</i> <sup>2</sup>	8	Occiput on board	"Best possible"	12*	11*	4.8 ± 2.1†	6.9 ± 4.4†	NM	31*‡
Watts <i>et al.</i> <sup>3</sup>	29	Occiput on board	Grade 1 = 86%, grade 2 = 14%	11.4 ± 1.6	8.9 ± 1.1	§	§	§	25.9 ± 2.8
Sawin <i>et al.</i> <sup>1</sup>	10	Occiput on 3-cm pad	"Limited to that necessary to [intubate] under direct vision"	6.6	5.4	2.4	1.6	0.9	16.9  #
Rudolph <i>et al.</i> <sup>8</sup>	20	Occiput on table	Grade 1 = 40%, grade 2 = 25%, grade 3 = 35%	10 ± 2**	10 ± 3**	3 ± 2**	5 ± 3**	NM	28 ± 5‡**
Turkstra <i>et al.</i> <sup>7</sup>	36	Back on board, forehead taped to Mayfield horseshoe	That providing "a reasonable opportunity" to intubate	15 ± 7††	6.9 ± 5.2	††††	††††	††††	28.9#
Current study	11	Occiput on 7-cm pad	Grade 1 = 64%, grade 2 = 36%	12.1 ± 4.9	6.0 ± 5.3	3.9 ± 3.1	4.1 ± 3.7	1.8 ± 3.6	28.1 ± 9.5

Data are presented as mean ± SD, in degrees.

\* Only mean values reported in text. † Values for C2-C3 and C3-C4 interpolated from data shown in figure 4 of the article. ‡ Value for occiput-C4. § Values for C2-C3, C3-C4, and C4-C5 not individually reported. Value for C2-C5 was 5.5 ± 1.1. || Only mean values reported. # Value not reported. Value is sum of means.

\*\* Numerical values not reported in text. Values are interpolated from figures 4 and 5 of the article. †† Numerical value not reported in text. Value is interpolated from figure 3 of the article. ††† Values for C2-C3, C3-C4, and C4-C5 not individually reported. Value for C2-C5 was 7 ± 5.

NM = not measured.

Hastings *et al.*<sup>12</sup> observed that laryngoscopy with a Miller blade resulted in 3° less external head extension than a Macintosh blade. Our values are quantitatively similar to those of Hastings *et al.*, but reveal the difference between blade types is largely accounted for by less extension at occiput-C1 with the Miller blade.

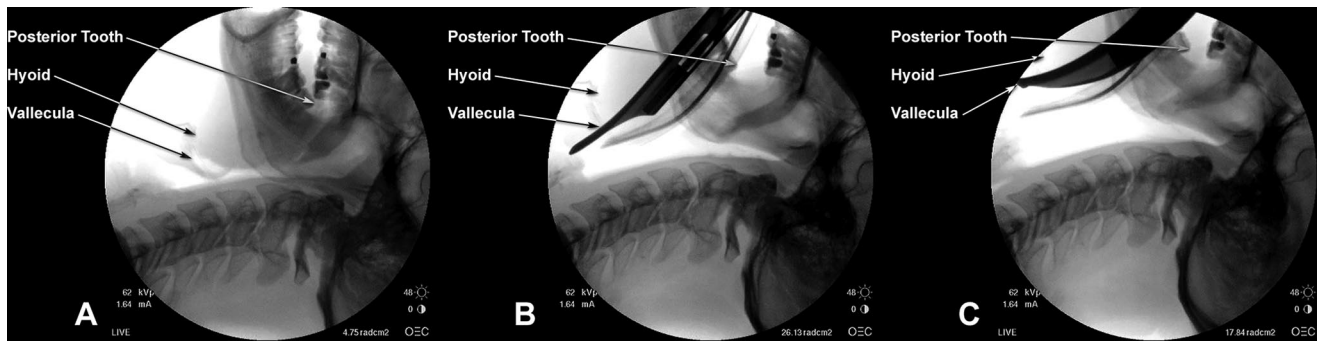
At each intervertebral segment, as well as overall, the difference between the Miller and Macintosh blades was less than the variation among patients. Therefore, in routine practice, the small difference between blades would be difficult to perceive against the background of normal interpatient variation. Because intubation with the Miller blade results in 15–20% less craniocervical extension to obtain the same glottic view as the Macintosh, it is possible that the Miller blade could be modestly advantageous in circumstances where neck mobility is less than normal and/or when minimization of craniocervical movement during intubation is desired. However, this potential advantage is entirely speculative because there are no randomized clinical trials showing the Miller blade to be superior to the Macintosh in either of these circumstances. In a cadaver model of a complete C5–C6 transection, Gerling *et al.*<sup>15</sup> reported that laryngoscopy with a Miller blade resulted in significantly less (1–2 mm) axial distraction at the unstable segment than with a Macintosh blade. However, in the same study, there were no differences between blades in anteroposterior subluxation or intervertebral extension at the unstable segment, although the study may have been underpowered. An accompanying editorial emphasized that the lesser cervical motion observed with the Miller blade was so small as to probably be clinically insignificant, even in the presence of an unstable spine.<sup>16</sup> Therefore, our study and others indicate that, although the Miller blade results in less craniocervical motion than the Macintosh, the difference is very small. When, if ever, such small differences might be clinically meaningful is not known.

#### *Mechanics of Direct Laryngoscopy and Tracheal Intubation*

All other factors being equal during laryngoscopy, the amount of craniocervical motion taking place will vary with how greatly preintubation head and neck position differs from that occurring with intubation. As an extreme example, suppose that, before intubation, the occiput and cervical spine were positioned in the same configuration as that occurring during intubation. In this circumstance, craniocervical motion during intubation would be zero. Therefore, the amount of spine motion that takes place during intubation necessarily depends on how the head, neck, and spine are initially positioned. Second, all other factors being equal, the degree of craniocervical extension required to create the line of sight varies, at least in part, with the degree of desired glottic visualization. This principle was demonstrated by

Hastings *et al.*,<sup>17</sup> who showed that, using a Macintosh blade, approximately 5° of greater head extension was necessary to visualize the entire glottis as opposed to only its posterior aspect. These two principles probably explain much of the variation present among previous studies that have quantified craniocervical motion during intubation with the Macintosh blade (table 3). However, these two principles do not explain the difference between the Macintosh and Miller blade observed in this study. First, in this study, preintubation head and neck position was radiographically defined (baseline 1) and was, for the purpose of measuring craniocervical motion, exactly the same for both intubations in each patient. Second, in this study, the degree of glottic visualization was equivalent between blade types; (see additional discussion in Limitations). Therefore, other mechanisms must be responsible for the lesser craniocervical extension associated with the Miller blade.

Another principle of intubation mechanics is, all other factors being equal, when the glottic inlet is positioned in a relatively posterior and/or cephalad position in the neck, lesser degrees of tissue displacement and/or craniocervical extension are required to achieve a line of sight. This concept is supported by studies showing that external laryngeal manipulation causing posterior and cephalad movement of the glottis in the neck improves glottic visualization.<sup>18–21</sup> Therefore, it is conceivable that the lesser craniocervical extension observed during intubation with the Miller blade could be on the basis of a difference in glottic position at intubation as compared with the Macintosh blade—with a relatively more posterior- and/or cephalad-oriented glottis with the Miller blade. To date, few studies have assessed how laryngoscopy and intubation change the position and anatomy of the larynx. Horton *et al.*<sup>22</sup> obtained lateral x-rays of the head and neck in conscious volunteers undergoing laryngoscopy with a Macintosh 3 blade. With laryngoscopy, the hyoid was displaced both anteriorly and caudad relative to the cervical spine. To explore the question of differential glottic position, we reviewed our cinefluoroscopy images. We observed that direct laryngoscopy resulted in an anterior and caudad displacement of the base of the epiglottis (vallecula) and hyoid relative to both the mandible and cervical spine in comparison with the preintubation (baseline 1) position. Because fluoroscopy exposure was set to optimize visualization of the cervical spine, in only a few patients was image quality sufficient to determine the position of the vallecula (n = 5) and/or hyoid (n = 3) throughout both intubation sequences relative to a fixed point on the mandible. However, in these patients, we observed that the vallecula was displaced more anteriorly (4 of 5; approximately 0.6–1.4 cm) and more caudally (5 of 5; approximately 0.6–3.4 cm) with the Macintosh blade compared with the Miller. The hyoid was also displaced more anteriorly (2 of 3; approximately 0.3–0.6 cm) and



**Fig. 1.** Still images for patient 13 at baseline 1 (A), intubation–Miller (B), and intubation–Macintosh (C). Compared with baseline, intervertebral motion (extension) with Miller and Macintosh blades was 2.7° and 7.0°, respectively, at occiput–C1; –0.4° and 2.2°, respectively, at C1–C2; and 14.1° and 22.4°, respectively, from the occiput to C5. The vallecula was displaced 1.4 cm more anteriorly and 1.7 cm more inferiorly with the Macintosh blade compared with the Miller. The hyoid was displaced 0.6 cm more anteriorly and 0.3 cm more inferiorly with the Macintosh compared with the Miller.

more caudally (3 of 3; 0.1–0.3 cm) with the Macintosh; an example is shown in figure 1. Therefore, these preliminary observations support but do not prove the hypothesis that laryngoscopy with Miller blade may result in a glottic position that is relatively less anterior and/or caudad than that which occurs with the Macintosh. Formal testing of this hypothesis deserves future study. If confirmed, this may explain, at least in part, why a lesser degree of craniocervical extension is required with the Miller blade.

A fourth principle of intubation mechanics is, all other factors being equal, either more effective tissue displacement, or a lesser volume of tissue to displace, should require lesser degrees of craniocervical extension to create a line of sight. Because the width of the Miller blade is approximately 50–60% of the width of the Macintosh, it displaces a lesser volume of tissue (tongue) during laryngoscopy. Hastings *et al.*<sup>12</sup> observed that, in addition to less external head extension with the Miller blade, applied lifting forces were also significantly less (30%) with the Miller blade as compared with the Macintosh. A possible explanation for these observations is that, with the Miller blade, the smaller volume of displaced tongue is more readily accommodated in the submandibular space, such that less lifting force is required. If the Miller blade is more likely to be successful in tissue displacement than the Macintosh (because it *requires* less tissue displacement), it should, therefore, obtain a better view of the glottis and/or require less craniocervical extension to create a line of sight. In separate studies, both Benumof *et al.*<sup>20</sup> and Arino *et al.*<sup>23</sup> observed that glottic visualization was significantly better with the Miller blade. Although Arino *et al.*<sup>23</sup> found that glottic visualization was significantly better with the Miller blade, paradoxically, they found ease of intubation was greater with the Macintosh. Apparently, although the Miller blade more often displaced tissue sufficient to visualize the entire glottis, this visual pathway was often too small to introduce the endotracheal tube with ease.

Finally, the preceding discussion of intubation me-

chanics has been based on the presumption that, with equivalent glottic position and visualization, the Macintosh and Miller blades would have precisely the same line of sight. However, that may not be the case. In a quantitative analysis of airway anatomy and laryngoscope design, Marks *et al.*<sup>24</sup> determined that, in the average adult, the line of sight along the Macintosh blade differs from the Miller by 2°–4° in the posterior direction. In essence, the curvature of the Macintosh blade acts as a visual “hill”—interrupting the line of sight. Therefore, to achieve the same glottic view with the Macintosh blade as with the Miller, either the tongue must be displaced slightly more into the submandibular space with the Macintosh or, if that cannot occur, an additional 2°–4° of craniocervical extension from the occiput to C4–C5 (the level of the glottic inlet) would be required. Therefore, rather than differences in tongue displacement and/or glottic position, another explanation for our findings may simply be that the curvature of the Macintosh blade requires approximately 3° of extra craniocervical extension to obtain the same view of the glottis as that with the Miller.

#### Limitations

The findings of this study must be considered while keeping several limitations in mind. First, this is a small study, involving few patients and even fewer anesthesiologists. Therefore, whether our findings are applicable to the more general patient population and anesthesia community is unknown. Because of the differences in head, neck, and airway anatomy between adults and children, our findings cannot be applied to the pediatric population. Likewise, patients who have anatomically unstable spines cannot be expected to exhibit the same craniocervical motion in response to the forces of laryngoscopy as do patients with stable spines. Therefore, it would not be safe to assume that the lesser extension observed with the Miller blade in this study would necessarily also result in less extension in the presence of

instability (e.g., patients with traumatic injury, trisomy 21, or rheumatoid arthritis).

Another limitation of this study relates to how glottic visualization was quantified. Because the Cormack and Lehane scale is categorical rather than continuous,<sup>13</sup> it is possible for different degrees of glottic visualization to receive the same score.<sup>25</sup> For example, visualization of the posterior 30% of the glottis and visualization of the posterior 5% of the glottis would both be scored as Cormack and Lehane grade 2. Use of a continuous scale, such as the percentage of glottic opening scale,<sup>26</sup> would have increased our ability to detect any difference in glottic visualization between blades. In addition, glottic visualization was not independently assessed but, rather, was reported by the anesthesiologist, who was aware of the blade being used. Bias on the part of the anesthesiologist could have altered perceptions and/or reports of glottic view. Therefore, an independent assessment of glottic view, without knowledge of blade type, would have increased objectivity. Such assessments are now possible with the use of a head-mounted video system that aligns with the laryngoscopist's line of sight and records glottic exposure as visualized by the laryngoscopist.<sup>27</sup> A recent study shows good intrarater and interrater agreement in glottic visualization scores with such a system.<sup>27</sup>

In summary, we observed that direct laryngoscopy and orotracheal intubation with a Miller blade resulted in 15–20% less craniocervical extension than with a Macintosh blade, on average approximately 3° less at occiput–C1 and approximately 5° less from the occiput to C5. These small differences are less than interpatient variation and are not likely to be of importance in most circumstances. Compared with the Macintosh, lesser extension with the Miller blade could be on the basis of differences in glottic position, tongue displacement, and/or line of sight along the blade. Additional studies are needed to confirm these observations and hypotheses.

The authors thank Luis Avila, M.D. (Wheaton Franciscan Hospital, Covenant Clinics Anesthesia, Waterloo, Iowa), Johnny E. Brian, M.D. (Anesthesia and Analgesia, P.C., Davenport, Iowa), and Robert From, D.O. (Associate Professor, University of Iowa Carver College of Medicine, Department of Anesthesia, Iowa City, Iowa), for their participation in this study. The authors also thank Koji Dairaku, M.D., Ph.D. (Physician, Yamaguchi University, Advanced Medical Emergency and Critical Care Center, Yamaguchi, Japan), for his translation of the article by Konishi *et al.*,<sup>11</sup> and Thomas C. Smith, B.S. (Web Applications Developer, University of Iowa Carver College of Medicine, Department of Anesthesia, Iowa City, Iowa), for creating figure 1.

## References

1. Sawin PD, Todd MM, Traynelis VC, Farrell SB, Nader A, Sato Y, Clausen JD, Goel VK: Cervical spine motion with direct laryngoscopy and orotracheal intubation: An *in vivo* cinefluoroscopic study of subjects without cervical abnormality. *ANESTHESIOLOGY* 1996; 85:26–36

2. Hastings RH, Vigil AC, Hanna R, Yang B-Y, Sartoris DJ: Cervical spine movement during laryngoscopy with the Bullard, Macintosh, and Miller laryngoscopes. *ANESTHESIOLOGY* 1995; 82:859–69
3. Watts ADJ, Gelb AW, Bach DB, Pelz DM: Comparison of the Bullard and Macintosh laryngoscopes for endotracheal intubation of patients with a potential cervical spine injury. *ANESTHESIOLOGY* 1997; 87:1335–42
4. Wahlen BM, Gercek E: Three-dimensional cervical spine movement during intubation using the Macintosh and Bullard™ laryngoscopes, the Bonfils fibroscope, and the intubating laryngeal mask airway. *Eur J Anaesthesiol* 2004; 21:907–13
5. Waltl B, Melischek M, Schusching C, Kabon B, Erlacher W, Nasel C, Fuchs M, Kapral S: Tracheal intubation and cervical spine excursion: Direct laryngoscopy *versus* intubating laryngeal mask. *Anaesthesia* 2001; 56:221–6
6. Sahin A, Salman MA, Erden A, Aypar U: Upper cervical vertebrae movement during intubating laryngeal mask, fiberoptic and direct laryngoscopy: A video-fluoroscopic study. *Eur J Anaesthesiol* 2004; 21:819–23
7. Turkstra TP, Craen RA, Pelz DM, Gelb AW: Cervical spine motion: A fluoroscopic comparison during intubation with lighted stylet, GlideScope, and Macintosh laryngoscope. *Anesth Analg* 2005; 101:910–5
8. Rudolph C, Schneider JP, Wallenborn J, Schaffranietz L: Movement of the upper cervical spine during laryngoscopy: A comparison of the Bonfils intubation fibroscope and the Macintosh laryngoscope. *Anaesthesia* 2005; 60:668–72
9. Majernick TG, Bieniek R, Houston JB, Hughes HG: Cervical spine movement during orotracheal intubation. *Ann Emerg Med* 1986; 15:417–20
10. Houswald M, Sklar DP, Tandberg D, Garcia JF: Cervical spine movement during airway management: Cinefluoroscopic appraisal in human cadavers. *Am J Emerg Med* 1991; 9:535–8
11. Konishi A, Sakai T, Nishiyama T, Higashizawa T, Bito H: Cervical spine movement during orotracheal intubation using the McCoy laryngoscope compared with the Macintosh and the Miller laryngoscopes [in Japanese]. *Masui* 1997; 46:124–7
12. Hastings RH, Hon ED, Nghiem C, Wahrenbrock EA: Force and torque vary between laryngoscopists and laryngoscope blades. *Anesth Analg* 1996; 82:462–8
13. Cormack RS, Lehane J: Difficult tracheal intubation in obstetrics. *Anaesthesia* 1984; 39:1105–11
14. Samsoun GLT, Young JRB: Difficult tracheal intubation: a retrospective study. *Anaesthesia* 1987; 42:487–90
15. Gerling MC, Davis DP, Hamilton RS, Morris GF, Vilke GM, Garfin SR, Hayden SR: Effects of cervical spine immobilization technique and laryngoscope blade selection on an unstable cervical spine in a cadaver model of intubation. *Ann Emerg Med* 2000; 36:293–300
16. Grossman D, Schriger DL: Immobilization technique and blade choice in the endotracheal intubation of trauma patients: Miller time or much ado about nothing? (editorial). *Ann Emerg Med* 2000; 36:351–3
17. Hastings RH, Wood PR: Head extension and laryngeal view during laryngoscopy with cervical spine stabilization maneuvers. *ANESTHESIOLOGY* 1994; 80:825–31
18. Krantz MA, Poulos JG, Chaouki K, Adamek P: The laryngeal lift: A method to facilitate endotracheal intubation. *J Clin Anesth* 1993; 5:297–301
19. Knill RL: Difficult laryngoscopy made easy with a “BURP.” *Can J Anaesth* 1993; 40:279–82
20. Benumof JL, Cooper SD: Quantitative improvement in laryngoscopic view by optimal external laryngeal manipulation. *J Clin Anesth* 1996; 8:136–40
21. Takahata O, Kubota M, Mamiya K, Akama Y, Nozaka T, Matsumoto H, Ogawa H: The efficacy of the “BURP” maneuver during a difficult laryngoscopy. *Anesth Analg* 1997; 84:419–21
22. Horton WA, Fahy L, Charters P: Disposition of cervical vertebrae, atlanto-axial joint, hyoid, and mandible during x-ray laryngoscopy. *Br J Anaesth* 1989; 63:435–8
23. Arino JJ, Velasco JM, Gasco C, Lopez-Timoneda F: Straight blades improve visualization of the larynx while curved blades increase ease of intubation: A comparison of the Macintosh, Miller, McCoy, Belscope and Lee-Fiberview blades. *Can J Anaesth* 2003; 50:501–6
24. Marks RRD, Hancock R, Charters P: An analysis of laryngoscope blade shape and design: New criteria for laryngoscope evaluation. *Can J Anaesth* 1993; 40:262–70
25. Yentis SM, Lee DJH: Evaluation of an improved scoring system for the grading of direct laryngoscopy. *Anaesthesia* 1998; 53:1041–4
26. Ochroch EA, Hollander JE, Kush S, Shofer FS, Levitan RM: Assessment of laryngeal view: percentage of glottic opening score *versus* Cormack and Lehane grading. *Can J Anaesth* 1999; 46:987–90
27. George RB, McKeen D, Law JA: Laryngoscopic evaluation with the Airway Cam® laryngoscopy video system. *Can J Anaesth* 2006; 53:512–5