

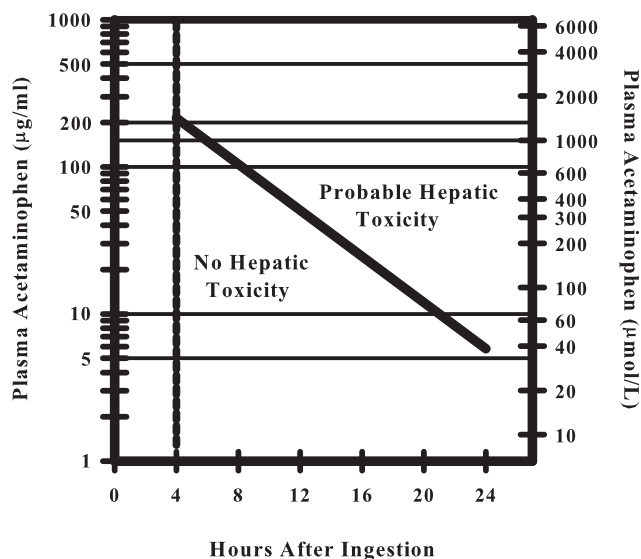
## Acetaminophen-induced, Not Desflurane-induced, Hepatotoxicity

*To the Editor:*—I believe that the case of hepatotoxicity after desflurane anesthesia in a 15-month-old child with Mobius syndrome after previous exposure to isoflurane,<sup>1</sup> reported by Drs. Côté and Bouchard, is not a case of desflurane-induced but acetaminophen-induced hepatotoxicity. Drs. Côté and Bouchard ignored that liver enzyme levels were too high for desflurane-induced hepatotoxicity, that the serum level of acetaminophen on the second postoperative day after multiple doses was high enough to induce hepatotoxicity, and that omeprazole is an inducer of the cytochrome P-450 enzymes (CYPs) CYP 1A2 and CYP 3A4, which increase oxidative metabolism of acetaminophen. They also ignored that cisapride increases the bioavailability of acetaminophen by inhibiting its glucuronidation in humans.

Cases of hepatotoxicity after isoflurane, enflurane, and desflurane anesthesia in the previous reports provided by Drs. Côté and Bouchard for references had increased liver enzymes, such as alanine aminotransferase and aspartate aminotransferase, and bilirubin, but none of the cases had a serum level of alanine aminotransferase or aspartate aminotransferase higher than 3,000 U/L, except one case in which the sample was taken after cardiac arrest.<sup>2</sup> The increased bilirubin level and jaundice were prominent in those cases. On the contrary, acute acetaminophen hepatotoxicity is characterized by marked increases in the aminotransferases, usually more than 3,000 U/L,<sup>3</sup> the bilirubin level is somewhat inconsistent in the correlation of degree of its increase to hepatic damage, and the onset of jaundice is delayed.<sup>4</sup> Therefore, the clinical feature seems to be acetaminophen toxicity.

The half-life of acetaminophen in healthy volunteers given high therapeutic doses is approximately 2 h. The half-life of acetaminophen in patients with hepatotoxicity is in excess of 4 h.<sup>3</sup> Single plasma levels of acetaminophen are not as reliable as plasma half-life. However, single plasma levels may be used with a Rumack-Matthew acetaminophen nomogram (fig. 1) as a rough prognostic guide.<sup>3,4</sup> In case of multiple doses of acetaminophen, the number of days from first ingestion for overdose and number of hours from last administration for therapeutic use (this information was not provided in the case report by Drs. Côté and Bouchard) should be taken into consideration when a single plasma level of acetaminophen is evaluated for possible toxicity. In a child who developed severe hepatotoxicity necessitating liver transplantation, the plasma level of acetaminophen was reported to be 66  $\mu\text{M}$  on admission to the emergency department 3 days after first ingestion of multiple overdoses of acetaminophen, which had been taken for 2 days.<sup>5</sup> In another pediatric patient, who developed hepatotoxicity with stage 2 encephalopathy, the plasma level of acetaminophen was 152  $\mu\text{M}$  on admission 2 days after first ingestion of multiple overdoses of acetaminophen, which had been taken for 1 day.<sup>5</sup> In the case report by Drs. Côté and Bouchard, the plasma level of acetaminophen of 210  $\mu\text{M}$  on the second postoperative day after multiple therapeutic doses was very high and high enough to induce hepatotoxicity, and their statement that "the acetaminophen level was in the therapeutic range" was not correct. Acetaminophen is excreted rapidly, even in patients with liver damage. If the plasma acetaminophen level is maintained in the therapeutic range (as Drs. Côté and Bouchard reported) of 210  $\mu\text{M}$  for more than 18 h (as shown in fig. 1), almost all patients will develop hepatotoxicity. For acetaminophen, there is no such thing as a therapeutic range of plasma level.

More than 90% of acetaminophen in the body is metabolized by way of conjugation, two thirds through glucuronidation and one third



**Fig. 1. Rumack-Matthew acetaminophen nomogram. The nomogram shows the relation between plasma acetaminophen concentration, time after drug ingestion, and the risk for hepatotoxicity. From Larson<sup>4</sup>; adapted with permission.**

through sulfation.<sup>6</sup> Approximately 5-9% undergoes oxidative conversion by CYPs (CYP1A2, CYP2E1, CYP3A4) to the toxic metabolite *N*-acetyl-*p*-benzoquinone imine (NAPQI).<sup>7</sup> CYP2E1 is the major source of NAPQI, with less contribution from CYP1A2 and CYP3A4. NAPQI is rapidly metabolized by conjugation with glutathione, forming a nontoxic acetaminophen-glutathione conjugate.<sup>8</sup> The degree of hepatic toxicity correlates with the activity of the metabolic pathway and glutathione availability. Overdoses of acetaminophen lead to the saturation of the glucuronidation and sulfation pathways, shunting more acetaminophen into the CYP system. The increased metabolism of acetaminophen by the CYP system increases the production of NAPQI. Glutathione stores within the liver are limited and will be depleted in an attempt to metabolize the increased NAPQI, and then NAPQI will accumulate, leading to hepatotoxicity.<sup>9</sup> Cisapride has been shown to inhibit conjugation of acetaminophen *via* glucuronidation without affecting conjugation *via* sulfation.<sup>10</sup> The coadministration of acetaminophen with cisapride can reduce acetaminophen glucuronide conjugate concentration and increase the availability of acetaminophen into the CYP system. Therefore, cisapride may be able to lead hepatotoxicity at therapeutic doses of acetaminophen. In addition, there is evidence that induction of CYPs other than CYP2E1, such as CYP1A2 and CYP3A4, can increase oxidative metabolism of acetaminophen, leading to hepatotoxicity at therapeutic dosages.<sup>11,12</sup> Although omeprazole has been shown to be a strong inducer of CYP1A2 and a weak inducer of CYP3A4,<sup>12</sup> omeprazole does not increase oxidative metabolism at therapeutic doses of acetaminophen.<sup>13</sup> However, at overdoses of acetaminophen, the inducers could augment the hepatotoxic effect.<sup>14</sup> It is most likely that the combination of cisapride and omeprazole in the case reported by Drs. Côté and Bouchard contributed to decreased conjugation *via* glucuronidation and increased oxidative metabolism of acetaminophen, leading to hepatotoxicity in the presence of acetaminophen overdose.

The absence of any problem with the liver after an eye procedure during total intravenous anesthesia 7 months later does not support the notion that the previous event was desflurane-induced hepatotoxicity. Possible explanations for the absence of hepatotoxicity after the eye

The above letter was sent to the authors of the referenced report. The authors did not feel that a response was required.—James C. Eisenach, M.D., Editor-in-Chief.

surgery despite the use of acetaminophen for pain control (which I assume they used) include the cessation of omeprazole and cisapride medication after successful Nissen fundoplication and the use of a much smaller dosage of acetaminophen after the eye surgery.

The case reported by Drs. Côté and Bouchard might be a case of desflurane-induced hepatotoxicity. However, based on the case report they described, it is a case of acetaminophen-induced hepatotoxicity.

**Charles Her, M.D., F.C.C.P.,** New York Medical College, Valhalla, New York. charles6133@msn.com

## References

1. Côté G, Bouchard S: Hepatotoxicity after desflurane anesthesia in a 15-month-old child with Mobius syndrome after previous exposure to isoflurane. *ANESTHESIOLOGY* 2007; 107:843-5
2. Lewis JH, Zimmerman HJ, Ishak KG, Mullick FG: Enflurane hepatotoxicity: A clinicopathologic study of 24 cases. *Ann Intern Med* 1983; 98:984-92
3. Rumack BH, Matthew H: Acetaminophen poisoning and toxicity. *Pediatrics* 1975; 55:871-6
4. Larson AM: Acetaminophen hepatotoxicity. *Clin Liver Dis* 2007; 11:525-48
5. Rivera-Penera T, Gugig R, Davis J, McDiarmid S, Vargas J, Rosenthal P, Berquist W, Heyman MB, Ament ME: *J Pediatr* 1997; 130:300-4

6. Watkins PB, Seeff LB: Drug-induced liver injury: Summary of a single topic clinical research conference. *Hepatology* 2006; 43:618-31

7. Manyike PT, Kharasch ED, Kalhorn TF, Slattery JT: Contribution of CYP2E1 and CYP3A to acetaminophen reactive metabolite formation. *Clin Pharmacol Ther* 2000; 67:275-82

8. Kaplowitz N: Acetaminophen hepatotoxicity: What do we know, what don't we know, and what do we do next? *Hepatology* 2004; 40:23-6

9. Mitchell JR, Jollow DJ, Potter WZ, Gillette JR, Brodie BB: Acetaminophen-induced hepatic necrosis. *J Pharmacol Exp Ther* 1973; 187:211-7

10. Itoh H, Nagano T, Takeyama M: Cisapride raises the bioavailability of paracetamol by inhibiting its glucuronidation in man. *J Pharm Pharmacol* 2001; 53:1041-5

11. Schmidt LE, Dalhoff K: The impact of current tobacco use on the outcome of paracetamol poisoning. *Aliment Pharmacol Ther* 2003; 18:979-85

12. Nishimura M, Koeda A, Suganuma Y, Suzuki E, Shimizu T, Nakayama M, Satoh T, Narimatsu S, Naito S: Comparison of inducibility of CYP1A and CYP3A mRNAs by prototypical inducers in primary cultures of human, cynomolgus monkey, and rat hepatocytes. *Drug Metab Pharmacokinet* 2007; 22:178-86

13. Xiaodong S, Gatti G, Bartoli A, Cipolla G, Crema F, Perucca E: Omeprazole does not enhance the metabolism of phenacetin, a marker of CYP1A2 activity, in healthy volunteers. *Ther Drug Monit* 1994; 16:248-50

14. Cheung L, Potts RG, Meyer KC: Acetaminophen treatment nomogram. *N Engl J Med* 1994; 330:1907-8

(Accepted for publication May 15, 2008.)

Anesthesiology 2008; 109:571

Copyright © 2008, the American Society of Anesthesiologists, Inc. Lippincott Williams & Wilkins, Inc.

## Two Cases with Past and Family History of Febrile Convulsion Developed Seizure-like Movements during Sevoflurane Anesthesia

*To the Editor:*—Febrile convulsion in children is considered to develop because, as their brain is still immature, they are hypersensitive to hyperthermia. The incidence of febrile convulsions is highest in patients aged 6 months to 3 yr and rare in patients older than 6 yr.<sup>1</sup> Although the precise risk of developing epilepsy after febrile convulsions is uncertain, febrile convulsions are known to be associated with epilepsy in childhood.<sup>2</sup> Epileptic subjects are particularly sensitive to the epileptogenic effect of sevoflurane; however, the degree to which history of febrile convulsions contributes to the epileptogenic effect of sevoflurane has not been determined.<sup>3</sup> Here, we report the cases of two pediatric patients with a personal and family history of febrile convulsion who experienced seizure-like movements during general anesthesia.

*Case 1:* A 10-yr-old boy was scheduled to undergo an appendectomy for a perforation caused by appendicitis. The patient had experienced febrile convulsions at the age of 3 yr, and his father had a history of them as well. At the time the patient entered the operating room, his axillary temperature was 38.9°C. General anesthesia was induced by 2-3% sevoflurane, 2 l/min oxygen, and 4 l/min nitrous oxide. Twenty minutes after the start of surgery, generalized tonic-clonic seizure-like movements were observed in the patient for 60 s. They disappeared after the administration of 2.5 mg midazolam and reappeared 25 min later. The patient's rectal temperature was 38.9°C. Sevoflurane was replaced by 6 mg · kg<sup>-1</sup> · h<sup>-1</sup> propofol, and the seizure-like movements did not recur. The patient's body surface was cooled by air blasting. His rectal temperature was 38.2°C at the completion of surgery. After the patient awoke from anesthesia, a clinical examination by a pediatrician was conducted, and no significant abnormalities were observed.

*Case 2:* A 4-yr-old girl was scheduled to undergo an appendectomy for appendicitis. She had experienced febrile convulsions at the ages of 1 and 2 yr, and her father had a history of them as well. General anesthesia was induced by 2-3% sevoflurane, 2 l/min oxygen, and 4 l/min nitrous oxide. The patient's rectal temperature was 37.8°C. Immediately after surgery, while the patient was awakening from anesthesia, rolling of her eyes and generalized tonic-clonic seizure-like movements were observed for 5 s

but resolved spontaneously. The seizure-like movements then reappeared, persisted for 30 s, and then disappeared after the administration of 1 mg midazolam. After the patient awoke from anesthesia, a clinical examination by a pediatrician revealed no significant abnormalities.

When seizure-like activities were observed during sevoflurane anesthesia, the rectal temperatures in cases 1 and 2 were 38.9° and 37.8°C, respectively. Although the direct cause of the seizure-like movements in both cases could not be determined, hyperthermia and sevoflurane were considered to be major contributing factors. An increase in the temperature of neuronal tissue could enhance the rate, magnitude, or synchrony of neuronal firing.<sup>2</sup> However, seizure-like movements during sevoflurane anesthesia are most often described during masked induction of anesthesia when sevoflurane at high concentrations (4-8%) is administered; epileptiform electroencephalographic activity has been recorded in healthy subjects at 1.5-2 minimum alveolar concentration levels (2.5-3.3%) of sevoflurane anesthesia.<sup>3</sup> In addition, because febrile seizures do not generally occur in the age group of the two patients, it is possible that the interaction of the increased temperature and sevoflurane elicited neuronal excitability in patients susceptible to febrile convulsions, particularly in those with a positive family history. Although malignant hyperthermia was considered, the rapid recovery of the patients and the absence of a family history for malignant hyperthermia made this unlikely. The incidence of serum creatine kinase increase was not observed in these patients.

**Takeshi Yano, M.D.,\* Shigeaki Okubo, M.D., Hiroaki Naruo, M.D., Tatsuma Iwasaki, M.D., Mayumi Takasaki, M.D., Isao Tsuneyoshi, M.D.** \*National Hospital Organization Miyakonojo Hospital, Miyazaki, Japan. ytake11271@nifty.com

## References

1. Waruiru C, Appleton R: Febrile seizures: An update. *Arch Dis Child* 2004; 89:751-6
2. Dubé CM, Brewster AL, Richichi C, Zha Q, Baram TZ: Fever, febrile seizures and epilepsy. *Trends Neurosci* 2007; 30:490-6
3. Constant I, Seeman R, Murat I: Sevoflurane and epileptiform EEG changes. *Paediatr Anaesth* 2005; 15:266-74

(Accepted for publication June 4, 2008.)

Support was provided solely from institutional and/or departmental sources.